Minimally invasive high-definition microscope assisted small channel treatment of lumbar disc herniation in children: a case report

Hao Yuan
Zunyi Medical College Affiliated Hospital: Affiliated Hospital of Zunyi Medical College
Nan Zhao
Zunyi Medical College Affiliated Hospital: Affiliated Hospital of Zunyi Medical College
Jun Ao
Zunyi Medical College Affiliated Hospital: Affiliated Hospital of Zunyi Medical College
Lv Sun
Zunyi Medical College Affiliated Hospital: Affiliated Hospital of Zunyi Medical College
Chong Wang
Zunyi Medical College Affiliated Hospital: Affiliated Hospital of Zunyi Medical College
Liu-Lin Xiong (liulin.xiong@mymail.unisa.edu.au)
Zunyi Medical College Affiliated Hospital: Affiliated Hospital of Zunyi Medical College
https://orcid.org/0000-0002-1623-5969

Technical note

Keywords: Lumbar disc herniation, minimally invasive, high-definition microscope

Posted Date: April 26th, 2021

DOI: https://doi.org/10.21203/rs.3.rs-392077/v1

Abstract

Background: Despite lumbar disc herniation (LDH) is common in adults, it is extremely rare in children. The treatment of LDH in children is still a challenge for surgeons. This study aimed to explore the pathogenesis, clinical characteristics and treatment methods of LDH in children for communication and learning.

Methods: In October 2017, a child with LDH who failed to receive conservative treatment underwent surgical treatment. The child underwent minimally invasive high-definition microscope-assisted nucleus pulposus resection and nerve root decompression. The soft tissues such as muscles and paravertebral ligaments were separated and removed under microscope, the nucleus pulposus of disc herniation was removed, and the left lumbar 5 nerve root was decompressed. During the short-term and long-term follow-up after operation, the assessment pain was significantly improved, the activity was not limited, and the muscle strength returned to normal.

Results: The next day after operation, the child could wear ordinary waist circumference to get out of bed, and the left lower limb muscle strength returned to grade 4-5, and were discharged 5 days after operation. After 3 years of telephone follow-up, the patient complained that the pain was significantly relieved, the left lower limb movement was not limited, and the muscle strength returned to normal.

Conclusions: In this case, the minimally invasive high-definition microscope assisted small channel treatment of LDH in children was successful, and the postoperative recovery was good. It can provide reference for LDH in children who need surgical treatment when conservative treatment was ineffective.

Introduction

Lumbar disc herniation (LDH) is a common condition in adults, nevertheless in children is extremely rare. Although the incidence of the disease is not high in children, the lack of proper and timely treatment will affect their growth and mental health. The clinical treatment strategy of LDH in children is mainly conservative treatment. However, when the sensory, motor and reflex changes occur in children with neurological impairment and the conservative treatment does not significantly improve, early surgery should be performed as much as possible, which is conducive to the recovery of postoperative nerve function and avoid further aggravation of injury [1, 2]. The traditional posterior open surgery decompression has great damage to the spinal stability of patients. With the popularization and application of minimally invasive techniques in spinal neurosurgery, a variety of surgical methods for the treatment of LDH have been developed in recent years. Among them, microscopic channel assisted discectomy and decompression is one of the common techniques [3, 4]. In October 2017, our hospital successfully performed nucleus pulposus resection and nerve root decompression for one child with LDH under a minimally invasive high-definition microscope assisted small channel. The children were followed up for 3 years after operation, and the results showed that the operation was effective,as reported below.

Case Report

A 13-year-old boy was admitted to hospital for "repeated left low back pain for 2 years." The child ' s parents narrated that the child had left back and leg pain after 2 years ago without obvious trauma and other inducements, and the initial pain was not obvious at the beginning of the onset, and there was no involved pain, and the symptoms were relieved after bed rest. In recent 6 months, the pain was aggravated and accompanied by radiation pain of the left lower limb, and the activity was limited, so he treated in our hospital. Physical examination showed that the child was forced to posture, left lower limb straight leg elevation test (+), acupuncture examination showed that the left lateral leg and left foot dorsal pain than the right side of the same site, left lower limb muscle strength grade 4, pathological sign (-), Frankel score was D.

Frontal and lateral X-ray films showed lumbar curvature straightened, no intervertebral space stenosis and ossification at the posterior edge of vertebral body (Fig. 1). The results of lumbar magnetic resonance imaging (MRI) showed that the left side of lumbar 4–5 intervertebral disc was prominent, and the nucleus pulposus was compressed into the dura and nerve root, and the spinal canal was narrowed (Fig. 2). Other examination results were unremarkable. The diagnosis was LDH and lumbar 5 nerve root disease in children. After admission, the relevant examination was completed, and the symptoms were not relieved after 6 weeks of conservative treatment. After discussion in the department, it was suggested that active surgical treatment should be performed. The surgical method was minimally invasive high-definition microscope assisted small channel discectomy and nerve root decompression.

The patient entered the operating room after sufficient preoperative preparation and then monitored vital signs. The right upper limb had an open venous channel, and oxygen was given at a flow rate of 2 L/minute (min) through the mask. After anesthesia induction, and the surgical segment was confirmed under the fluoroscopy positioning of the "C" arm X-ray machine, and the body surface was marked. The puncture point was set at 9–12 millimeter (mm) beside the midline. We used the percutaneous needle to locate the articular process of the responsible gap, positioned and punctured the Kirschner wire to the desired lamina space, and the expansion sleeve was bluntly separated along the Kirschner wire to separate ligaments, paravertebral muscles and other tissues. Finally, the surgical channel was placed and fixed along the sleeve. The soft tissues such as muscles and paravertebral ligaments were separated and removed under microscope. Part of the lamina was removed by bite forceps, and the ligamentum flavum in the spinal canal was removed. The upper edge of the resection reached the attachment edge of the medial edge of the upper lamina, the lower edge reached the attachment point of the upper edge of the lower lamina, and the lateral reached the medial side of the articular process to fully expose the spinal canal, dural sac and nerve root. Gently pulled the nerve root and dural sac to the opposite side to exposed the herniated intervertebral disc, removed the herniated nucleus pulposus, and decompressed the left lumbar 5 nerve root. The lumbar 5 nerve root could be liberated through the channel, and the wound was washed and closed after the operation (Fig. 3).

outine antibiotics were used to prevent infection 1 day after operation. The next day after operation, the child could wear ordinary waist circumference to get out of bed, and the left lower limb muscle strength returned to grade 4–5, and were discharged 5 days after operation. Physical examination before discharge: left lower limb straight leg raising test (-), left leg anterolateral, foot back acupuncture pain improvement, left lower limb muscle strength grade 5, pathological sign (-), Frankel score was D. Reexamination of lumbar CT showed satisfactory spinal canal decompression and no obvious protrusion of nucleus pulposus; MRI showed satisfactory decompression of spinal canal and no obvious compression of dura (Fig. 4). After 3 years of telephone follow-up, the patient complained that the pain was significantly relieved, the left lower limb movement was not limited, and the muscle strength returned to normal. At present, the patient has returned to normal life and learning, Frankel score was E.

Discussion

LDH is a common lumbar lesion, which could lead to low back pain and lower extremity radicular pain [5, 6]. It is prevalent in older people, but extremely rare in adolescents. According to previous reports, the incidence of LDH in pediatric and adolescent populations varied from 1 % to 5 % in those who were 20 years old or younger [7–9]. The pathogenesis is unclear in children and adolescents, but trauma, genetics and dysfunctional biomechanical conditions are likely contributory [10]. In childhood, the elasticity of the fibrocartilaginous ring of the intervertebral disc is better, and the well-hydrated-like nucleus pulposus also has the effect of mitigating impact. Therefore, the intervertebral disc in childhood has strong compression resistance and less calcification, and the damage of the intervertebral disc is mostly cartilage plate, and the fibrocartilaginous ring rarely ruptured [11]. In the past, it was thought that intervertebral disc degeneration would not occur before the age of 20, but recent studies have shown that intervertebral disc degeneration can occur before the age of 10 [12].

The symptoms of LDH in children are mostly atypical. In this case, the main manifestation of the child was discogenic pain caused by nerve root compression, and there were left limb weakness and progressive aggravation of symptoms. At present, there are few reports and insufficient understanding of LDH in children in China, and it is often misdiagnosed as lumbar sprain and rheumatic myocarditis in children [13]. Since the application of computed tomography (CT) and MRI imaging examinations, the accuracy of diagnosis has been improved. LDH in children does not often have the common signs and symptoms of adult LDH. It’s typical symptoms and signs include low back pain, limited flexion, abnormal gait and limited straight leg elevation. And it is worth noting that the pain is not obvious, neurological examination is rarely found positive. With the advantage of high resolution, MRI has become the most useful tool in diagnosing lumbar lesions [14].

Considering that adolescent spine is in the stage of growth and development and the intervertebral disc are not yet mature, most scholars believe that surgical treatment has large trauma, many complications and postoperative recurrence, so non-surgical treatment is advocated [15]. However, some scholars believe that degenerative changes have not occurred in adolescent intervertebral discs. Most children with

endplate rupture of cartilage and local epiphyseal ring penetrate into the spinal canal together, and the protrusion often contains cartilage and bone components. Due to the small size and tension plasticity of the protrusion, early surgical treatment is advocated. In this case, we believed that the child had initially adopted non-surgical treatment, but after a period of conservative treatment, it was ineffective, and the left lower limb had sensory, muscle strength, and reflex changes. At the same time, the MRI examination results suggested that the nucleus pulposus was to compress the dura or nerve root. Based on this situation, we considered that surgery should be performed in time to prevent the prolonged conservative time from aggravating the neurological damage of children.

In the selection of surgical types, there are many controversies about the surgical methods of LDH in children [1,3,4,16–18]. Some scholars suggested that the intervertebral disc tissue should be removed as little as possible, as long as the purpose of nerve root decompression was achieved. Some scholars believe that the degenerative nucleus pulposus and the ruptured posterior annulus fibrosus should be completely removed, and the internal annulus fibrosus should be retained as much as possible, which is conducive to the regeneration of intervertebral disc and helps to prevent the recurrence of intervertebral disc herniation. In recent years, endoscopic surgery such as discoscope and intervertebral foramen mirror has been carried out through muscle expansion approach, which reduces the iatrogenic soft tissue injury caused by conventional surgery and reduces the probability of postoperative chronic lumbar pain. The use of endoscopic instruments to remove the compressed nerve intervertebral disc has achieved good clinical effect, which is equivalent to the clinical effect of traditional surgery. The postoperative recovery is fast and the complications are few, and there is no significant adverse effect on spinal stability. However, due to the limitation of endoscopic instruments, it is not suitable to use micro high-speed grinding drill, Kerrison bone biting forceps and other instruments during the operation, and the nerve decompression for some severe spinal stenosis is not sufficient. For children with endplate rupture of cartilage and local epiphysis ring, it is more likely to penetrate into the spinal canal, and the decompression effect of minimally invasive endoscopic surgery alone may not be satisfactory. Therefore, in this case, we adopted minimally invasive combined with microscopic laminectomy, which not only retained the articular process joints, spinous processes and interspinous ligaments, but also well revealed the satisfactory surgical vision of the spinal canal combined with microscope. The free nucleus pulposus and ruptured annulus fibrosus could be completely removed, and the epiphyseal tissue that penetrated into the spinal canal could be resected together, so as to completely relieve the pressure on nerve roots and dura mater, and avoid the occurrence of lumbar spinal stenosis.

In this case, combined with the symptoms, signs and imaging data of children, the diagnosis was more clearly, and the symptoms did not improve and showed an aggravating trend during hospitalization. Therefore, surgical treatment was selected. For the selection of specific surgical procedures, the minimally invasive high-definition microscope with small influence on the later life of the child was selected to assist the operation under small channels, and the waist circumference was fixed after operation to increase the stability of the lumbar spine. According to the current follow-up, the short-term and long-term recovery of children are ideal.

Conclusions

In this case, the curative effect of minimally invasive high-definition microscope assisted small-channel surgery in the treatment of LDH in children was satisfactory. According to the current follow-up, no complications occurred and the recovery was good, suggesting that this surgical method can be used as one of the treatment methods for children with failed conservative treatment and nerve root symptoms.

Abbreviations

LDH: Lumbar disc herniation

MRI: Magnetic resonance imaging

CT: Computed tomography

Declarations

Availability of data and materials

The datas are available from the corresponding author upon reasonable request.

CT: Computed tomography

Acknowledgements

No.

Authors’contributions

Hao Yuan and Jun Ao performed the operations, collected the clinical data. Nan Zhao and Liu-lin Xiong completed the manuscript. Chong Wang and Lv Sun participated in the operations. All authors have no conflicts of interest to disclose. All authors have read and approved the final submitted manuscript.

Funding

This research was funded by the Guizhou Provincial Department of Science and Technology (Grant number: LC (2021)002) and Joint Fund of Zunyi Science and Technology Bureau-Affiliated Hospital of Zunyi Medical University (No. HZ2020220). New technical name: minimally invasive high-definition microscope assisted small channel lumbar disc herniation nucleus pulposus resection, nerve root decompression.

Ethics

Informed consent was obtained from the patient, and the disclosure of this clinical case was approved by the Ethics Committee of Zunyi Medical University (The ethics approval number is KLL-2020-214). This

case strictly adheres to the ethical standards of the Declaration of Helsinki and the International Ethical Guidelines for Human Biomedical Research.

Consent for publication

Consent for publication was obtained from all participants.

Competing interests

All authors have no conflicts of interest to disclose. All authors have read and approved the final submitted manuscript.

Authors' information (optional)

Affiliations

Department of Spinal Surgery, The Affiliated Hospital of Zunyi Medical University, Zunyi 563000, Guizhou, China.

Hao Yuan, Jun Ao, Lv Sun, Chong Wang

Department of Anesthesiology, The Affiliated Hospital of Zunyi Medical University, Zunyi 563000, Guizhou, China.

Nan Zhao & Liu-Lin Xiong

Department of Anesthesiology, Hospital of Stomatology, Zunyi Medical University, Zunyi, Guizhou, China.

Nan Zhao

References

1. Fakouri B, Nnadi C, Boszczyk B, et al. When is the appropriate time for surgical intervention of the herniated lumbar disc in the adolescent? J Clin Neurosci, 2009, 16: 1153-1156.
2. Raghu ALB, Wiggins A, Kandasamy J. Surgical management of lumbar disc herniation in children and adolescents. Clin Neurol Neurosurg, 2019, 185: 105486.
3. Zheng C, Wu F, Cai L. Transforaminal percutaneous endoscopic discectomy in the treatment of far-lateral lumbar disc herniations in children. Int Orthop, 2016, 40: 1099-1102.
4. Wang X, Zeng J, Nie H, et al. Percutaneous endoscopic interlaminar discectomy for pediatric lumbar disc herniation. Childs Nerv Syst, 2014, 30: 897-902.
5. Cilingir D, Hintistan S, Yigitbas C. Nonmedical methods to relieve low back pain caused by lumbar disc herniation: a descriptive study in northeastern Turkey. Pain Manag Nurs. 2014, 15: 449-457.

6. Toyone T, Tanaka T, Kato D, et al. Low-back pain following surgery for lumbar disc herniation. A prospective study. J Bone Joint Surg Am. 2004, 86-A: 893-896.
7. Bradbury N, Wilson LF, Mulholland RC. Adolescent disc protrusions. A long-term follow-up of surgery compared to chymopapain. Spine (Phila Pa 1976). 1996, 21: 372-377.
8. Kumar R, Kumar V, Das NK, et al. Adolescent lumbar disc disease: findings and outcome. Childs Nerv Syst. 2007, 23: 1295-1299.
9. Lee JY, Ernestus RI, Schroder R, et al. Histo-logical study of lumbar intervertebral disc herni-ation in adolescents. Acta Neurochir (Wien). 2000, 142: 1107-1110.
10. Lavelle WF, Bianco A, Mason R, et al. Pediatric disk herniation. J Am Acad Orthop Surg, 2011, 19: 649-656.
11. Dang, Lei, Chen, et al. Lumbar Disk Herniation in Children and Adolescents: The Significance of Configurations of the Lumbar Spine. Neurosurgery, 2015, 77(6): 954-959.
12. Alexiou GA, Stefanaki K, Sfakianos G, et al. Lumbar disc herniation in a child with cystic fibrosis: case report. Archivos Argentinos De Pediatria, 2014, 112(2): e43.
13. McAvoy M, McCrea HJ, Chavakula V, et al. Long-term outcomes of lumbar microdiscectomy in the pediatric population: a large single-institution case series. J Neurosurg Pediatr, 2019, 24(5): 1-9.
14. Eun SS, Lee HY, Lee SH, et al. MRI versus CT for the diagnosis of lumbar spinal ste-nosis. J Neuroradiol. 2012, 39: 104-109.
15. Karademir M, Eser O, Karavelioglu E. Adolescent lumbar disc herniation: Impact, diagnosis, and treatment. J Back Musculoskelet Rehabil, 2017, 30: 347-352.
16. Lagerbäck T, Elkan P, Möller H, et al. An observational study on the outcome after surgery for lumbar disc herniation in adolescents compared with adults based on the Swedish Spine Register. Spine J, 2015, 15: 1241-1247.
17. Gulati S, Madsbu MA, Solberg TK, et al. Lumbar microdiscectomy for sciatica in adolescents: a multicentre observational registry-based study. Acta Neurochir (Wien), 2017, 159: 509-516.
18. Kwon DW, Kim KH, Park JY, et al. Clinical outcomes and considerations of the lumbar interbody fusion technique for lumbar disk disease in adolescents. Childs Nerv Syst, 2013, 29(8): 1339-1344.

Figures

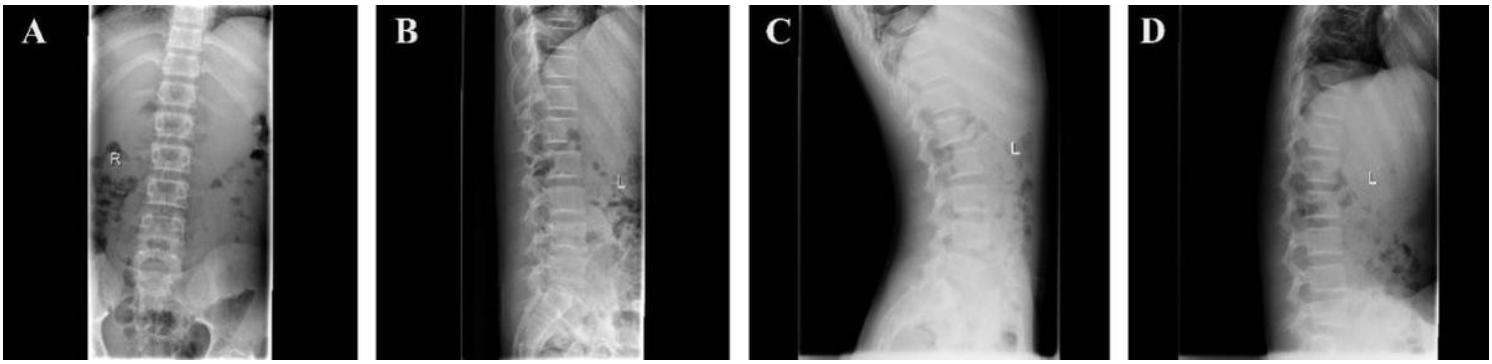

Figure 1

X-ray of lumbar spine before operation. (A–B) Frontal and lateral X-ray films showed lumbar curvature straightened, no intervertebral space stenosis and ossification at the posterior edge of vertebral body. (C–D) There was no obvious displacement of vertebral body in lumbar hyperextension and hyperflexion X-ray films.

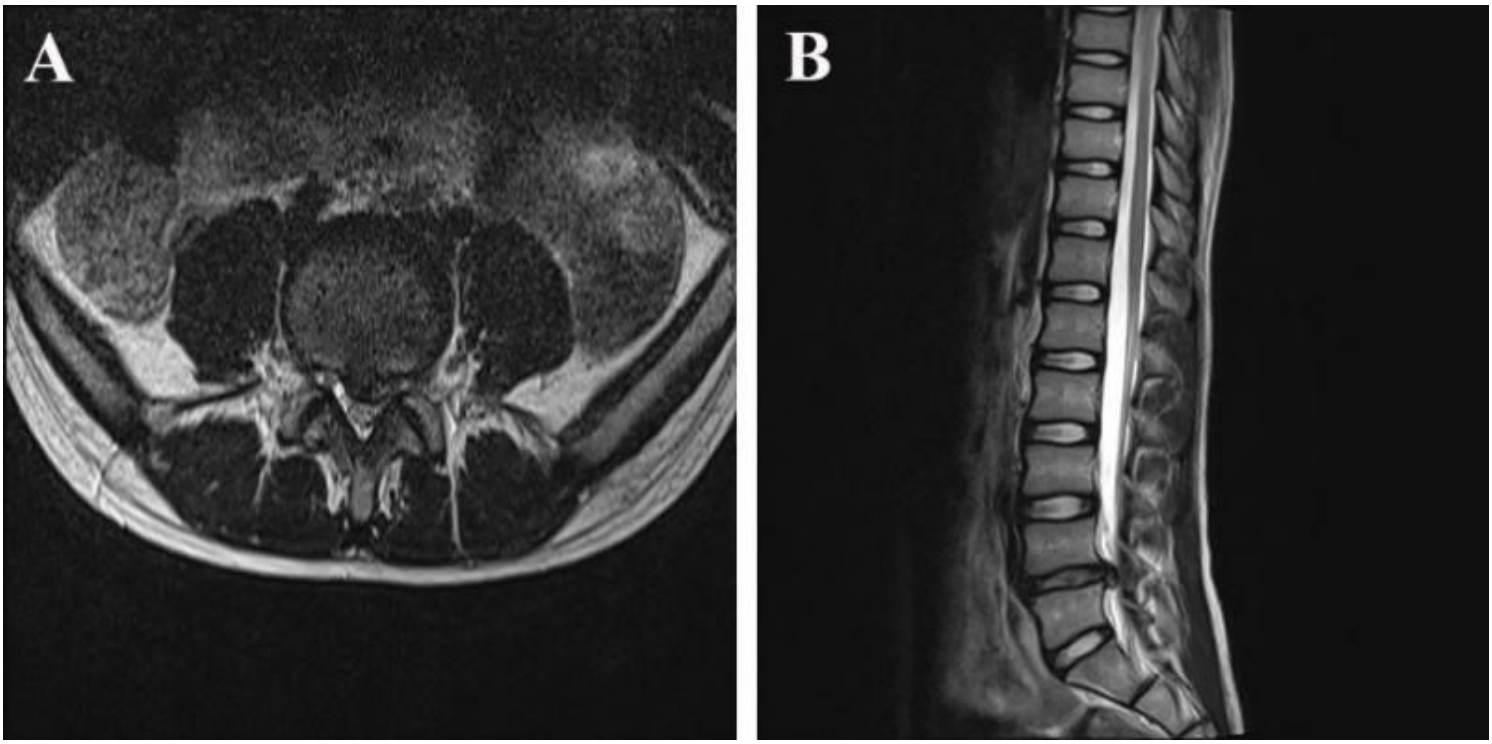

Figure 2

MRI of lumbar spine before operation. (A) The left side of L4-5 intervertebral disc was prominent, and the nucleus pulposus was compressed into the dura and nerve root, and the spinal canal was narrowed. (B) The L4-5 intervertebral discs were prominent and the spinal canal was narrow.

Figure 3

Pictures of intraoperative operation. (A) L5 nerve root release was seen in the channel. (B) Minimally invasive incision after operation. (C) Operation under high-definition microscope.

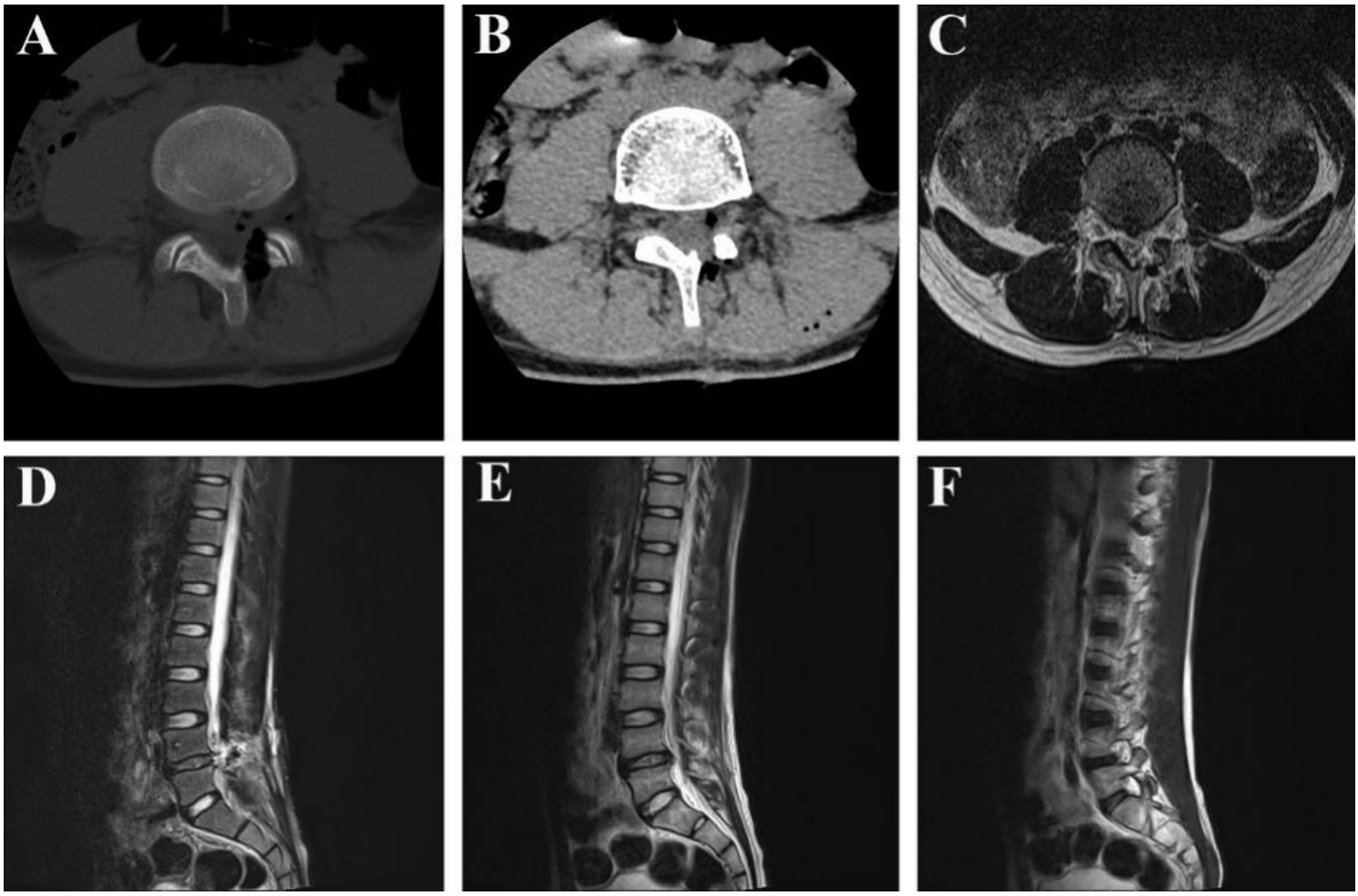

Figure 4

CT and MRI of lumbar spine after operation. (A, B) CT showed complete decompression of lamina window, satisfactory decompression of spinal canal, no obvious prominent nucleus pulposus. (C) MRI showed satisfactory spinal canal decompression. (D) MRI showed traces of posterior channel implantation. (E, F) MRI showed satisfactory decompression of spinal canal and no obvious compression of dura.