Osteoid Osteoma Intracanalis of the Cervical Spine : a rare case

Sabri Ibrahim (sabriibrahimnc@usu.ac.id)
Universitas Sumatera Utara

Steven Tandean
Universitas Sumatera Utara

Muhammad Ari Irsyad
Universitas Sumatera Utara

Nindi Lizen
Universitas Sumatera Utara

Case report

Keywords: osteoid osteoma, spine, cervical

Posted Date: May 14th, 2021

DOI: https://doi.org/10.21203/rs.3.rs-398728/v1

Abstract

Background

Osteoid osteoma is benign, accounted for 10–40% of spine tumours, Majority occurred in the lumbar spine which occurred in 59%, in spine frequently located in lamina, pedicles, or the transverse and spinous process. Pain is the most common symptoms, classically almost present at night and may awaken the patients. Imaging with CT scan may reveal a focal dense lesion with sclerotic reactive bone, and calcification may appeared. On MRI it may not be as specific as CT. CT guided radiofrequency ablation was safe and effective in spinal osteoid osteoma, but with proximity to neurological structures may not indicated in this group of patients

Case Presentation

Female 61 years old, came to our emergency department with chief complaint of weakness of lower extremities. This has occurred for 5 years and worsening every year. History of neck pain was found. Patient also complained about numbness in both hand and foot for the last 5 years. On physical examination, hyporeflex was found in lower extremities, with motoric of 2 and motoric of 4 in the hand. Sensation was normal in patient. Laminectomy was done on C7/T1, after laminectomy, the flavum ligament was still present, after resecting the ligament, the compact bone in vertebral canal compressing the spinal cord contralaterally, resulting thinning of spinal cord. Using high speed drill, the bone was drilled slowly until reaching the posterior corpus vertebrae.

Discussion

Osteoid osteoma comprised of 10–12% total spinal tumour with cell origin of osteoblast and occurred in 1st and 2nd decade of life, occurred mostly in lumbar and predominant in female. Osteoid osteoma comprised of 10–12% total spinal tumour with cell origin of osteoblast and occurred in 1st and 2nd decade of life and occurance is mostly present in lumbar, cervical and dominantly arising from posterior elements. Surgery is the preferred in patients with no recurrency and low remission of symptoms.

Conclusion

Osteoid osteoma is a benign case of spinal tumour and occurance is also low in all spinal tumor. Radiculopathy is the most common symptoms nonetheless neurological deficit is rarely present. Patients may respond well after surgery with no complication found.

Background

The term osteoma was first coined by Jaffe until Dahlin and Johnson put the term osteoid osteoma. On WHO classification, osteoid osteoma classified as soft tissue and bone tumour [1]. Osteoid osteoma is benign, accounted for 10–40% of spine tumours. Majority occurred in the lumbar spine which occurred in 59%, in spine frequently located in lamina, pedicles, or the transverse and spinous process [2]. Osteoid

osteoma mostly occurred in 5–25 years old and the dominance in male population with a ratio 3:1 to female [3].

Relatively present in 3% of all primary bone tumours, this benign phenomenon occurred only about 10% in all spine pathology [4]. The natural occurance remains unknown although some author stated that high level of prostaglandin E2 and prostacyclin have been found causing inflammation and vasodilatation. It is thought to be occurred because of increasing of the level in COX-2 in osteoblast and that this pathway may causing lesional sclerosing [5]. Local production of productions prostaglandin, plays an important role in the presentation of pain and may respond to NSAID treatment [6].

Mostly this case may be symptomatic with the most common presentation is painful in lesion region when has central nidus of 15 mm in diameter. The symptoms may vary in time, which possibly may occur in weeks or months, with characteristic of deep, aching and intensely painful. This classically almost present at night and may awaken the patients [7]. Reactive scoliosis was also reported in patients with spinal osteoid osteoma [8].

On X-ray imaging, this may appear as small, radiolucent surrounded by variably sclerosing lesion or thickening of cortical bone [9]. Detection of imaging wit CT scan preferred generally for demonstrating and localizing the lesion. Imaging with CT scan may reveal a focal dense lesion with sclerotic reactive bone, and calcification may appeared. On MRI it may not be as specific as CT, in which hyperemia and bone marrow edema may discourage the tumoral diagnosis[3]. On Histopathology, macroscopically may be appeared as nidus in distinct round or oval reddish area, and nidus may be soft and granular or may be hard and sclerotic. Histologically, this may be seen as small and well-defined area with irregularly bone trabeculae and varying mineralization [9].

Interstitial laser photocoagulation and percutaneous radiofrequency coagulation increasingly popular for treatment of non-spinal osteoid osteoma. CT guided radiofrequency ablation was safe and effective in spinal osteoid osteoma, but with proximity to neurological structures may not indicated in this group of patients. Most commonly method uses is the surgery and prognosis in relieving of pain is good in resection of tumour [10].

Here, we reported a case of osteoid osteoma in spine as a rare case.

Case Presentation

Female 61 years old, came to our emergency department with chief complaint of weakness of lower extremities. This has occurred for 5 years and worsening every year. History of neck pain was found. Patient also complained about numbness and weakness in foot for the last 5 years. On physical examination, hyporeflex was found in lower extremities, with motoric of 2 in lower extremities and motoric of 4 in both hands. Sensation was normal in patient. The imaging is seen in Fig. 1A, 1B

Laminectomy was done on C7/T1, after laminectomy, the flavum ligament was still present, after resecting the ligament, the compact bone in vertebral canal compressing the spinal cord contralaterally, resulting thinning of spinal cord (Fig. 1C, 1D). Using high speed drill, the bone was drilled slowly until reaching the posterior corpus vertebrae. After that, lateral mass screw placement was done on this patient.

Postoperatively, patient has good recovery and improving motor function. Neck pain was greatly reduced, and motoric level improved 1 point. Neck pain was not present and patient had been discharged prior to improvement after surgery. Histopathology examination was done with the diagnosis of osteoid osteoma (Fig. 1).

Discussion

We reported a case of female 61 years old complaining weakness of lower extremity and history of neck pain for almost 5 years, with numbness also found and worsening each year. Based on literature, osteoid osteoma comprised of 10–12% total spinal tumour with cell origin of osteoblast and occurred in 1st and 2nd decade of life and is mostly present in lumbar, cervical and dominantly arising from posterior elements [11]

In a study done by Zhou Z., et al in 2017 they concluded that in all spinal tumour dominantly occurred in female with total 17 patients, the demographic of male is 8 patients and female is 9 patients and the range of age is 16–67 years old. We also reported a case of female, 61 years old, the same with study done by Zhou Z [12].

Osteoid osteoma occurred in cortical bone is regarded as classical type and the one occurred in cancellous and subperiosteal bone remain less frequent. Osteoid osteoma may obscure the nidus, resulting in incomplete delineation of nidus which is caused by surrounding reactive bone formation. In our cases, we reported a case in which the pathology is in C7/T1. Tumour near neural foramen will attribute this sign. Often, the tumour may go into remission over 2 to 8 years. An algorithm for patients with osteoid osteoma in cervical spine has been made by Ozaki et al in 2002 (Fig. 2)

Based on study done by Davies M., et al in 2002, they identified 37 cases of osteoid osteoma and diagnosing osteoid osteoma using MRI and they concluded that 28 out of 37 cases, the nidus can be clearly visualised and seen as small focal abnormality. The role of imaging is to identify and localising the tumour, in terms of surgical planning, and many author suggested that CT scan is generally regarded better to visualise osteoid osteoma better than MRI [14].

For osteoid osteoma, surgery usually indicated in which group of patients with non controlled pain after medication and patients with risk of scoliosis. Options such as curettage, or excision may be offered in patients. A study done by Quraishi NA., et al in 2017, having 84 patients with osteoid osteoma undergone surgical treatment. They demonstrated that most of the tumour have dimension of 1.4 cm in left to right dimension and 1.31 cm in cephalad-caudal dimension. They concluded that most of patients undergone

surgical options with posterior approach with recurrency of 7% of total patients [15]. In our cases, surgical resection was done and patient had no worsening symptoms, also motoric improvement and neck pain was not found in patients.

Vanderschueren GM et al in 2009, using radiofrequency ablation concluded that this treatment is effective and safe for patients with spinal osteoid osteoma with success rate of 79% with no complication following and they suggested that lesion with 5 mm noncooled tip may be treated by radiofrequency ablation [16].

Conclusion

Osteoid osteoma is a benign case of spinal tumour and occurance is also low in all spinal tumor. Radiculopathy is the most common symptoms nonetheless neurological deficit is rarely present. Patients may respond well after surgery with no complication found.

List Of Abbreviations

CT: Computed Tomography

MRI : Magnestic Resonance Imaging

NSAID: Non-Steroidal Anti Inflammatory Drug

WHO: World Health Organization

Declarations

Ethics approval and consent to participate

Not applicable.

Consent for publication

A consent form has been signed by the patient. The original of the signed form is held by the institution and can be made available to the editors upon request

Availability of data and materials

Not applicable.

Competing interests

The authors declare that they have no competing interests

Funding

None

Author Contribution

SI, MAI, and NL are directly contributing in clinical case, creating and editing manuscript, and reviewing the manuscript

Acknowledgments

We would like to thank all the staff and residents of Neurosurgery Department of Universitas Sumatera Utara

Author details

[1]Sabri Ibrahim, Department of Neurosurgery Faculty of Medicine, Universitas Sumatera Utara, Indonesia. Correspondence : [sabriibrahimnc@usu.ac.id]. [2]Steven Tandean, Department of Neurosurgery Faculty of Medicine, Universitas Sumatera Utara, Indonesia: [steven_tandean@yahoo.com]. [3]Muhammad Ari Irsyad, Department of Neurosurgery Faculty of Medicine, Universitas Sumatera Utara, Indonesia. Correspondence: [ari_irsyad@usu.ac.id]. [3]Nindi Lizen, Department of Neurosurgery Faculty of Medicine, Universitas Sumatera Utara, Indonesia. Correspondence: [nindi.prokami@gmail.com]

References

1. Barlow E, Davies AM, Cool WP, Barlow D, Mangham DC. Osteoid osteoma and osteoblastoma: novel histological and immunohistochemical observations as evidence for a single entity. J Clin Pathol. 2013;66(9):768–74.
2. Gomes FS, Alves C, Cardoso PS, Ling TP. A Rare Case of an Osteoid Osteoma of the Cervical Spine. Case Reports in Orthopedic Research. 2020;3(2):79–87.
3. Albisinni U, Facchini G, Spinnato P, Gasbarrini A, Bazzocchi A. Spinal osteoid osteoma: efficacy and safety of radiofrequency ablation. Skeletal radiology. 2017;46(8):1087–94.
4. Gasbarrini A, Cappuccio M, Bandiera S, Amendola L, Van Urk P, Boriani S. Osteoid osteoma of the mobile spine: surgical outcomes in 81 patients. Spine. 2011;36(24):2089–93.
5. Noordin S, Allana S, Hilal K, Nadeem N, Lakdawala R, Sadruddin A, Uddin N. 2018. Osteoid osteoma: contemporary management. *Orthopedic reviews*, *10*(3).
6. Bhure U, Roos JE, Strobel K. Osteoid osteoma: multimodality imaging with focus on hybrid imaging. Eur J Nucl Med Mol Imaging. 2019;46(4):1019–36.
7. Martel J, Bueno Á, Nieto-Morales ML, Ortiz EJ. Osteoid osteoma of the spine: CT-guided monopolar radiofrequency ablation. Eur J Radiol. 2009;71(3):564–9.
8. Iyer RS, Chapman T, Chew FS. Pediatric bone imaging: diagnostic imaging of osteoid osteoma. Am J Roentgenol. 2012;198(5):1039–52.

9. Boscainos PJ, Cousins GR, Kulshreshtha R, Oliver TB, Papagelopoulos PJ. Osteoid osteoma. Orthopedics. 2013;36(10):792–800.
10. Chen YL, Jiang WY, Ma WH. 2020. Osteoid osteoma: lower back pain combined with scoliosis. *Journal of International Medical Research*, *48*(2), p.0300060520903873.
11. Chi JH, Bydon A, Hsieh P, Witham T, Wolinsky JP, Gokaslan ZL. Epidemiology and demographics for primary vertebral tumors. Neurosurg Clin N Am. 2008;19(1):1–4.
12. Zhou Z, Wang X, Wu Z, Huang W, Xiao J. Epidemiological characteristics of primary spinal osseous tumors in Eastern China. World J Surg Oncol. 2017;15(1):1–8.
13. Gadiya A, Shah K, Patel P, Nene A. 2019. Osteoid osteoma of cervical spine: a case report and review of literature. *Journal of orthopaedic case reports*, *9*(1), p.78.
14. Davies M, Cassar-Pullicino VN, Davies MA, McCall IW, Tyrrell PN. The diagnostic accuracy of MR imaging in osteoid osteoma. Skeletal radiology. 2002;31(10):559–69.
15. Quraishi NA, Boriani S, Sabou S, Varga PP, Luzzati A, Gokaslan ZL, Fehlings MG, Fisher CG, Dekutoski MB, Rhines LD, Reynolds JJ. A multicenter cohort study of spinal osteoid osteomas: results of surgical treatment and analysis of local recurrence. The Spine Journal. 2017;17(3):401–8.
16. Vanderschueren GM, Obermann WR, Dijkstra SP, Taminiau AH, Bloem JL, van Erkel AR. Radiofrequency ablation of spinal osteoid osteoma: clinical outcome. Spine. 2009;34(9):901–3.

Figures

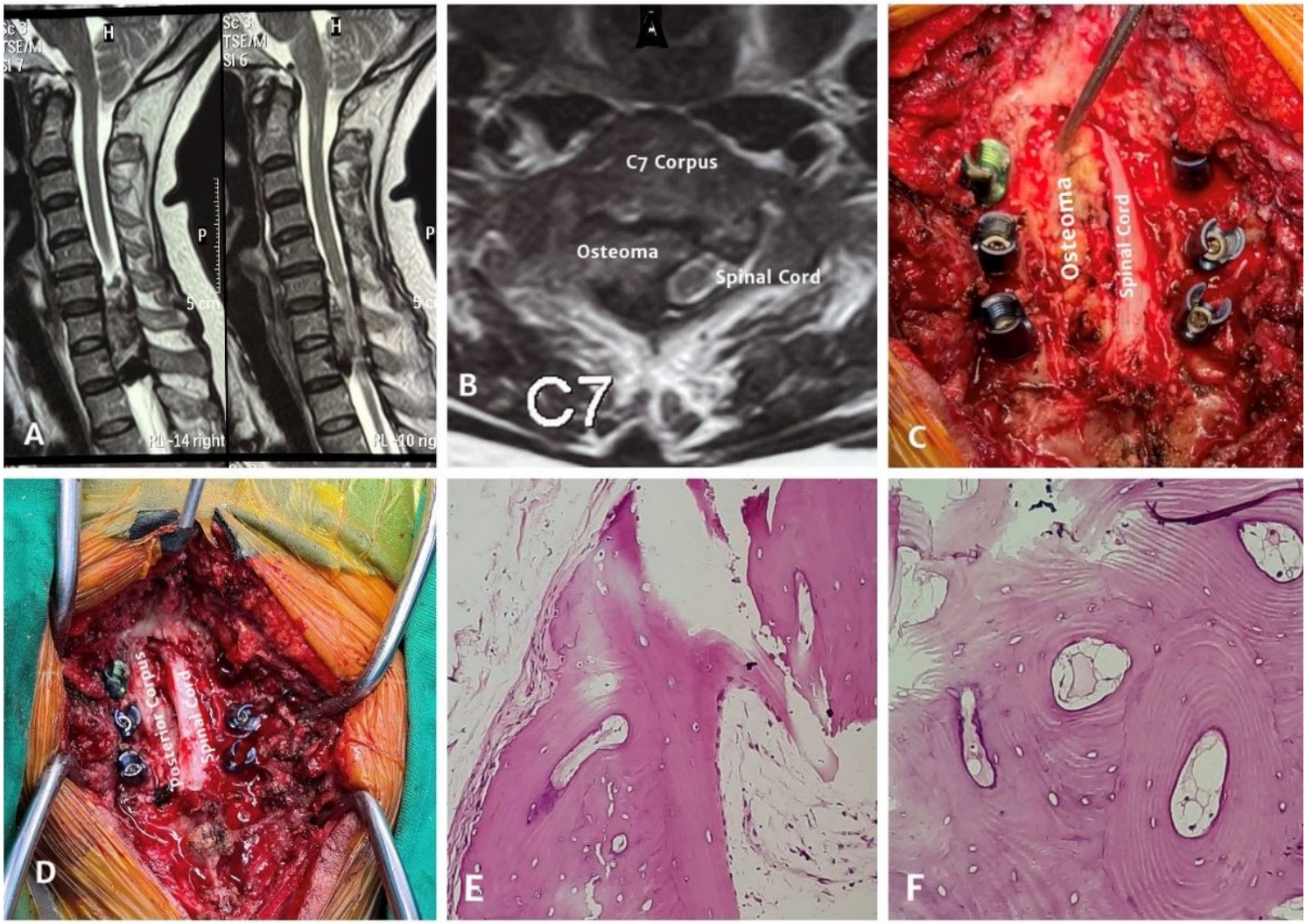

Figure 1

A). an isointense mass was found on C6/C7/T1 with contrast CT scan. B). on axial CT scan an osteoma was found on C7. C, D). intraoperative picture of the mass. E, F). histopathology was done and osteoma was diagnosed

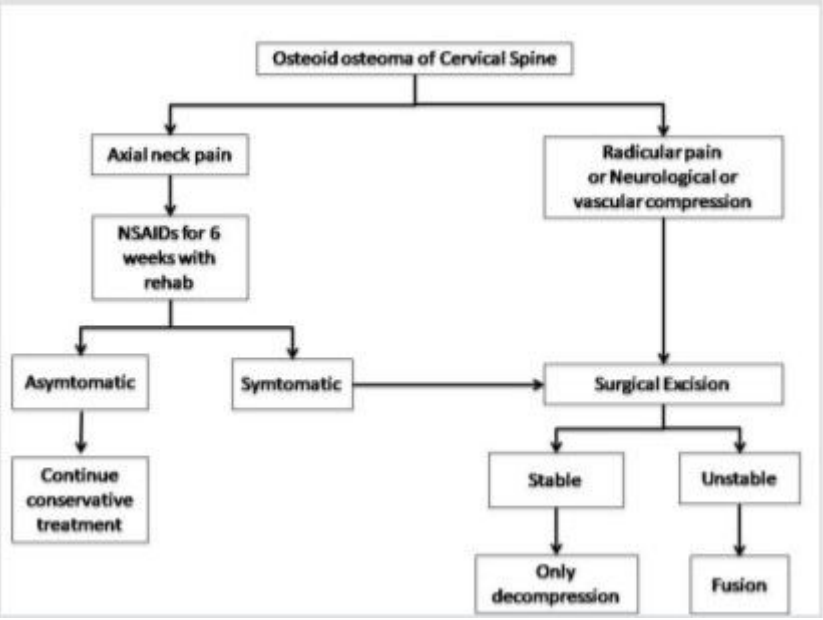

Figure 2

Algorithm of patients with osteoid osteoma in cervical spine [13]