Focal choroidal excavation complicated with choroidal neovascularization in young and middle aged patients

Wenyi Tang
Fudan University
Ting Zhang
Fudan University
Qinmeng Shu
Fudan University
Chunhui Jiang
Fudan University
Qing Chang
Fudan University
Gezhi Xu
Fudan University
Hong Zhuang
Eye & ENT Hospital of Fudan University https://orcid.org/0000-0002-3585-1142

Research Article

Keywords:

Posted Date: October 26th, 2018

DOI: https://doi.org/10.21203/rs.1.3/v1

Version of Record: A version of this preprint was published at International Journal of Ophthalmology on June 18th, 2019. See the published version at https://doi.org/10.18240/ijo.2019.06.16.

Abstract

Background To investigate the clinical and optical coherence tomography (OCT) features of focal choroidal excavation (FCE) complicated with choroidal neovascularization (CNV) in young and middle aged patients. Methods We performed a retrospective review of 26 patients with FCE accompanied by CNV. All patients underwent a complete ophthalmic examination. We analyzed the clinical characteristics of patients, focusing on the spectral-domain OCT features. All patients received intravitreal injection of anti-vascular endothelial growth factor (anti-VEGF) agents. And we assessed the changes of central retinal thickness and best-corrected visual acuity (BCVA) after anti-VEGF therapy. Results The mean age of 26 patients was 35.5 ± 7.3 years (range, 21 - 48 years). Of the 26 FCE lesions, 11 were located subfoveally, 6 were parafoveal, and 9 were extrafoveal. The mean FCE depth was 129.8 ± 50.3 μm, and the mean width was 901.3 ± 306.0 μm. The FCE depth was correlated positively with the width, but not correlated with age or refractive error. CNV was located within the excavation (19 eyes) or adjacent to the excavation (7 eyes). After anti-VEGF therapy, the central retinal thickness was significantly reduced and the BCVA was significantly improved. In the absorption process of subretinal fluid, we found that the fluid in the excavations needed to be absorbed at the last. A small amount of residual fluid could still be seen in a few deep excavations even after a long-term follow-up. Conclusions FCE may be an important reason to cause CNV. Especially in young patients with idiopathic CNV, we should pay attention to the use of OCT to check the presence of FCE. Anti-VEGF therapy is generally effective for CNV associated with FCE.

Figures

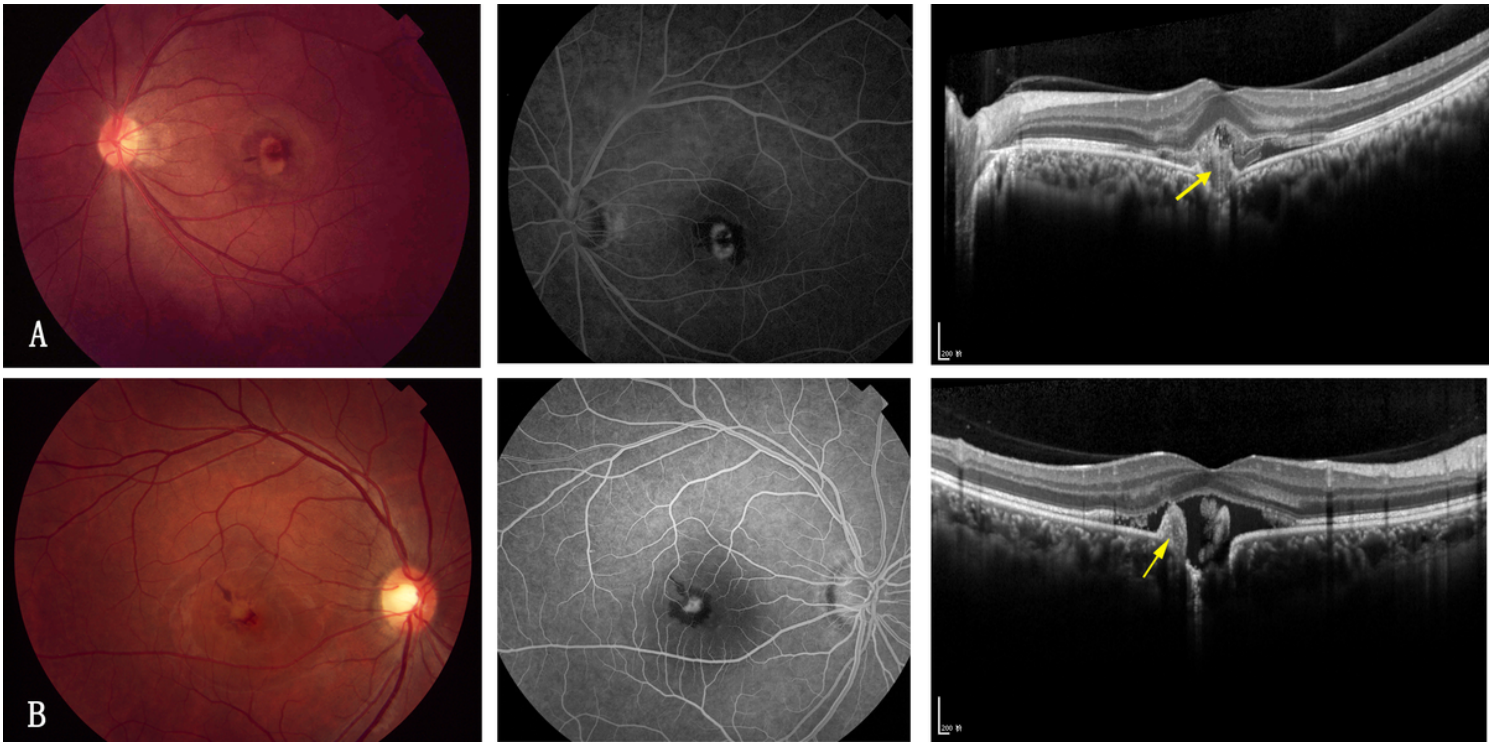

Figure 1

Fundus photos (left column), FFA (middle column) and OCT images (right column) of two patients at the time of presentation. The fundus photos of these two patients both show submacular hemorrhage and exudates caused by CNV; FFA images of these two patients show fluorescence leakage; The OCT images reveal the positional relationship between CNV and FCE: A. the CNV lesion is located mainly within the excavation; B. the CNV lesion is adjacent to the excavation. The hyperreflective CNV lesions on the OCT images are indicated by arrows.

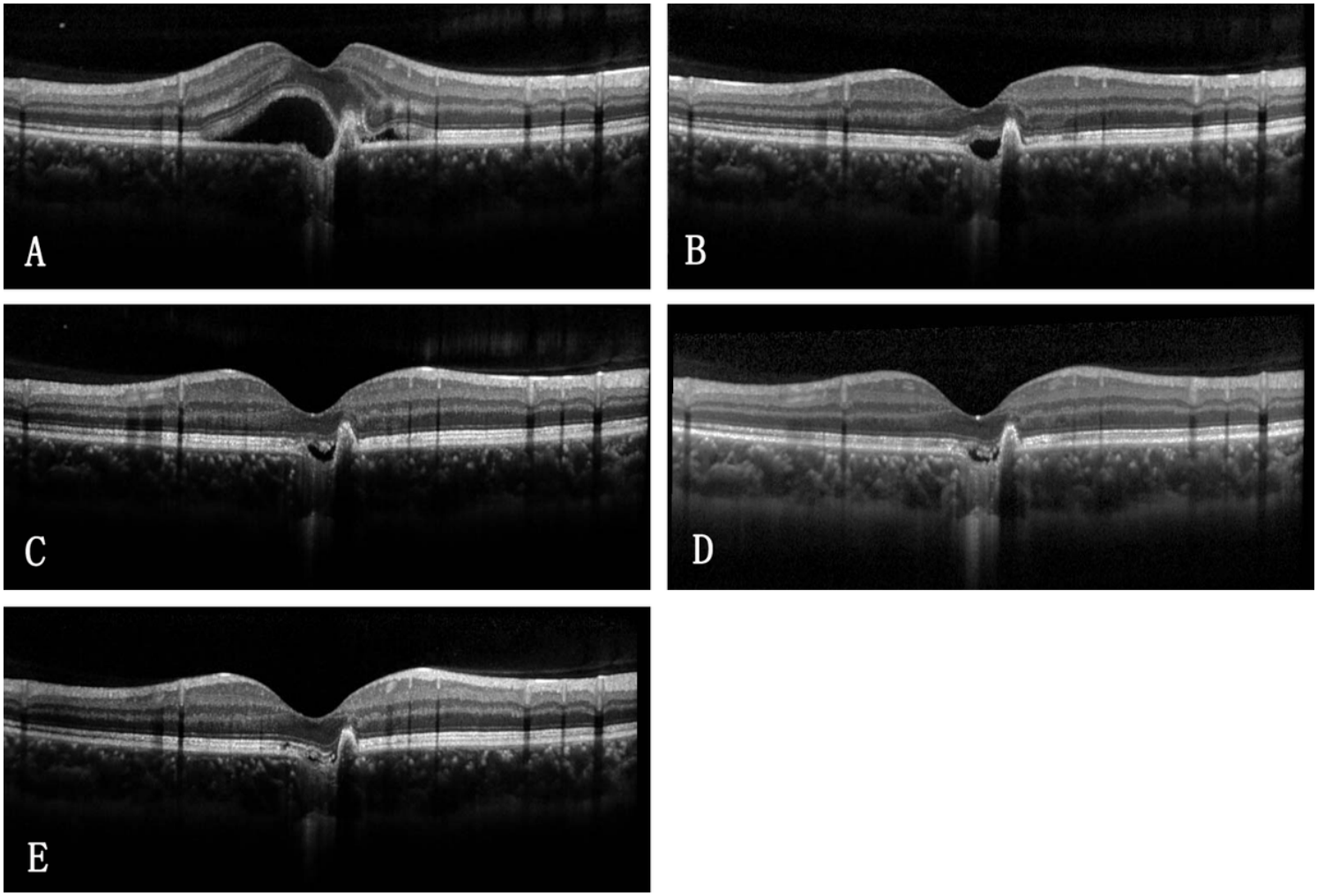

Figure 2

OCT scans from a 28-year-old male patient showing the gradual absorption of subretinal fluid after intravitreal anti-VEGF therapy. This patient received 3 intravitreal injections. A. At the initial visit, the OCT image revealed a CNV lesion adjacent to the excavation, with obvious subretinal fluid; B. 1 month after the 1st intravitreal injection, the subretinal fluid was reduced. But the choroidal excavation was full of fluid; C. 1 month after the 2nd intravitreal injection; D. 1 month after the 3rd intravitreal injection, the residual fluid in the excavation was still seen; E. 3 months after the 3rd intravitreal injection, the fluid in the excavation was completely absorbed at last.

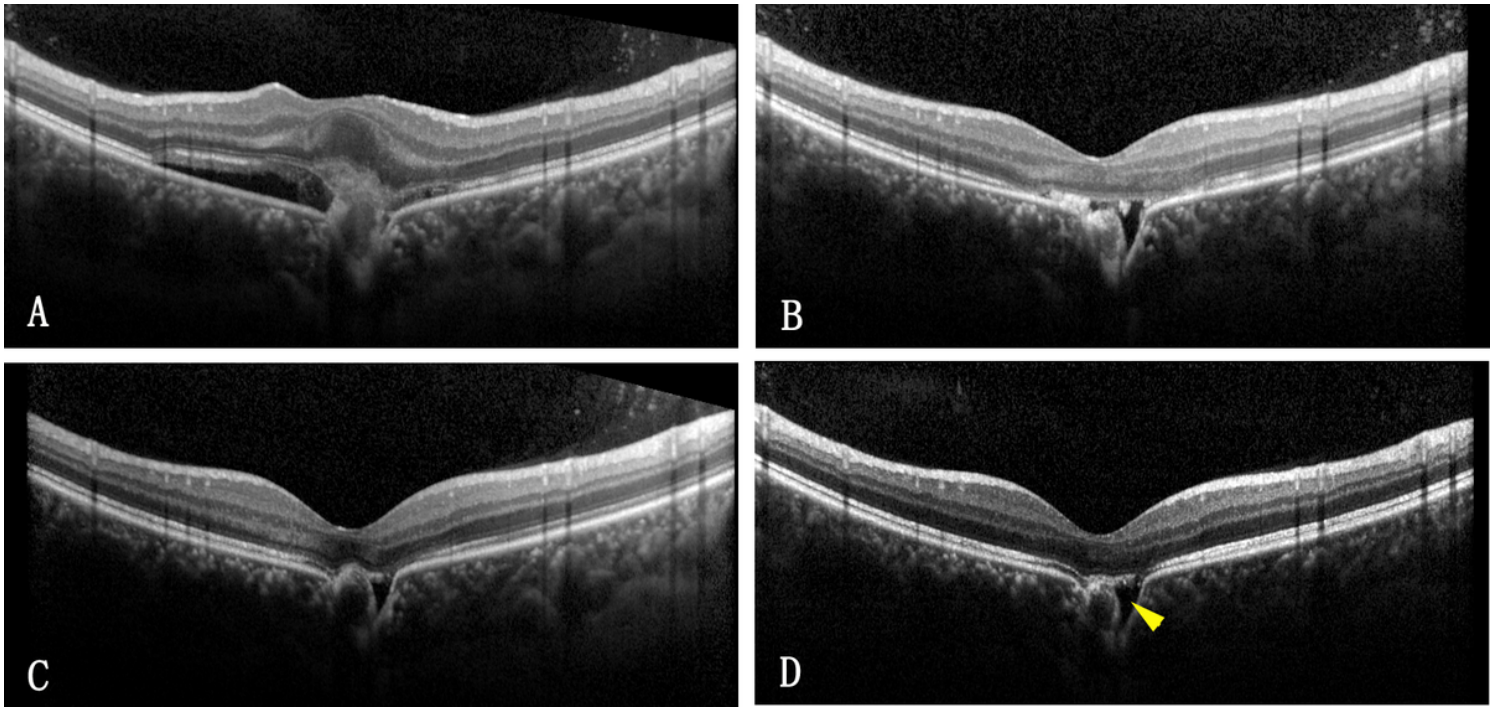

Figure 3

OCT scans from a 29-year-old female patient who received 2 intravitreal injections of anti-VEGF agents. A. At the initial visit, the OCT image revealed a CNV lesion in a deep choroidal excavation, with obvious subretinal fluid; B. 1 month after the 1st intravitreal injection, the CNV atrophied and the subretinal fluid was reduced; C. 3 months after the 2nd intravitreal injection, the subretinal fluid continued to be absorbed, but the residual fluid in the excavation was still seen; D. 12 months after the 2nd intravitreal injection, a small amount of residual fluid (arrowhead) could still be seen in the deep excavation.