Safety of Endovascular Treatment for Concomitant Unruptured Intracranial Aneurysms and Cerebral Vascular Stenosis

Hengwei Jin
Jing Wang
Xiangyu Meng
Youxiang Li
Zhongrong Miao
Hongwei He (hehongwei0123@163.com)

Research

Keywords: endovascular treatment, unruptured intracranial aneurysm, cerebral vascular stenosis

Posted Date: July 8th, 2020

DOI: https://doi.org/10.21203/rs.3.rs-40545/v1

Abstract

Background To evaluate the safety of endovascular therapy for concomitant unruptured intracranial aneurysms (UIAs) and cerebral vascular stenosis. Methods Patients between January to August 2019 were retrospectively reviewed at our institution. Concomitant UIA and cerebral vascular stenosis patients underwent endovascular treatment were included. The demographics and clinical information were collected. Patients were divided into 4 groups according to lesions that was treated (aneurysm, stenosis, both lesions in a single session or in separated sessions). Patients were divided into another 2 groups based on locations of aneurysm and stenosis (ipsilateral and non-ipsilateral). The demographics and clinical data were compared among groups. Results A total of 105 (4.9%) cases have concomitant UIA and cerebral vascular stenosis. Eighty-one patients underwent endovascular treatment for the stenosis(n=18), aneurysm(n=41) or both lesions (one session=10; separated sessions n=12). Seven (8.6%) patients experienced procedural related complications, including 1 (1.2%) hemorrhagic and 6 (7.4%) ischemic types. In terms of procedures, 4 (6.3%) complications is related with UIA embolization, 2(5.0%) related with intracranial stenosis angioplasty. Complication rate of patients underwent intracranial angioplasty and aneurysm embolization simultaneously is much higher (20%) than that of the other groups (5.6%-8.3%). Patients with ipsilateral lesions also had higher complication rate (11.1%) than non-ipsilateral patients (6.7%). Follow-up (74 patients, mean=6.5months) result showed good clinical outcome in 70 (94.6%) patients. Conclusions Simultaneous treatment for concomitant UIA and extracranial stenosis may not pose additional risks. Ipsilateral lesions and single session procedure for intracranial stenosis and UIA are potential risk factors for periprocedural complications.

Background

Concomitant existence of unruptured intracranial aneurysms (UIAs) and cerebral vascular stenosis are relatively rare lesions supposed to have high treatment risks[1]. Embolization of the UIA may decrease blood perfusion of the brain due to low blood pressure under general anesthesia, which may cause ischemic events. Conversely, angioplasty of the stenosis in patients with UIAs may cause UIA rupture due to hemodynamic changes such as increased blood flow, especially when UIA and stenosis are located ipsilaterally. No consensus currently exists to guide endovascular treatment for this kind of patients. Many patients with concomitant carotid stenosis and ipsilateral UIA underwent endovascular treatment have been reported. The overall complication rate is not high and clinical outcome turn out to be good[2–7]. However, rare authors have reported endovascular treatment results of concomitant UIAs and cerebral vascular stenosis despite location and degree of stenosis, as well as location and morphology characteristics of UIAs. The risk of ischemic stroke secondary to stenosis and the risk of subarachnoid hemorrhage (SAH) secondary to UIA rupture must be evaluated and balanced before treatment[8–10]. What is the risk factors for procedural related complications and whether there are any difference between intracranial and extracranial lesions is not known. In the current study, we evaluate the safety of endovascular treatment for concomitant UIAs and cerebral vascular stenosis to solve these questions.

Materials And Methods

Patients

This study was approved by the ethics committee of our hospital, and all patients provided written informed consent. We retrospectively reviewed patients from January to August 2019 at our institution. All patients were diagnosed with imaging studies including computed tomography angiography (CTA), magnetic resonance angiography (MRA), and/or DSA. Patients with concomitant UIA and cerebral vascular stenosis were included. Patients demographics, clinical information, procedure details, complications and clinical follow-up results were collected. Patients were excluded from the study if there was no complete information. Patients who were lost to follow-up or without further treatment after diagnosis were eliminated in further analyses. Patients were divided into 4 groups according to lesions that was treated (UIA, stenosis, both lesions in a single session or both lesions in separated sessions). Patients were divided into another 2 groups based on the relationship between the UIA and stenosis (ipsilateral and non-ipsilateral). The demographics, complications and clinical outcomes were compared among groups.

Definitions of variables

Patients' demographics and clinical data were collected. In the current study, cerebral vascular include intracranial vascular, as well as extracranial segment of common carotid artery (CCA), internal carotid artery (ICA) and vertebral artery (VA). Initial clinical presentations were categorized into specific ischemic symptoms and non-specific symptoms. Specific ischemic symptoms are symptoms directly resulted by relative stenosis, include stenosis related numbness of anybody parts, weakness of limbs, vertigo and slurred speech, etc. Some patients found UIA incidentally when performing routine medical examination (asymptomatic UIA). Non-specific symptoms include non-specific headache, dizziness and asymptomatic UIA. The stenosis was stratified into 4 distinct categories (NASCET criteria) based on degree: mild (< 50%), moderate (50%-70%), severe (70%-99%) and occluded (100%).

The relationship between UIA and stenosis is categorized into two types according to the location: ipsilateral and non-ipsilateral. The former refers to both UIA and stenosis located at left CCA system (left CCA, Left ICA, Left MCA and Left ACA), right CCA system (right CCA, right ICA, right MCA and right ACA) or posterior circulation (Unless UIA and stenosis located at bilateral VAs respectively). For multiple UIAs and/or stenosis, any two lesions located at the same system were categorized into ipsilateral group.

Endovascular embolization status of the UIA was classified into complete occlusion, near complete occlusion and partial occlusion according to Raymond Classification for intracranial embolization. Pipeline is excepted because flow diverter is not applicable for Raymond classification.

Periprocedural complications are categorized into ischemic and hemorrhagic types. Ischemic complication is defined as any additional neurologic deficits compared with pre-operation and infarctions

confirmed by CT/MRI within 30 days after procedure[11]. Hemorrhagic complication is defined as intracranial hemorrhage (ICH/SAH) happened within 7 days after procedure confirmed by CT[12]. All patients were evaluated with the modified Rankin Scale (mRS) before procedure and at last follow-up. mRS 0–2 (independent) is regarded as favorable clinical outcome and mRS ≥ 3 (dependent) is regarded as unfavorable clinical outcome.

UIA embolization and Stenosis angioplasty

There is no consensus for the treatment of concomitant aneurysm and stenosis. Treatment indication for stenosis and UIA is strictly according to the Guidelines from the American Heart Association/American Stroke Association(AHA/ASA) respectively[13, 14]. Dual antiplatelet therapy that comprised aspirin (100 mg/day) and clopidogrel (75 mg/day) was initiated at least 5 days before stent implantation. For UIA embolization, all procedures were performed under general anesthesia. A 6- to 8-F sheath was inserted through the femoral artery and a 6- to 8-F guiding catheter was navigated into the internal carotid or the vertebral artery. For ostial ICA, an 8-F guiding catheter was used for all patients. The guiding catheter was flushed via a pressure bag with saline containing 3000U of heparin/500 ml. The microcatheter tip was guided to the desired position using micro-guidewire. The UIA was embolized with coils alone, stent-assisted coils or pipeline with or without coils. For angioplasty, general anesthesia and local anesthesia are adopted for intracranial and extracranial lesions respectively. During the intervention, 3000–4000 IU of heparin was administered, and additional 1000 IU per hour. Angioplasty (balloon angioplasty along or stenting) was done according to the standardized routine form AHA/ASA and our Unit[14]. Before and immediately after the procedure, the neurological function of every patient was evaluated.

Follow-up

All patients received in-person or telephone follow-up. The final mRS score was based on their functional status at last follow-up.

Statistical analyses

Patients' characteristics were described with frequencies for categorical variables and mean standard deviation for continuous variables. Categorical variables were compared using Fisher exact test or the Pearson χ^2 test. Continuous variables were compared between groups using student's t test or one-way ANOVA. All P values were reported as 2-sided. $P < 0.05$ was considered significant. All statistical analyses were conducted by using SPSS 22.0 (Chicago, IL, USA).

Results

Patients demographics and clinical information

A total 2140 patients were reviewed, and 105(4.9%)patients have concomitant UIAs and cerebral vascular stenosis. Eighty-one patients underwent endovascular treatment and were involved in this study. Age range from 40–82 years old (mean ± standard deviation: 60.2 ± 7.6 years old). Thirty-six (44.4%) patients' initial presentation are specific ischemic symptoms. Sixty-two patients have 1 UIAs, 14 patients have 2 and 5 patients have more than 3, making a total of 106 UIAs. The maximum diameter of UIA range from 1–20 mm (mean ± SD: 4.47 ± 3.06 mm). Fifty-one patients have 1 stenosis, 20 patients have 2 and 10 patients have more than 3, making a total of 126 stenosis. There are 73(57.9%) intracranial and 53(42.1%) extracranial stenosis respectively. As for degree of the stenosis, there are 43(34.1%) severe, 55(43.7%) moderate, 15(11.9%) mild and 13(10.3%) occluded lesions. According to our classification, 36 patients have lesions located ipsilaterally, and other 45 patients have lesions located non-ipsilaterally. Male patients are inclined to have ipsilateral lesions ($p = 0.031$). There is no statistical significance in terms of other baselines among groups. Patients demographics and clinical information are demonstrated in Table 1.

Table 1
Demographics and morphologic characteristics of patients

Parameters	Value
Total patients, n (%)	81(100.0%)
Age (years), Mean(± SD)	60.20(± 7.60)
Gender, Male, n (%)	51(63.0%)
Initial presentation, n (%)	
Specific ischemic symptom	36(44.4%)
Non-specific symptom	45(55.6%)
Total UIAs, n (%)	106(100.0%)
Location of UIAs, n (%)	
Anterior circulation	75(70.8%)
Posterior circulation	31(29.2%)
Size of UIAs(mm), Mean(± SD)	4.47 ± 3.06
Total stenosis, n (%)	126(100.0%)
No. of stenosis per patient, n (%)	
1	51(63.0%)
2	20(24.7%)
≥ 3	10(12.3%)
Location of stenosis 1, n (%)	
Intracranial	73(57.9%)
Extra-cranial	53(42.1%)
Location of stenosis 2, n (%)	
CCA and ICA	45(35.7%)
BA/VA	26(20.6%)
MCA	55(43.7%)
Degree of stenosis, n (%)	
Occlusion (100%)	13(10.3%)

SD: stand deviation; UIA: unruptured intracranial aneurysm; mRS: modified Rankin Scale; CCA: common carotid artery; ICA: internal carotid artery;BA: basilar artery; VA: vertebral artery; MCA: middle cerebral artery

Parameters	Value
Severe (70%)	43(34.1%)
Moderate (50%-70%)	55(43.7%)
Mild (50%)	15(11.9%)
SD: stand deviation; UIA: unruptured intracranial aneurysm; mRS: modified Rankin Scale; CCA: common carotid artery; ICA: internal carotid artery;BA: basilar artery; VA: vertebral artery; MCA: middle cerebral artery	

Treatment

Among the 81 patients received treatment, 41 were received UIA embolization, 18 received angioplasty, 10 received both UIA embolization and angioplasty in the same session (Fig. 1), 12 received both UIA embolization and angioplasty in separated sessions (Fig. 2). A total of 63 UIAs were treated, including coil embolization of 10 (15.9%), stent assistant coil embolization of 38 (60.3%), and pipeline of 15(23.8%). Raymond grade 3 in 28 patients (44.4%), grade 2 in 15(23.8%) and grade 1 in 5(7.9%). Fifteen patients were treated using Pipeline, which Raymond grade scale is not applicable for the evaluation of occlude state. Forty stenosis were treated, including 22(55.0%) intracranial and 18(45.0%) extra-cranial. All treated lesions were achieved good result with good forward blood flow and a very rate of remaining stenosis.

Complications and clinical follow-up

A total of 7 (8.6%) procedural related complications happened, including 1 (1.2%) hemorrhagic and 6 (7.4%) ischemic types. One patient died of SAH after stent assisted embolization of an RVA UIA, accompanied by an BA stenosis (ipsilateral). Among 6 ischemic complications, 1 patient died of LVA occlusion (In-stent thrombosis) after Pipeline implantation for an UIA, non-ipsilateral LICA stenosis at C4 segment and RVA occlusion is exist for this patient. Four patients experienced ischemic complications (2 related with UIA embolization and 2 with angioplasty) and have permanent neurological deficits at last follow-up. Another one patient received ostial ICA angioplasty and ipsilateral MCA UIA embolization during one procedure, and experienced transient ischemic symptoms and completely recovered at discharge. For this patient, we are not sure the complication is caused by UIA embolization or angioplasty, because they are ipsilaterally located and managed at the same session.

In total, in terms of procedures, 4 (6.3%) complications are related with UIA embolization, 2(5.0%) related with intracranial stenosis angioplasty and 1 is not sure. In terms of lesions location, 4(11.1%) complications happened in patients with ipsilateral lesions and 3(6.7%) in non-ipsilateral lesions. The summarized complication occurrence and follow-up result based on different groups are revealed in Table 2 and Table 3. The complication rate of patients under simultaneous treatment of UIA and

intracranial stenosis is higher (20% & 5.6%-8.3%). The complication rate of ipsilateral group is also 11.1%, while that of non-ipsilateral group is only 6.7%. Among all the 81 patients, 7(8.6%) were failed to follow-up, leaving 74 to analyze the clinical outcome. Follow-up period ranges from 3 to 11 months (mean ± SD: 6.5 months). Clinical follow-up demonstrated no ischemic and hemorrhagic stroke. Among the 7 patients experienced complications, 3 have favorable clinical outcome and 4 (5.4% of total) have unfavorable clinical outcome(mRS ≥ 3).

Table 2
Groups based on endovascular treatment strategy

Parameters	UIA Embo.	Angioplasty	Both 2	Both 1	P
No. of cases, n (%)	41(50.6%)	18(22.2%)	12(14.8%)	10(12.3%)	-
Age (years), Mean(± SD)	59.7 ± 7.7	60.2 ± 7.7	61.3 ± 8.8	60.9 ± 6.4	0.913
Gender, Male, n (%)	26(64.3%)	11(61.1%)	10(83.3)	4(40.0%)	0.219
Hypertension, n (%)	31(75.6%)	15(83.3%)	11(91.7%)	7(70.0%)	0.544
Diabetes, n (%)	9(22.0%)	5(27.8%)	5(50.0%)	5(50.0%)	0.146
Complications, n (%)	3(7.3%)	1(5.6%)	1(8.3%)	2(20.0%)	0.584
mRS ≥ 3 at last follow-up	2(4.8%)	0(0%)	1(8.3%)	1(10.0%)	0.469

UIA: unruptured intracranial aneurysm; UIA Embo.: patients underwent UIA embolization;Angioplasty: Patients underwent angioplasty; Both 2: Patients underwent UIA embolization and angioplasty at separated sessions; Both 1: Patients underwent UIA embolization and angioplasty at the same session; SD: stand deviation

Table 3
Groups based on the relationship between UIA and stenosis

Parameters	Ipsilateral	Non-ipsilateral	P
No. of cases, n (%)	36(44.4%)	45(55.6%)	-
Age (years), Mean(± SD)	59.3 ± 7.9	60.9 ± 7.4	0.349
Gender, Male, n (%)	18(50.0%)	33(73.3%)	0.031
Maximum diameter of UIA (mm), Mean(± SD)	4.6 ± 3.21	4.4 ± 2.94	0.793
Stent assisted coiling, n (%)	25(69.4%)	28(62.2%)	0.449
Intracranial stenosis, n (%)	10(27.8%)	12(26.7%)	0.473
Complications, n (%)	4(11.1%)	3(6.7%)	0.479
mRS ≥ 3 at last follow-up	2(5.5%)	2(4.4%)	0.483

UIA: unruptured intracranial aneurysm; SD: stand deviation

Discussion

In this study, we reviewed consecutive patients in a single center for patients with concomitant UIA and cerebral vascular stenosis. A total 2140 patients were reviewed, and 105 patients have concomitant UIA and cerebral vascular stenosis. Eighty-one patients underwent endovascular therapy for the UIA and/or stenosis. The incidence of concomitant UIA and cerebral vascular stenosis is around 4.9%. The reported incidence of concomitant carotid artery stenosis and UIA ranges between 3% and 5%[8, 15]. In this cohort, patients were included if they have any concomitant UIAs and cerebral vascular stenosis, instead of patients only with concomitant carotid artery stenosis and UIA. No consensus has been achieved to guide endovascular treatment of concomitant UIAs and cerebral artery stenosis. Angioplasty may increase the risk of UIA rupture from altered hemodynamics. Embolization of an UIA through untreated stenosis pose additional risks. The mechanical interaction between the access catheters and stenotic plaque may increase the risk of thromboembolic complications[15, 16].

Several reports have investigated whether simultaneous carotid artery stenting (CAS) and coil embolization, or multi-staged therapy is better. Simultaneous therapy will decrease the risk of UIA rupture but may increase the risk of thromboembolic complications[5, 17, 18]. There is a theoretical risk of UIA rupture during and after angioplasty secondary to cerebral hyper perfusion syndrome[8, 19]. Alternatively, if management is first focused on UIA, the patient may subsequently be at risk for perioperative cerebral ischemia as a result of a reduction in perfusion pressure during anesthesia[8, 9]. As the safety of endovascular modalities for UIA treatment and carotid stenosis continues to improve, the notion of single-staged treatment has increasing appeal. Cases reports have demonstrated the feasibility of simultaneous single-staged treatment of concomitant carotid stenosis and ipsilateral UIAs[7, 17, 20, 21]. Some authors hold different views. Carotid artery angioplasty in the setting of a concomitant UIA can be performed safely without an increased 30-day or late-term risk of rupture. If indicated, treatment of the UIA can take place after the patient recovers from the carotid procedure[22]. The complication rates of endovascular angioplasty for CAS is around 2.5%[23]. In this study, no complication is related with extracranial stenosis (extracranial segment of CCA□ICA and VA) angioplasty, which indicate the safety of same session treatment for concomitant UIA and extracranial stenosis.

The reported overall complications rate of endovascular treatment for intracranial stenosis is around 10%, and the unfavorable clinical outcome rate is around 5%[24–26]. The reported complications rate of endovascular treatment for UIAs is 4.9% [27] and unfavorable outcome is around 4.8%[28]. In this cohort, UIA embolization and intracranial stenosis angioplasty related complication is 4 (6.3%) and 2 (5.0%) respectively, and total unfavorable clinical outcome is 4 (5.4%). The judgement of responsible lesion is based on procedures, but we should treat the UIA and stenosis as one entity because they are concomitant. One would be risk factor when we are managing the other and we should treat them as a whole instead of investigating responsible lesions. The complication incidence in this cohort is acceptable compared with reported literatures. Short term clinical follow-up revealed no ischemic and hemorrhagic stroke, indicating that endovascular treatment for concomitant UIA and intracranial stenosis is safe and effective. Due to small sample size and low complication rate, our grouped analyses based

on treatment strategy and lesions distribution revealed no statistically significant risk factors for procedural related complications, but the complication rate of patients underwent intracranial angioplasty and UIA embolization in a single session is much higher (20%) than that of the other groups (5.6%-8.3%). Patients with ipsilateral lesions also had higher complication rate (11.1%) than non-ipsilateral patients (6.7%). Even though there is no statistical significance, we think these two factors are inclined to be high risk factors associated with periprocedural complications. Our experience has led us to treat UIA and intracranial stenosis in separated sessions.

Limitations Of The Study

Our study has several limitations. Due to the retrospective and single center property of the current study, the 4.9% incidence of concomitant UIA and cerebral vascular stenosis patients may have some bias. Population based study may be more accurate. Secondly, due to small sample size and low complication incidence, we did not find any statistically significant risk factors for procedural related complications. The inclined risk factors, including single session procedure for both lesions and intracranial lesions, are to be verified multicentric trials or registries.

Conclusions

Simultaneous treatment for concomitant UIA and extracranial stenosis may not pose additional risks. Ipsilateral lesions and single session procedure for intracranial stenosis and UIA are potential risk factors for periprocedural complications. The result of this study needs to be confirmed by further studies.

Abbreviations

UIA: Unruptured intracranial aneurysm; SAH: subarachnoid hemorrhage; mRS: modified Rankin Scale; CCA: common carotid artery; ICA: internal carotid artery□BA□basilar artery; VA: vertebral artery; MCA: middle cerebral artery

Declarations

Ethics approval and consent to participate

This study was approved by the ethics committee of Beijing Tiantan Hospital. This study was processed according to the principles expressed in the Declaration of Helsinki.

Consent for publication

Not applicable.

Availability of data and materials

All data generated or analyzed during this study are included in this published article.

Competing interests

The authors declare that they have no competing interests.

Funding

None

Authors' contribution

MZ and HH had substantial contributions to conception and design of the study. MX and LY had main responsibility for experiment, acquisition of data and data analysis. JH and WJ write the article. MZ and HH had final approval of the version to be published. All authors have read and approved the final manuscript.

Acknowledgement

Not applicable

References

1. Siddiqui, A., N. Vora, R.C. Edgell, et al. Rupture of a cerebral aneurysm following carotid endarterectomy. J Neurointerv Surg. 2012;4(5):e27.
2. Yang, W., X. Rong, M. Braileanu, et al. Is Carotid Revascularization Safe for Patients with Concomitant Carotid Stenosis and Intracranial Aneurysms? World Neurosurg. 2016;93:11-18.
3. Suh, B.Y., W.S. Yun and W.H. Kwun. Carotid artery revascularization in patients with concomitant carotid artery stenosis and asymptomatic unruptured intracranial artery aneurysm. Ann Vasc Surg. 2011;25(5):651-655.
4. Liang, Y., J. Wang and B. Li. Coexistence of internal carotid artery stenosis with intracranial aneurysm. Int J Stroke. 2014;9(3):306-307.
5. Gallego Leon, J.I., L. Concepcion Aramendia, F. Ballenilla Marco, et al. Concomitant endovascular treatment of concomitant extracranial carotid stenosis and intracranial aneurysm. Our experience. Interv Neuroradiol. 2009;15(1):53-59.

6. Borkon, M.J., H. Hoang, C. Rockman, et al. Concomitant unruptured intracranial aneurysms and carotid artery stenosis: an institutional review of patients undergoing carotid revascularization. Ann Vasc Surg. 2014;28(1):102-107.
7. Campos, J.K., L.M. Lin, N.B. Beaty, et al. Tandem cervical carotid stenting for stenosis with flow diversion embolisation for the treatment of intracranial aneurysms. Stroke Vasc Neurol. 2019;4(1):43-47.
8. Kappelle, L.J., M. Eliasziw, A.J. Fox, et al. Small, unruptured intracranial aneurysms and management of symptomatic carotid artery stenosis. North American Symptomatic Carotid Endarterectomy Trial Group. Neurology. 2000;55(2):307-309.
9. Ballotta, E., G. Da Giau, R. Manara, et al. Extracranial severe carotid stenosis and incidental intracranial aneurysms. Ann Vasc Surg. 2006;20(1):5-8.
10. Kann, B.R., T. Matsumoto and M.D. Kerstein. Safety of carotid endarterectomy associated with small intracranial aneurysms. South Med J. 1997;90(12):1213-1216.
11. Suh, D.C., S.J. Kim, D.H. Lee, et al. Outcome of endovascular treatment in symptomatic intracranial vascular stenosis. Korean J Radiol. 2005;6(1):1-7.
12. Park, H.K., M. Horowitz, C. Jungreis, et al. Periprocedural morbidity and mortality associated with endovascular treatment of intracranial aneurysms. AJNR Am J Neuroradiol. 2005;26(3):506-514.
13. Thompson, B.G., R.D. Brown, Jr., S. Amin-Hanjani, et al. Guidelines for the Management of Patients With Unruptured Intracranial Aneurysms: A Guideline for Healthcare Professionals From the American Heart Association/American Stroke Association. Stroke, 2015;46(8):2368-2400.
14. Kernan, W.N., B. Ovbiagele, H.R. Black, et al. Guidelines for the prevention of stroke in patients with stroke and transient ischemic attack: a guideline for healthcare professionals from the American Heart Association/American Stroke Association. Stroke. 2014;45(7):2160-2236.
15. Pappada, G., L. Fiori, R. Marina, et al. Incidence of asymptomatic berry aneurysms among patients undergoing carotid endarterectomy. J Neurosurg Sci. 1997;41(3): 257-262.
16. Adams, H.P., Jr. Carotid stenosis and coexisting ipsilateral intracranial aneurysm. A problem in management. Arch Neurol. 1977;34(8):515-516.
17. Badruddin, A., M.S. Teleb, M.G. Abraham, et al. Safety and feasibility of simultaneous ipsilateral proximal carotid artery stenting and cerebral aneurysm coiling. Front Neurol. 2010;1:120.
18. Wajima, D., I. Nakagawa, T. Wada, et al. A Trial for an Evaluation of Perianeurysmal Arterial Pressure Change during Carotid Artery Stenting in Patients with Concomitant Severe Extracranial Carotid Artery Stenosis and Ipsilateral Intracranial Aneurysm. Turk Neurosurg. 2019;29(5):785-788.
19. Ogasawara, K., N. Sakai, T. Kuroiwa, et al. Intracranial hemorrhage associated with cerebral hyperperfusion syndrome following carotid endarterectomy and carotid artery stenting: retrospective review of 4494 patients. J Neurosurg. 2007;107(6):1130-1136.
20. Cvetic, V., M. Dragas, M. Colic, et al. Simultaneous Endovascular Treatment of Tandem Internal Carotid Lesions: Case Report and Review of Literature. Vasc Endovascular Surg. 2016;50(5):359-362.

21. Park, J.C., B.J. Kwon, H.S. Kang, et al. Single-stage extracranial carotid artery stenting and intracranial aneurysm coiling: technical feasibility and clinical outcome. Interv Neuroradiol. 2013;19(2):228-234.
22. Tallarita, T., T.J. Sorenson, L. Rinaldo, et al. Management of carotid artery stenosis in patients with coexistent unruptured intracranial aneurysms. J Neurosurg. 2019.
23. Paraskevas, K.I., E.L. Kalmykov and A.R. Naylor. Stroke/Death Rates Following Carotid Artery Stenting and Carotid Endarterectomy in Contemporary Administrative Dataset Registries: A Systematic Review. Eur J Vasc Endovasc Surg. 2016;51(1):3-12.
24. Kadooka, K., N. Hagenbuch, V. Anagnostakou, et al. Safety and efficacy of balloon angioplasty in symptomatic intracranial stenosis: A systematic review and meta-analysis. J Neuroradiol. 2019.
25. Ye, G., X. Yin, X. Yang, et al. Efficacy and safety of drug-eluting stent for the intracranial atherosclerotic disease: A systematic review and meta-analysis. J Clin Neurosci. 2019;59:112-118.
26. Derdeyn, C.P., M.I. Chimowitz, M.J. Lynn, et al. Aggressive medical treatment with or without stenting in high-risk patients with intracranial artery stenosis (SAMMPRIS): the final results of a randomised trial. Lancet. 2014;383(9914):333-341.
27. Algra, A.M., A. Lindgren, M.D.I. Vergouwen, et al. Procedural Clinical Complications, Case-Fatality Risks, and Risk Factors in Endovascular and Neurosurgical Treatment of Unruptured Intracranial Aneurysms: A Systematic Review and Meta-analysis. JAMA Neurol. 2019;76(3):282-293.
28. Naggara, O.N., P.M. White, F. Guilbert, et al. Endovascular treatment of intracranial unruptured aneurysms: systematic review and meta-analysis of the literature on safety and efficacy. Radiology. 2010;256(3):887-897.

Figures

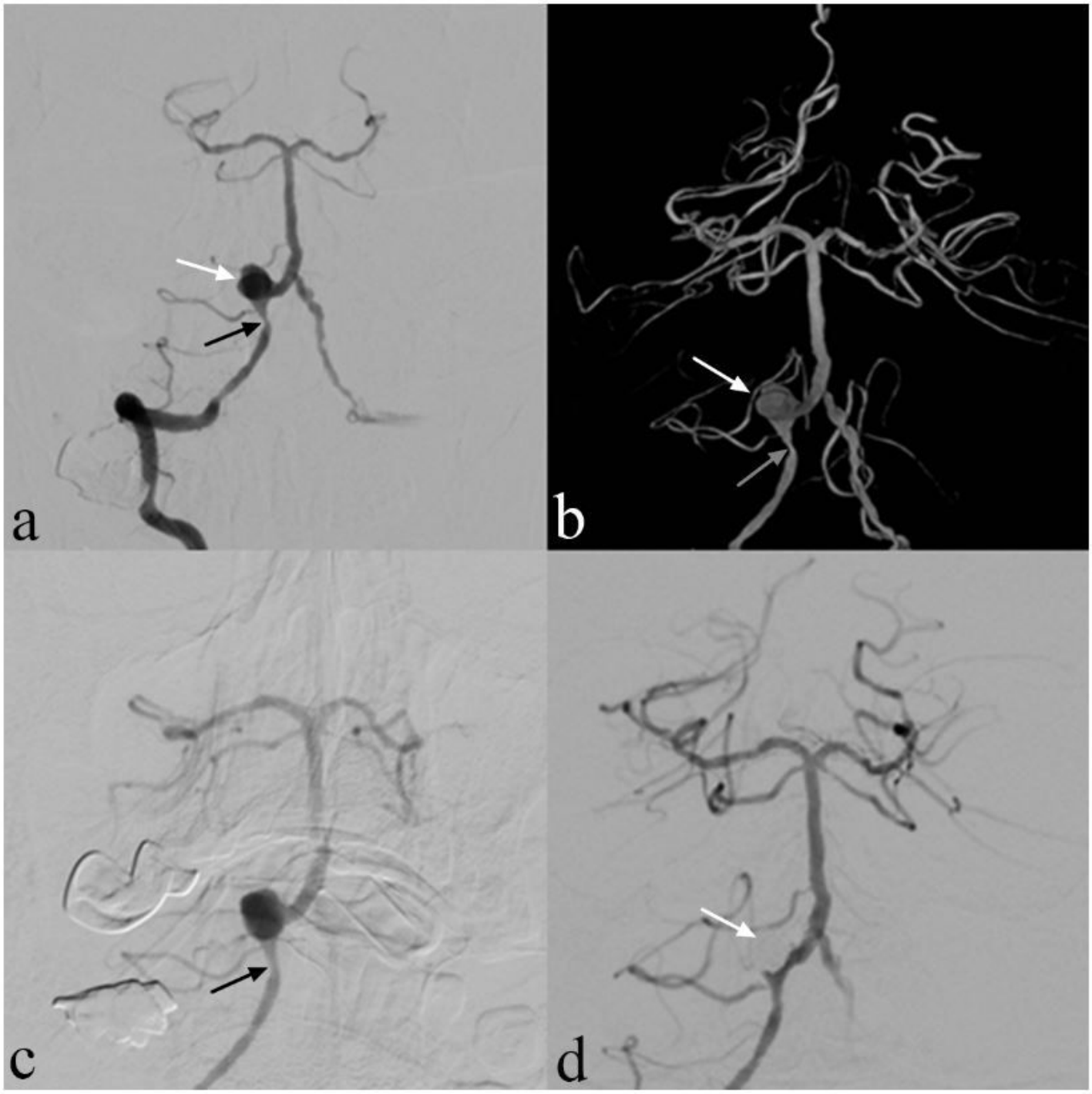

Figure 1

Single session angioplasty of stenosis and UIA embolization. A patient with mild barylalia for 10 days. DSA revealed severe stenosis in the left right vertebral artery as well as an ipsilateral aneurysm located at the very distal of the stenosis (a, b). Balloon dilatation was performed successfully for the stenosis(c). The aneurysm was embolized in in the same session (d).

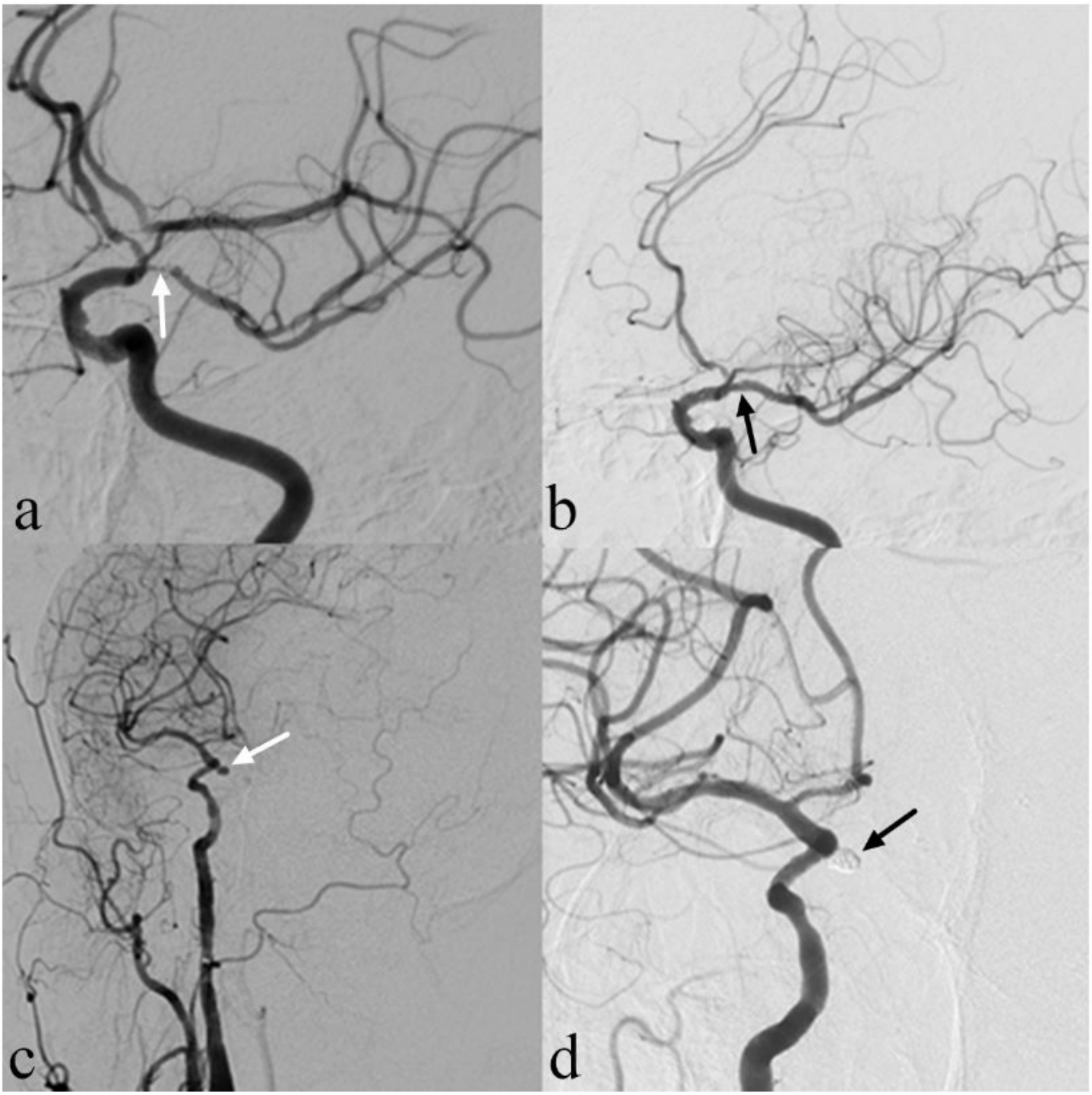

Figure 2

Separated sessions angioplasty of stenosis and UIA embolization. A patient with weakness in the right limbs for 1 month. DSA showed severe stenosis at left MCA (a) and non-ipsilateral post communicating artery aneurysm (c). In the first procedure, we performed balloon dilation and stent implantation for the stenosis (b). One month later, we performed stent assisted coiling of the aneurysm successfully (d).