Endovascular Revascularization of Heavily Calcified Occlusion in Superior Mesenteric Artery using Transcollateral Approach

Kazunori Horie (horihori1015@gmail.com)
Sendai Kousei Hospital https://orcid.org/0000-0002-8614-7729

Akiko Tanaka
Sendai Kousei Hospital

Norio Tada
Sendai Kousei Hospital

Research Article

Keywords: superior mesenteric artery, computed tomography, transcollateral approach, endovascular therapy

Posted Date: April 19th, 2021

DOI: https://doi.org/10.21203/rs.3.rs-406665/v1

Abstract

BACKGROUND: Mesenteric ischemia is often a manifestation of severe vascular disease involving the superior mesenteric artery (SMA). Endovascular revascularization is still challenging in a chronic total occlusion (CTO) of SMA.

CASE PRESENTATION: An-73-year-old male was referred to our hospital because of a 2-year history of abdominal angina after each meal. Computed tomography (CT) images revealed a heavily calcified CTO in the ostium of SMA. Angiography did not show the collateral route suitable for transcollateral approach (TCA); however, the three-dimension CT detected pancreaticoduodenal arcade from the celiac artery to the occluded SMA. According to CT imaging, transcollateral wire crossing from the celiac artery was successful in the SMA-CTO. After pull-through of the guide wire, two balloon-expandable stents were deployed in the ostium of SMA. During 3 months after the stent implantation, the patient had no further episodes of abdominal angina on dual-anti-platelet therapy

CONCLUSIONS: We demonstrated a case of SMA occlusion with heavy calcification treated with stent implantation using TCA guided by CT imaging.

Background

Mesenteric ischemia is often a manifestation of severe vascular disease involving the superior mesenteric artery (SMA) and/or the celiac artery. Endovascular therapy (EVT) of these vessels is now an acceptable treatment to improve the clinical symptom.[1-4] Because a chronic total occlusion (CTO) of the SMA is challenging to achieve recanalization using antegrade approach, several case reports showed the efficacy of transcollateral approach (TCA) in SMA-CTO via the celiac artery and/or inferior mesenteric artery (IMA)[5,6]; however, established TCA routes are not unknown because of the complexity of collateral network in abdominal arteries. Previous reports have described the feasibility of preoperative multidetector computed tomography (CT) was useful to manifest the anatomical findings such as vessel sizes, route and distribution of calcification in EVT for CTO in limb arteries.[7,8] We report a case of heavily calcified SMA-CTO treated with TCA wiring via the celiac artery guided by three-dimensional CT (3D-CT) imaging.

Case Presentation

An-73-year-old male with the history of hypertension, diabetes and lower extremity artery disease was referred to our hospital because of a 2-year history of abdominal angina after each meal. Upper and lower gastrointestinal endoscopies showed no abnormal findings. CT images revealed a heavily calcified CTO in the ostium of SMA (Figure 1A and axial imaging in Supplementary Movie 1) and 3D-CT detected pancreaticoduodenal arcade with filling of the SMA from the celiac artery (Figure 1B and 1C). Angiography of the celiac artery in the front view revealed collateral blood flow supplying to the SMA; however, the pancreaticoduodenal arcade was not visualized clearly (Figure 2A and Supplementary Movie

2). According to the collateral route shown by the 3D-CT, we attempted TCA approach and retrograde wire crossing of the SMA-CTO. A 6.0-Fr Brite Tip Judkins Right4 guiding catheter (Cordis, Miami, FL, US) via the left radial artery was engaged in the ostium of the celiac artery. We proceeded the Hi-Torque Command 0.014 guidewire (Abbott Medical, Santa Clara, California, US) with Corsair microcatheter with 150 cm length (Asahi Intecc, Aichi, Japan) into the gastroduodenal artery. Jupiter SFC guidewire (Boston Scientific, MA, US) could advance into the superior pancreaticoduodenal artery and reach the distal portion of the SMA-CTO. After cannulating the microcatheter, Vassallo 14 guidewire (Cordis, Miami, FL, US) could cross the CTO (Figure 2B). A 6.0-Fr long sheath was inserted into the right common femoral artery and a 12.0-20.0 mm En-Snare (Merit Medical, Tokyo, Japan) was used to capture the Vassallo 14 guidewire, which was withdrawn through the right femoral sheath. Eagle Eye intravascular ultrasound (IVUS; Philips Volcano, Rancho Cordova, CA, US) confirmed the intraplaque wire crossing (Supplementary Movie 3). After dilatation with 6.0 mm Shiden HP balloon (Kaneka Medix, Osaka, Japan) at 20 atm (Figure 2C), two Express Vascular SD of 6.0 × 18mm (Boston Scientific) was implanted in the SMA. IVUS revealed that the stents were well expanded (Supplementary Movie 4), and angiography showed antegrade blood flow in the SMA (Figure 2D). The patient had no major post-operative complications and was discharged from the hospital. During 3 months after the EVT, the patient had no further episodes of abdominal angina on dual-anti-platelet therapy.

Discussion

In patients with mesenteric ischemia because of chronic occlusion in SMA, the primary and secondary patency were reported 76% and 90% at 2 years after stent implantation.[4] The primary patency rate after stent implantation was still challenging; however, EVT for chronic mesenteric ischemia was associated with lower in-hospital mortality and complication rate than open surgery.[4,9] Therefore, EVT for the CTO of SMA and/or celiac arteries is now considered an acceptable and less invasive alternative to surgical revascularization. By contrast, antegrade wire crossing appears to be difficult in SMA-CTO, because angiography often cannot identify the origin of the SMA from aortic root and the ostium cannot be cannulated easily by guiding catheters.

Typically, collaterals to the SMA are frequently seen from the celiac artery and/or the IMA. Although several reports demonstrated the the efficacy of TCA for SMA occlusion,[5,6] TCA has been attempted in patients with well-developed collateral channels. Some patients with SMA occlusions have tinny collaterals between celiac and mesenteric arteries, and angiography often cannot reveal visible candidates for TCA. Wire perforation and arterial dissection in the collateral arteries for SMA can be a fatal complication because of intraabdominal hemorrhage and intestinal necrosis; therefore, reliable routes of TCA should be identified before the EVT. Moreover, the present case had the heavy calcification in the CTO and pull-through of a guidewire was necessary to deliver a high-pressure balloon and deploy balloon expandable stents. Although TCA was essential to achieve the revascularization, there are few reports demonstrating the efficacy of CT imaging to evaluate tinny collateral routes in patients with SMA-CTO. In the present case report, 3D-CT imaging was useful to clarify the connection through the arcade

from the superior pancreaticoduodenal artery to SMA. Therefore, TCA wiring could be performed safely in the most reliable collateral route.

Conclusions

We demonstrated a case of heavily calcified CTO in the SMA, in which 3D-CT allowed to visualize the reliable collateral channel from the celiac artery. TCA was safely performed in the guidance of CT imaging and CTO could be treated with stent implantation.

List Of Abbreviations

SMA – Superior mesenteric artery

EVT –Endovascular therapy

CTO – Chronic total occlusion

TCA – Transcollateral approach

IMA – Inferior mesenteric artery

CT – Computed tomography

IVUS – intravascular ultrasound

Declarations

Ethics approval and consent to participate

The case report was approved by the institutional review board of our hospital, and the approval number is 27-33.

Consent for publication

Written informed consent for publication was obtained from the patient.

Availability of data and materials

The datasets used and/or analyzed during the current study are available from the corresponding author on reasonable request.

Competing interests

The authors declare that they have no competing interests.

Funding

No sources of funding were declared for this case report.

Authors' contributions

KH and AT analyzed and interpreted the patient data regarding the endovascular therapy and the clinical course. KH wrote the article. NT is expected to have drafted the work and substantively revised the work.

Acknowledgements

The authors are very grateful to Shinji Kasahara for their support in reconstructing the CT imaging.

References

1. Chahid T, Alfidja AT, Biard M, Ravel A, Garcier JM, Boyer L (2004) Endovascular treatment of chronic mesenteric ischemia: results in 14 patients. Cardiovasc Intervent Radiol;27(6):637-42.
2. Nyman U, Ivancev K, Lindh M, Uher P (1998) Endovascular treatment of chronic mesenteric ischemia: report of five cases. Cardiovasc Intervent Radiol;21(4):305-13.
3. Landis MS, Rajan DK, Simons ME, Hayeems EB, Kachura JR, Sniderman KW (2005) Percutaneous management of chronic mesenteric ischemia: outcomes after intervention. J Vasc Interv Radiol;16(10):1319-25.
4. Zettervall SL, Lo RC, Soden PA, et al. (2017) Trends in Treatment and Mortality for Mesenteric Ischemia in the United States from 2000 to 2012. Ann Vasc Surg;42:111-119.
5. Milner R, Woo EY, Carpenter JP (2004) Superior mesenteric artery angioplasty and stenting via a retrograde approach in a patient with bowel ischemia–a case report. Vasc Endovascular Surg.;38(1):89-91.
6. Robken J, Shammas NW (2007) Treatment of a totally occluded superior mesenteric artery facilitated by retrograde crossing via collaterals from the celiac artery. J Endovasc Ther;14(5):745-7.
7. Della Schiava N, Naudin I, Bordet M, et al. (2020) Analysis of Preoperative CT Scan Can Help Predict Technical Failure of Endovascular Treatment of TASC C-D Aortoiliac Chronic Total Occlusions. Ann Vasc Surg:S0890-5096(20)30789-5.
8. Hayakawa N, Kodera S, Ohki N, Sakkya S, Kanda J (2021) Efficacy of three-dimensional road mapping by fusion of computed tomography angiography and fluoroscopy in endovascular treatment of aorto-iliac chronic total occlusion. Heart Vessels;36(3):359-365.
9. Oderich GS, Macedo R, Stone DH, et al. (2018) Low Frequency Vascular Disease Research Consortium Investigators. Multicenter study of retrograde open mesenteric artery stenting through laparotomy for treatment of acute and chronic mesenteric ischemia. J Vasc Surg;68(2):470-480.

Figures

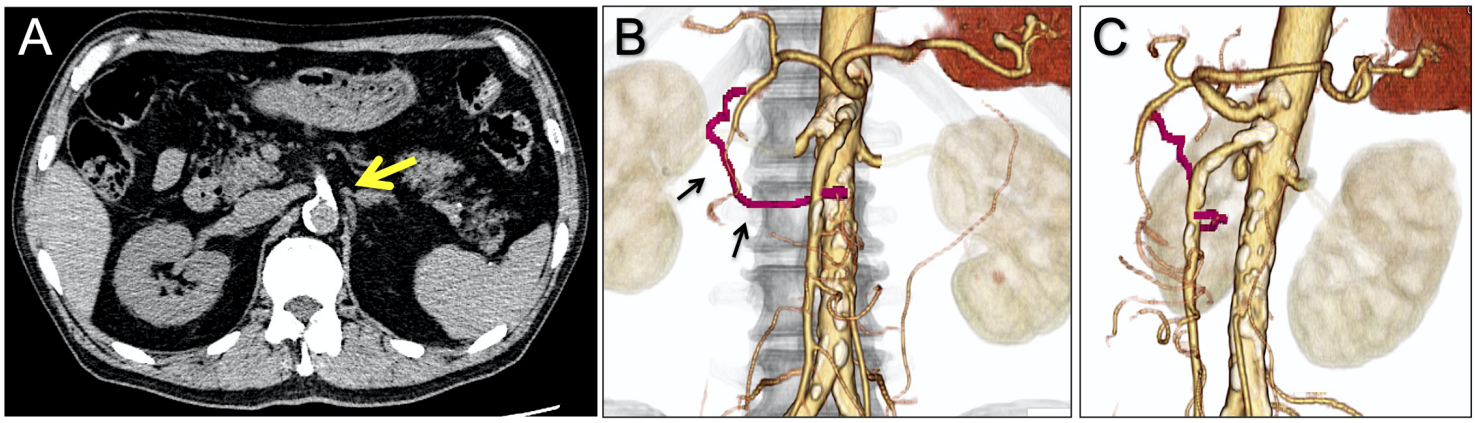

Figure 1

Computed tomography. A, Noncontrast computed tomography (CT) revealed a heavily calcified occlusion in the ostium of the superior mesenteric artery (a yellow arrow). B and C, Contrast-enhanced CT showed a pancreaticoduodenal arcade in the front view (black arrows) and in the angulated 65-degree left anterior oblique position.

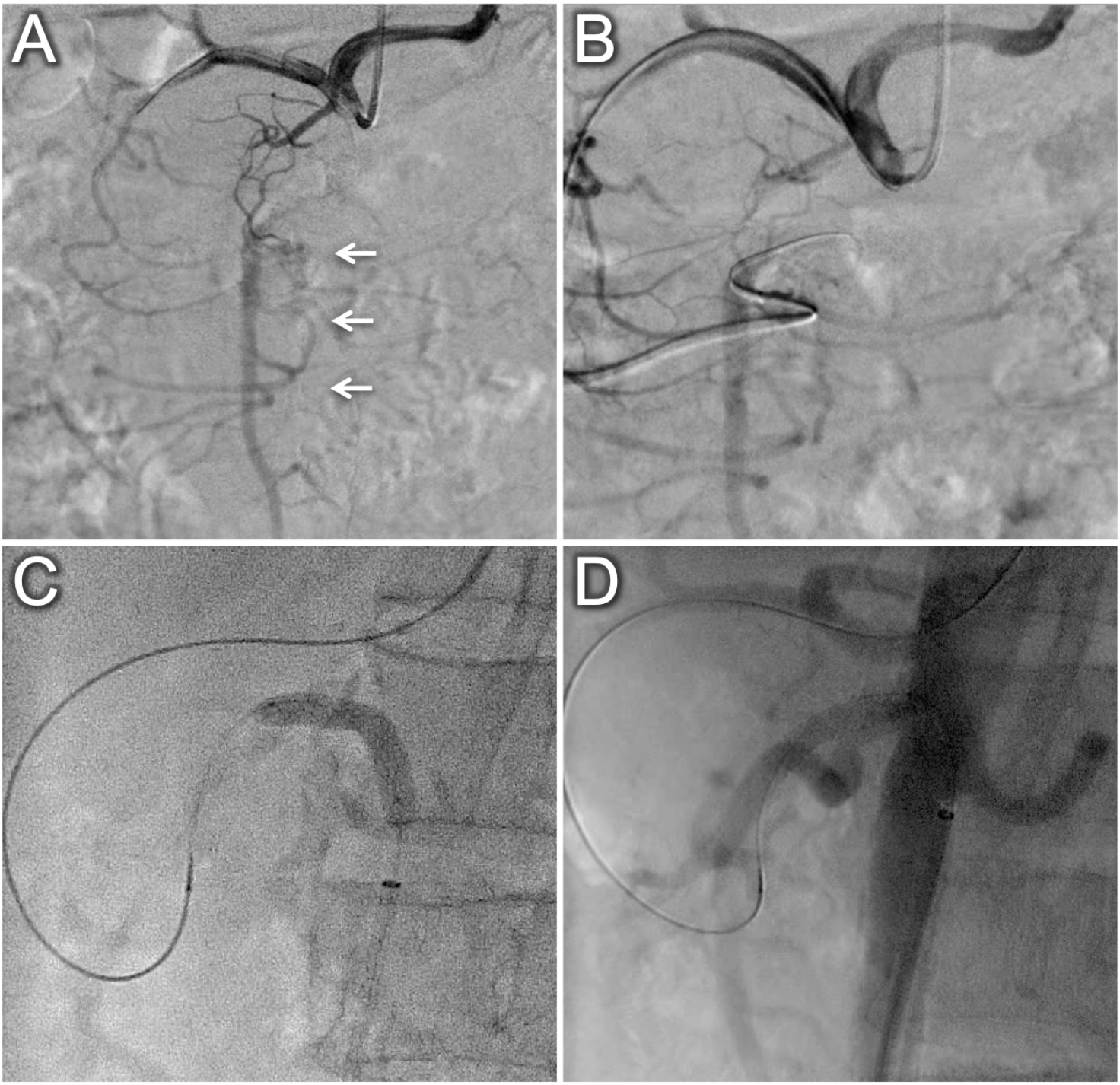

Figure 2

Angiography and endovascular therapy. A, Digital subtraction angiography from the celiac artery showed collateral blood flow supplying to the superior mesenteric artery (SMA) (white arrows); however, did not show the pancreaticoduodenal arcade clearly. B, The Jupiter SFC guidewire with Corsair microcatheter reached the distal portion of the chronic total occlusion (CTO) in the SMA through the pancreaticoduodenal arcade as shown by computed tomography imaging. C, A 6.0 mm balloon was dilatated in the CTO. D, Angiography showed antegrade blood flow in the SMA after two balloon expandable stents.

Supplementary Files

This is a list of supplementary files associated with this preprint. Click to download.

- FinalIVUSSMA.mov
- PreIVUSSMA.mov
- Supplementmovie1.mp4
- SupplementallegendTCAinSMA.docx
- SupplementaryMovie2.XA.mpg