The whirlpool sign predicts cases of testicular torsion with the preserved flow: a case series

Zhihua Xu
Wenzhou Medical University Second Affiliated Hospital
Shuangshuang Ni
Wenzhou Medical University Second Affiliated Hospital
Senmin Wu
Wenzhou Medical University Second Affiliated Hospital
Hui Zhu
Wenzhou Medical University Second Affiliated Hospital
Kai Chen
Wenzhou Medical University Second Affiliated Hospital
Hongxia Luo (luohongxia0127@163.com)
Wenzhou Medical University Second Affiliated Hospital https://orcid.org/0000-0002-5894-0359

Research article

Keywords: Testicular torsion; Ultrasound; Pediatric; Color doppler; Whirlpool sign

Posted Date: July 29th, 2020

DOI: https://doi.org/10.21203/rs.3.rs-42065/v1

Abstract

Background To investigate the diagnostic characteristics of high-frequency ultrasound with color doppler flow signal in pediatric testicular torsion to increase the diagnostic accuracy.

Methods Seven pediatric patients from October 2017 to August 2019 with preserved blood flow signal but surgically diagnosed as testicular torsion were retrospectively included into the study. The imaging manifestations of high-frequency ultrasonography were evaluated.

Results Seven cases of testicular torsion with preserved blood flow aging from 49 days to 15 years old were included in the study. All the cases had preserved blood flow in testis, but the surgical findings showed various twist degrees from 90° to 540°. Preoperative ultrasound showed spermatic cord distortion in all cases, and the testicular long axis tilted in four cases.

Conclusion In some testicular torsion cases, color doppler may show normal or increased blood flow signals in the testis. The “whirlpool sign” in the spermatic cord is an important indicator suggestive of testicular torsion.

Background

Testicular torsion is a common scrotal emergency, occurring in 5–25% of pediatric patients(1–3). The first peak onset appears within one year after birth, followed by a second surge in early adolescence, with an incidence of 65% between 12 and 18 years due to a rapid increase of testicular volume during puberty. Intravaginal testicular torsion is the most common type, and it primarily occurs between 3 and 20 years old(4, 5). To prevent testicular necrosis, an accurate and quick diagnosis is essential to determine the subsequent treatment(6). The salvage rate is less than 10% if the revascularization is operated after 24 hours in patients with testicular torsion (7–9). Therefore, the early identification of risk factors in predicting testicular torsion and potential necrosis is important to improve children’s outcomes.

Testicular torsion is the reduction of blood flow to the testis after spermatic cord torsion, and the blood flow signal and the degree of spermatic cord twist is reported to be the most common risk factors in predicting testicular loss(10). Testicular ultrasonography (US) is an ideal imaging tool to diagnose testicular torsion before the operation. The reduced or absence of testicular blood flow signal has high diagnostic accuracy with the sensitivity of 86–100% and the specificity of 97.9–100% (11). Besides, color doppler US has been proven particularly useful in the differential diagnosis(12, 13).

However, for patients with intermittent and partial testicular torsion, the diagnosis is arguable and complicated as ultrasound blood flow signals are not significantly reduced compared to the other healthy side despite having persistent symptoms(14). Therefore, preserved intratesticular blood flow may lead to a false negative diagnosis(5, 15). A recent study has shown that the ‘whirlpool sign,’ which is defined as an abrupt change in the course of the spermatic cord with a spiral twist at the external inguinal ring or in the scrotal sac(16), was the critical feature in patients with the preserved flow. Therefore, the purpose of this study was to investigate the ultrasound diagnostic indicators of testicular torsion with blood flow signals in ultrasound color doppler, to avoid under diagnosis of testicular torsion and save the testicles as much as possible.

Methods

Patient cohort

Keywords searing with 'torsion’ was performed in scrotal or testicular Imaging throughout the Picture Archiving and Communication System (PACS) from October 2017 to August 2019 to retrieve patients with suspected testicular torsion. The patients in the absence of blood flow in testis were excluded from this study. This study was approved by the local Research Ethics Committee (Ethics Reference No.: L-2020-19), and the requirement of the patient consent form was waived.

Instruments And Methods

All sonograms were obtained with a 5–12 MHz linear transducer (LOGIQ 7 of GE, EPIQ7 of PHILIPS). The children were placed in the supine position, and the testes were scanned horizontally and longitudinally with a high-frequency probe. The position, size, morphology, internal echo, a spermatic cord of the testis and epididymis and the testicular sheath cavity were observed. Color doppler contrasted the blood flow signals in both testes. Torsion of the spermatic cord was diagnosed by ultrasound if the degree of torsion larger or equal to one-quarter twist (90°) was observed(15, 17). The blood perfusion of parenchyma testis at both sides were assessed and compared to the normal side.

Result

Clinical manifestations

Fifty-seven pediatric patients with suspected testicular torsion were identified from PACS, and 50 cases without detectable blood flow were excluded. Seven cases were finally included in the study, and all the seven pediatric patients received the surgery after US exams within three hours and were confirmed to have testicular torsion.

The age of the cohort ranged from 49 days to 15 years old. Six patients had scrotal pain and swelling, and one patient who was only 49 days had scrotal swelling, including four on the left side and three on the right side. None of the patients reported a medical history of previous trauma. The demographics and

clinical characteristics were summarized in Table 1.

Table 1

Sonographic findings												Sur
case	Age	Time of onset	Affected side	Size	Location	Morphology	Echo	Blood flow	Epididymis	Hydrocele	Spermatic cord	Intra obs
1	14 years 3 months	7 hours	right	increase	normal	plump	uniform	normal	swelling	yes	whirl sign	180 rud
2	14 years 7 months	3hours	right	increase	normal	plump	nonuniform	normal	swelling	yes	whirl sign	360 cou rud
3	8 years 3 months	5days	left	increase	tilt	broad bean shape	uniform	increase	swelling	yes	whirl sign	90° cou rud
4	13 years 8 months	4days	left	increase	normal	plump	nonuniform	normal	normal	none	whirl sign	180 cou test epid
5	8 years 5 months	15hours	left	increase	tilt	plump	nonuniform	increase	swelling	none	whirl sign	540 test pur
6	49days	4days	right	increase	tilt	broad bean shape	nonuniform	normal	swelling	yes	whirl sign	90° test pur
7	6 years 4 months	2days	left	increase	tilt	plump	nonuniform	increase	swelling	yes	whirl sign	540 rud

Ultrasound Performance

The diseased testicles were enlarged. Two of seven cases were inboard bean-shaped, four were tilted, five had heterogeneous signals of parenchyma. Fissure-free echogenic areas were seen around the mediastinum of the testis. Color doppler showed that the blood flow signal of the testis parenchyma increased in three cases compared to the opposite side, and no significant difference was found in four cases. In addition, six patients had enlarged epididymis heads and increased blood flow signals. Testicular hydrocele existed in five cases. The spermatic cords were twisted and presented as “whirlpool sign” in all patients, and the boundary with the epididymis was unclear, forming pseudotumor-like nodules beneath them. The overall results were displayed in Table 1.

Surgical Results

All seven cases had unilateral testicular torsion, and all of them were intrathecal testicular torsion, two cases had a one-quarter twist (90°), two cases had a two-quarter twist (180°), one case had 360° in torsion, two cases twisted at 540°. The blood supply was preserved in four testicles, and three cases had reversible ischemia. The matching surgical results were displayed in Table 1.

Discussion

The volume of the testicles increases

When twisted, testicles increased in size due to the congestion of parenchyma and presented a full and spherical shape, which is often misdiagnosed as orchitis. A difference in the size of testicles at both sides, with the affected testis larger in volume than the asymptomatic side, is a crucial feature, suggestive of testicular torsion(16). The testicular volume of the affected side in the present study is larger than that of the contralateral side in all patients (Figure1).

Testicular position

The testes are commonly in an upright position. If the long axis of the testicle is inclined or even horizontally relative to the long axis of the thigh or long axis of the femur, especially if the orientation of the testicular mediastinum changes in the cross section, it may indicate testicular torsion(18). Four testicles were oblique (Figure 2).

Besides, previous studies have also reported that testicular torsion is more likely to occur on the left side (4,19) because the left spermatic cord is longer than the right. This study also found that four testicular torsions occurred on the left, whereas three testicular torsions happened on the right side, which was consistent with previous studies. But the study with a larger sample size is warranted.

Heterogeneous echotexture of the testicles

Testicular torsion can have a various twisting degree and thus result in heterogeneous parenchymal echotexture seen in testicular torsion. The presence of significant heterogeneity indicates a late torsion and testicular nonviability. Whereas, the homogeneous signal of testicular parenchymal may indicate the variability of testicles(20,21). In the present study, there were five cases with the heterogeneous echo of testis parenchyma and fissure anechoic around mediastinum (Figure3), and the result matched with surgical findings. Careful mapping of the testicular echotexture can help with the early diagnosis of potential segmental necrosis and can also aid the follow-up exam when the echotexture returns to normal.

Epididymal enlargement

The epididymis is inevitably involved in the torsion, and it is often enlarged. In our study, the epididymis was enlarged in various degrees, and it thus can be commonly misled to epididymitis. An 8 years 3month-old boy from the current cohort with the third episode of acute left scrotal pain for five days and was initially misdiagnosed as epididymitis. In addition, the increased epididymis and the convoluted spermatic cord are also easily entangled together to form pseudo mass (Figure 4, Video1). The appearance of the pseudo mass is similar to that of an inflamed epididymis. Sonographic review of the spermatic cord can differentiate testicular torsion with pseudo mass formation from epididymitis. The presence of a straight spermatic cord with a hyperemic epididymis but no pseudo mass can be seen with both epididymitis and torsion of an appendage, both of which should be treated medically, not surgically(14).

The spermatic cord–“whirlpool sign”

The diagnosis of torsion is based on a lack of blood flow in the testes or a marked reduction in blood flow in the affected testes(22). However, in the present study, three cases showed an increased blood flow signal, and four cases had preserved blood flow (Figure5), which indicated the low yield of blood perfusion in diagnosing testicular torsion by US. Four cases with even hyperperfusion were given by the reasons as follows:1) enlarged testicular volume may increase the diagnostic sensitivity of color doppler US(23);2) inflammatory response happening surround the ischemic testicular parenchyma may increase the parenchymal perfusion(24); 3) There are different types of testicular torsion including complete testicular torsion, intermittent testicular torsion, and partial or incomplete torsion based on the various twist degrees(14).

In the present study, all of the patients were intrathecal testicular torsion which was confirmed by surgery with various twisting situations from 90° to 540°. Taken together, the residual blood flow in all cases may be caused by intermittent or spermatic cord torsion. In this case, the ‘whirlpool sign' was the key feature(Figure6), which was consistent with early studies(5,14,18,25). The "whirlpool sign" of the spermatic cord is considered to be a more direct and specific sign of testicular torsion and is valuable for the diagnosis of complete, intermittent, and incomplete torsion of the testis, regardless of color doppler US findings(5,18,25). In patients with preserved blood flow, the position of the spermatic cord and testes should be assessed comprehensively. Therefore, in the diagnosis of testicular torsion, ultrasound examination needs to evaluate the full length of the spermatic cord.

Study limitations

This study had some limitations. First, the study has a small sample size. Second, all the patients we had tested color doppler, but resistive index (RI) and venous flow were not assessed. Third, we did not recruit normal volunteers but using the opposite healthy side of the testis as the reference group. The prospective case-control study with a larger sample size should be conducted to confirm our findings in the future.

Conclusion

Testicular ultrasonography has an indelible importance to the preoperative diagnosis of testicular torsion in the pediatric patient and is a great evaluation for acute scrotal pain. What’s more ,ultrasonography and color Doppler US have proven particularly useful in the differential diagnosis (12, 13).Despite its high sensitivity and specificity, both false-negative and false-positive findings occur. Testis with color doppler flow signals might be a obstacle for surgical exploration with resultant testicular loss in the false-negative cases.In patients with swollen and painful testicles, we should pay attention to these testicles with no blood flow signals, which is highly suggestive testicular torsion. However, patients with increased or no change in testicular blood flow signal should also be paid attention to.The presence of preserved intratesticular blood flow, which is often observed in these cases, may lead to a false negative diagnosis(5, 15). We should further observe the morphology and position of the testis, the echo of the testis parenchyma, especially evaluate the spermatic cord throughout its course(18), so as to avoid missing testicular torsion with blood flow signals.

Abbreviations

US: Ultrasonography

PACS: Picture Archiving and Communication System

Declarations

Ethics approval and consent to participate: All procedures performed in studies involving human participants were in accordance with the Research Ethics Committee of The Second Affiliated Hospital of Wenzhou Medical University. (Ethics Reference No.: L-2020-19).The requirement of the patient consent form was waived.

Consent for publication: Not applicable.

Availability of data and materials: The datasets used and analysed during the current study are available from the corresponding author on reasonable request.

Competing interests: On behalf of all authors, the corresponding author states that there is no conflict of interest.

Funding: No funding was received.

Authors' contributions:

All authors have read and approved the manuscript.

ZH X. Responsible for study design, conduct of the study, data collection, data analysis and manuscript preparation,drafting the article.

SS N. Participated in conduct of the study, data collection and data analysis.

SM W. Responsible for study design, conduct of the study, data collection, data analysis.

H Z. Responsible for study design, conduct of the study, data collection, data analysis.

K C. Responsible for study design, conduct of the study, data collection, data analysis.

HX L. Responsible for study design, conduct of the study, data analysis and manuscript preparation and revising article.

Acknowledgements: The authors thank the help from the the doctor from urology.

References

1. Sung EK, Setty BN, Castro-Aragon I. Sonography of the pediatric scrotum: emphasis on the Ts–torsion, trauma, and tumors. AJR American journal of roentgenology. 2012;198:996–1003.
2. Boettcher M, Bergholz R, Krebs TF, Wenke K, Aronson DC. Clinical predictors of testicular torsion in children. Urology. 2012;79:670–4.
3. Yang C, Song B, Tan J, Liu X, Wei GH. Testicular torsion in children: a 20-year retrospective study in a single institution. TheScientificWorldJournal. 2011;11:362–8.
4. Williamson RC. Torsion of the testis and allied conditions. Br J Surg. 1976;63:465–76.
5. Vijayaraghavan SB. Sonographic differential diagnosis of acute scrotum: real-time whirlpool sign, a key sign of torsion. Journal of ultrasound in medicine: official journal of the American Institute of Ultrasound in Medicine. 2006;25:563–74.
6. Janetschek G, Schreckenberg F, Mikuz G, Marberger M. Experimental testicular torsion: effect on endocrine and exocrine function and contralateral testicular histology. Urol Res. 1988;16:43–7.
7. Davenport M. ABC of general surgery in children. Acute problems of the scrotum Bmj. 1996;312:435–7.
8. Jefferson RH, Perez LM, Joseph DB. Critical analysis of the clinical presentation of acute scrotum: a 9-year experience at a single institution. The Journal of urology. 1997;158:1198–200.
9. Patriquin HB, Yazbeck S, Trinh B, Jequier S, Burns PN, Grignon A, Filiatrault D, Garel L, Dubois J. Testicular torsion in infants and children: diagnosis with Doppler sonography. Radiology. 1993;188:781–5.
10. Mellick LB. Torsion of the testicle: it is time to stop tossing the dice. Pediatr Emerg Care. 2012;28:80–6.
11. Kitami M. Ultrasonography of pediatric urogenital emergencies: review of classic and new techniques. Ultrasonography. 2017;36:222–38.
12. Gunther P, Schenk JP, Wunsch R, Holland-Cunz S, Kessler U, Troger J, Waag KL. Acute testicular torsion in children: the role of sonography in the diagnostic workup. European radiology. 2006;16:2527–32.
13. Kravchick S, Cytron S, Leibovici O, Linov L, London D, Altshuler A, Yulish E. Color Doppler sonography: its real role in the evaluation of children with highly suspected testicular torsion. European radiology. 2001;11:1000–5.
14. Munden MM, Williams JL, Zhang W, Crowe JE, Munden RF, Cisek LJ. Intermittent testicular torsion in the pediatric patient: sonographic indicators of a difficult diagnosis. AJR American journal of roentgenology. 2013;201:912–8.
15. Prando D. Torsion of the spermatic cord: the main gray-scale and doppler sonographic signs. Abdominal imaging. 2009;34:648–61.
16. Bandarkar AN, Blask AR. Testicular torsion with preserved flow: key sonographic features and value-added approach to diagnosis. Pediatric radiology. 2018;48:735–44.
17. Yidong L, Guo LX. Diagnosis and treatment of testicular torsion safety consensus. Journal of modern department of Urology. 2019;24:434–7.
18. Baud C, Veyrac C, Couture A, Ferran JL. Spiral twist of the spermatic cord: a reliable sign of testicular torsion. Pediatric radiology. 1998;28:950–4.
19. Skoglund RW, McRoberts JW, Ragde H. Torsion of the spermatic cord: a review of the literature and an analysis of 70 new cases. The Journal of urology. 1970;104:604–7.
20. Eaton SH, Cendron MA, Estrada CR, Bauer SB, Borer JG, Cilento BG, Diamond DA, Retik AB, Peters CA. Intermittent testicular torsion: diagnostic features and management outcomes. The Journal of urology. 2005;174:1532–5. discussion 5.
21. Kaye JD, Shapiro EY, Levitt SB, Friedman SC, Gitlin J, Freyle J, Palmer LS. Parenchymal echo texture predicts testicular salvage after torsion: potential impact on the need for emergent exploration. The Journal of urology. 2008;180:1733–6.

22. Hormann M, Balassy C, Philipp MO, Pumberger W. Imaging of the scrotum in children. European radiology. 2004;14:974–83.
23. Ingram S, Hollman AS. Colour Doppler sonography of the normal paediatric testis. Clin Radiol. 1994;49:266–7.
24. D'Andrea A, Coppolino F, Cesarano E, Russo A, Cappabianca S, Genovese EA, Fonio P, Macarini L. US in the assessment of acute scrotum. Crit Ultrasound J. 2013;5(Suppl 1):8.
25. Cassar S, Bhatt S, Paltiel HJ, Dogra VS. Role of spectral Doppler sonography in the evaluation of partial testicular torsion. Journal of ultrasound in medicine: official journal of the American Institute of Ultrasound in Medicine. 2008;27:1629–38.

Figures

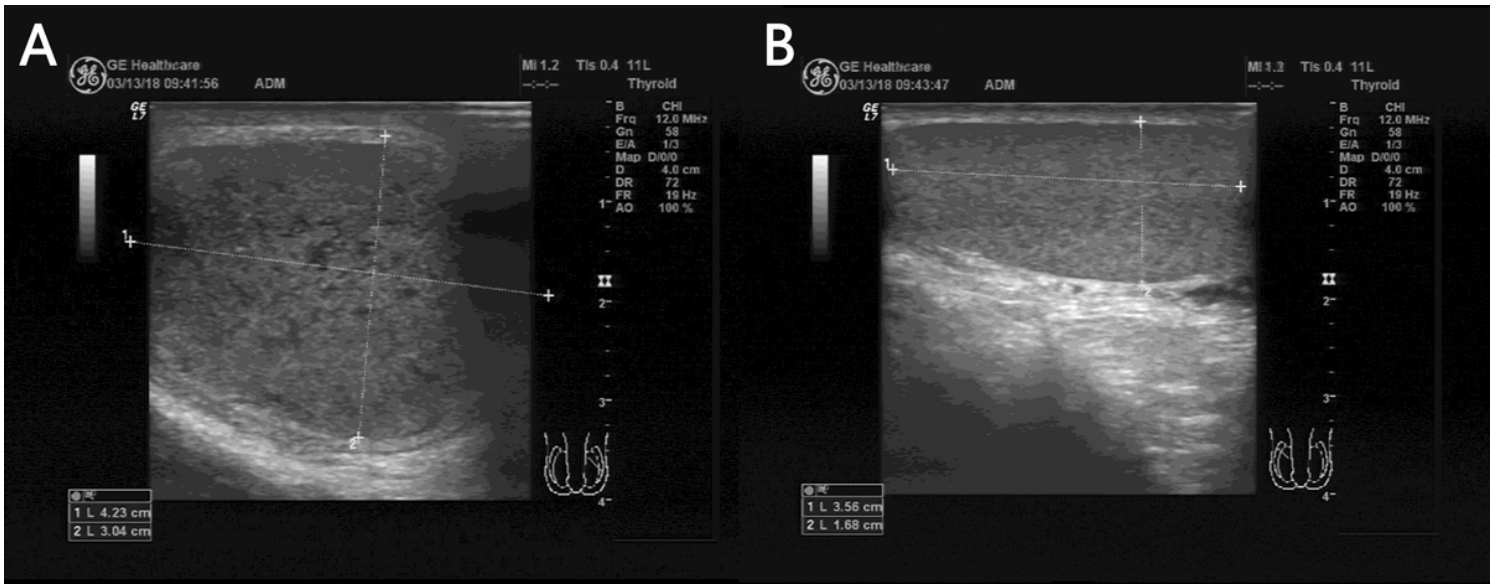

Figure 1

13 years 8 month-old boy with first episode of acute left scrotal pain for 4 days.The left testicle was twisted(A) and its testicle size was significantly larger than that of the right(B).

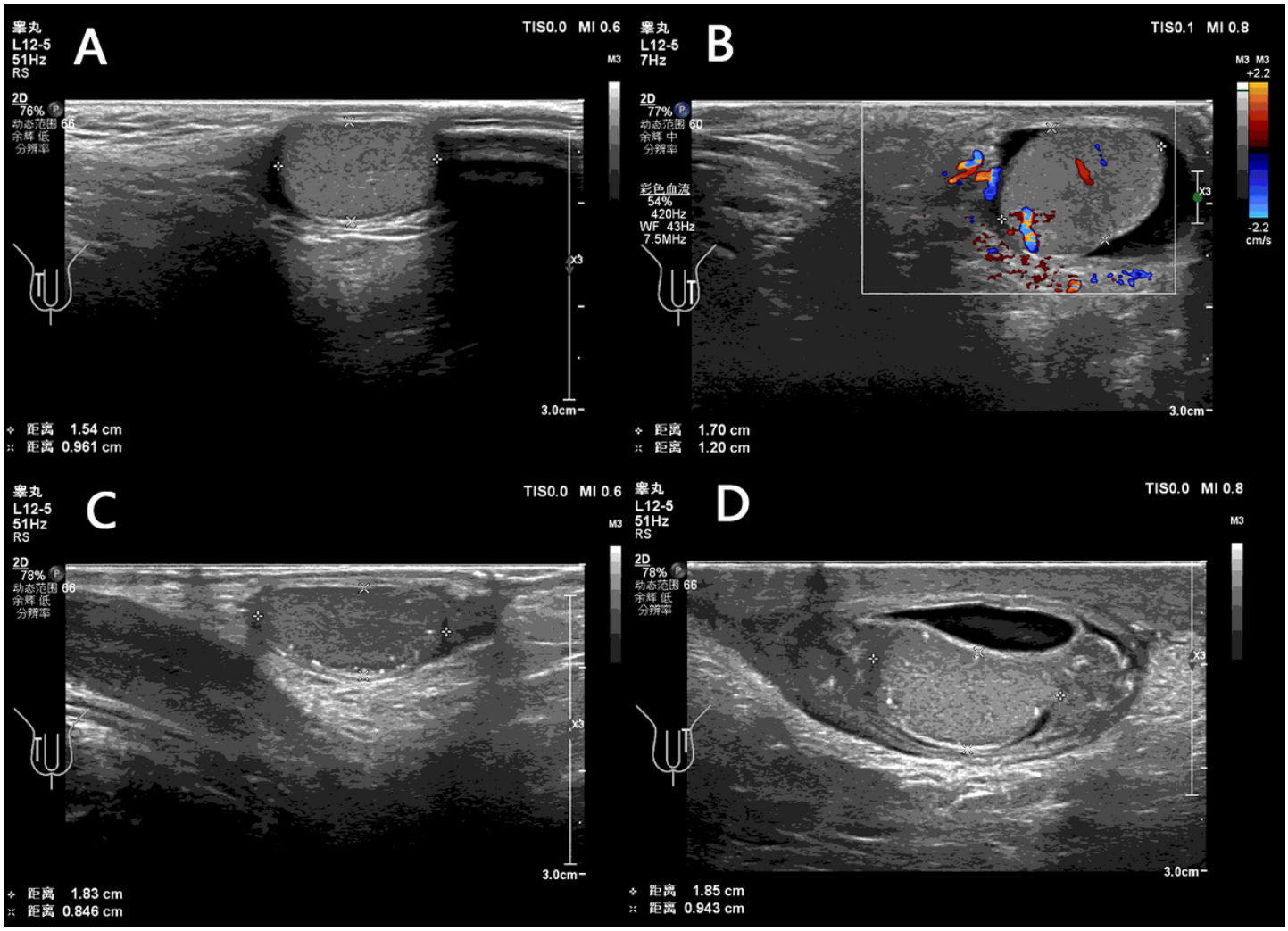

Figure 2

A,B.6 years 4 month-old boy with first episode of acute left scrotal pain for 2 days. A.Normal testicles, no change in testicular axial direction.B.Torsion of the testicles, testicles change in axial direction. C,D.8 years 3month-old boy with third episode of acute left scrotal pain for 5 days,initially misdiagnosed as epididymitis.C.Normal testicles, no change in testicular axial direction.D.Torsion of the testicles, testicles change in axial direction.

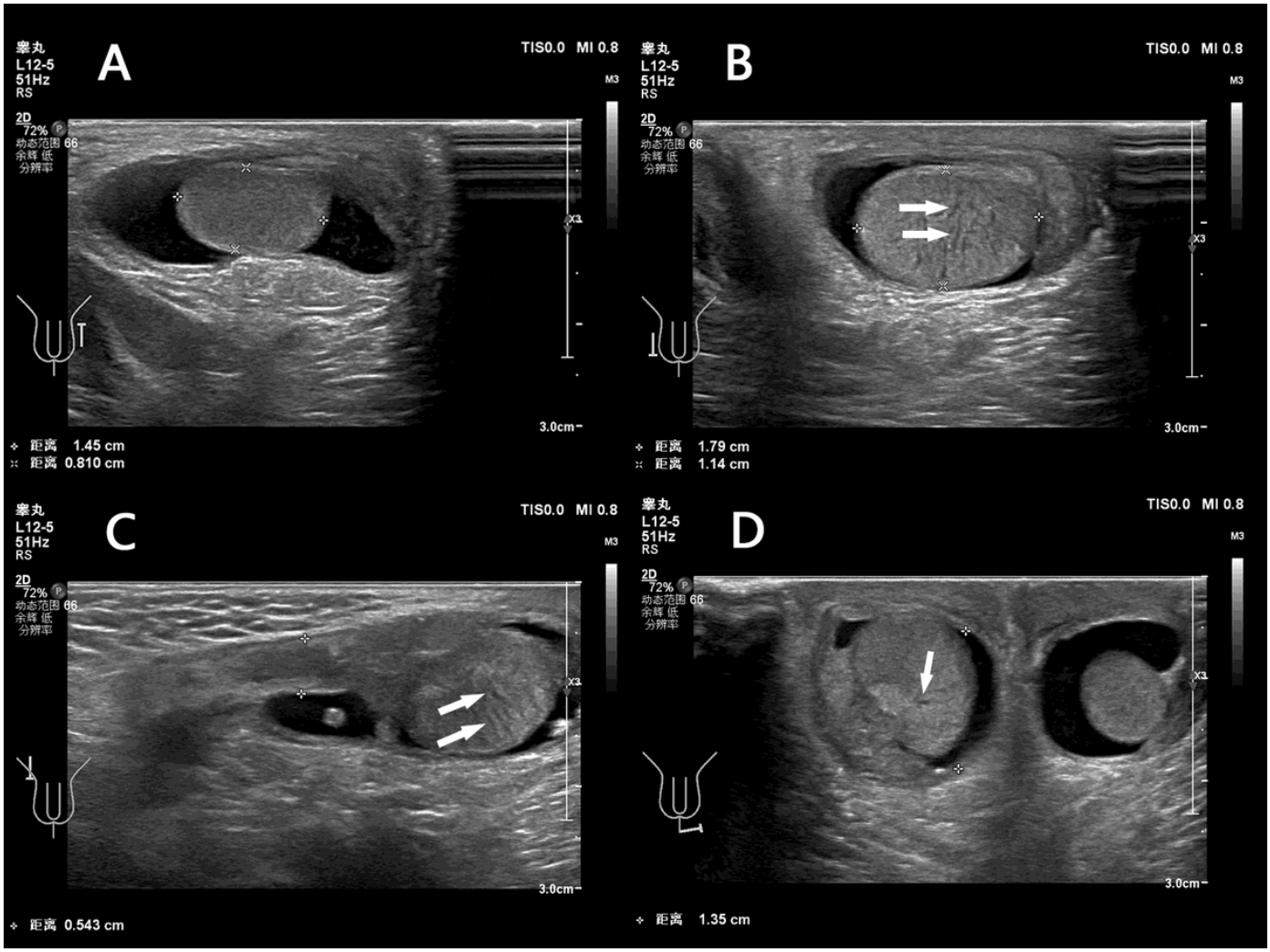

Figure 3

49 days boy with first episode of acute right scrotal swelling for 4 days, A was normal testicles, which echo was evenly. B,C,D were the torsion of the testicles, The echo of testis parenchyma was uneven and fissure anechoic around mediastinum(arrows).

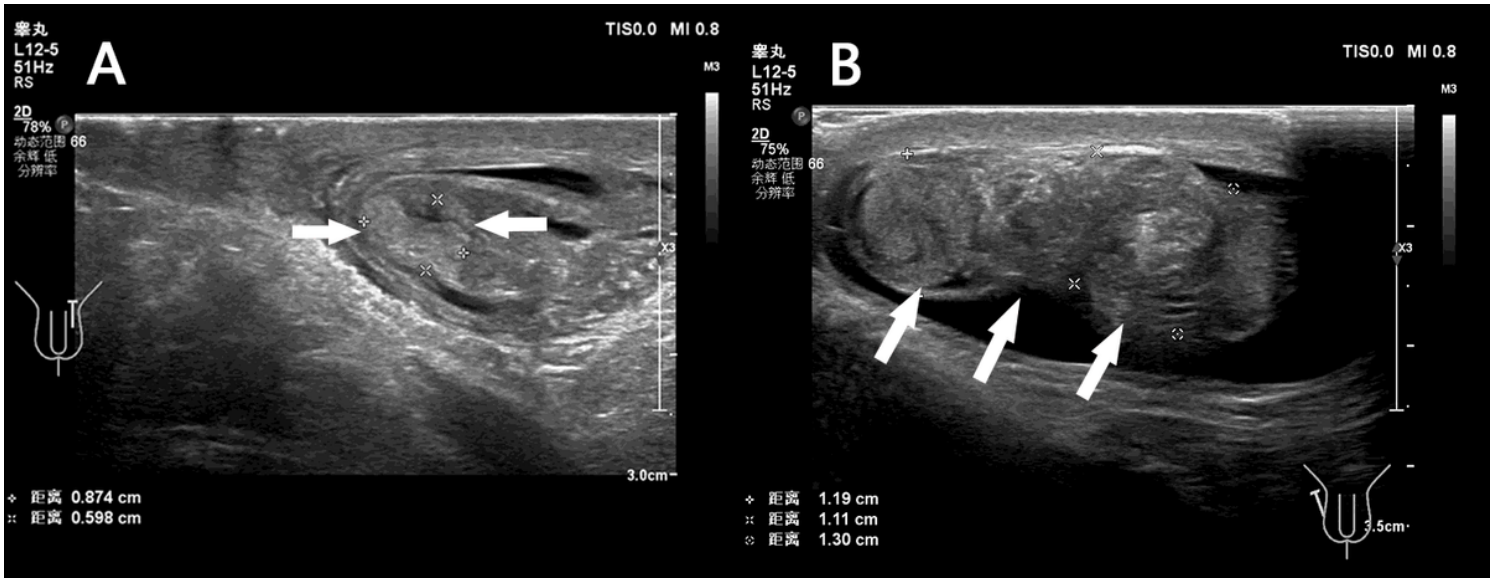

Figure 4

A.8 years 3month-old boy with third episode of acute left scrotal pain for 5 days,initially misdiagnosed as epididymitis.B.14 years 3month-old boy with first episode of acute right scrotal pain for 7 hours.The conglomerate of edematous epididymis and convoluted spermatic cord-“epididymal-cord complex”to form

pseudomass(arrows).

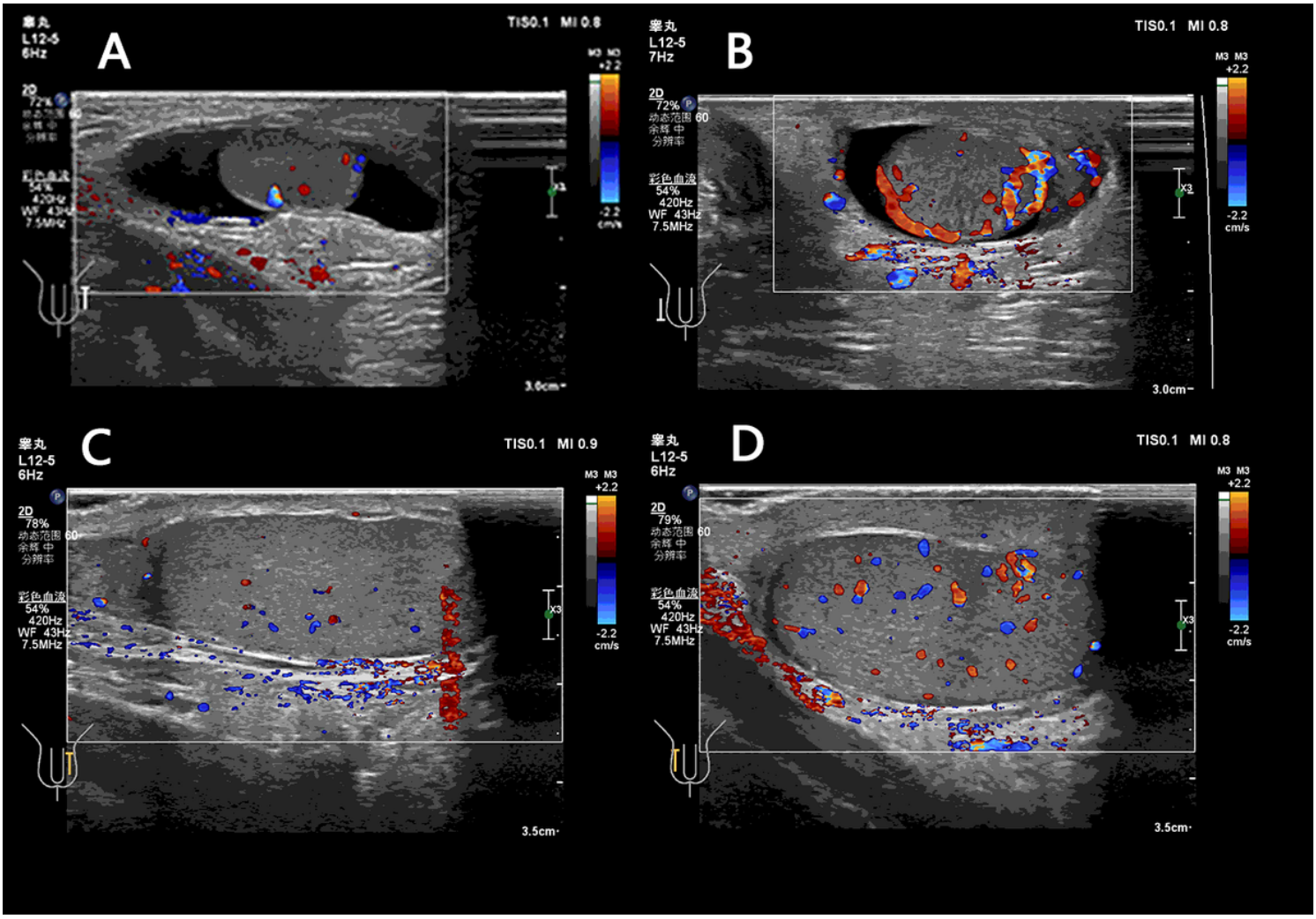

Figure 5

A and B,49 days boy with first episode of acute right scrotal swelling for 4 days.C and D, 14 years 3month-boy with first episode of acute right scrotal swelling for 7hours.AC were normal testicle, testicle color doppler flow is normal. BD were testicular torsion, testicular color doppler blood flow slightly increased.

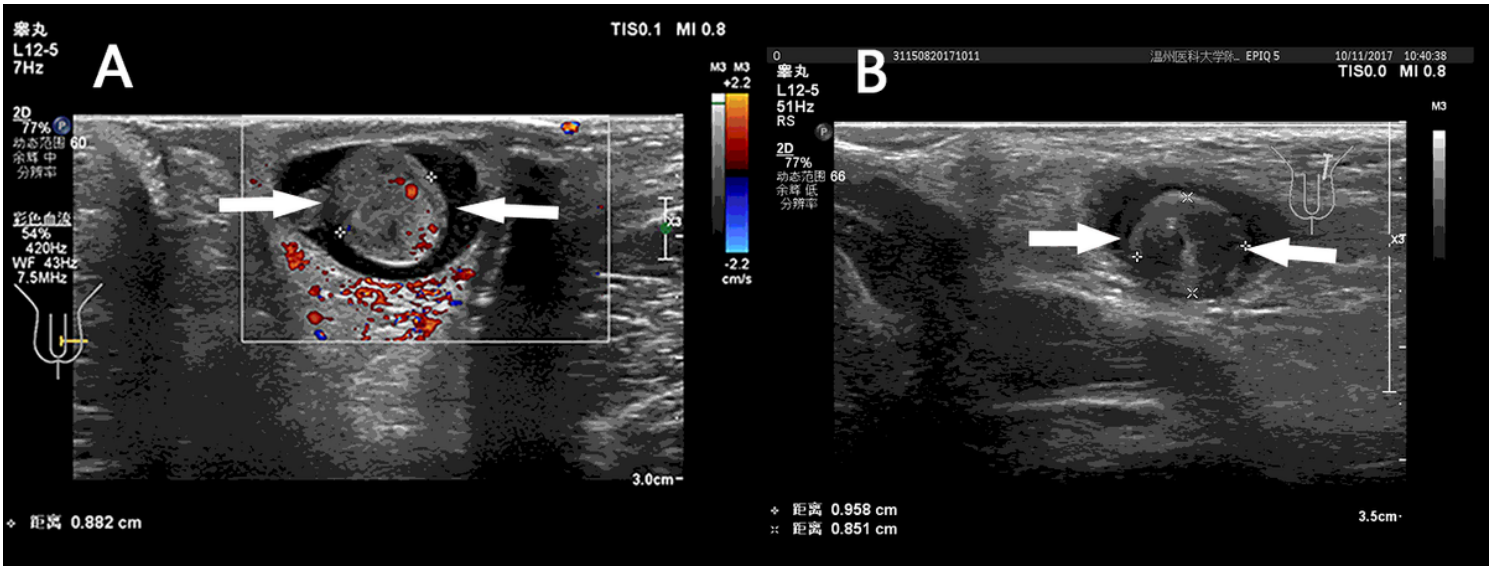

Figure 6

A.6 years 4 month-old boy with first episode of acute left scrotal pain for 2days. B.8 years 5 month-old boy with first episode of acute left scrotal pain for15 hours. A,B showed a “whirlpool sign” in spermatic cord(arrows).

Supplementary Files

This is a list of supplementary files associated with this preprint. Click to download.

- Video1.AVI