Wrist Tuberculosis-experience From Eighteen Cases: A Retrospective Study

longfei zou (1006433656@qq.com)
Southwest Medical University
meiyun tan (408940902@qq.com)
xing guo
Southwest Medical University
jiang guo
Southwest Medical University
hao xue
Southwest Medical University
shuling zheng
Southwest Medical University
jianhua zhang
Southwest Medical University
denghua huang
Southwest Medical University
hui lv
Southwest Medical University

Research article

Keywords: wrist, tuberculosis, arthrodesis, anti-tuberculous treatment, curative effect evaluation

Posted Date: July 29th, 2020

DOI: https://doi.org/10.21203/rs.3.rs-42568/v1

Abstract

Background

Wrist tuberculosis is a rare disease, easy to cause misdiagnosis, delay treatment and lead to poor prognosis. In this study, the clinical manifestations, diagnosis, treatment and prognosis of 18 cases of wrist tuberculosis were analyzed retrospectively.

Methods

We conducted a retrospective study investigating tuberculosis of the wrist, diagnosed in 18 patients from August 2013 to November 2018. Puncture biopsy confirmed the diagnosis. The study includes 11 males and 7 females, and 8 left and 10 right wrists. The average age was 53.5 ± 18.3 years and ranged from 15 to 81 years. The disease course was 1 to 42 months, with an average of 15.1 ± 11.3 months. Eighteen patients were treated with surgery and chemotherapy, 3 patients with severe bone defect were treated with wrist fusion, and 15 patients were treated with focus removal. The Gartland and Werley score, DASH score, the range of motion (ROM), grip strength, and imaging examinations were used to evaluate the postoperative recovery of the patients.

Results

Eighteen patients were followed up for 15 to 77 months, with an average follow up of 39.7 ± 15.3 months. The ESR and CRP levels were normal for all patients after chemotherapy. No recurrence of tuberculosis was observed in any of the patients. Among the 15 focus removal, the Gartland and Werley scores at admission, two weeks of chemotherapy, 1 month after surgery, and the last follow-up were 21.73 ± 4.33, 18.60 ± 3.16,11.27 ± 2.79, and 5.07 ± 2.28, respectively; and DASH scores were 45.87 ± 5.58, 39.47 ± 4.72,22.67 ± 6.54, and 6.73 ± 2.94, respectively. The wrist range of motion (ROM) and grip strength improved significantly compared to those at admission. Among the three cases of wrist fusion, 2 were fixed with a steel plate and the fixation position of wrist joint was good. One case was fixed with Kirschner wire and resulted in a slightly deformed wrist joint.

Conclusion

For the patients with wrist tuberculosis, early diagnosis, preoperative and postoperative chemotherapy, thorough focus removal, and appropriate fixation of the affected limb can help restore the function of the affected wrist, reduce the recurrence rate, and improve the quality of life.

Background

Tuberculosis is a chronic infectious disease caused by *Mycobacterium tuberculosis*. Tuberculosis infection is still a major health risk in developing countries. Patients infected with the autoimmune deficiency virus and those receiving immunosuppressive therapy are more likely to be infected with tuberculosis than normal individuals [1, 2]. Tuberculosis affects all organs of the human body and infections of the skeleton are the third most common after tuberculosis and lymphadenopathy, accounting for approximately 10–35% of tuberculosis's impact outside of the lungs [3]. The spine is the most frequently infected site [4] followed by large load-bearing joints (e.g., hip, knee, and ankle) [5]. Tuberculosis of the wrist is a rare but debilitating condition that typically affects young and middle-aged individuals. Tuberculosis of the joint usually has a long course and is rarely diagnosed before developing arthritis [6]. In wrist tuberculosis, the flexor tendon sheath and carpal capsule are the most frequently invaded structures while the extensor tendon sheath and flexor tendon sheath usually remain relatively unaffected [7]. Although wrist tuberculosis is rare, most of the patients are young and middle-aged. Early diagnosis and treatment may help restore the function of their affected limb and thereby improve their quality of life. The present study reviewed and analyzed the wrist tuberculosis cases from our hospital between August 2013 and November 2018, in order to gain further understanding of the clinical manifestations, diagnosis, and treatment of wrist tuberculosis.

Methods

Patients' data

Eighteen patients (female: 7, male: 11; age: 15–81 years, mean: 53.5 ± 18.3) with wrist tuberculosis were admitted to our department between August 2013 and November 2018. The course of disease ranged from 1 to 42 months (mean: 15.1 ± 11.3); 8 patients had tuberculosis of the left wrist and 10 the right wrist. Two patients had a history of pulmonary tuberculosis prior to the onset of carpal tuberculosis. We also reviewed the patients' history of diseases and identified any systemic diseases or other diseases that may impair the immune system. Preoperative examination revealed that two patients had a sinus formation with purulent exudate in the wrist joint. Before coming to our hospital, five patients had undergone debridement and removal of lesions in other hospitals but did not receive chemotherapy. Physical examination revealed wrist pain, swelling, restricted movement, sinus formation, pus flow, deformity, wrist mass and numbness, pain, stiffness, and mobility disorder; however, no low fever night sweats were observed. The general information of the patients is displayed in Table 1. Blood sedimentation (ESR) was detected by the instrument, normal (0–26 mm/H). The normal value of CRP was (0–5 mg/L).

Table 1
Clinical and pathology findings in eighteen patients with tuberculous infection of the wrist.

Patient	Age(years)/Sex/Side	Duration (months)	Symptoms	Coexisting Disease	Injury factors	Prior wrist surgery	ESR (mm/hour)	CRP (mg/L)	Pathology findings
1	15/F/L	19	Wrist pain, swelling, skin temperature arisen with limitation of motion	Nil	Nil	Nil	62	7.84	Caseating granulomatous with chronic inflammation cells
2	68/F/L	6	Wrist pain, swelling with limitation of motion	Hypertension, coronary heart disease	Toil	Nil	70	16..32	Granulomatous inflammation with Langerhans giant cells
3	50/M/R	12	Wrist swelling and fingers with limitation of motion	Nil	Nil	Nil	119	6.15	Caseating granulomatous, inflammation cells and acid-fast bacilli
4	70/F/R	16	Wrist pain, swelling, purulent secretion, sinus tract and fingers with limitation of motion	Nil	Nil	Nil	83	23.25	Granulomatous inflammation, with Langerhans giant cells
5	49/M/L	1	Wrist pain, swelling, fingers and wrist with limitation of motion	Nil	Nil	One month ago, the local hospital operated on the wrist	36	1.62	Caseating granulomatous, inflammation cells
6	58/M/L	30	Wrist pain, swelling with limitation of motion	Nil	Fall on the stairs	One year ago, the local hospital operated on the wrist	38.9	10.25	Chronic inflammation with Langerhans giant cell and rice bodies
7	73/F/R	42	Wrist pain,swelling, skin temperature arisen and fingers with limitation of motion	Nil	Nil	Nil	30	3.64	Granulomatous inflammation and acid-fast bacilli
8	64/F/R	6	Wrist pain, swelling with limitation of motion, and stiffness of fingers	Nil	Nil	Nil	89	15.37	Caseating granulomatous and Langerhans giant cells
9	60/F/R	9	Wrist pain, swelling with numbness of fingers	Nil	Nil	Nil	27	3.99	Inflammation with Langerhans giant cells and acid-fast bacilli
10	55/F/L	18	Wrist pain, swelling with limitation of motion	Nil	Nil	Eight months ago, the local hospital operated on the wrist	32	6.00	Granulomatous inflammation with Langerhans giant cells

Patient	Age(years)/Sex/Side	Duration (months)	Symptoms	Coexisting Disease	Injury factors	Prior wrist surgery	ESR (mm/hour)	CRP (mg/L)	Pathology findings
11	81/M/R	6	Wrist pain, swelling, malformation, skin temperature arisen, purulent secretion, sinus tract with limitation of motion	Diabetes mellitus	Sprain	Nil	50	146.17	Chronic inflammation cells acid-fast bacilli and rice bodies
12	41/M/R	24	Wrist pain, swelling, fingers and wrist with limitation of motion, numbness of fingers	Nil	Nil	One year ago, the local hospital operated on the wrist	14	1.12	Caseating granulomatous and inflammation cells
13	69/F/L	15	Wrist pain, swelling with numbness of fingers	Hypertension	Nil	Nil	30	14.26	Caseating granulomatous with Langerhans giant cells and acid-fast bacilli
14	59/F/R	26	Wrist pain, swelling, skin temperature arisen, fingers and wrist with limitation of motion, numbness of fingers	Nil	Fall	Nil	64	38.43	Granulomatous inflammation inflammation cells and rice bodies
15	18/M/L	5	Wrist pain, swelling with limitation of motion	Nil	Nil	Nil	38	7.35	Granulomatous inflammation Inflammation with Langerhans giant cells
16	60/F/R	1	Wrist pain, swelling with skin temperature arisen	Nil	Nil	Nil	75	74.94	Caseating granulomatous acid-fast bacilli and rice bodies
17	29/M/R	28	Wrist pain, swelling with limitation of motion	Nil	Nil	Six months ago, the local hospital operated on the wrist	62	8.67	Chronic inflammation with Langerhans giant cell and granulomatous inflammation
18	45/F/L	18	Wrist pain, swelling, malformation with limitation of motion	Hepatitis B	Nil	Nil	58	11.99	Caseating granulomatous Inflammation with Langerhans giant cells and acid-fast bacilli

Examinations and treatment:

Examinations

Preoperative puncture biopsy was used to confirm the diagnosis of wrist tuberculosis, and the puncture was cultured and subjected to a Zieh1-Neelsen stain at the same time. The patients were examined using routine blood, biochemical, and coagulation tests. Radiography and magnetic

resonance imaging (MRI) of the affected wrist were used to evaluate the lesion and design the operative procedure. The range of motion (ROM) and grip strength were used to evaluate the wrist's function. The physician-based Gartland–Werley score [8] and the patient-reported DASH (disabilities of the arm, shoulder, and hand) score system [9]were used to indicate the overall functional outcome. Before the culture results, chemotherapy was administered for 2 weeks with four oral anti-tuberculous agents: isoniazid 5 mg/kg, rifampicin 10 mg/kg, pyrazinamide 20 mg/kg, and ethambutol 15 mg/kg per day. After the culture results were obtained, the drug administration was adjusted according to the sensitivity test results. Since tuberculosis is a wasting disease and patients generally have low albumin, all patients consulted the nutrition department for perioperative hypoproteinemia, an important part of the treatment. Cefuroxime was used prophylactically for 3 days during the perioperative period to prevent infection and eliminate the bacteria in the joint.

Operation

All patients in this study were operated on by the same surgeon. Among the 18 cases, 12 cases were anesthetized using tracheal intubation and 6 cases were anesthetized using brachial plexus. All patients were in the supine position, and balloon tourniquet was bound to the upper arm to prevent intraoperative hemorrhage. The tourniquet was inflated to 200KPa. A 6 cm S-shaped incision was made on the affected side through the wrist. The skin and subcutaneous tissue were cut layer by layer. For the lesions of wrist joint on the palm side, the tendon of palmaris longus muscle was pulled to the radial side, the deep fascia and transverse carpal ligament were opened, the median nerve was carefully dissociated, and the tendon of the wrist was separated from the supporting band of the flexor carpi. Numerous rice bodies and gray caseous substances were observed in and around the wrist for some patients. The lesion was curetted repeatedly to remove all the rice bodies, caseous substance, and surrounding necrotic tissues. Removed tissues were sent for pathological biopsy, general bacterial culture, bacterial and fungal smear, and acid-fast staining tests. In some patients, severe erosion of the carpal bones was found intraoperatively, and the residual bone mass was considered inadequate for stabilizing the wrist and restoring its function after removal of the necrotic bone. The right length and shape of the steel plate were chosen, in line with the functional position of the wrist joint. The proximal end of the plate was fixed to the radius, the distal end of the plate was fixed to the third metacarpal, and the wrist joint was fixed to the functional position. If the Kirschner wire would fix the wrist firmly, a 2.0 mm Kirschner wire was inserted into the ulnar and radial sides to fix the wrist in the functional position. The incision was repeatedly rinsed with normal saline, hydrogen peroxide, and iodophor. After exploring the carpal canal to ensure the absence of evident compression, two rubber drainage strips were placed and the wound was wrapped with a sterile dressing. Except for those treated by plating, all patients were fixed with plaster and the carpal joint was adjusted to the functional position.

Postoperative Treatment:

After surgery, all patients were administered intensive treatment with isoniazid (5 mg/kg), rifampicin (10 mg/kg), pyrazinamide (20 mg/kg), and ethambutol (15 mg/kg) tetrad anti-TB drugs for 3 months, followed by the oral drugs isoniazid (5 mg/kg) and rifampicin (10 mg/kg) for 9 months. Liver and kidney functions were reviewed every month. The patients were followed up every four weeks for six months after discharge. Patients were then followed up every 8 weeks from 6 months to 1 year. In the second year, patients were followed up every 3 months for the first 6 months and then every 6 months. During each follow-up, ESR and CRP were measured until they returned to normal levels. X-rays were used to assess the wrist recovery at each follow-up.

Outcome Measurement:

The patients were followed-up by the Gartland and Werley scale and DASH score, and wrist function was evaluated using the range of motion (ROM) and grip strength. Wrist mobility (flexion, extension, supination, and pronation) was measured with a goniometer and grip strength with a Jamar dynamometer. The Gartland-Werley scale is a physician-based scoring system that includes residual deformity, subjective findings, ROM, postoperative complications, and poor finger function. The score ranges from 0 to 52, with a higher score indicating a worse wrist function. DASH is a validated patient report questionnaire for assessing the patient's ability to perform daily activities. The scores range from 0 to 100, with 0 for no disability and 100 for maximum disability. X-ray, CT, and MRI scans are performed when necessary.

Statistical Analysis:

All statistical analyses were conducted using the SPSS Statistical Software (SPSS for Windows, version 23.0). All data are presented as mean and standard deviation. ANOVA was used to compare the differences between Gartland and Werley's wrist score and DASH. P values less than 0.05 were considered statistically significant.

Results

18 patients were followed up for 15 to 77 months with an average of 39.61 ± 15.37 months. There were two cases of the peripheral skin defect, one of which healed after local dressing and the other recovered after a skin graft. All patients completed their chemotherapy under direct observation therapy (DOT). There were no adverse reactions nor changes to the chemotherapy regimens. The culture of wrist secretions did not produce any drug-resistant bacteria. No patients showed any recurrence symptoms during the follow-up of at least 15 months, the ESR and CRP levels were normal for all patients after chemotherapy, and X-ray examination showed no lesions in the affected side of the wrist. For the three patients with a wrist joint fusion, two of them internal fixation with a steel plate was employed. During the follow-up, the steel plate was confirmed to be not loose, fractured, or displaced. 1 patient was fixed with Kirschner wire. During the eight months of follow-up, Kirschner wire displacement occurred. Finally, the palm

deviates to the ulnar side. Gartland and Werley and DASH scores of the 15 patients that underwent simple lesion removal were statistically analyzed during admission, two weeks after chemotherapy, 1 month after surgery, and at the last follow-up. The difference was statistically significant (Table 2). The range of motion (ROM) and grip strength had significantly improved (Table 3).

Table 2
Gartland-Werley and DASH score at on admission, two weeks of chemotherapy, one month after surgery and last follow-up.

Point-in-time	Gartland–Werley score (points)	DASH (points)
On admission	21.73 ± 4.33	45.87 ± 5.58
Two weeks of chemotherapy	18.60 ± 3.16	39.47 ± 4.72
One month after surgery	11.27 ± 2.79	22.67 ± 6.54
Last follow-up	5.07 ± 2.28	6.73 ± 2.94
F	72.228	483.182
P	<0.0001	<0.0001

Table 3
Comparison of ROM and grip strength of the operated wrist at on admission, two weeks of chemotherapy, one month after surgery and last follow-up.

	On admission		Two weeks of chemotherapy		One month after surgery		Last follow-up	
	Mean(SD)	% of value on contralat. side	Mean(SD)	% of value on contralat. side	Mean(SD)	% of value on contralat. side	Mean(SD)	% of value on contralat. side
Flexion (°)	43.3(6.6)	65.7	47.7(5.6)	70.3	53.7(5.1)	82.7	61.9(5.0)	95.5
Extension(°)	44.0(7.3)	62.4	48.5(5.8)	68.3	53.7(5.8)	78.4	62.9(4.7)	91.9
Pronation(°)	59.0(8.7)	67.5	63.5(7.3)	72.1	68.1(6.7)	76.3	77.3(4.6)	87.6
Supination(°)	56.1(5.3)	58.7	61.7(5.6)	62.3	67.7(5.2)	73.9	75.9(4.8)	81.4
Radial deviation(°)	13.8(4.0)	63.0	15.8(3.3)	67.6	17.7(2.9)	81.3	21.4(3.2)	93.0
Ulnar deviation(°)	24.3(4.3)	73.3	25.7(4.4)	76.9	28.1(3.5)	85.5	32.1(2.6)	92.2
Grip strength(kg)	12.7(5.6)	43.3	15.2(4.7)	50.5	20.5(3.5)	68.3	28.1(4.7)	93.5

Selected case reports

Case 1

A 29-year-old right-handed woman had no other complications and no previous history of tuberculosis. The symptoms were progressive pain, swelling, and limited movement of the right wrist for 24 months. Physical examination showed that the skin temperature of the right wrist was increased and that there was a 4 cm mass on the dorsal side, which had wave motion; however, the skin was not broken. Wrist mobility was limited and the range of activity was recorded. An X-ray of the wrist showed the collapse of the joint (Fig. 1a). A CT of the wrist showed extensive damage to the distal radius and carpus, disordered bone structure, increased patchy density shadow, and multiple gritty changes (Fig. 1b). An MRI of the wrist showed that the structure of the wrist joint was disordered, the carpal bone was damaged, the surrounding soft tissue was swollen, and that multiple tendons were damaged (Fig. 1c). The results of the biopsy showed Langerhans giant cells and chronic granulomatous inflammation in the right wrist (Fig. 1d). Zieh1-Neelsen stains were positive. The ESR level was 62 mm/hour whereas the CRP level was 8.67 mg/L. After receiving rifampicin, isoniazid, pyrazinamide, and ethambutol for two weeks, surgical treatment was performed, and the pathological synovial tissue was resected and internal fixation performed. Resection of lunate and capitate bone was carried out during the operation. Histology showed necrotizing granulomatous inflammation. An 8-hole 2.7 mm stainless steel plate was used to fix the joint. The proximal part was fixed to the radius and the distal part was fixed to the third metacarpal. The established chemotherapy plan was strictly followed after the operation. The incision healed completely at two weeks and no recurrence was observed at 48 months follow-up.

Case 2

A 50-year-old right-handed middle-aged woman had no other medical history. The ulnar mass of the right carpal palm was found one year ago and the dorsal mass six months ago. Physical examination showed that the right wrist joint was swollen and that its movement was limited. The ulnar

mass of the palm of the right wrist was about 2·2 cm while the dorsal mass was about 3·3 cm. The shape was irregular, the touch was tough, and the movement was poor. The movement of the right finger was limited and the right thumb was dysfunctional. The X-ray of the wrist showed that the bone structure of the right multiple carpal bones was disordered, and had a reduced bone density and narrowed joint space (Fig. 2a). Ultrasonic examination showed an irregularly shaped, 2.4 gular cm cystic mass in the dorsal skin of the right wrist with a clear boundary. There was a super echo in the mass and no obvious blood flow signal was observed in CDFI (Fig. 2b). CT revealed the disordered bone structure of the right carpal bones, the base of the 1–5 metacarpal bone and the carpal joint surface of the radius, reduced density, and multiple insect-like bone destruction areas (Fig. 2c). MRI showed multiple bone destruction of the right carpus and mass shadow in the palmar soft tissue at the distal end of the right radius and ulna (Fig. 2d). Biopsy revealed caseous granuloma and inflammatory cells (Fig. 2e). Zieh1-Neelsen stains were positive. The level of ESR was 119 mm/hour the level of CRP was 6.15 mg/L. Two weeks after chemotherapy with rifampicin, isoniazid, pyrazinamide, and ethambutol, surgical treatment was conducted and the synovial tissue of the lesion was resected followed by a Kirschner wire fixation. Two 2.0 mm Kirschner wires were used to fix the wrist on the ulnar and radial sides (Fig. 2f). Histological examination showed necrotizing granulomatous inflammation. The established chemotherapy plan was strictly followed after the operation. After 8 months of follow-up, the Kirschner wires were displaced (Fig. 2g). The fusion of the wrist was good. The Kirschner wire was taken out and there was no recurrence during the 39 months follow-up.

Case 3

A 49-year-old right-handed woman had no other complications. The manifestations included the left wrist cyst, pain, swelling, flush skin, and warm skin for a month. A scar incision of 3–4 cm long was found on the left wrist. The left wrist was swollen, tenderness was obvious, and the movement was limited. One month before the admission, the patient underwent "cyst resection" in another hospital. No pathological biopsy or chemotherapy was performed after the operation. Symptoms were not relieved, persistent pain, and swelling. An X-ray revealed multiple destructions of carpal bone and narrowing of the joint space on the left side (Fig. 3a). On CT scan, the bone structure of the left carpus appeared disordered, had irregular patchy exudation, and was swollen around the soft tissue (Fig. 3b). MRI revealed the destruction of the left carpal bone and the multiple nodular shadows in the wrist (Fig. 3c). Biopsy revealed caseous granuloma and inflammatory cells (Fig. 3e). Although the Zieh1-Neelsen stains were negative, cultures returned positive for *Mycobacterium tuberculosis*. The level of ESR was 36 mm/hour and the level of CRP was 1.62 mg/L. Rifampicin, isoniazid, pyrazinamide, and ethambutol were used for 2 weeks after the chemotherapy, and the patients were treated by debridement and plaster external fixation. Histology revealed multiple tuberculous granulomas with caseous necrosis and multinucleated giant cells. After 2 weeks, the incision healed had well and the plaster was fixed for an additional 4 weeks. During the 62 months follow-up period, no recurrence was observed.

Discussion

Tuberculosis of the wrist causes a variety of conditions such as skin lesions, tenosynovitis, bursitis, osteomyelitis, arthritis, and tuberculous allergic reaction [10]. Early manifestations of tuberculosis of the wrist joint, however, are not typical as they may start gradually and advance over a long time [11]. During the early stage of simple tuberculosis of the wrist, the lesions are mostly confined to the synovium of the wrist, joint capsule, and other surrounding soft tissues. The patient experiences pain and swelling of the wrist without exhibiting any manifestation characteristics of tuberculosis such as hot flashes, night sweats, and poor appetite. As the infection advances, the wrist mobility becomes limited, the pain and swelling aggravate, and the abscesses and sinus tract may form locally. With an increasing exudation of the focus, the wrist pressure increases causing ischemia and necrosis of the adjacent tendons and nerves. Further development of these pathological changes results in the destruction of the periosteum, followed by necrosis and degeneration of the bones. When pathologies develop to the edge of the articular surface, the articular cartilage erodes and the subchondral bone is destroyed. With the destruction of the carpal bones, the spaces are filled by necrotic tissue resulting in arthritis and deformity of the affected carpal joint [12]. Chandrasekharan et al. believe that tuberculosis of the wrist joint can be histologically divided into three stages. During the early stage, granuloma infiltration is present in the tendon sheath, followed by fiber tissue destruction and caseation of the tendon sheath. During the last stage, the tendon is replaced by infiltrating granuloma and ruptures [7], and the wrist deformity is increased.

Early diagnosis of this disease is difficult and therefore the misdiagnosis rate is quite high. It takes an average of 16–19 months from the onset of carpal symptoms for a clear diagnosis [11]. In our patients, the course of the disease was (15.1 ± 11.3) months. Tuberculosis of the wrist can originate from trauma-related infection or through the pathogen transport by blood circulation from the other organs. It can also be caused by an infection of wrist joint by *Mycobacterium tuberculosis* after a trauma. In our case, four (22%) patients had a history of wrist trauma. However, upon the occurrence of bone and joint tuberculosis, the proportion of patients with previous tuberculosis was 1 / 3 − 1 / 2 [13], and the proportion of patients with active tuberculosis was lower. In our series, only 2 (11%) patients had a previous diagnosis of tuberculosis. Therefore, it is important to determine whether the patients have tuberculosis or had a previous history of tuberculosis so that it may be used for the diagnosis of wrist tuberculosis. Blood tests of patients with wrist tuberculosis revealed increased levels of ESR and CRP and decreased levels of albumin. Radiographically, the majority of the lesions showed wrist masses with unclear boundaries, bone destruction, narrowing of the carpal joint space, and involvement of the distal radius and ulna. With disease progression, the invasion of the carpal bones by the lesion became more advanced, forming extensive periostitis [14]. However, in the case of simple synovial tuberculosis, there was no clear radiographical sign of osteoporosis or bone destruction. During the early stage of wrist tuberculosis, it is difficult to radiographically diagnose the lesion. In case of evident radiographical signs of joint destruction and calcification, further imaging examinations are warranted [15]. MRI is an effective tool for identifying carpal tuberculosis [16]. It can clearly show the soft tissue of the wrist, offering a clearer understanding of the tendon injury, blood vessel, and articular cartilage. It can also detect early effusion in the wrist as well as the inflammatory changes of bone. The carpal tuberculosis MRI showed rice bodies in the carpal mass

and abnormal thickening of the synovium. On T2WI, the low-density lesions, low-density synovium with central erosion and surrounding abscess are important markers that distinguish tuberculosis from other types of arthritis [17, 18]. MRI examination allows for an early diagnosis of wrist tuberculosis. In recent years, color Doppler ultrasonography had also commonly been used for the diagnosis of wrist diseases. For example, during effusion and empyema in the wrist, ultrasonography can clearly identify their location and volume and reveal the involvement of blood vessels, nerves, and tendons in the wrist joint [15]. When rice bodies are observed intraoperatively in the wrist joint, it is highly indicated to be tuberculosis. There are two opinions regarding the formation of rice bodies. One is that the synovium is necrotic and exfoliated, and is wrapped by fibrin. The other states that they are the formation of mature collagen, reticular protein, and elastin, similar to connective tissue[15]. Histopathology is the gold standard for the diagnosis of tuberculosis [13]. Earlier studies divided pathological manifestations of wrist tuberculosis into three stages. Stage 1 is tissue hyperemia and edema, infiltration and exudation of inflammatory cells, accompanied by purulent secretion. Stage 2 is the synovial infarct shedding, fibrin wrapping, formation of rice granules [15]. During Stage 3, the patient develops synovial thickening with nodular granuloma. Tuberculosis of the wrist is often differentiated from suppurative infection, tenosynovitis, giant cell tumor of the tendon sheath, sarcoidosis, pigmented villonodular synovitis, gouty arthritis, and rheumatoid arthritis [7].

Early use of anti-tuberculosis drugs is key to successful treatment [19]. During the early stage, if the soft tissue and adjacent bones are not affected, the disease can be conservatively managed with drugs. If the conservative treatment proves ineffective, an operation must be considered. When the patient develops bone destruction, the infected tissues should be surgically thoroughly removed [20]. The operation procedures undertaken are based on the patient's conditions. However, no matter what procedures, the general principle is to provide sufficient, combined chemotherapy, and complete focus removal, appropriate fixation after the operation, and strengthening of the physique. These are key to prevent the recurrence of joint tuberculosis. A combination of operation and chemotherapy can preferably alleviate the symptoms, and chemotherapy should be delivered preoperatively as it can reduce bone destruction and expansion of the infection [21]. In our study, five patients received antecedent surgical clearance of the focus of the wrist. However, they were not given anti-tuberculous postoperatively, a factor that likely contributed to the recurrence of wrist tuberculosis. Surgical debridement without prescription of chemotherapeutic agents may lead to the recurrence of wrist tuberculosis [7]. Chemotherapy should follow the basic principles of "early, regular, whole process, appropriate amount, and combination". For drug-sensitive tuberculosis with a definite diagnosis, the first choice of drug treatment scheme has been the same since the 1970s [22]. During operation, advisable not to excessively pursue small incision. Instead, it is essential to fully expose the focus, protecting the blood vessels and nerves of the wrist, and thoroughly remove the focus tissue, especially the caseous substance and rice bodies, including the necrotic carpal bone, tendon, tendon sheath, and the surrounding soft tissue, and to fully scrape the focus tissue with a curette until the normal bone surface and tissue ooze blood. In case of a severely erosion of the carpal bones, the wrist function of cannot be restored after removing the necrotic bone, joint fusion can be performed. Arthrodesis can be performed with steel plates or Kirschner wires. The steel plate should be used for internal fixation if there are more necrotic carpal bones and if the wrist joint is unstable after more carpal bones are removed. Compared to the Kirschner wire, the fixation is more reliable; however, the cost is higher. If there is less amount of wrist bone removal and if the Kirschner wire can be fixed firmly, the patient and their guardian should be consulted. Kirschner wire fixation may fix the wrist in a deformed position. Among the three cases of wrist fusion, 2 were fixed with a steel plate and the fixation position of wrist joint was good. One case was fixed with Kirschner wire and resulted in a slightly deformed wrist joint. Recently, it has been reported that patients with a tuberculosis-related bone defect can be implanted with a 3D-printed porous composite scaffold. Isoniazid and rifampicin can be modified and added to the implant. Through 3D printing, bone defects can be repaired and bone regeneration is promoted. The scaffold slowly releases antituberculosis drugs, allowing for a high drug concentration around the focus while keeping the systemic concentration below the safety limit [23]. Some studies have reported a vacuum suction drainage combined with external fixation for a safe, reliable, and effective treatment for severe wrist tuberculosis. This modality also effectively reduces the incidence of infection, promotes the functional reconstruction, shortens the wound healing time, and reduces the recurrence of tuberculosis [24].

Conclusions

For the patients with wrist tuberculosis, early diagnosis, preoperative and postoperative chemotherapy, thorough focus removal, and appropriate fixation of the affected limb can help restore the function of the affected wrist, reduce the recurrence rate, and improve the quality of life.

Abbreviations

DASH
Disabilities of the arm, shoulder, and hand; ROM:Range of motion; ESR:Erythrocyte sedimentation rate; CRP:C-reactive protein; CT:Computed tomography; MRI:Magnetic Resonance Imaging; CDFI:Color doppler flow imaging; DOT:Direct observation therapy

Declarations

Ethics approval and consent to participate:The study was approved by the Ethics committee of St. Mary`s Hospital of Catholic University. All animal experiments were performed with the approval and guidance of the Institutional Review Board (CMCDJ-AP-2012-017).

Consent for publication:All authors have read and approved the publication.

Availability of data and materials:Authors declares that data and materials in the study are available from the corresponding author Y.Y. Kim on reasonable request.

Competing interests: None

Funding: No funds were received in support of this work.

Author contributions: MQ: participated in experimental acquisition and data, analysis of results, and drafting of the manuscript; JK andWH:conducted the analysis of results and statistical analysis; and YK: participated in study design, formation of hypotheses, interpretation of data, and preparation of manuscript.

Acknowledgments: This work was supported by the Catholic University of Korea, Daejeon St. Mary`s Hospital, Clinical research institute.

Author details

[1]Department of Orthopedic Surgery, The Affiliated Hospital of Southwest Medical University, No. 25 Taiping Road, Luzhou, Sichuan 646000, People's Republic of China

References

1. Casado JL, Moreno S, Fortun J, Antela A, Quereda C, Navas E, Moreno A, Dronda F. Risk factors for development of tuberculosis after isoniazid chemoprophylaxis in human immunodeficiency virus-infected patients. Clin Infect Dis. 2002;34(3):386–9. doi:10.1086/324746.
2. 10.1093/qjmed/77.1.1039
   Qunibi WY, al-Sibai MB, Taher S, Harder EJ, de Vol E, al-Furayh O, Ginn HE. (1990) Mycobacterial infection after renal transplantation–report of 14 cases and review of the literature. Q J Med.1990;77 (282):1039–1060. doi:10.1093/qjmed/77.1.1039.
3. Sharma SK, Mohan A. Extrapulmonary tuberculosis. Indian J Med Res. 2004;120(4):316–53.
4. Liu Z, Li W, Zhang Y, Wu Y, Xiao X, Sun Z, Yang Y, Hu W, Wang X, Zeng H. Analysis of Clinical Factors, Bacterial Genotyping, and Drug Resistance for Spinal Tuberculosis in South-Central China. Biomed Res Int 2020:9871390. doi:10.1155/2020/9871390.
5. Malaviya AN, Kotwal PP. Arthritis associated with tuberculosis. Best Pract Res Clin Rheumatol. 2003;17(2):319–43. doi:10.1016/s1521-6942(02)00126-2.
6. Evanchick CC, Davis DE, Harrington TM. Tuberculosis of peripheral joints: an often missed diagnosis. J Rheumatol. 1986;13(1):187–9.
7. Chandrasekharan J, Sambandam SN, Cheriyakara S, Mounasamy V. Tuberculous tenosynovitis presenting as finger drop: a case report and a systematic review of the literature. Muscles Ligaments Tendons J. 2016;6(2):258–63. doi:10.11138/mltj/2016.6.2.258.
8. von Recum J, Matschke S, Jupiter JB, Ring D, Souer JS, Huber M, Audige L. Characteristics of two different locking compression plates in the volar fixation of complex articular distal radius fractures. Bone Joint Res. 2012;1(6):111–7. doi:10.1302/2046-3758.16.2000008.
9. Hudak PL, Amadio PC, Bombardier C. Development of an upper extremity outcome measure: the DASH (disabilities of the arm, shoulder and hand) [corrected]. The Upper Extremity Collaborative Group (UECG). Am J Ind Med.1996; 29 (6):602–608. doi:10.1002/(sici)1097-0274(199606)29:6<602:aid-ajim4>3.0.co;2-l
10. Al-Qattan MM, Al-Namla A, Al-Thunayan A, Al-Omawi M. Tuberculosis of the hand. J Hand Surg Am. 2011;36(8):1413–21. doi:10.1016/j.jhsa.2011.05.036. quiz 1422.
11. Bayram S, Ersen A, Altan M, Durmaz H. Tuberculosis tenosynovitis with multiple rice bodies of the flexor tendons in the wrist: A case report. Int J Surg Case Rep. 2016;27:129–32. doi:10.1016/j.ijscr.2016.08.021.
12. Sbai MA, Benzarti S, Bouzaidi K, Sbei F. Maalla R.A rare localization of tuberculosis of the wrist: The scapholunate joint. Int J Mycobacteriol. 2015;4(2):161–4. doi:10.1016/j.ijmyco.2015.04.001.
13. 10.7759/cureus.6203
    Sivasamy P, Bajuri MY, Ghani AW. Tuberculosis of the Left Wrist Joint and Spine. Cureus.2019;11 (11):e6203. doi:10.7759/cureus.6203.
14. Chen PY, Qiu LY, Wang YJ, Shi NC, Xu J. [Imaging diagnosis of synovial tuberculosis of sheath of wrist]. Zhongguo Gu Shang. 2010;23(5):373–5.
15. Teo SC, George J, Kamarul T. Tubercular synovitis mimicking rheumatoid nodules. Med J Malaysia. 2008;63(2):159–61.
16. Luke W, Gunathilake M, Munidasa D, Munidasa D, De Silva ST. Tuberculous monoarthritis of the wrist in a patient with systemic lupus erythematosus: a case report. BMC Res Notes. 2017;10(1):343. doi:10.1186/s13104-017-2629-2.
17. Hsu CY, Lu HC, Shih TT. Tuberculous infection of the wrist: MRI features. AJR Am J Roentgenol. 2004;183(3):623–8. doi:10.2214/ajr.183.3.1830623.
18. Sawlani V, Chandra T, Mishra RN, Aggarwal A, Jain UK, Gujral RB. MRI features of tuberculosis of peripheral joints. Clin Radiol. 2003;58(10):755–62. doi:10.1016/s0009-9260(03)00271-x.
19. Prakash J, Mehtani A. Hand and wrist tuberculosis in paediatric patients - our experience in 44 patients. J Pediatr Orthop B. 2017;26(3):250–60. doi:10.1097/bpb.0000000000000325.

20. Bajuri MY.Chronic Osteomyelitis of the Femur with Segmental Bone Defect: Concepts and Treatment. Journal of Krishna Institute of Medical Sciences University.2017;6 (2).
21. Prakash J, Mehtani A. Isolated tuberculosis of scaphoid in the skeletally immature: a rare cause of chronic wrist pain. BMJ Case Rep. 2015. doi:10.1136/bcr-2015-209569.
22. Zha BS, Nahid P. Treatment of Drug-Susceptible Tuberculosis. Clin Chest Med. 2019;40(4):763–74. doi:10.1016/j.ccm.2019.07.006.
23. Zhu M, Li K, Zhu Y, Zhang J, Ye X. 3D-printed hierarchical scaffold for localized isoniazid/rifampin drug delivery and osteoarticular tuberculosis therapy. Acta Biomater. 2015;16:145–55. doi:10.1016/j.actbio.2015.01.034.
24. Eschweiler J, Allmendinger F, Stromps JP, Nick HE, Pallua N, Radermacher K. [Biomechanical modelling of the wrist joint]. Z Orthop Unfall. 2014;152(2):161–9. doi:10.1055/s-0034-1368246.

Figures

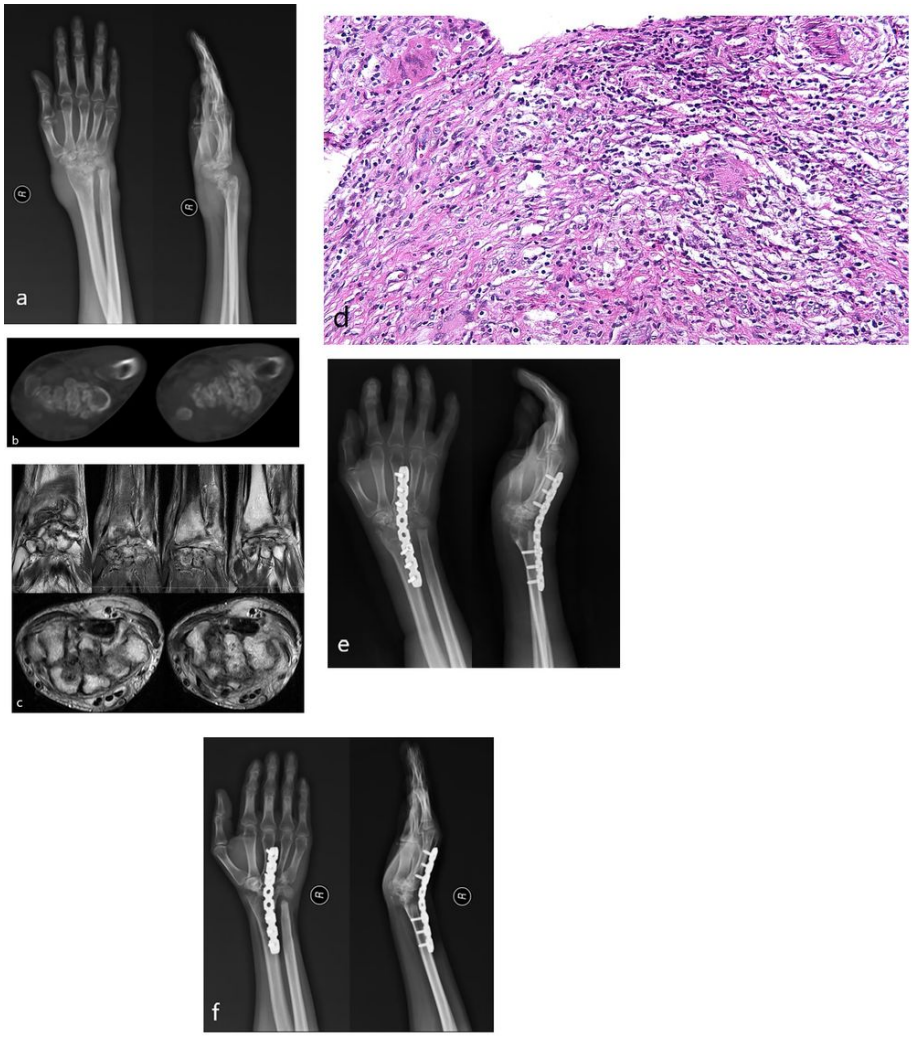

Figure 1

aConventional radiography anterior posterior and lateral viewpre-operation, bCT scanpre-operation, cPre-operative MR images, d The biopsypre-operation e X-ray scan one month post-operation, fX-ray scan 48 months post-operation)

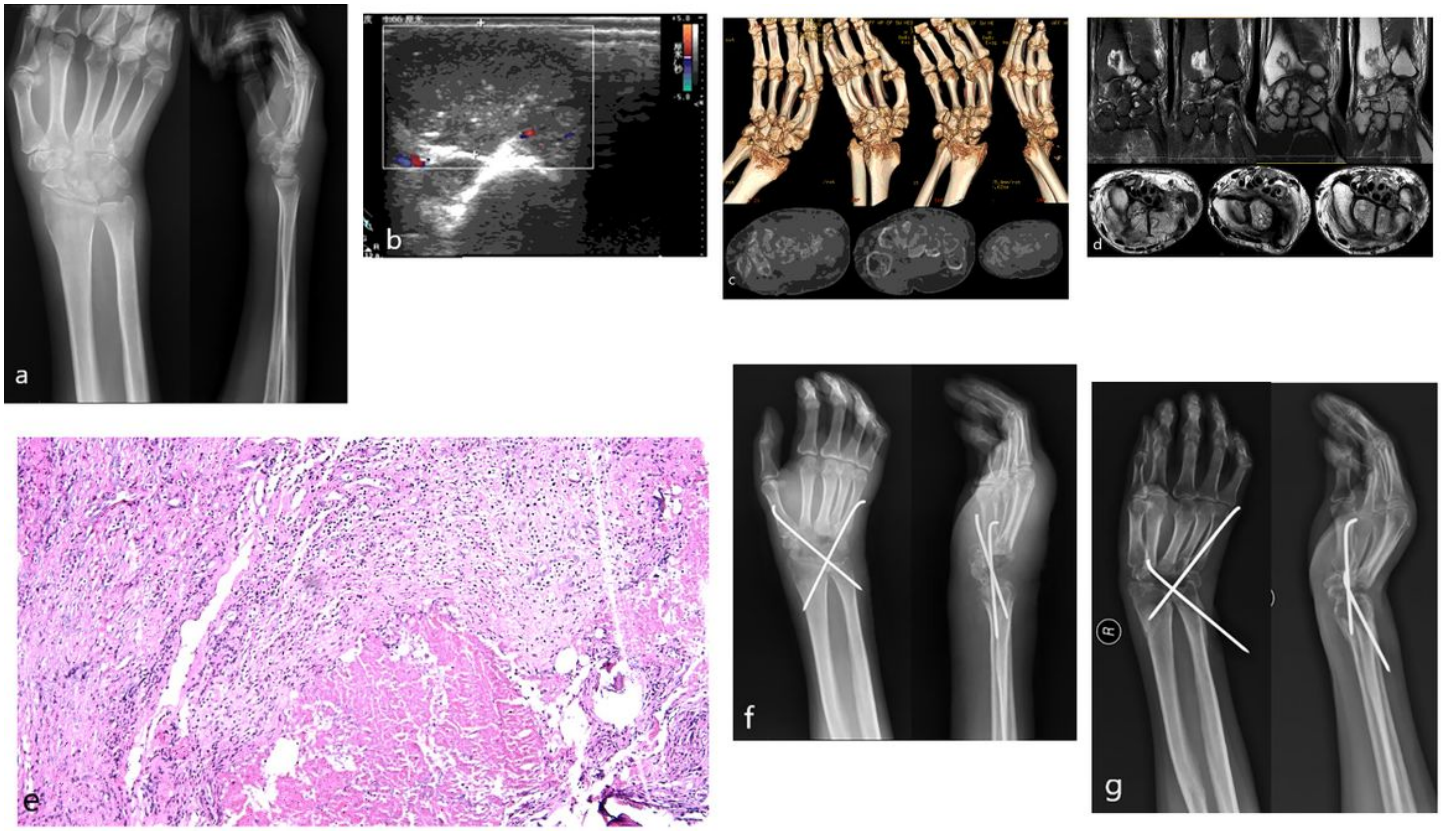

Figure 2

aConventional radiography anterior posterior and lateral viewpre-operation, b The CDFI of the wrist pre-operation, cCT scan pre-operation, dPre-operative MR images, eThe biopsy pre-operation, f X-ray scan one month post-operation, g X-ray scan eight months post-operation)

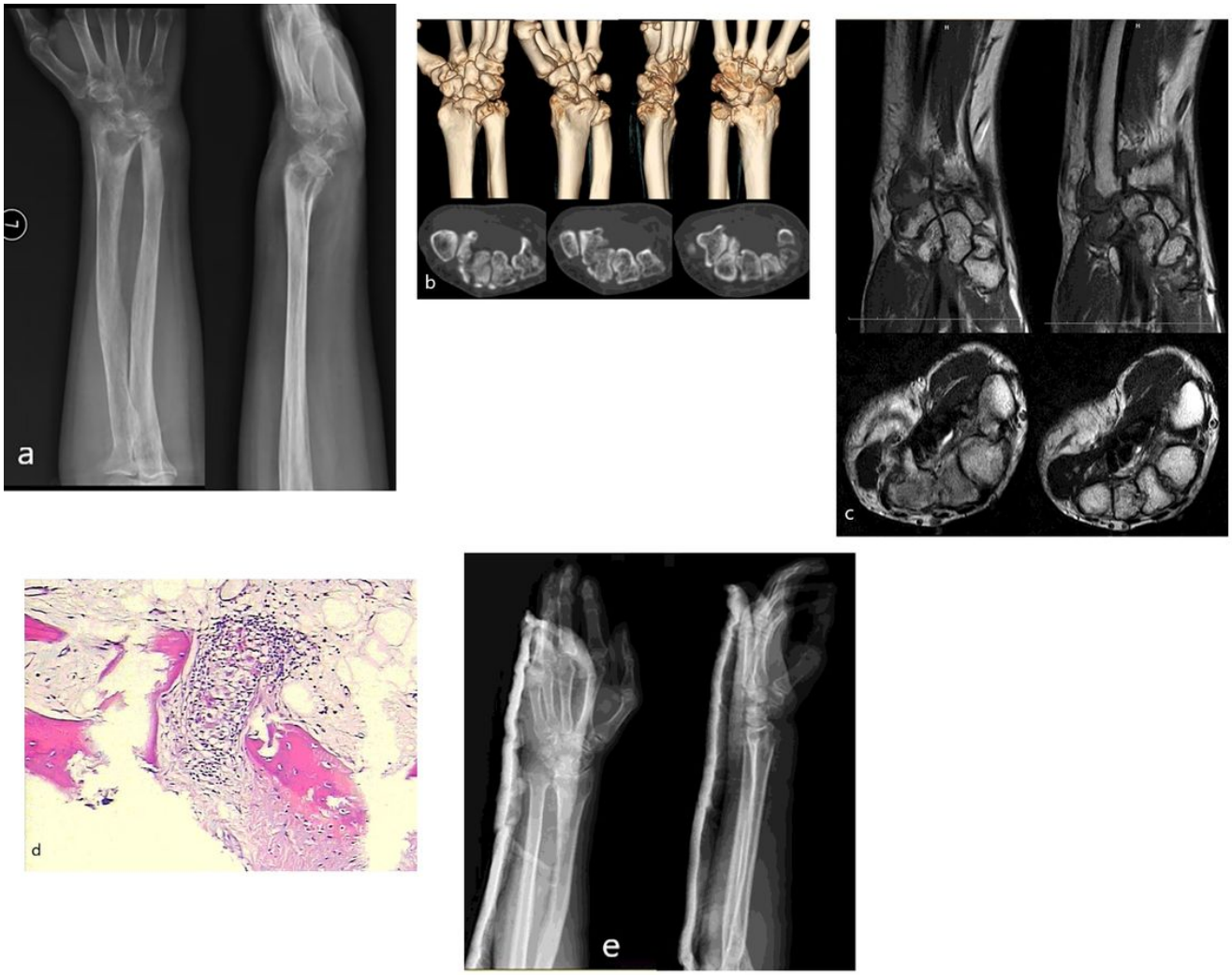

Figure 3

aConventional radiography anterior posterior and lateral viewpre-operation, bCT scan pre-operation, cPre-operative MR images, dThe biopsy pre-operation, e X-ray scan immediately after surgery)