TAE Combined with Microwave Ablation in the Treatment of Rare Giant Hepatic Hemangioma:Case Report and Literature Review

Yi-fu Feng
Taizhou University
Xin-yi Chen
Taizhou University
Jing-gang Mo
Taizhou University
Hai-ling Wu
Taizhou University
Jian-yu Zhou
Taizhou University
Chong Jin
Taizhou University
Hao Jiang
Taizhou University
Wang Kun-Peng (wangkp9644@tzzxyy.com)
https://orcid.org/0000-0001-5088-2548

Case report

Keywords: giant hepatic hemangioma, TAE, microwave ablation, case report

Posted Date: July 20th, 2020

DOI: https://doi.org/10.21203/rs.3.rs-42707/v1

Abstract

Background: hepatic hemangioma is the most common benign tumor of the liver. However, patients with large hemangiomas that cause compression symptoms or that are at risk of rupture may need further intervention. It is necessary to explore additional minimally invasive and personalized treatment options.

Case presentation: A 47-year-old female was diagnosed with right hepatic hemangioma for more than 10 years. Abdominal contrast-enhanced CT and CEUS revealed that there was a large hemangioma in the right liver, with a size of approximately 95x97x117 mm. Due to the patient's refusal of surgical treatment, hepatic artery embolization was performed in the first stage, then after 25 days of liver protection treatment, the liver function indexes decreased to normal levels. Then, B-ultrasound-guided microwave ablation of the giant hepatic hemangioma was performed. Ten days after the surgery, hepatobiliary ultrasonography showed that the hemangioma of the right liver was smaller than the previous size (the volume was reduced by approximately 30%). Then the patient was discharged from the hospital, and CT suggested that the hepatic hemangioma is significantly smaller two months after discharge. Because of COVID-19, the patient's CT examination was delayed.

Conclusions: TAE combined with microwave ablation is a safe and effective minimally invasive treatment for hepatic hemangioma.

Backgroud

Hepatic hemangioma is the most common benign tumor of the liver[1], which usually only needs regular reexamination, but surgical intervention is usually required when its diameter becomes larger or causes symptoms[2]. With the deepening of the concept of minimally invasive and rapid rehabilitation, exploring the minimally invasive treatment of hepatic hemangioma is a hot topic. In recent years, there have been many studies on interventional therapy[3]and ablation of hepatic hemangioma[4]. However, the safety and effect of interventional therapy and ablation on hepatic hemangioma need to be confirmed by further study[5]. Previous studies mostly focused on comparing the safety and effectiveness of simple interventional therapy or simple ablation and surgical treatment, and they are limited to hepatic hemangiomas with a diameter less than 5cm[6]. In fact, interventional therapy combined with ablation may be more effective than single interventional therapy or single ablation therapy[7].

However, there are no reports of Transcatheter arterial embolization (TAE) combined with microwave ablation in the treatment of hepatic hemangiomas larger than 10 cm in diameter. Here, we report a case of hepatic hemangioma with diameter 10 cm treated successfully by TAE combined with microwave ablation. We further summarize the literature and our successful experience in order to provide new ideas for minimally invasive and personalized treatment options for hepatic hemangioma.

Case Presentation

A 47-year-old woman complained that the physical examination found hemangioma for more than 10 years, had a history of caesarean section and unilateral salpingectomy and had failed interventional hepatic artery embolization at local hospital. CT examination with an abdominal contrast-enhanced CT showed the following: the right lobe of the liver had a low-density mass with a size of approximately 95 × 97 × 117 mm, the boundary was clear, the density was uniform, suggested a right hepatic hemangioma, (Fig. 1). Ultrasound angiography showed that the right posterior hepatic lobe displayed a strong echogenic area with a size of 95 × 97 × 117 mm, and the boundary was still clear. A total of 2.4 ml of sulfur hexafluoride microbubble solution was injected through the anterior elbow vein, showing a small amount of enhancement around the arterial phase in the strong echo zone. During this period, the contrast agent was significantly filled. Contrast-enhanced ultrasound showed right hepatic posterior hemangiomas (Fig. 2).

However, the patient refused surgical treatment., the patient was strongly encouraged to undergo microwave ablation due to the consideration of large local lesions as well as to protect the surrounding important blood vessels, to ensure the scope of ablation, to reduce intraoperative bleeding caused by puncture and ablation. The detailed plan according to the location and size of the lesion was as follows: one-stage hepatic artery interventional embolization, followed by short-term B-ultrasound-guided microwave ablation of hepatic giant hemangioma.

Intraoperatively, the patient was placed in the supine position and covered with a perineal routine disinfection drape. Right groin local anesthesia (2% lidocaine) was administered. The femoral artery was punctured, followed by placement of a sheath and an intrathecal heparin water-sealed tube, and then intrathecal 5-Fr angiography was performed. A catheter was inserted for celiac artery angiography, which showed that the hepatic artery was significantly thickened and tortuous, and a large mass-like abnormal staining area was seen in the right liver (Fig. 3A, B). Microcatheters and micro-guidewires were introduced into the right hepatic artery from the contrast catheter, and the micro-guidewire was withdrawn. Then, 10 mg dexamethasone and 8 mg ondansetron were perfused, and the microcatheter and micro-guidewire were superselected to the right lobe of the liver. In the small branch, angiography was performed to determine the supply of the blood vessels. Under fluoroscopy, the microcatheter was injected slowly with 20 ml iodized oil + 15,000 units bleomycin + a small amount of contrast medium mixture, and then a small amount of gelatin sponge was injected into the blood vessels in the main supply vessels. There was mild reflux, and angiography showed that the abnormal staining area of the liver had disappeared (Fig. 3C). The patient had no obvious discomfort, and the catheter was withdrawn. The sheath was removed after surgery, the puncture site was pressure-bandaged, the sandbag was pressed to stop the bleeding, and the patient was placed in a supine position for 24 hours. The side was continuously pressed for 8 hours. In terms of the postoperative monitoring of vital signs, there were no complaints of discomfort, no transient fever, and a maximum body temperature of 38 °C; routine blood tests showed a white blood cell count of 13.3 × 10 ^ 9 / L, 87.4% central granulocytes, and increased liver function indicators (ALT 105 U / L, AST 74 U /L, r-GT 74 U/L). Postoperative prophylactic antibiotics and liver protection treatment were administered. Two days later, routine blood examination showed that the white

blood cell levels decreased to normal, and the liver function indicators were normal (ALT 105 U/L, AST 74 U/L, r-GT 76 U/L), so liver protection treatment was continued.

After 25 days, the liver function index decreased (ALT 61 U/L, AST 24 U/L, r-GT 164 U/L), and B-ultrasound-guided microwave ablation of hepatic hemangioma was carried out. The patient was placed in a supine position, general anesthesia was administered, and routine surgery and disinfection of the surgical field were carried out; for ultrasonic positioning, an 11-point blade with a 2 mm small mouth was positioned on the skin, avoiding color Doppler blood flow, and two 15 G needles were punctured into the right posterior hepatic lobe for real-time ultrasound-guided microwave ablation. The following procedures were used for the lesions: N1: Right lower hepatic lobe lesion in the lower front, energy: 55 Wx600 s; N2: Right posterior hepatic lobe lesion in the posterior segment, energy: 55 Wx600 s (Fig. 4A) ; N3: Right hepatic posterior lobe lesion in the middle front, energy: 55 Wx600 s; N4: Right posterior lobe lesion in the middle of the posterior region, energy: 55 Wx600 s (Fig. 4B); and N5: in the upper segment of the right posterior hepatic lobe, energy: 55 Wx600 s. The double needle (N1N2, N3N4) had a total length of 1200s, and the single needle (N5) had a total length of 600 s. The dynamic observation of the mass area was covered by a strong echo (Fig. 4C), and the double needle was resected into a single needle. Postoperative monitoring of vital signs was normal. Preoperative prophylactic antibiotics and postoperative liver protection treatment were administered.

Hepatobiliary ultrasonography 10 days after the operation showed that the posterior lobe of the right liver had a strong echo region with a size of 71 × 66 × 58 mm and a relatively clear boundary, and the hemangioma in the right liver decreased in size compared with the previous size (approximately 30% smaller in volume) (Fig. 5A), Then the patient was discharged from the hospital, CT 2 months after discharge showed a right lamellar hepatic mass with a high-density shadow after microwave ablation of the hepatic hemangioma (Fig. 5B). Because of COVID-19, the patient's CT re-examination was delayed.

Discussion

The incidence of hepatic hemangioma is 0.4%~20.0%[8], and the autopsy discovery rate is 0.4%~7.3%[9].Hepatic hemangioma mostly grows slowly and has no tendency to become malignant; additionally, spontaneous rupture is rare. Some scholars abroad have classified large hemangiomas as those > 5 cm in diameter. Most hepatic hemangiomas do not require treatment or only need regular follow-up. However, giant hemangiomas larger than 5 cm in diameter may cause compression symptoms, such as obstructive jaundice, gastric outlet obstruction, and Budd-Chiari syndrome, or coagulopathy (Kasabach-Merritt syndrome) requiring further intervention[10]. The current treatments include surgery, interventional therapy[3], radiofrequency and microwave ablation[4].

TAE is a common method used for the treatment of hepatic hemangioma. Most of the larger hepatic hemangiomas requiring clinical treatment have a multi-arterial blood supply. Some arteries that are a part of this blood supply are not easily found during angiography, and collateral circulation easily forms after embolization of these artery, resulting in recurrence of hepatic hemangioma. If the tumor is over-

embedded, it may cause serious complications such as abnormal liver function, intrahepatic bile duct injury or ectopic embolism. Therefore, TAE is often used as an adjunct therapy or alternative[3]. For large (5–10 cm), symptomatic hepatic hemangiomas the safety and effect of microwave ablation have not been fully confirmed[5]. The patient had previously undergone TAE treatment for hepatic hemangioma, but the effect was dissatisfied. The hepatic hemangioma was more than 10 cm in size, and the surgical trauma was substantial. Simple TAE or microwave and radiofrequency treatments may not meet the treatment needs.

Microwaves have a higher thermal efficiency than radiofrequency ablation [11].This is mainly due to the different ways in which microwaves and radiofrequencies interact with tissues. The heat-generating component of radiofrequency ablation is mainly located within a few millimeters around the electrode and is susceptible to tissue carbonization. The expansion of the solidification range mainly depends on conduction heat dissipation, while microwaves have a certain penetrating power in the tissue, their heating range is large, and they are subject to the impact of carbonization, which is small. Since microwaves have a higher tissue solidification temperature than radiofrequencies, they have a strong coagulation ability in blood vessels, and their coagulation volume and shape are less affected by blood vessels; thus, microwave ablation has a larger ablation range, more easily resulting in intratumor ablation. The sufficiently high temperature for ensuring a large ablation range through heat transfer reflects the higher thermal efficiency of microwave ablation. The volume of microwave ablation is larger than that of radiofrequency ablation, which can reduce the number of punctures and the incidence of complications. For tumors with a diameter ≥ 5 cm, microwave ablation can be combined with multiple needles to significantly expand the ablation volume. Therefore, for large tumors, microwave ablation is more advantageous than radiofrequency ablation.[12] Microwave ablation is also less affected by blood perfusion. It is more suitable for treating tumors adjacent to large blood vessels. Multiple needles do not interfere with each other at the same time during ablation, and they have a synergistic effect, thereby making the ablation range larger and the ablation time shorter[13].

We decided to adopt microwave ablation combined with TAE treatment. The safety and efficacy of microwave ablation combined with TAE treatment is better than those of ablation alone[14]. The reasons are as follows: (1) TAE can effectively reduce the blood supply in the tumor by embolizing the blood vessels of the hemangioma, which can reduce the heat taken away by the "heat sedimentation effect" caused by the rich blood flow during the ablation process, resulting in a large microwave ablation treatment efficiency; (2) after TAE blocks the artery supplying the hemangioma, it can effectively reduce the risk of intraoperative bleeding; and (3) the application of iodized oil to the tumor in the TAE procedure can further define the hemangioma boundary and accurately locate it to avoid damage to the surrounding organs[15]. Of course, the optimal interval and the choice of vascular sealing materials during TAE treatment require further research and demonstration.

The main complications of ablation are hemorrhage, important organ puncture injuries, and organ thermal injuries, such as pleura, diaphragm, and lung injuries. Hemolysis-related complications, such as

anemia, jaundice, hemoglobinuria and temporary kidney injury, and even severe cases, lead to acute renal failure[16]. To reduce the risk of ablation and puncture, we believe that the puncture process should pass through more normal liver tissue as much as possible to reduce the risk of bleeding; furthermore, precise needle insertion, avoidance of repeated puncture, and utilizing the safety distance from “high-risk organs” when placing needles should be implemented. To avoid thermal damage, the needle should be ablated to prevent bleeding when withdrawing the needle; to avoid the excessive volume of single ablation, adequate rehydration should be administered during the perioperative period, especially during surgery, and if necessary, alkalinized urine should be implemented to avoid acute kidney injury or even renal failure. Complete ablation of the tumor should not be excessively pursued in order to avoid causing excessive side damage; if necessary, the tumor can be ablated once the puncture causes bleeding. Feasible local ablation of the tumor can be carried out while considering conservative treatment, including hepatic artery embolization and surgical hemostasis.

Conclusions

After slight treatment with TAE combined with ablation, the hemangioma was mostly necrotic, and the volume was significantly reduced; at the very least, the tumor will not continue to grow rapidly and affect liver function, in line with the therapeutic purposes and concepts of benign liver tumors. TAE combined with microwave ablation is a safe and effective minimally invasive treatment for hepatic hemangioma.

Abbreviations

CT
Computed tomography; ALT:Alanine aminotransferase; AST:Aspartate aminotransferase; r-GT:r-glutamyl transpeptidase; TAE:Transcatheter arterial embolization.

Declarations

Ethics approval and consent to participate

The study protocols were approved by the Ethical Committee of the Taizhou Central Hospital.

Consent for publication

Written informed consent was obtained from the patient for publication of this article. A copy of the written consent is available for review by the Editor of this journal.

Availability of data and materials

The datasets used and/or analysed during the current study are available from the corresponding author on reasonable request.

Competing interests

The authors declare that they have no competing interests.

Funding

Zhejiang Medical and Health Science and Technology Program, No.2017KY711 (publishing fee); Project of Taizhou University, No.2018PY057 (image processing); Project of Taizhou Central Hospital, No.2019KT003 (English editing)

Authors' contributions

YFF and KPW designed this study and wrote the manuscript; XYC and JGM, collected the patient ’s clinical date; JGM , HLW and HJ carried out the TAE treatment; XYC , JYZ and CJ carried out the microwave ablation ; KPW and XYC revised the manuscript; All authors read and approved the final manuscript.

Acknowledgements

We are very grateful to our colleagues from the Department of Pathology for providing the pathological pictures.

References

[1] Eghlimi H, Arasteh P, Azade N. Orthotopic liver transplantation for Management of a Giant Liver Hemangioma: a case report and review of literature[J]. BMC Surg, 2020,20(1):142.

[2] Zhong L, Men TY, Yang GD, et al. Case report: living donor liver transplantation for giant hepatic hemangioma using a right lobe graft without the middle hepatic vein[J]. World J Surg Oncol, 2014,12:83.

[3] Furumaya A, van Rosmalen BV, Takkenberg RB, et al. Transarterial (Chemo-) Embolization and Lipiodolization for Hepatic Haemangioma[J]. Cardiovasc Intervent Radiol, 2019,42(6):800-811.

[4] Wang Z, Tang X, Qi X, et al. Feasibility, safety, and efficacy of ultrasound-guided percutaneous microwave ablation for giant hepatic hemangioma[J]. Int J Hyperthermia, 2018,35(1):246-252.

[5] Tang X, Ding M, Lu B, et al. Outcomes of ultrasound-guided percutaneous microwave ablation versus surgical resection for symptomatic large hepatic hemangiomas[J]. Int J Hyperthermia, 2019,36(1):632-639.

[6] Takaki H, Yamakado K, Uraki J, et al. Radiofrequency ablation combined with chemoembolization for the treatment of hepatocellular carcinomas larger than 5 cm[J]. J Vasc Interv Radiol, 2009,20(2):217-224.

[7] Kang S G, Yoon CJ, Jeong SH, et al. Single-session combined therapy with chemoembolization and radiofrequency ablation in hepatocellular carcinoma less than or equal to 5 cm: a preliminary study[J]. J Vasc Interv Radiol, 2009,20(12):1570-1577.

[8] EASL Clinical Practice Guidelines on the management of benign liver tumours[J]. J Hepatol, 2016,65(2):386-398.

[9] Toro A, Mahfouz AE, Ardiri A, et al. What is changing in indications and treatment of hepatic hemangiomas. A review[J]. Ann Hepatol, 2014,13(4):327-339.

[10] Hasan H Y, Hinshaw JL, Borman EJ, et al. Assessing normal growth of hepatic hemangiomas during long-term follow-up[J]. JAMA Surg, 2014,149(12):1266-1271.

[11] Kamal A, Elmoety A, Rostom Y, et al. Percutaneous radiofrequency versus microwave ablation for management of hepatocellular carcinoma: a randomized controlled trial[J]. J Gastrointest Oncol, 2019,10(3):562-571.

[12] Facciorusso A, Di Maso M, Muscatiello N. Microwave ablation versus radiofrequency ablation for the treatment of hepatocellular carcinoma: A systematic review and meta-analysis[J]. Int J Hyperthermia, 2016,32(3):339-344.

[13] Vietti V N, Duran R, Guiu B, et al. Efficacy of microwave ablation versus radiofrequency ablation for the treatment of hepatocellular carcinoma in patients with chronic liver disease: a randomised controlled phase 2 trial[J]. Lancet Gastroenterol Hepatol, 2018,3(5):317-325.

[14] Thornton LM, Cabrera R, Kapp M, et al. Radiofrequency vs Microwave Ablation After Neoadjuvant Transarterial Bland and Drug-Eluting Microsphere Chembolization for the Treatment of Hepatocellular Carcinoma[J]. Curr Probl Diagn Radiol, 2017,46(6):402-409.

[15] Saraswat VA, Pandey G, Shetty S. Treatment algorithms for managing hepatocellular carcinoma[J]. J Clin Exp Hepatol, 2014,4(Suppl 3):S80-S89.

[16] van Tilborg A, Dresselaars HF, Scheffer HJ, et al. RF Ablation of Giant Hemangiomas Inducing Acute Renal Failure: A Report of Two Cases[J]. Cardiovasc Intervent Radiol, 2016,39(11):1644-1648.

Figures

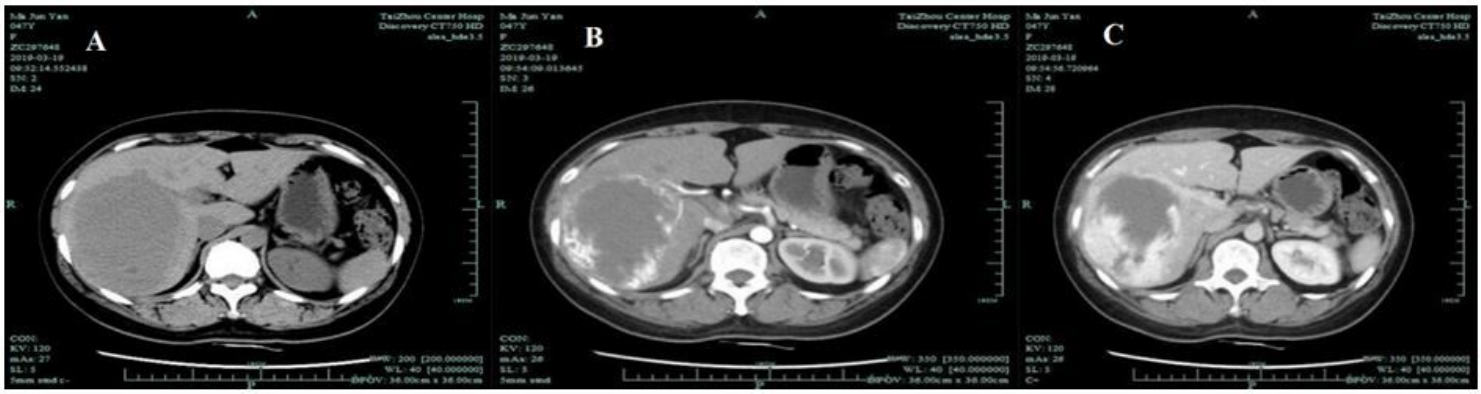

Figure 1

CT suggested a right hepatic hemangioma, 1A: Plain, 1B arterial phase, 1C : venous phase.

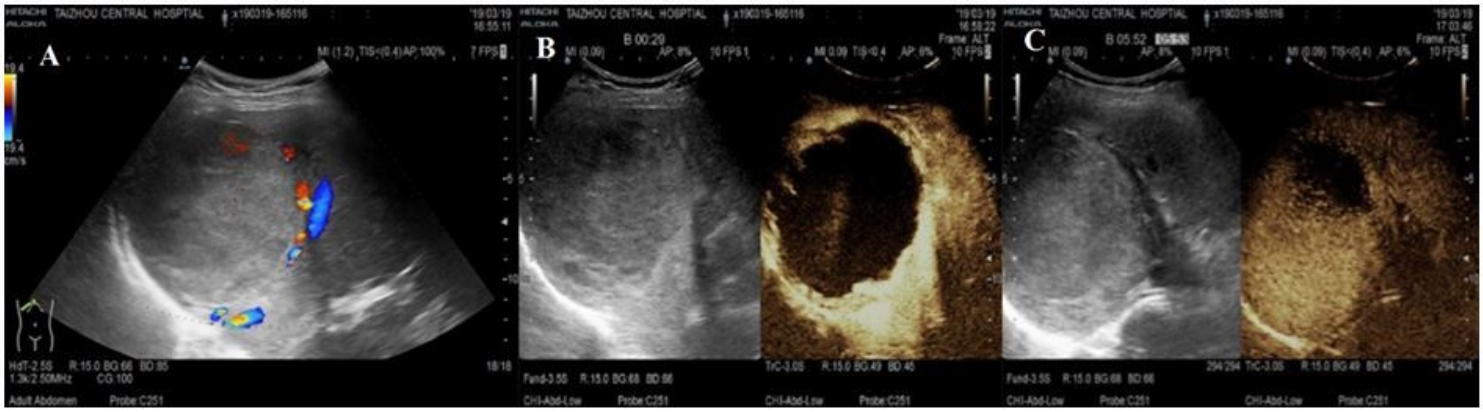

Figure 2

Ultrasound angiography showed that the right posterior hepatic lobe displayed a strong echogenic area with a size of 95x97x117 mm.

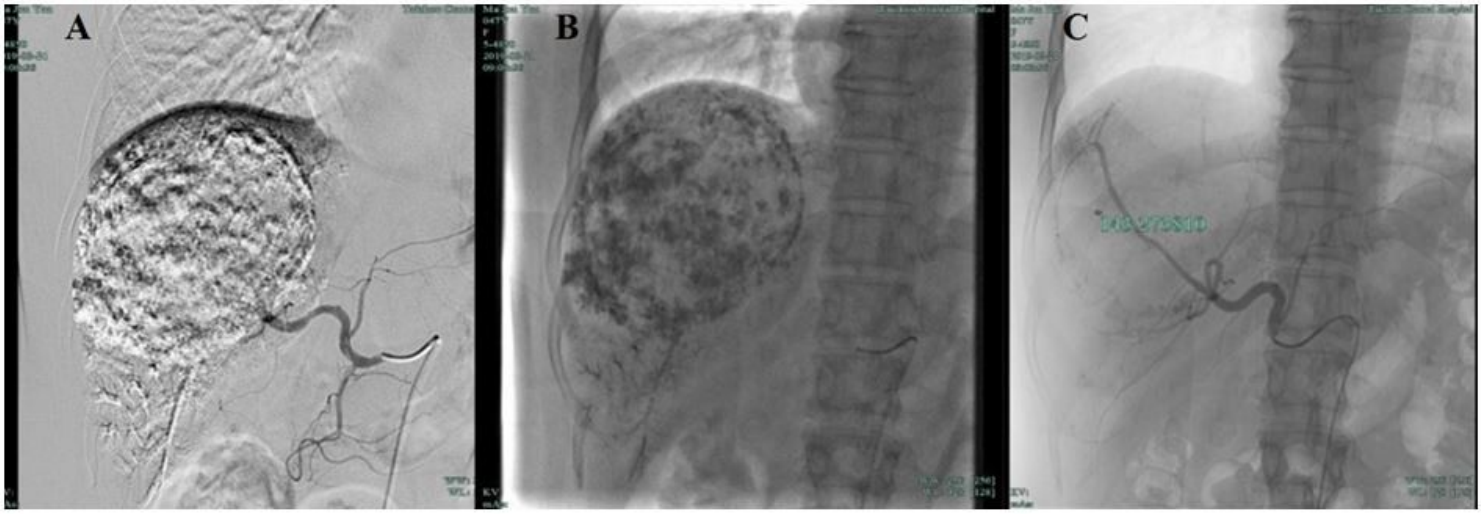

Figure 3

A and B: large abnormal staining area in the right liver, C: abnormal staining area disappeared.

Figure 4

Partial images of radiofrequency ablation guided by B-ultrasound.

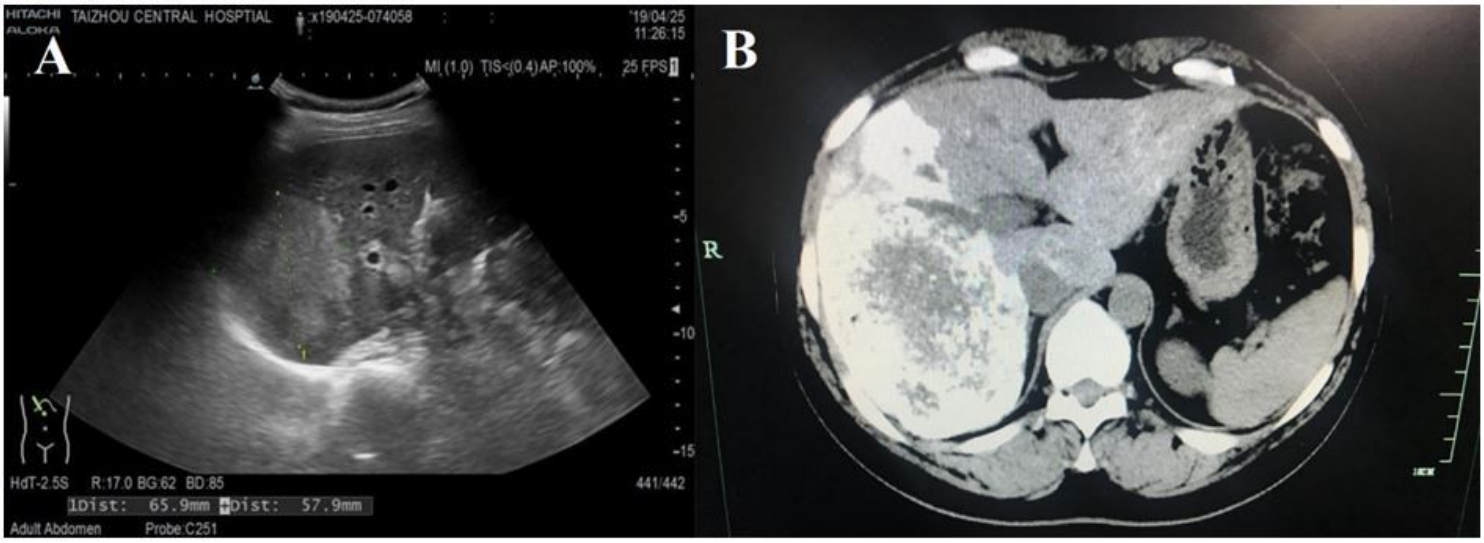

Figure 5

Results of B-ultrasound and CT reexamination after operation.