How Can Patient-Reported Outcomes of Periacetabular Osteotomy be Improved? A Short-Term Follow-up of 79 Hips.

YiNuo Fan
Guangzhou University of Chinese Medicine
Weifeng Li
Guangzhou University of Chinese Medicine
Yunlong Wu
Guangzhou University of Chinese Medicine
Guoju Hong
the University of Alberta
Zhongfeng Li
Guangzhou University of Chinese Medicine
Lixin Chen
Guangzhou University of Chinese Medicine
Hanjun Fang
The First Affiliated Hospital of Guangzhou University of Chinese Medicine
Chi Zhou
The First Affiliated Hospital of Guangzhou University of Chinese Medicine
Zhenqiu Chen (chenzq2019@126.com)
The First Affiliated Hospital of Guangzhou University of Chinese Medicine

---

Research Article

Keywords: Bernese periacetabular osteotomy, Patient-reported outcomes, Multivariate logistic regression analysis, Receiver operating characteristic curve

Posted Date: April 21st, 2021

DOI: https://doi.org/10.21203/rs.3.rs-428249/v1

Abstract

Background

Bernese periacetabular osteotomy (PAO) is an effective treatment for patients with developmental dysplasia of the hip (DDH). PAO has been widely used in China, but few follow-up outcomes have been reported in the international community. Moreover, the risk factors affecting patient-reported outcomes have not been discussed in recent studies. In this study, patient-reported outcomes after PAO were reported, and risk factors affecting patient-reported outcomes were analyzed.

Methods

Patients who underwent PAO for DDH from January 2014 to January 2020 were selected as the study subjects, and 79 hips were included in the analysis after screening (71 patients, with an average follow-up time of 2.98 years). The Harris Hip Score (HHS) and International Hip Outcome Instrument-12 (iHOT-12) were used to assess hip function and patient quality of life. A HHS < 80 was defined as symptomatic hips, that is, an adverse outcome; otherwise, it indicated preserved hips. Multivariate logistic regression analysis was used to predict the risk factors influencing the patient-reported outcomes, and receiver operating characteristic (ROC) curve analysis was performed on the risk factors to determine their sensitivity, specificity and cutoff value.

Results

Clinical outcome analysis demonstrates marked improvements in patient-reported outcomes. The multivariate logistic regression analysis showed that when the postoperative LCEA was > 38°, adverse outcomes were much more likely. However, a Tönnis angle of -10°-0 was a protective factor. In addition, hips with fair or poor joint congruency were 7.794-fold more likely to develop negative outcomes. The ROC curve analysis showed that the optimal thresholds for the LCEA and Tönnis angles used to predict outcomes after PAO were 38.1° and – 9°, respectively. The patients with a postoperative LCEA < 38.1° had a success rate of 83%. In contrast, the success rate was 32% for patients with a postoperative LCEA > 38.1°. In addition, while the patients with a postoperative Tönnis angle of -9°-0 had a success rate of 70%, and those with a Tönnis angle of 0–10° had a success rate of 65%; the success rate of a Tönnis angle <-9° was only 10%.

Conclusions

Our results demonstrate marked improvements in patient-reported outcomes. Among hips with preoperative excellent or good joint congruency treated by experienced surgeons who obtain the proper postoperative LCEA and Tönnis angles, good patient-reported outcomes can be expected.

Introduction

Developmental dysplasia of the hip (DDH) refers to inadequate coverage of the femoral head by the acetabulum due to abnormal structural development of the hip, which leads to subluxation or complete dislocation of the hip(1, 2). It has been reported that the disease has a high prevalence in Asia and the United States, with 1-1.5 DDH children affected per 1000 newborns(3). The disease is characterized by hidden onset and slow early progression, then accelerated progression when the disease reaches a certain stage, leading to advanced secondary osteoarthritis and, ultimately, a total hip replacement (THR) (4). Among THR recipients, DDH patients account for approximately 20% ~ 40%, ranking second in among those with THR(5). The age of onset of DDH symptoms is 20–40 years old. If THR is administered immediately after symptom onset, then DDH patients may face revision and other problems in the many decades after the operation, which can seriously affect the health of the patient(6). THR is not an ideal choice for young patients and patients whose expected survival time is several times longer than the prosthesis life span. However, early hip preservation surgery and correction of abnormal hip morphology can relieve pain symptoms, delay the progression of osteoarthritis, and delay or even prevent the need for a THR.

Periacetabular osteotomy (PAO), first used by Ganzs, is one of the most commonly used hip-conserving surgeries for DDH(7). PAO not only corrects the lateral, anterior coverage, forward and backward tilt, and inward and outward displacement of the acetabulum but also ensures continuity of the posterior column of the pelvis and provides satisfactory correction of the acetabulum in DDH patients, thereby delaying hip osteoarthritis and THR, rendering it fully applicable to young patients(8).

This surgery has been widely used in many countries, and some follow-up results have confirmed the efficacy of PAO(9–21). China was one of the countries to adopt PAO early, but there are few follow-up studies on PAO, making current PAO studies important. In addition, we found that short-term follow-ups after PAO mostly addressed patient-reported outcomes with no discussion of risk factors affecting patient-reported outcomes(10, 12–15, 18, 19). Considering the current situation, this study retrospectively analyzed the data of DDH patients treated with PAO, observed the standard anteroposterior radiograph of the pelvis before and after PAO, and measured the lateral center-to-edge angle (LCEA), acetabular coverage ratio, sharp angle and Tönnis angle. Intensive follow-up was conducted from August to September 2020, and the quality of life of the patients was assessed through the Harris Hip Score (HHS) and International Hip Outcome Tool-12 (iHOT-12). The purpose of this study was to evaluate the short-term efficacy of PAO for DDH, analyze the risk factors affecting patient-reported outcomes, and propose measures to improve patient-reported outcomes.

Materials And Methods

General information

After approval by the Institutional Review Committee, patients who underwent PAO for DDH in the First Affiliated Hospital of Guangzhou University of Chinese Medicine from 2014 to January 2020 were selected as study subjects. The diagnosis of DDH was determined by highly qualified physicians through radiographic evidence and symptoms. The inclusion criteria were: (1) "Y" cartilage closure; (2) radiographic evaluation was lower than Tönnis grade 3; (3) younger than 55 years old; (4) complete follow-up data; (5) all DDH patients who met these criteria underwent PAO. The exclusion criteria were as follows: (1) isolated acetabular retroversion, neuromuscular or connective-tissue disorder, Legg-Calve-Perthes disease, or DDH combined with other diseases, such as Legg-Calve-Perthes disease or acetabular retroversion; (2) Tönnis grade 3 or other hip trauma; and (3) patients with no follow-up due to interrupted communication.

Preoperative and postoperative examination

Before PAO, the functional activity of the hip and quality of life of the patient were evaluated by HHS and iHOT-12, and a standard anteroposterior radiograph of the pelvis was routinely taken. After PAO, the HHS and iHOT-12 ratings were evaluated, and a standard anteroposterior radiograph of the pelvis was taken.

Outcome Measures

The HHS and iHOT-12 were used to evaluate the joint activity, pain, and quality of life in preoperative and postoperative patients with PAO. HHSs can be divided into four grades: excellent (≥90), good (80-89), fair (70-79), and poor (<70) and include measures of pain, function, joint movement, limb deformity, etc. In this study, adverse outcomes were defined through HHSs. According to previous studies(22, 23), a HHS < 80 is defined as symptomatic hips, that is, an adverse outcome; otherwise, the score indicates preserved hips. From August to September 2020, all included patients were administered a questionnaire.

The LCEA, acetabular coverage ratio, sharp angle and Tönnis angle were used to evaluate the radiographic correction degree during the PAO. LCEA, acetabular coverage ratio, sharp angle and Tönnis angle were measured by Digimizer software (version 5.4.6) before and after the PAO. DDH is generally believed to exist with an LCEA<20°(24, 25), acetabular coverage ratio < 75%(26), sharp angle>40°(27)and Tönnis angle>10°(28). In addition, according to previous studies(24, 25), the preoperative LCEA was graded as follows: LCEA<5°, 5°< LCEA<20°, and LCEA>20°. According to Wells et al.(21), a postoperative LCEA was graded as 20° < LCEA<38° and LCEA >38°. There is no uniform standard for the range of correction for the Tönnis angle after PAO. According to the experience of the surgeons involved with this study, the postoperative Tönnis angle was within the appropriate range at 0±10°. Therefore, we graded the postoperative Tönnis angle as 0 < Tönnis angle <10°, -10°< Tönnis angle <0 and Tönnis angle <-10°. All of these indicators were measured and observed by three authors, and the final results were averaged.

The Tönnis classification of hip osteoarthritis(29, 30) was divided into four grades: 0 (no signs of osteoarthritis), 1 (slight narrowing of the joint space, slight lipping at the joint margin, and slight sclerosis of the femoral head or acetabulum), 2 (small cysts in the femoral head or acetabulum, moderate narrowing of the joint space, and moderate loss of sphericity of the femoral head), and 3 (large cysts,

severe narrowing or obliteration of the joint space, severe deformity of the femoral head, and avascular necrosis). Joint congruency(31) was described by excellent (radii of curvature of the acetabulum and femoral head identical and joint space maintained), good (curvature of the femoral head and acetabulum not identical, but joint space preserved), fair (joint space partially narrowed), and poor (loss of joint space). Hips with excellent or good joint congruency were considered an acceptable outcome.

Statistical Analysis

Continuous variables are expressed as the means and standard deviations, and categorical variables are expressed as numbers and percentages. When preoperative and postoperative radiographic parameters and patient-reported outcomes were analyzed, a t-test was used when they conformed to a normal distribution; the Wilcoxon signed-rank test was used when they did not conform to a normal distribution. Multivariate logistic regression analysis was used to conduct statistical analysis on the included parameters to predict the risk factors influencing the outcome, and receiver operating characteristic (ROC) curve analysis was performed on the risk factors to determine their sensitivity, specificity and cutoff value. $P < 0.05$ was considered statistically significant, and all data were statistically analyzed with SPSS Software version 23.0 (IBM).

Results

A total of 71 patients (19 male and 52 female) were included in the analysis. The mean follow-up time was 2.98 ± 1.31 years. The mean age and BMI were 30.93 ± 11.14 years old (range, from 10 to 54 years old) and 21.10 ± 1.77, respectively (Table 1). In this group, the operative time was 1.40–6.75 h, and the average operative time was 2.99 h.

Table 1
Patient Characteristics

Characteristic*	
Number of patients *(hips)*	71 (79)
Age†(yr)	30.93 ± 11.14(10 ~ 54)
Females (*no. [%]*)	52(73.2%)
Time to latest follow-up*(yr)*	2.98 ± 1.31
Height‡*(m)*	1.58 ± 0.10
Weight‡*(kg)*	53.27 ± 8.98
BMI‡*(kg/m2)*	22.21 ± 1.73
*BMI = body mass index. †The values are given as the mean and the standard deviation, with the range in parentheses. ‡The values are given as the mean and the standard deviation.	

Patient-reported Outcomes

The changes in patient-reported outcomes were significantly different between the final follow-up and the preoperative results. The patients reported a mean improvement from a 60.90 ± 21.35 preoperatively to a 81.37 ± 7.45 at the last follow-up (P < 0.001) on the HHS scale and from 61.34 ± 26.10 to 87.00 ± 19.79 (p < 0.001) on the iHOT-12 scale (Table 2). In addition, the comparison between the HSS of the preserved hip group (86.02 ± 3.29) and the symptomatic hip group (74.06 ± 5.99) was statistically significant (P < 0.001). By comparing the follow-up times of the preserved hip group and those of the symptomatic hip group, we found that the difference was not statistically significant (Table 3), which indicated that the difference in the follow-up time between the two groups did not lead to bias in the HHS-based results.

Table 2
Patient-Reported Outcomes

Characteristic	Mean (SD)		P Value
	Preoperative	Postoperative	
HHS†	60.90 ± 21.35	81.37 ± 7.45	<0.001
iHOT-12*	61.34 ± 26.10	87.00 ± 19.79	<0.001
†Harris Hip Score. *International Hip Outcome Tool-12.			

Table 3
Patient-Reported Outcomes at Latest Follow-up

	Mean (SD)		P Value
	Preserved (n = 47 hips)	Symptomatic (n = 32 hips)	
HHS	86.28 ± 3.25	74.16 ± 5.80	<0.01
Time to the latest follow-up*(yr)**	3.16 ± 1.30	2.69 ± 1.23	0.113
*Time of Patient-Reported Outcomes obtained at the latest follow-up.			

Radiographic Parameters Outcomes

The preoperative distribution of Tönnis Classification of Hip Osteoarthritis was a Tönnis grade 0 of 10 hips, Tönnis grade 1 of 50 hips, and Tönnis grade 2 of 19 hips. In the latest postoperative follow-up, 2 hips advanced to Tönnis grade 1 from Tönnis grade 0, 5 hips advanced to Tönnis grade 2 from Tönnis grade 1, and 1 hip advanced to Tönnis grade 3 from Tönnis grade 2. The progression of 79 hips in terms of Tönnis grade is shown in Fig. 1.

After PAO, the hips were classified according to a HHS < 80, and a total of 47 preserved hips and 32 symptomatic hips were documented. The statistical results showed that 34 preserved and 7 symptomatic hips were in the LCEA range of 20°-38°, and 12 preserved and 25 symptomatic hips had an LCEA > 38° (p

< 0.001). After PAO, the 30 preserved and 16 symptomatic hips and the 17 preserved and 8 symptomatic hips had a Tönnis angle of -10°-0, and only 8 symptomatic hips had a Tönnis angle of <-10° (P < 0.001). There were 9 preserved hips and 22 symptomatic hips with poor or fair joint congruency before PAO (P < 0.001), while there were only 5 preserved hips and 11 symptomatic hips with poor or fair joint congruency after PAO (P = 0.01). The changes in the other radiographic parameters were not statistically significant (Table 4).

Table 4
Patient Characteristics of Cohort

Radiographic parameters	No.		P Value†
	Preserved (n = 47 hips)	Symptomatic (n = 32 hips)	
Preoperative radiographic parameters			
Acetabular coverage ratio < 75%	46	29	0.358
Sharp angle > 40°	44	31	0.900
LCEA			0.239
< 5°	16	9	
5°-20°	26	15	
> 20 °	5	8	
Tönnis angle > 10°	46	31	1.000
Joint congruency poor or fair	9	22	0.000
Postoperative radiographic parameters			
Acetabular coverage ratio > 75%	47	32	1.000
Sharp angle < 40°	40	31	0.186
LCEA			0.000
20°-38°	34	7	
> 38°	12	25	
Tönnis angle			0.001
0°-10°	30	16	
-10°-0°	17	8	
<-10°	0	8	
Joint congruency poor or fair	5	11	0.010
†Based on univariable comparisons between preserved and symptomatic hips.			

The radiographic parameters were greatly changed before and after PAO. The acetabular coverage ratio improved from 0.58 to 0.90 (P < 0.001), the sharp angle improved from 48.09 to 33.81 (P < 0.001), the

LCEA improved from 8.77 to 37.60 (P < 0.001), and the Tönnis angle improved from 22.71 to 0.60 (P < 0.001, Table 5).

Table 5
Radiographic Correction

Characteristic	Mean (SD)*		P Value†
	Preoperative	Postoperative	
Acetabular coverage ratio	0.58 ± 0.14	0.90 ± 0.08	<0.001
Sharp angle*(°)*	48.09 ± 4.93	33.81 ± 5.01	<0.001
LCEA*(°)*	8.77 ± 13.06	37.60 ± 8.46	<0.001
Tönnis angle*(°)*	22.71 ± 9.44	0.59 ± 7.02	<0.001

* The values are given as the mean and the standard deviation. †Based on univariable comparisons between Preoperative and Postoperative outcome.

Risk factors were predicted based on multivariate logistic regression analysis. This study included age, sex, BMI, preoperative and postoperative LCEA, acetabular coverage ratio, sharp angle, Tönnis angle and joint congruency in the risk factor analysis. The results showed that the LCEA, Tönnis angle and preoperative joint frequency had a significant influence on the outcome, and the remaining factors were not significantly different. When the postoperative LCEA was > 38°, the risk of an adverse outcome was 16.573-fold higher (odds ratio [OR]: 16.573; 95% CI: 2.912 to 94.323; P = 0.002; Table 6). However, a Tönnis angle of 10°-0 was a protective factor (odds ratio [OR]: 0.083; 95% CI: 0.012 to 0.554; P = 0.010). In addition, hips with fair or poor joint congruency were 7.794 times more likely to develop negative outcomes (odds ratio [OR]: 7.794; 95% CI: 1.909 to 31.816; P = 0.004).

Table 6
The Multinomial Logistics Regression Analysis

Variable	OR (95% CI)	P Value
Postoperative LCEA*		0.007
< 20°		1.000
> 38°	16.573(2.912–94.323)	0.002
Postoperative Tönnis angle†		0.037
<-10°		0.999
-10° -0°	0.083 (0.012–0.554)	0.010
Preoperative Joint congruency poor or fair	7.794 (1.909–31.816)	0.004

* The statistical results of < 20° and > 38° in Postoperative LCEA were compared with 20°-38°.†The statistical results of <-10°and − 10°-0 in Postoperative LCEA were compared with 0–10°.

The ROC analysis showed that the AUC of the postoperative LCEAs and Tönnis angles was 0.75 and 0.64 (Table 7), respectively. The multinomial logistic regression analysis demonstrated that the LCEA and Tönnis angle were good predictors of outcomes in patients with DDH, revealing that the patient-reported outcomes may be determined by the postoperative LCEAs and Tönnis angles. The optimal cutoff values revealed by the ROC analysis for the postoperative LCEAs and Tönnis angles were 38.1 and − 9, respectively (Fig. 2, Table 7). The cutoff for the LCEA had a specificity and sensitivity of 75% and 78%, respectively. The patients with a postoperative LCEA < 38.1 had a success rate of 83% (7 of 42). In contrast, the success rate was 32% (12 of 37) for patients with a postoperative LCEA > 38.1. In addition, while the patients with a postoperative Tönnis angle of -9°-0 had a success rate of 70% (16 of 23), and patients with a Tönnis angle of 0–10° had a success rate of 65% (30 of 40), the success rate of a Tönnis angle <-9° was only 10% (1 of 10).

Table 7
Prognostic Values of Postoperative Tönnis angle and LCEA

	Cutoff value	**AUC**	**Specificity/Sensitivity**	**No./Total (%)***
Tönnis angle	-9	0.64	98%/28%	
Success rate				
0–10°				30/46 (65%)
-9°-0				16/23 (70%)
<-9°				1/10 (10%)
LCEA	38.1	0.75	75%/78%	
Success rate				
<38.1°				35/42 (83%)
>38.1°				12/37 (32%)
** Preserved hips in the interval/All hips in the interval (%)*				

Discussion

DDH has a high incidence in China, with an incidence of 2.9% in Taiwan(32). If left untreated, joint wear gradually increases and eventually a THR is required(4). Therefore, hip preservation is a good choice for young patients with DDH. The purpose of hip preservation is to alleviate pain symptoms, slow the progression of osteoarthritis, and delay or even prevent the need for a THR by correcting the hip malformations. Compared with THR, PAO is an ideal choice for young people with symptomatic DDH(33, 34). Current follow-up results confirmed the efficacy of PAO(9–21). China was one of the countries to adopt PAO early, but there are few follow-up studies on PAO in the international community. Therefore, we

followed patients with DDH after PAO to observe the short-term efficacy of PAO and to predict the factors that affect patient-reported outcomes.

Our study was one of the largest short-term follow-up studies analyzing patient-reported outcomes after PAO performed to alleviate symptomatic DDH. We analyzed the factors that influenced patient-reported outcomes after PAO. In this retrospective study, we found that patients who underwent PAO in our study had good postoperative radiographic parameters and outcome improvement as indicated by patient reports. Additionally, the patients' progression of Tönnis grade was not obvious. Our data suggest that while hips with fair or poor joint congruency preoperatively and an oversized postoperative LCEA were correlated with unsatisfactory patient-reported outcomes, the proper postoperative Tönnis angle was a positive factor for good patient-reported outcomes. When the LCEA and Tönnis angle was 38.1° and − 9°, respectively, these are two critical values affected patient-reported outcomes.

In a study of 123 hips followed for a mean of 4.3 years after PAO, Trumble et al.(18) reported that 102 hips were preserved, 7 hips required a THR, and 6 subsequent intertrochanteric osteotomies were performed. The patients reported a mean improvement from 65 points preoperatively to 89 points at the latest follow-up, based on HHSs. The latest follow-up radiographic severity of osteoarthrosis, assessed according to Tönnis grade, progressed in only 6 hips. Although this study on PAO revealed good outcomes, only a simple follow-up was performed, and risk factors were not explored in depth. In another prospective, multicenter cohort of 391 hips followed for a mean of 2.6 years after PAO, Clohisy et al.(10) reported that age, sex and BMI were predictive factors of certain outcome measures. This study suggested that the strongest predictors of successful outcomes were female sex, increased age, and a high BMI. In addition, pain, hip function, and quality of life improved after PAO. In our study, 79 hips after PAO performed to alleviate DDH were followed for a mean of 2.98 years, and 32 hips were considered symptomatic. According to the Tönnis grade, DDH progressed in only 8 hip joints. This study showed that sex, age and BMI had no effect on the outcome measures, which may be related to it being a single-center study and including only a limited number of hips.

Wells et al.(20) and Matheney et al.(35) reported that poor or fair preoperative joint congruency is a risk factor for failure, which was consistent with our findings. Another study by Wells et al.(21) analyzed the outcomes of 154 hips followed for an average of 10.3 years and found that excessive postoperative femoral head coverage (LCEA > 38°) was a predictor of failure. Additionally, Albers et al.(9) reported 165 hips after PAO and found that improper acetabular reorientation may accelerate osteoarthritis progression in patients with DDH, and proper acetabular reorientation without introducing femoroacetabular impingement (FAI) improved hip survivorship. To our knowledge, while there have been no other studies to indicate how radiographic parameters can be corrected to obtain favorable outcomes, the current studies showed that an LCEA of > 38° may increase the risk of adverse outcomes. We speculate that the cause of the adverse outcomes may be associated with excessive acetabular coverage, which increases the chance of secondary FAI(9, 21). Additionally, the correction of the postoperative Tönnis angle after PAO was unclear. According to the experience of the surgeon, a Tönnis angle of 0 ± 10° is in an acceptable range and was achieved in these surgeries. Our multivariate logistic

regression analysis found that a Tönnis angle of 10°-0 was a protective factor. Furthermore, considering the results of ROC analysis, our study suggest that a Tönnis angle of -9°-0 may result in better outcomes (Table 7). Not only there is no previous study to support this result, but different surgeons may have different understandings of the correction of the Tönnis angle; therefore, larger multicenter, prospective studies are needed to verify and explain why a postoperative Tönnis angle of -9°-0 is a predictor of successful outcomes.

Our study had some limitations. First, compared with prospective and multicenter studies, the level of evidence in this retrospective and single-center studies is insufficient. All patients underwent surgery by experienced PAO surgeons, which may limit the generalizability of this study. Second, we included 8 patients for analysis who underwent bilateral PAO, which may have affected the results. Third, patients were subjectively selected for inclusion in a retrospective study, which can lead to bias. While we cannot eliminate possible selection bias, strict inclusion criteria can help with drawing significant conclusions. Last, we only have the parameters of anteroposterior radiographs, but not the relevant parameters of frog-leg and false-profile radiographs.

Considering these limitations, our study presents novel findings. Short-term follow-up results in the past were mostly reports of patient-reported outcomes, and few studies included baseline or preoperative radiographic parameters in the multinomial logistic regression analysis for the prediction of risk factors. In contrast with these short-term follow-up results, our study not only performed an analysis of the impact of postoperative radiographic parameters on patient-reported outcomes but also performed ROC analysis on the postoperative LCEAs and Tönnis angles to determine their cutoffs.

Taken together, our results demonstrate marked improvements in patient-reported outcomes after PAO. Among hips with excellent or good joint congruency preoperatively treated by experienced surgeons who obtained the proper postoperative LCEAs and Tönnis angles, good patient-reported outcomes can be expected; the early symptomatic hip rates were low. Continued expansion and follow-up of this study will provide a higher level of clinical evidence to further determine how to improve patient-reported outcomes of PAO. Future studies should pay attention to comparing more postoperative radiographic parameters between asymptomatic and symptomatic hips to determine whether these parameters can be used as factors for predicting failure and as a reference value for PAO.

Abbreviations

PAO, Bernese periacetabular osteotomy; DDH, Developmental dysplasia of the hip; HHS, Harris Hip Score; iHOT-12, International Hip Outcome Instrument-12; ROC, receiver operating characteristic; THR, total hip replacement; LCEA, lateral center-to-edge angle; FAI, femoroacetabular impingement.

Declarations

Ethics approval and consent to participate

The institutional review board of the first affiliated hospital of Guangzhou University of Chinese Medicine approved this study. All methods were carried out in accordance with relevant guidelines and regulations. Informed consent was obtained from all subjects.

Consent for publication

Not applicable.

Availability of data and materials

The datasets used or analysed during the current study are available from the corresponding author on reasonable request.

Competing interests

The authors declare that they have to no conflict of interest.

Fund

This work was supported by High-level hospital construction project (The First Affiliated Hospital of Guangzhou University of Chinese Medicine, Grant No: 211020030705) in the form of covering the consultation fees of data statistical analysis.

Authors' contribution

Conceptualization: Yinuo Fan and Zhenqiu Chen. Literature search: Yinuo Fan, Weifeng Li and Guoju Hong. Data extraction and quality assessment: Weifeng Li and Yunlong Wu. Software: Weifeng Li, Lixin Chen and Yunlong Wu. Formal analysis: Yinuo Fan, Guoju Hong, and Hanjun Fang. Validation: Chi Zhou, Wei He and Zhenqiu Chen. Writing: Yinuo Fan. All authors read and approved the final manuscript.

Acknowledgments

No acknowledgement.

References

1. MacKenzie IG, Wilson JG. Problems encountered in the early diagnosis and management of congenital dislocation of the hip. J Bone Joint Surg Br. 1981;63-B(1):38-42.
2. Dunn PM, Evans RE, Thearle MJ, Griffiths HE, Witherow PJ. Congenital dislocation of the hip: early and late diagnosis and management compared. Arch Dis Child. 1985;60(5):407-14.
3. Feldman GJ, Parvizi J, Sawan H, Erickson JA, Peters CL. Linkage Mapping and Whole Exome Sequencing Identify a Shared Variant in CX3CR1 in a Large Multi-Generation Family. J Arthroplasty. 2014;29(9):238-41.

4. Furnes O, Lie SA, Espehaug B, Vollset SE, Engesaeter LB, Havelin LI. Hip disease and the prognosis of total hip replacements - A review of 53 698 primary total hip replacements reported to the Norwegian Arthroplasty Register 1987-99. Journal of Bone and Joint Surgery-British Volume. 2001;83b(4):579-86.
5. Ganz R, Leunig M, Leunig-Ganz K, Harris WH. The etiology of osteoarthritis of the hip - An integrated mechanical concept. Clin Orthop Relat R. 2008;466(2):264-72.
6. Pollard TC, Gwilym SE, Carr AJ. The assessment of early osteoarthritis. J Bone Joint Surg Br. 2008;90(4):411-21.
7. Ganz R, Klaue K, Vinh TS, Mast JW. A new periacetabular osteotomy for the treatment of hip dysplasias - Technique and preliminary results (Reprinted from Clin Orthop, vol 232, pg 26-36, 1988). Clin Orthop Relat R. 2004(418):3-8.
8. Yang S, Zusman N, Lieberman E, Goldstein RY. Developmental Dysplasia of the Hip. Pediatrics. 2019;143(1).
9. Albers CE, Steppacher SD, Ganz R, Tannast M, Siebenrock KA. Impingement Adversely Affects 10-year Survivorship After Periacetabular Osteotomy for DDH. Clin Orthop Relat R. 2013;471(5):1602-14.
10. Clohisy JC, Ackerman J, Baca G, Baty J, PE B, Kim YJ, et al. Patient-Reported Outcomes of Periacetabular Osteotomy from the Prospective ANCHOR Cohort Study. J Bone Joint Surg Am. 2017;99(1):33-41.
11. Clohisy JC, Barrett SE, Gordon JE, Delgado ED, Schoenecker PL. Periacetabular osteotomy for the treatment of severe acetabular dysplasia. J Bone Joint Surg Am. 2005;87a(2):254-9.
12. Davidson D, Yen YM, Jette AM, Olarsch S, Kim YJ. Responsiveness of the SF-36 and WOMAC Following Periacetabular Osteotomy for Acetabular Dysplasia. J Bone Joint Surg Am. 2011;93a(23):2214-8.
13. Jacobsen JS, Soballe K, Thorborg K, Bolvig L, Jakobsen SS, Holmich P, et al. Patient-reported outcome and muscle-tendon pain after periacetabular osteotomy are related: 1-year follow-up in 82 patients with hip dysplasia. Acta Orthop. 2019;90(1):40-5.
14. Livermore AT, Anderson LA, Anderson MB, Erickson JA, Peters CL. Correction of mildly dysplastic hips with periacetabular osteotomy demonstrates promising outcomes, achievement of correction goals, and excellent five-year survivorship. Bone Joint J. 2019;101b(6):16-22.
15. Ricciardi BF, Fields KG, Wentzel C, Nawabi DH, Kelly BT, Sink EL. Complications and short-term patient outcomes of periacetabular osteotomy for symptomatic mild hip dysplasia. Hip Int. 2017;27(1):42-8.
16. Sanchez-Sotelo J, Trousdale RT, Berry DJ, Cabanela ME. Surgical treatment of developmental dysplasia of the hip in adults: I. Nonarthroplasty options. J Am Acad Orthop Surg. 2002;10(5):321-33.
17. Steppacher SD, Tannast M, Ganz R, Siebenrock KA. Mean 20-year followup of bernese periacetabular osteotomy. Clin Orthop Relat R. 2008;466(7):1633-44.

18. Trumble SJ, Mayo KA, Mast JW. The periacetabular osteotomy - Minimum 2 year followup in more than 100 hips. Clin Orthop Relat R. 1999(363):54-63.
19. Wasko MK, Yanik EL, Pascual-Garrido C, Clohisy JC. Psychometric Properties of Patient-Reported Outcome Measures for Periacetabular Osteotomy. J Bone Joint Surg Am. 2019;101(6).
20. Wells J, Millis M, Kim YJ, Bulat E, Miller P, Matheney T. Survivorship of the Bernese Periacetabular Osteotomy: What Factors are Associated with Long-term Failure? Clin Orthop Relat Res. 2017;475(2):396-405.
21. Wells J, Schoenecker P, Duncan S, Goss CW, Thomason K, Clohisy JC. Intermediate-Term Hip Survivorship and Patient-Reported Outcomes of Periacetabular Osteotomy The Washington University Experience. J Bone Joint Surg Am. 2018;100(3):218-25.
22. Harris WH. Traumatic arthritis of the hip after dislocation and acetabular fractures: treatment by mold arthroplasty. An end-result study using a new method of result evaluation. J Bone Joint Surg Am. 1969;51(4):737-55.
23. Yin J, Zhu H, Gao Y, Zhang C. Vascularized Fibular Grafting in Treatment of Femoral Neck Nonunion: A Prognostic Study Based on Long-Term Outcomes. J Bone Joint Surg Am. 2019;101(14):1294-300.
24. Kraeutler MJ, Safran MR, Scillia AJ, Ayeni OR, Garabekyan T, Mei-Dan O. A Contemporary Look at the Evaluation and Treatment of Adult Borderline and Frank Hip Dysplasia. Am J Sport Med. 2020;48(9):2314-23.
25. Nepple JJ, Wells J, Ross JR, Bedi A, Schoenecker PL, Clohisy JC. Three Patterns of Acetabular Deficiency Are Common in Young Adult Patients With Acetabular Dysplasia. Clin Orthop Relat R. 2017;475(4):1037-44.
26. Yang YH, Zuo JL, Liu T, Xiao JL, Liu SL, Gao ZL. Morphological Analysis of True Acetabulum in Hip Dysplasia (Crowe Classes I-IV) Via 3-D Implantation Simulation. J Bone Joint Surg Am. 2017;99(17).
27. Kalore NV, Jiranek WA. Save the Torn Labrum in Hips With Borderline Acetabular Coverage. Clin Orthop Relat R. 2012;470(12):3406-13.
28. Larson CM, Moreau-Gaudry A, Kelly BT, Byrd JWT, Tonetti J, Lavallee S, et al. Are Normal Hips Being Labeled as Pathologic? A CT-based Method for Defining Normal Acetabular Coverage. Clin Orthop Relat R. 2015;473(4):1247-54.
29. Kovalenko B, Bremjit P, Fernando N. Classifications in Brief: Tonnis Classification of Hip Osteoarthritis. Clin Orthop Relat R. 2018;476(8):1680-4.
30. Tonnis D, Heinecke A. Acetabular and femoral anteversion: Relationship with osteoarthritis of the hip. J Bone Joint Surg Am. 1999;81a(12):1747-70.
31. Yasunaga Y, Ochi M, Terayama H, Tanaka R, Yamasaki T, Ishii Y. Rotational acetabular osteotomy for advanced osteoarthritis secondary to dysplasia of the hip. J Bone Joint Surg Am. 2006;88a(9):1915-9.
32. Chang CH, Chiang YT, Lee ZL, Kuo KN. Incidence of surgery in developmental dysplasia of the hip in Taiwan. J Formos Med Assoc. 2007;106(6):462-6.

33. Dindo D, Demartines N, Clavien PA. Classification of surgical complications - A new proposal with evaluation in a cohort of 6336 patients and results of a survey. Ann Surg. 2004;240(2):205-13.
34. McAuley JP, Szuszczewicz ES, Young A, Engh CA, Sr. Total hip arthroplasty in patients 50 years and younger. Clin Orthop Relat Res. 2004(418):119-25.
35. Matheney T, Kim YJ, Zurakowski D, Matero C, Millis M. Intermediate to Long-Term Results Following the Bernese Periacetabular Osteotomy and Predictors of Clinical Outcome. J Bone Joint Surg Am. 2009;91a(9):2113-23.

Figures

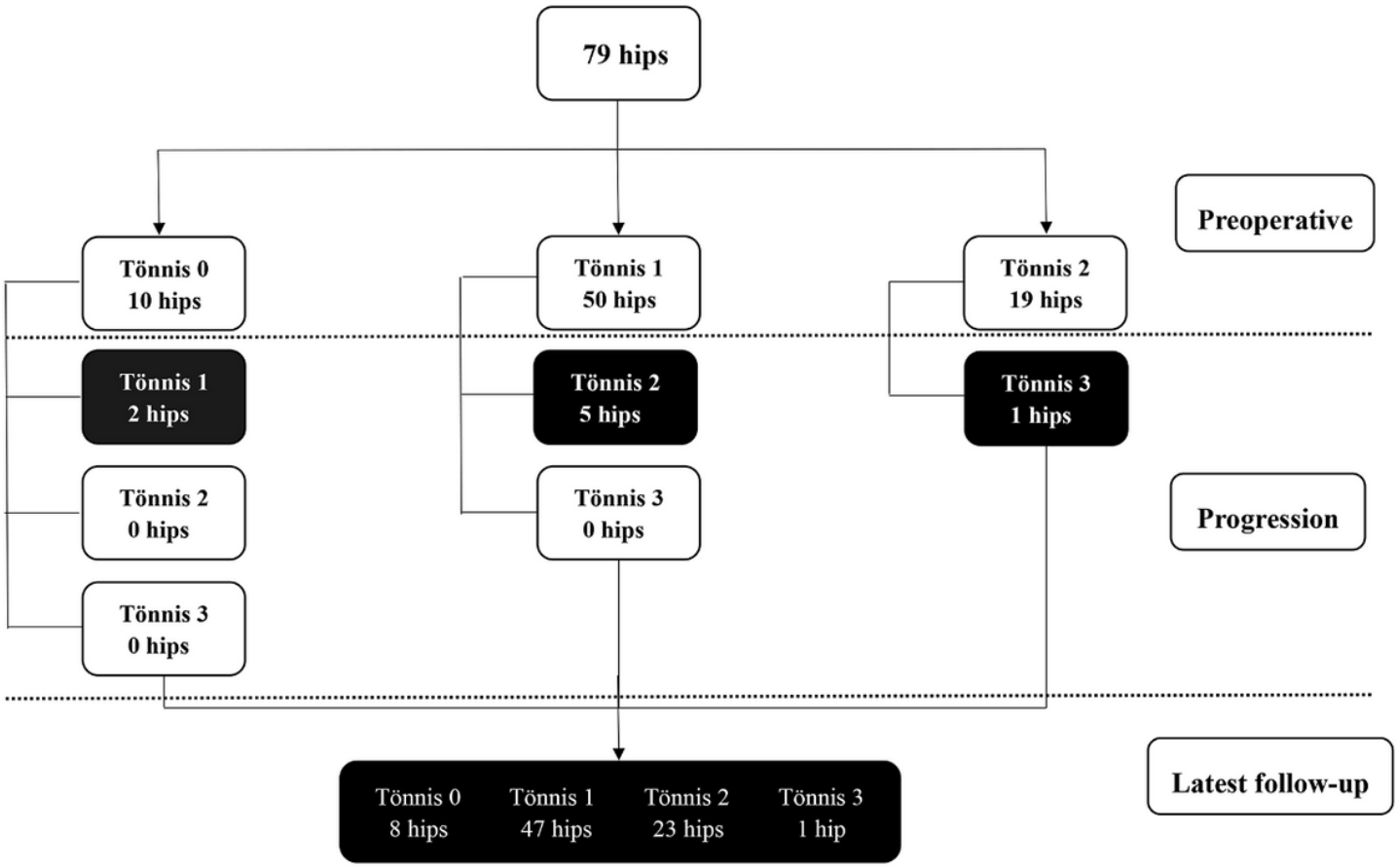

Figure 1

The progression of osteoarthritis according to the Tönnis classification.

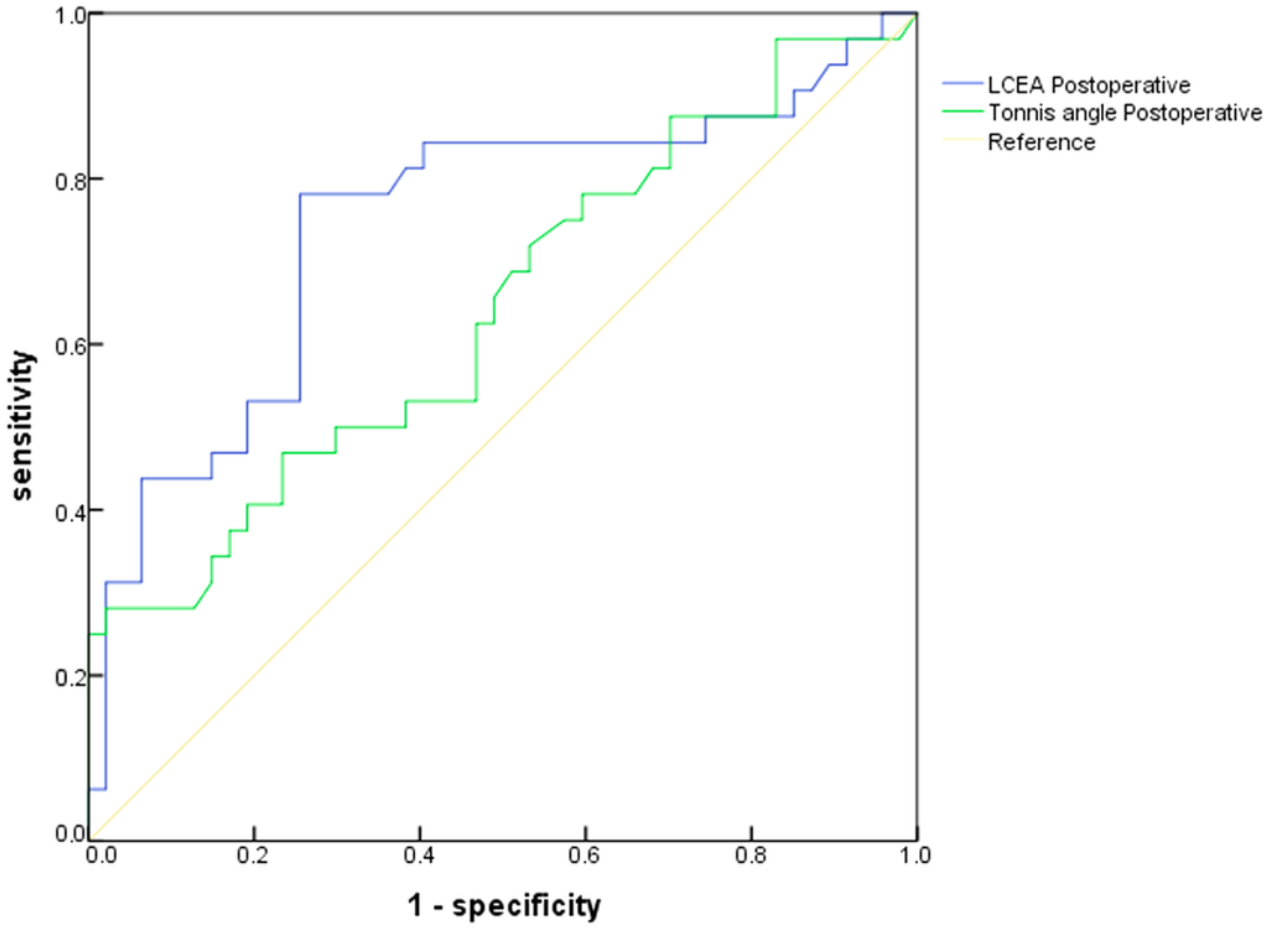

Figure 2

ROC curve of postoperative LCEA and Tönnis angle.