Differential Diagnosis of Pancreatic Serous Cystadenomas and Mucinous Cystadenomas: Utility of Texture Analysis in Combination with Morphological Characteristics

Jing Yang
Sichuan University West China Hospital
Xinli Guo
Sichuan University West China Hospital
Weiwei Zhang
Sichuan University West China Hospital
Jinen Song
Sichuan University West China Hospital
Xuelei Ma (drmaxuelei@gmail.com)
West China Hospital, Sichuan University https://orcid.org/0000-0002-9148-5001
Hui Xu
Sichuan University West China Hospital

Research article

Keywords: Pancreas; Serous cystadenoma; Mucinous cystadenoma; Diagnosis; Multidetector computed tomography

Posted Date: August 28th, 2019

DOI: https://doi.org/10.21203/rs.2.13612/v1

Version of Record: A version of this preprint was published on December 16th, 2019. See the published version at https://doi.org/10.1186/s12885-019-6421-7.

Abstract

Background Texture analysis of medical images has been reported to be a reliable technique for differential diagnosis of neoplasms. This study was to investigate the performance of textural features and the combined performance of textural features and morphological characteristics in the differential diagnosis of pancreatic serous and mucinous cystadenomas. Methods We retrospectively reviewed 59 patients with pancreatic serous cystadenoma and 32 patients with pancreatic mucinous cystadenoma at our hospital. Textural features were extracted using the LifeX software, and the least absolute shrinkage and selection operator (LASSO) method was applied to select the textural features. The differential diagnostic abilities of morphological features, textural features, and their combination were evaluated using receiver operating characteristic (ROC) analysis, with the area under the receiver operating characteristic curve (AUC) as the main indicator. Results The combination of morphological characteristics and textural features showed a higher AUC (0.893, 95% CI 0.816-0.970) than use of morphological characteristics (0.783, 95% CI 0.665-0.900) or textural features (0.777, 95% CI 0.673-0.880) alone. Conclusions In conclusion, our preliminary results highlighted the potential of CT texture analysis to discriminate pancreatic serous cystadenomas from mucinous cystadenomas. Furthermore, the combination of morphological and textural features can significantly improve the diagnostic performance, which may provide a reliable method to select patients with indication of surgical intervention in consideration of the different treatment principles of the two diseases.

Background

Cystic neoplasms of the pancreas are historically considered rare subsets of pancreatic lesions. However, pancreatic neoplasms are being diagnosed more frequently given the widespread use of abdominal cross-sectional imaging techniques [1]. In asymptomatic subjects, the prevalence of pancreatic cysts on abdominal imaging ranges from 2% to 16%, and increases with advancing age [2, 3]. Various pathological entities of pancreas may present with the radiological diagnosis of cystic lesions, including benign, borderline, and malignant neoplasms, and non-neoplastic pancreatic cysts [3]. The common cystic neoplasms which are considered benign include serous cystadenomas and pseudocysts, whereas mucinous cystadenomas and intraductal papillary mucinous neoplasms (IPMN) are the common potentially malignant or malignant lesions that require careful analysis [4]. Differential diagnosis is clinically important in order to allow proper management of serous cystadenomas which are benign and surgery should be avoided or minimized, and mucinous cystadenomas which are potential malignant and deserve surgical resection [5, 6]. Patient demographics, high-quality cross-sectional imaging, endoscopic ultrasound (EUS) and cyst fluid analysis have been reported to be useful in the differential diagnosis of pancreatic cystic neoplasms [6, 7]. However, the accuracy of preoperative diagnosis is still relative low, ranging from 47% to 78% [8-11]. Many of these lesions remain difficult to classify without operative resection.

Computed tomography (CT) is most widely used in the visualization and differentiation of pancreatic cysts based on morphological features, such as location, size, contour, calcifications of cyst wall, septa,

and mural nodules [12, 13]. However, the accuracy of these morphological characteristic in the differential diagnosis is still unsatisfactory. In the past years, interest has grown in computerized texture analysis of medical images that provides a more detailed and reproducible quantitative assessment of cancer lesion characteristics. Texture analysis refers to a number of mathematical methods that can be used to describe the intensities and spatial distributions of pixels [14]. Texture analysis has been reported to be a reliable technique for differential diagnosis of benign and malignant neoplasms of breast and thyroid [15, 16]. However, for the discrimination of pancreatic serous cystadenomas and mucinous cystadenomas, few applications of texture analysis of medical images have been reported. In this research, we assessed the diagnostic role of textural features, and evaluated the combined performance of morphological and textural features in the differential diagnosis of pancreatic serous cystadenomas and mucinous cystadenomas.

Methods

Patient population

The Ethics Administration Office of West China Hospital, Sichuan University approved this retrospective study and waived the requirement for informed consent. Patients who were histopathological diagnosed with pancreatic serous or mucinous cystadenoma at our institution between January 2011 and October 2018 were identified from electronic database. Patients without preoperative contrast-enhanced CT images were excluded. Thirty-two patients with mucinous cystadenomas and 59 patients with serous cystadenomas were enrolled. The selection process of patients was shown in the Additional Figure 1.

Image acquisition and texture analysis

All patients underwent contrast-enhanced CT examination of abdomen following injection of 1.5-2.0 mL/kg of an anionic contrast medium (Omnipaque 350, GE Healthcare) at a rate of 3 mL/s. The images were obtained at a 5 mm section thickness after a 60-65 second delay, with the following acquisition parameters: 120 kVp; 200 to 250 mAs; pitch, 0.75-1.5; collimation, 0.625 mm. All CT examinations were performed using one of the scanners: Brilliance-64, Philips Medical Systems, Eindhoven, The Netherlands; 128-MDCT scanner Somatom Definition, Siemens Healthcare Sector, Forchheim, Germany. Texture analysis of the contrast-enhanced CT images was performed using LifeX software (http://www.lifexsoft.org) [17]. A three-dimensional region of interest (ROI) around the margin of lesion was drawn manually by an experienced abdominal radiologist and textural parameters were retrieved from the ROI. The following 6 groups of textural indices were extracted: histogram, shape and size, gray-level co-occurrence matrix (GLCM), neighborhood gray-level different matrix (NGLDM), gray level run length matrix (GLRLM), and gray-level zone-length matrix (GLZLM).

Statistical Analysis

The least absolute shrinkage and selection operator (LASSO) method was applied to select the textural features. All textural data were given as mean ± standard deviation. Statistical differences of textural

parameters of the patients were analyzed using the Manne-Whitney U test. A p value of less than 0.05 was considered to indicate statistical significance. Receiver operating characteristic curve (ROC) analysis was conducted to estimate the performance of textural features, morphological characteristics, and their combination in the differential diagnosis of serous cystadenomas and mucinous cystadenomas, with the area under the receiver operating characteristic curve (AUC) as the main indicator. Diagnostic accuracy based on the AUC value is defined as follows: 0.9–1.0, excellent; 0.8–0.9, good; 0.7–0.8, moderate; 0.6–0.7, fair; and 0.5–0.6, poor [18]. All statistical analyses were performed using PYTHON software and SPSS version 20.0 (IBM Corporation, Armonk, NY, USA).

Results

Patient population

Baseline characteristics of the patients were summarized in Table 1. The median ages were 52 years (29-73 years) for patients with serous cystadenomas and 46 years (2-71 years) for patients with mucinous cystadenomas. There were 16 males and 43 females in the serous cystadenoma group and 5 males and 27 females in the mucinous cystadenoma group. The morphological features were extracted from CT images, including location, size, wall enhancement, mural nodule, cyst, central calcification, and contour of disease lesions. Example of a transverse CT image obtained in a patient with mucinous cystadenoma was shown in the Additional Figure 2.

Differences between mucinous cystadenomas and serous cystadenomas

Fifteen textural parameters were selected using LASSO methods. There were signifcant differences between mucinous cystadenomas and serous cystadenomas in 11 of the 15 parameters: SHAPE_Volume (mL) (132.410 *vs* 16.830, p=0.002), SHAPE_Volume (# vx) (86440.906 *vs* 13405.898, p=0.004), GLRLM_HGRE (High Gray-level Run Emphasis) (10705.686 *vs* 11045.168, p=0.007), GLRLM_SRHGE (Short-Run High Gray-level Emphasis) (8960.444 *vs* 9693.035, p<0.001), GLRLM_LRHGE (Long-Run High Gray-level Emphasis) (23180.285 *vs* 19307.823, p=0.004), GLRLM_GLNU (Gray-Level Non-Uniformity) (12199.099 *vs* 1410.730, p=0.002), GLRLM_RLNU (Run Length Non-Uniformity) (36232.333 *vs* 7832.312, p=0.007), GLZLM_LZE (Long-Zone Emphasis) (68473.586 *vs* 13787.533, p=0.002), GLZLM_LZHGE (Long-Zone High Gray-level Emphasis) (7.251E+8 *vs* 1.459E+8, p=0.003), GLZLM_GLNU (Gray-Level Non-Uniformity) (521.486 *vs* 98.004, p=0.001), and GLZLM_ZLNU (Zone Length Non-Uniformity) (1275.021 *vs* 383.108, p=0.008) (Table 2). No significant differences were found in minValue, maxValue, NGLDM_Busyness and GLZLM_SZHGE (Short-Zone High Gray-level Emphasis). The differences in textural features and morphological characteristics between mucinous cystadenoma and serous cystadenoma were shown in the Figure 1.

Receiver operating characteristic analysis

To discriminate between pancreatic mucinous cystadenomas and serous cystadenomas groups, the AUC of textural parameter with statistical significance between mucinous and serous cystadenomas groups

were calculated. The results of ROC analysis were shown in Table 3 and Figure 2. The AUC of SHAPE_Volume (mL), GLRLM_SRHGE, GLRLM_GLNU and GLZLM_GLNU were larger than or equal to 0.700, which were 0.700 (95% confdence interval [CI] 0.580-0.821), 0.756 (95% CI 0.652-0.859), 0.701 (95% CI 0.580-0.821) and 0.704 (95% CI 0.587-0.820), respectively. The combination of all 11 textural parameters showed good ability to discriminate mucinous cystadenomas and serous cystadenomas (AUC 0.777, 95% CI 0.673-0.880). With regard to morphological features, the AUC were 0.641 (95% CI 0.523-0.759) for location, 0.710 (95% CI 0.590-0.830) for size, and 0.667 (95% CI 0.542-0.793) for lobulated contour. Furthermore, the AUC of the combination of morphological and textural features was 0.893 (95% CI 0.816-0.970).

Discussion

Mucinous cystadenomas constitute approximately 23% of all the resected cystic lesions of pancreas, and serous cystadenomas account for 16% [19]. Mucinous cystadenomas have considerable malignant potential, with estimates ranging from 10% to 50% [20]. In contrast, serous cystadenomas are considered benign and are typically found incidentally. A large multicenter study found only 3 cases of serous adenocarcinomas in a series of 2622 patients with serous cystadenoma, which suggested that serous cystadenomas are almost always benign and indolent tumor [21]. Thus, surgical intervention should be proposed in a minority of patients with serous cystadenoma, only for those who had uncertain diagnosis after systemic examinations or had symptoms [21, 22]. Given the risk of invasive disease and the relatively young age at diagnosis, surgical management is recommended for all mucinous cystadenomas patients who are medically fit for the surgery [23]. Therefore, the differential diagnosis of the two diseases is clinically crucial to the treatment regimen options.

Although CT images enable the correct diagnosis in typical cases, serous cystadenomas, especially macrocystic or oligocystic type, is difficult to distinguish from mucinous cystadenomas [24]. Previous studies have reported many cases of pancreatic serous cystadenoma that are misdiagnosed as mucinous cystadenoma and therefore are inappropriately managed [24-26]. In this study, the results showed that morphological features and textural parameters including location, size, lobulated contour, SHAPE_Volume (mL), SHAPE_Volume (# vx), GLRLM_HGRE, GLRLM_SRHGE, GLRLM_LRHGE, GLRLM_GLNU, GLRLM_RLNU, GLZLM_LZE, GLZLM_LZHGE, GLZLM_GLNU and GLZLM_ZLNU were significant differentiators of pancreatic mucinous cystadenomas and serous cystadenomas. Furthermore, the combination of morphological and textural features demonstrated good ability to discriminate the two diseases.

The majority of studies conducted in recent years have focused on the morphological features of medical images. Previous studies have summarized the typical radiologic appearances of mucinous cystadenoma: located in the body or tail of pancreas, solitary cyst, mural nodules, enhancement of the peripheral wall and diameter greater than 2 cm [13, 22, 27-29]. Some researchers have concluded that the diagnosis of serous cystadenoma can be made base on the lesion’s radiologic presentations including multilobular mass, central calcifications and lack of wall enhancement [13, 22]. However, the results have

been controversial in different researches. Johnson et al have reported that blind reviewers are able to correctly classify above 90% of cases of mucinous or serous cystadenomas, whereas Curry et al have reported that the rates of reviewers correctly identified serous cystadenomas and mucinous cystadenomas are 27% and 25%, respectively [12, 29]. In this study, we also assessed the performance of morphological features in the differentiation diagnosis of pancreatic serous and mucinous cystadenomas and suggested that tumor location, size and lobulated contour were reliable indices. Moreover, the combination use of location, size, wall enhancement, mural nodule, solitary cyst, central calcification and lobulated contour could improve the diagnostic value.

Texture analysis refers to a variety of mathematical methods that could be used to describe the position and intensity of signal features, which provides a useful way to maximize the information that can be derived from medical images[14]. Many previous studies focused on textural features have been performed. It has been proposed that textural parameters extracted from the disease lesions can be used to discriminate benign and malignant breast tumors, benign and malignant thyroid nodules, pancreatic lymphoma and pancreatic adenocarcinoma, as well as primary and metastatic lung lesions [15, 16, 30, 31]. However, less attention being paid to textural features of pancreatic cystadenomas, which may be helpful in discrimination of serous and mucinous cystadenomas. In the present study, the results demonstrated that textural parameters were relative good indices in the differentiation of serous and mucinous cystadenomas. Furthermore, the combination of morphological and texture analysis can significantly improve the diagnostic performance. As an AUC > 0.8 indicated a good accuracy, this combination is considered to be able to distinguish between pancreatic mucinous cystadenomas and serous cystadenomas, and it has potential clinical practical value[18].

There are several limitations in this study. Firstly, the number of patients is relatively small. Second, this is a retrospective analysis in a single center. Third, there is subjectivity in the process of manually outlining the lesion boundary. Therefore, prospective studies with a large population are required to confirm the validity of the present findings.

Conclusions

In conclusion, our preliminary results highlighted the potential of CT texture analysis to discriminate pancreatic serous cystadenomas and mucinous cystadenomas. Furthermore, the combination of morphological features and texture analysis can significantly improve differential diagnostic performance, which may provide a reliable method for selecting pancreatic cystadenoma patients who need surgical intervention.

Abbreviations

LASSO: least absolute shrinkage and selection operator; ROC: receiver operating characteristic; AUC: area under the receiver operating characteristic curve; IPMN: intraductal papillary mucinous neoplasms; EUS: endoscopic ultrasound; CT: computed tomography; GLCM: gray-level co-occurrence matrix; NGLDM:

neighborhood gray-level different matrix; GLRLM: gray level run length matrix; GLZLM: gray-level zone-length matrix; HGRE: high gray-level run emphasis; SRHGE: short-run high gray-level emphasis; LRHGE: long-run high gray-level emphasis; GLNU: gray-level non-uniformity; RLNU: run length non-uniformity; LZE: long-zone emphasis; LZHGE: long-zone high gray-level emphasis; GLNU: gray-level non-uniformity; ZLNU: zone length non-uniformity; SZHGE (short-zone high gray-level emphasis; CI: confdence interval.

Declarations

Ethics approval and consent to participate

The Ethics Administration Office of West China Hospital, Sichuan University approved this retrospective study and waived the requirement for informed consent.

Consent for publication

Not applicable.

Availability of data and materials

The datasets used and/or analysed during the current study are available from the corresponding author on reasonable request.

Competing Interests

The authors declare that they have no competing interests

Funding

None

Authors' contributions

JY designed the study, performed the data analysis and drafted the manuscript. XG and JS performed the data analysis and drafted the manuscript. WZ extracted the data. XM designed the study. All authors read and approved the final manuscript.

Acknowledgements

None

References

1. Khalid A, Brugge W: **ACG practice guidelines for the diagnosis and management of neoplastic pancreatic cysts.** *Am J Gastroenterol* 2007, **102:**2339-2349.

2. de Jong K, Nio CY, Hermans JJ, Dijkgraaf MG, Gouma DJ, van Eijck CH, van Heel E, Klass G, Fockens P, Bruno MJ: **High prevalence of pancreatic cysts detected by screening magnetic resonance imaging examinations.** *Clin Gastroenterol Hepatol* 2010, **8:**806-811.
3. de Jong K, Bruno MJ, Fockens P: **Epidemiology, diagnosis, and management of cystic lesions of the pancreas.** *Gastroenterol Res Pract* 2012, **2012:**147465.
4. Goh BK, Tan DM, Thng CH, Lee SY, Low AS, Chan CY, Wong JS, Lee VT, Cheow PC, Chow PK, et al: **Are the Sendai and Fukuoka consensus guidelines for cystic mucinous neoplasms of the pancreas useful in the initial triage of all suspected pancreatic cystic neoplasms? A single-institution experience with 317 surgically-treated patients.** *Ann Surg Oncol* 2014, **21:**1919-1926.
5. Pyke CM, van Heerden JA, Colby TV, Sarr MG, Weaver AL: **The spectrum of serous cystadenoma of the pancreas. Clinical, pathologic, and surgical aspects.** *Ann Surg* 1992, **215:**132-139.
6. Ketwaroo GA, Mortele KJ, Sawhney MS: **Pancreatic Cystic Neoplasms: An Update.** *Gastroenterol Clin North Am* 2016, **45:**67-81.
7. Jani N, Bani Hani M, Schulick RD, Hruban RH, Cunningham SC: **Diagnosis and management of cystic lesions of the pancreas.** *Diagn Ther Endosc* 2011, **2011:**478913.
8. Correa-Gallego C, Ferrone CR, Thayer SP, Wargo JA, Warshaw AL, Fernandez-Del Castillo C: **Incidental pancreatic cysts: do we really know what we are watching?** *Pancreatology* 2010, **10:**144-150.
9. Cho CS, Russ AJ, Loeffler AG, Rettammel RJ, Oudheusden G, Winslow ER, Weber SM: **Preoperative classification of pancreatic cystic neoplasms: the clinical significance of diagnostic inaccuracy.** *Ann Surg Oncol* 2013, **20:**3112-3119.
10. Salvia R, Malleo G, Marchegiani G, Pennacchio S, Paiella S, Paini M, Pea A, Butturini G, Pederzoli P, Bassi C: **Pancreatic resections for cystic neoplasms: from the surgeon's presumption to the pathologist's reality.** *Surgery* 2012, **152:**S135-142.
11. Del Chiaro M, Segersvard R, Pozzi Mucelli R, Rangelova E, Kartalis N, Ansorge C, Arnelo U, Blomberg J, Lohr M, Verbeke C: **Comparison of preoperative conference-based diagnosis with histology of cystic tumors of the pancreas.** *Ann Surg Oncol* 2014, **21:**1539-1544.
12. Curry CA, Eng J, Horton KM, Urban B, Siegelman S, Kuszyk BS, Fishman EK: **CT of primary cystic pancreatic neoplasms: can CT be used for patient triage and treatment?** *AJR Am J Roentgenol* 2000, **175:**99-103.
13. Cohen-Scali F, Vilgrain V, Brancatelli G, Hammel P, Vullierme MP, Sauvanet A, Menu Y: **Discrimination of unilocular macrocystic serous cystadenoma from pancreatic pseudocyst and mucinous cystadenoma with CT: initial observations.** *Radiology* 2003, **228:**727-733.
14. Castellano G, Bonilha L, Li LM, Cendes F: **Texture analysis of medical images.** *Clin Radiol* 2004, **59:**1061-1069.
15. Ardakani AA, Gharbali A, Mohammadi A: **Classification of Benign and Malignant Thyroid Nodules Using Wavelet Texture Analysis of Sonograms.** *J Ultrasound Med* 2015, **34:**1983-1989.
16. Li Z, Yu L, Wang X, Yu H, Gao Y, Ren Y, Wang G, Zhou X: **Diagnostic Performance of Mammographic Texture Analysis in the Differential Diagnosis of Benign and Malignant Breast Tumors.** *Clin Breast*

Cancer 2018, **18:**e621-e627.

17. Nioche C, Orlhac F, Boughdad S, Reuze S, Goya-Outi J, Robert C, Pellot-Barakat C, Soussan M, Frouin F: **LIFEx: A Freeware for Radiomic Feature Calculation in Multimodality Imaging to Accelerate Advances in the Characterization of Tumor Heterogeneity.** 2018, **78:**4786-4789.
18. van Gruting IMA, Stankiewicz A, Kluivers K, De Bin R, Blake H, Sultan AH, Thakar R: **Accuracy of Four Imaging Techniques for Diagnosis of Posterior Pelvic Floor Disorders.** *Obstet Gynecol* 2017, **130:**1017-1024.
19. Valsangkar NP, Morales-Oyarvide V, Thayer SP, Ferrone CR, Wargo JA, Warshaw AL, Fernandez-del Castillo C: **851 resected cystic tumors of the pancreas: a 33-year experience at the Massachusetts General Hospital.** *Surgery* 2012, **152:**S4-12.
20. Chandwani R, Allen PJ: **Cystic Neoplasms of the Pancreas.** *Annu Rev Med* 2016, **67:**45-57.
21. Jais B, Rebours V, Malleo G, Salvia R, Fontana M, Maggino L, Bassi C, Manfredi R, Moran R, Lennon AM, et al: **Serous cystic neoplasm of the pancreas: a multinational study of 2622 patients under the auspices of the International Association of Pancreatology and European Pancreatic Club (European Study Group on Cystic Tumors of the Pancreas).** 2016, **65:**305-312.
22. Farrell JJ, Fernandez-del Castillo C: **Pancreatic cystic neoplasms: management and unanswered questions.** *Gastroenterology* 2013, **144:**1303-1315.
23. Tanaka M, Fernandez-del Castillo C, Adsay V, Chari S, Falconi M, Jang JY, Kimura W, Levy P, Pitman MB, Schmidt CM, et al: **International consensus guidelines 2012 for the management of IPMN and MCN of the pancreas.** *Pancreatology* 2012, **12:**183-197.
24. Kim SY, Lee JM, Kim SH, Shin KS, Kim YJ, An SK, Han CJ, Han JK, Choi BI: **Macrocystic neoplasms of the pancreas: CT differentiation of serous oligocystic adenoma from mucinous cystadenoma and intraductal papillary mucinous tumor.** *AJR Am J Roentgenol* 2006, **187:**1192-1198.
25. Le Borgne J, de Calan L, Partensky C: **Cystadenomas and cystadenocarcinomas of the pancreas: a multiinstitutional retrospective study of 398 cases. French Surgical Association.** *Ann Surg* 1999, **230:**152-161.
26. Sainani NI, Saokar A, Deshpande V, Fernandez-del Castillo C, Hahn P, Sahani DV: **Comparative performance of MDCT and MRI with MR cholangiopancreatography in characterizing small pancreatic cysts.** *AJR Am J Roentgenol* 2009, **193:**722-731.
27. Le Baleur Y, Couvelard A, Vullierme MP, Sauvanet A, Hammel P, Rebours V, Maire F, Hentic O, Aubert A, Ruszniewski P, Levy P: **Mucinous cystic neoplasms of the pancreas: definition of preoperative imaging criteria for high-risk lesions.** *Pancreatology* 2011, **11:**495-499.
28. Manfredi R, Ventriglia A, Mantovani W, Mehrabi S, Boninsegna E, Zamboni G, Salvia R, Pozzi Mucelli R: **Mucinous cystic neoplasms and serous cystadenomas arising in the body-tail of the pancreas: MR imaging characterization.** *Eur Radiol* 2015, **25:**940-949.
29. Johnson CD, Stephens DH, Charboneau JW, Carpenter HA, Welch TJ: **Cystic pancreatic tumors: CT and sonographic assessment.** *AJR Am J Roentgenol* 1988, **151:**1133-1138.

30. Huang Z, Li M, He D, Wei Y, Yu H, Wang Y, Yuan F, Song B: **Two-dimensional Texture Analysis Based on CT Images to Differentiate Pancreatic Lymphoma and Pancreatic Adenocarcinoma: A Preliminary Study.** *Acad Radiol* 2018.
31. Kirienko M, Cozzi L, Rossi A, Voulaz E, Antunovic L, Fogliata A, Chiti A, Sollini M: **Ability of FDG PET and CT radiomics features to differentiate between primary and metastatic lung lesions.** 2018, **45:**1649-1660.

Tables

Table 1: Characteristics of the patients

Characteristics	Serous cystadenoma	Mucinous cystadenoma
Age (years)		
Median (range)	52 (29-73)	46 (2-71)
Gender		
Male	16 (27.1%)	5 (15.6%)
Female	43 (72.9%)	27 (84.4%)
Location		
Head or neck	30 (50.8%)	7 (21.9%)
Body or tail	29 (49.2%)	25 (78.1%)
Mean size (range) (cm)	3.51 (1.00-8.00)	5.78 (1.78-12.00)
Wall enhancement		
Yes	24 (40.7%)	20 (62.5%)
No	35 (59.3%)	12 (37.5%)
Mural nodule		
Yes	0 (0)	4 (12.5%)
No	59 (100%)	28 (87.5%)
Solitary cyst		
Yes	24 (40.7%)	11 (34.4%)
No	35 (59.3%)	21 (65.6%)
Central calcification		
Yes	2 (3.4%)	5 (15.6%)
No	57 (96.6%)	27 (84.4%)
Lobulated contour		
Yes	54 (91.5%)	19 (59.4%)
No	5 (8.5%)	13 (40.6%)

Table 2: Comparison of serous cystadenoma and mucinous cystadenoma using textural features selected by Lasso method

Parameters	Mucinous cystadenoma (Mean±standard deviation)	Serous cystadenoma (Mean±standard deviation)	p value
minValue	--77.781±107.754	-69.237±73.228	0.790
maxValue	201.719±137.339	192.559±116.206	0.871
SHAPE_Volume (mL)	132.410±198.422	16.830±26.591	**0.002**
SHAPE_Volume (# vx)	86440.906±133750.594	13405.898±26123.459	**0.004**
GLRLM_HGRE	10705.686±319.685	11045.168±569.278	**0.007**
GLRLM_SRHGE	8960.444±784.341	9693.035±680.864	**<0.001**
GLRLM_LRHGE	23180.285±7008.004	19307.823±3270.445	**0.004**
GLRLM_GLNU	12199.099±20095.997	1410.730±2446.675	**0.002**
GLRLM_RLNU	36232.333±51393.630	7832.312±15277.470	**0.007**
NGLDM_Busyness	1.213E+17±1.23E+18	-5.192E+15±5.007E+16	0.303
GLZLM_LZE	68473.586±112680.309	13787.533±29805.620	**0.002**
GLZLM_SZHGE	6136.418±754.452	6291.730±1023.557	0.105
GLZLM_LZHGE	7.251E+8±1.168E+9	1.459E+8±3.095E+8	**0.003**
GLZLM_GLNU	521.486±767.516	98.004±115.961	**0.001**
GLZLM_ZLNU	1275.021±1705.679	383.108±474.747	**0.008**

Abbreviations: HGRE, High Gray-level Run Emphasis; SRHGE, Short-Run High Gray-level Emphasis; LRHGE, Long-Run High Gray-level Emphasis; GLNU, Gray-Level Non-Uniformity; RLNU, Run Length Non-Uniformity; LZE, Long-Zone Emphasis; SZHGE, Short-Zone High Gray-level Emphasis; LZHGE, Long-Zone High Gray-level Emphasis; GLNU, Gray-Level Non-Uniformity; ZLNU, Zone Length Non-Uniformity.

A p value <0.05 was considered statistically significant.

Table 3: The results of receiver operating characteristic analysis

Characteristics	Area under the curve (95% CI)	p value
Age	0.568 (0.430-0.706)	0.294
Location (head or neck vs body or tail)	0.641 (0.523-0.759)	**0.028**
Size	0.710 (0.590-0.830)	**0.001**
Wall enhancement	0.619 (0.497-0.741)	0.064
Mural nodule	0.565 (0.435-0.694)	0.316
Solitary cyst	0.526 (0.400-0.652)	0.687
Central calcification	0.564 (0.435-0.693)	0.323
Lobulated contour	0.667 (0.542-0.793)	**0.009**
SHAPE_Volume (mL)	0.700 (0.580-0.821)	**0.002**
SHAPE_Volume (# vx)	0.685(0.563-0.808)	**0.004**
GLRLM_HGRE	0.672 (0.562-0.781)	**0.007**
GLRLM_SRHGE	0.756 (0.652-0.859)	**<0.001**
GLRLM_LRHGE	0.682 (0.559-0.805)	**0.004**
GLRLM_GLNU	0.701 (0.580-0.821)	**0.002**
GLRLM_RLNU	0.671 (0.548-0.794)	**0.007**
GLZLM_LZE	0.698 (0.575-0.822)	**0.002**
GLZLM_LZHGE	0.692 (0.567-0.817)	**0.003**
GLZLM_GLNU	0.704 (0.587-0.820)	**0.001**
GLZLM_ZLNU	0.668 (0.547-0.790)	**0.008**
Combination_Textural parameters	0.777 (0.673-0.880)	**<0.001**
Combination_Morphological features	0.783 (0.665-0.900)	**<0.001**
Combination_All	0.893 (0.816-0.970)	**<0.001**

Abbreviations: HGRE, High Gray-level Run Emphasis; SRHGE, Short-Run High Gray-level Emphasis; LRHGE, Long-Run High Gray-level Emphasis; GLNU, Gray-Level Non-Uniformity; RLNU, Run Length Non-Uniformity; LZE, Long-Zone Emphasis; LZHGE, Long-Zone High Gray-level Emphasis; GLNU, Gray-Level Non-Uniformity; ZLNU, Zone Length Non-Uniformity Zone.

Figures

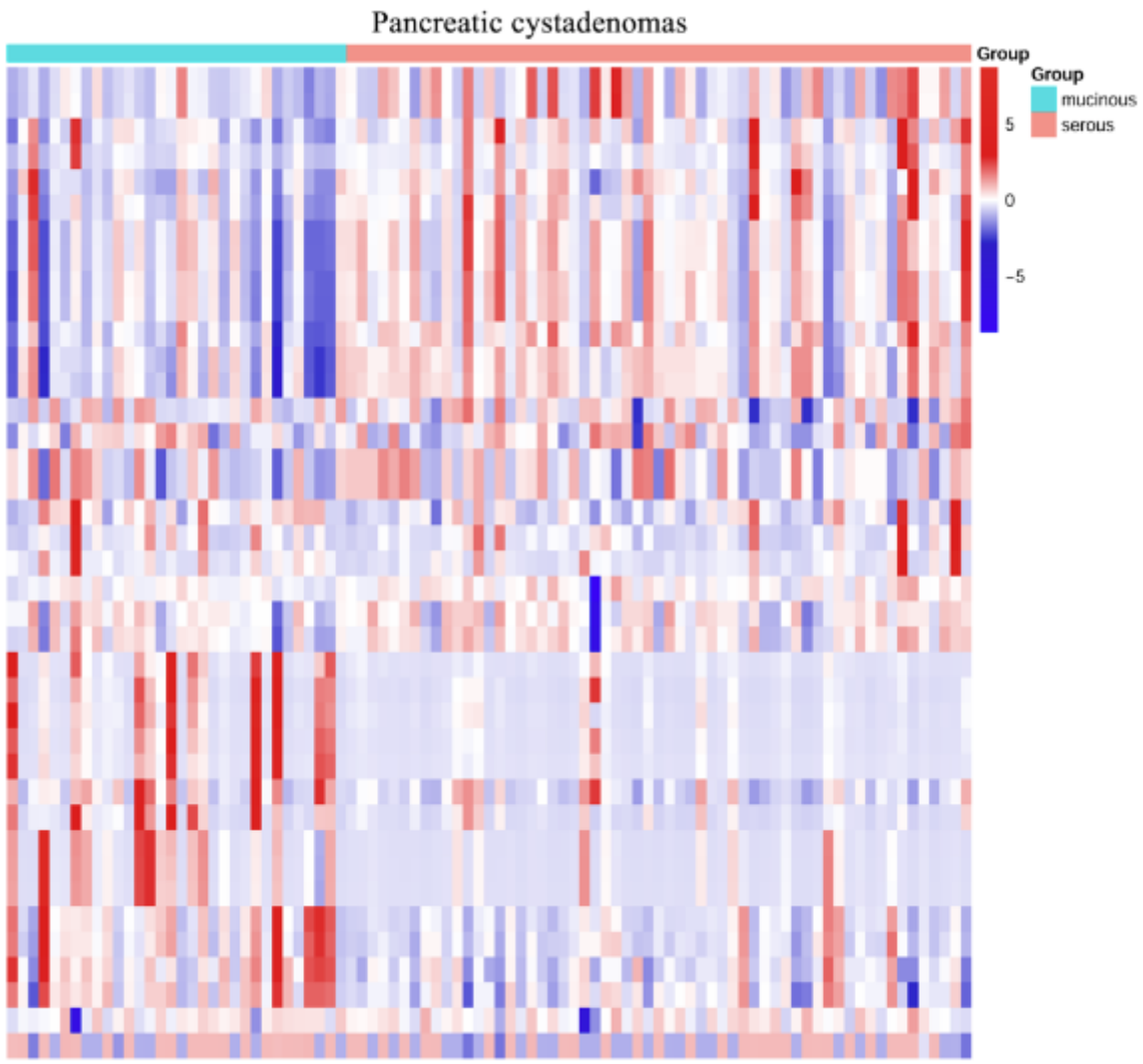

Figure 1

Heat map of the textural features and morphological characteristics for differentiating between pancreatic mucinous cystadenoma and serous cystadenoma.

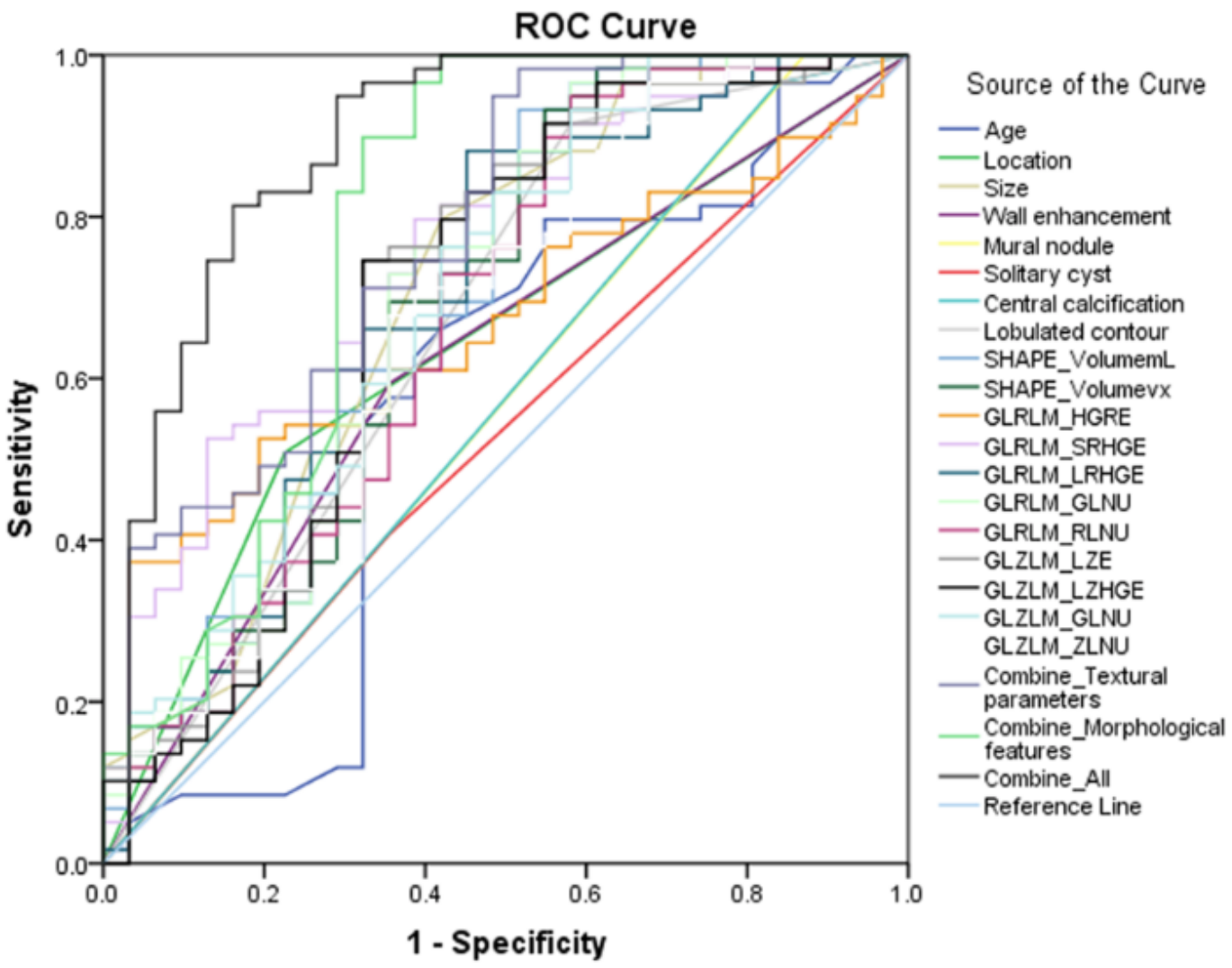

Figure 2

Receiver Operating Characteristic (ROC) analysis of textural features. The area under the receiver operating characteristic curve: age, 0.568 (0.430-0.706); location (head or neck vs body or tail), 0.641 (0.523-0.759); size, 0.710 (0.590-0.830); wall enhancement, 0.619 (0.497-0.741); mural nodule, 0.565 (0.435-0.694); solitary, 0.526 (0.400-0.652); central calcification, 0.564 (0.435-0.693); lobulated contour, 0.667 (0.542-0.793); SHAPE_Volume (mL), 0.700 (0.580-0.821); SHAPE_Volume (# vx), 0.685(0.563-0.808); GLRLM_HGRE, 0.672 (0.562-0.781); GLRLM_SRHGE, 0.756 (0.652-0.859); GLRLM_LRHGE, 0.682 (0.559-0.805); GLRLM_GLNU, 0.701 (0.580-0.821); GLRLM_RLNU, 0.671 (0.548-0.794); GLZLM_LZE, 0.698 (0.575-0.822); GLZLM_LZHGE, 0.692 (0.567-0.817); GLZLM_GLNU, 0.704 (0.587-0.820); GLZLM_ZLNU, 0.668 (0.547-0.790); combination of textural parameters, 0.777 (0.673-0.880); combination of morphological features, 0.783 (0.665-0.900); combination of textural parameters and morphological features, 0.893 (0.816-0.970).

Supplementary Files

This is a list of supplementary files associated with this preprint. Click to download.

- supplement1.docx