Biometric indicators of Eyes with Occult Lens Subluxation inducing Secondary Acute Angle Closure

Xiaoli Xing (xxlteh@126.com)
Tianjin Medical University Eye Hospital https://orcid.org/0000-0002-7381-0413

Liangyu Huang
Tianjin Medical University Eye Hospital

Fang Tian
Tianjin Medical University Eye Hospital

Yan Zhang
Tianjin Medical University Eye Hospital

Yingjuan Lv
Tianjin Medical University Eye Hospital

Wei Liu
Tianjin Medical University Eye Hospital

AihuaLiu Liu
Tianjin Medical University Eye Hospital

Research article

Keywords: Lens subluxation; Acute angle-closure; Biometry; Anterior chamber depth; Lens thickness; Axial length

Posted Date: October 15th, 2019

DOI: https://doi.org/10.21203/rs.2.432/v3

Version of Record: A version of this preprint was published at BMC Ophthalmology on March 5th, 2020. See the published version at https://doi.org/10.1186/s12886-020-01355-7.

Abstract

Background : To compare the anterior biometry of eyes with secondary acute angle closure induced by occult lens subluxation (LS), misdiagnosed as acute primary angle closure (APAC) (ASAC-LS) at the first visit, APAC, chronic primary angle closure glaucoma (CPACG), cataract. Methods : This retrospective case study included 17 eyes with primary angel closure(PAC)due to occult LS, who were misdiagnosed as APAC on their first visit, 56 eyes diagnosed as APAC, 54 eyes diagnosed as CPACG, and 56 eyes diagnosed as cataract. Axial length (AL), central corneal thickness (CCT), anterior chamber depth (ACD) , aqueous depth (AD) and lens thickness (LT) were recorded. Lens position (LP), relative lens position (RLP), corrected lens position (CLP) were calculated. Quantitative data were subject to one-way analysis of variance and correlation analysis. Categorical data were analyzed using the chi-squared test. Receiver operating characteristic (ROC) curves were plotted to obtain a suitable cutoff value of ocular biometry. Results: The patients in the ASAC-LS group had a longer ocular axial length than those with acute angle closure and CPACG. Corneal thickness in the ASAC-LS group was not significantly different from that in the APAC group, but was significantly different from those of the CPACG and cataract group. The APAC group had the smallest ACD, while the ASAC-LS group had the smallest AD. The ASAC-LS group exhibited significantly shallower AD ($P<0.01$). The ASAC-LS group had the largest lens thickness. According to ROC curve analysis,RLP, ACD, AD, LP, CLP, CCT were high power of discrimination. Conclusions: This study revealed that LS secondary PAC patients had a shallower AD, thicker CCT comparing to those of APAC, CPACG and cataract patients. LP and CLP can be helpful for differential diagnosis.

Introduction

Lens subluxation (LS) refers to a common malposition of lens, whose pathological mechanism involves partial zonular dehiscence of lens, causing partial deviation of the lens from its original position. LS is a common cause of acute secondary angle closure. Acute angle closure is an ophthalmic emergency that can often lead to irreversible optic nerve damage and requires timely treatment to counteract elevated intraocular pressure (IOP) [1]. Acute secondary angle closure induced by LS (ASAC-LS) is very similar to acute primary angle closure (APAC). They both manifest as acute attacks including severe pain in the eye, headache, ocular hypertension, and shallow anterior chamber. Nonetheless, the clinical manifestations of occult LS are atypical, with insignificant signs of iridodonesis and phacodonesis. When acute secondary angle closure is misdiagnosed as APAC, miotic agents would be administered, and trabeculectomy may even be performed. However, if correct diagnosis can be made before the surgery, appropriate treatments would be applied according to the patients’ condition, thereby increasing the success rate of the surgery and the recovery of visual function [2].

The biometric characteristics of patients with APAC include small corneal diameter, short ocular axial length, shallow central and peripheral anterior chamber[3, 4], lens thickening [5], and anterior displacement of the lens. To this end, we analyzed anterior segment biometric characteristics in a group of patients with ASAC-LS, and compared these biometric characteristics with the patients with APAC and

chronic primary angle closure glaucoma (CPACG). It is hoped that this study can be helpful for the diagnosis and differential diagnosis of these ocular diseases.

Methods

This retrospective case study included 17 eyes of 17 patients with ASAC-LS (7 left eyes and 10 right eyes), who were misdiagnosed as APAC on their first visit. All of the patients were admitted from Jan 10, 2016 to Dec 28, 2017 in Tianjin Medical University Hospital. In addition, sample size of the control groups was calculated and comparing with with the ASAC-LS group, we chose 3:1 ratio. Clinical features and demographic of the patients were retrieved from the patient's medical records from Jan 10, 2016 to Mar, 2016. 56 eyes of 56 patients diagnosed with APAC, 54 eyes of 54 patients diagnosed with CPACG, and 56 eyes of 56 patients diagnosed with cataract inpatients were also consecutively included (All the patients had vision in both eyes). This study was conducted in accordance with the Helsinki Declaration and was approved by the Ethics Committee of Tianjin Medical University Eye Hospital.

ASAC-LS was diagnosed according to the following criteria, including sudden pain in the eye, decreased vision with or without nausea and vomiting. Slit lamp microscopy reveals phacodonesis, lens inclination or vitreous herniation into the anterior chamber, central and peripheral shallow anterior chamber, and asymmetric iris bulge. The diagnosises of LS were confirmed during the surgery. The range of lens zonula dehiscence was recorded during subsequent surgery, with the average of 5 ± 2.24 o'clock lens zonula dehiscence.

APAC was diagnosed with the following criteria[6-8], including substantially elevated IOP and closed angle, acute eye pain, blurred vision, or nausea and vomiting. More importantly, ischemic injury caused by acute ocular hypertension, ciliary or mixed congestion, corneal edema, and glaucoma flecks should be detected.

The diagnostic criteria of CPACG included narrow angle with anterior synechiae of varying widths, IOP > 22 mmHg, and glaucomatous optic disc damage and visual field shrinkage [9-11]. The angle closure should be more than two quadrants, yet there was no ischemic injury in the anterior segment caused by acute ocular hypertension.

Exclusion criteria were history of laser peripheral iridotomy or peripheral iridectomy, glaucoma filtration surgery, angle closure caused by ocular trauma, uveitis, myopia (more than -3D), neovascularization or intumescent swelling or hypermature lens. The patients with acute angle closure in both eyes were excluded. The subjects in which Lenstar LS 900 (Haag-Streit USA, INC., USA) examination could not be performed because of severe lens opacity or corneal edema were also not included in the study.

All patients underwent visual acuity and slit lamp examinations, Goldmann IOP measurements, fundus examinations, Goldmann gonioscopy, Lenstar LS900 biometric measurements. Ocular biometric measurements included ocular axial length (AL), central corneal thickness (CCT), aqueous depth (AD, depth from the endothelium of the cornea to the anterior surface of the lens), anterior chamber depth

(ACD, depth from the epithelium of the cornea to the anterior surface of the lens, equal to CCT+AD), and lens thickness (LT). Ultrasound biomicroscope (UBM) examinations were performed by an experienced ophthalmologist as described in the literature [2] to evaluate the lens position. The following formulas were used to assess the biometric chataracters of the patients. Lens position (LP)= ACD+$^{1}/_{2}$LT. Corrected anterior chamber depth (CLP)= AD+1/2LT. Relative lens position (RLP)= [ACD +$^{1}/_{2}$LT] /AL ×10 [12]. To investigate the relevant factors of LS induced acute IOP elevation, we analysize the correlation of the AD and the range of lens zonula dehiscence statistically.

Statistical analysis

Statistical analysis was performed using SPSS version 18.0 (IBM Corporation, Armonk, NY, USA). Quantitative data were expressed as mean ± standard deviation. Quantitative data were subject to one-way analysis of variance and correlation analysis. Categorical data were analyzed using the Chi-squared test, and P<0.05 was considered to be statistically significant.

Receiver operating characteristic (ROC) curves were plotted to obtain a suitable cutoff value of ocular biometry to separate ASAC-LS patients from APAC. P-value < 0.05 was considered statistically significant.

Results

Table 1. Biometry parameters in groups

	Parameters				P value
	ASAC-LS	APAC	CPACG	Cataract	
Gender					0.025*
Male	11	12	16	20	
Female	7	44	38	36	
Age (y)	64.47±7.82	66.05±8.41	67.44±7.97	67.61±11.14	0.540
AL (mm)	23.23±0.68	22.42±0.77	22.56±0.92	23.47±1.30	0.000*
CCT (μm)	569.00±91.66	552.98±40.29	527.57±39.24	536.46±37.29	0.002*
AD (mm)	1.25±0.35	1.64±0.26	1.77±0.22	2.59±0.39	0.000*
ACD (mm)	2.49±0.56	2.21±0.26	2.33±0.32	3.13±0.39	0.000*
LT (mm)	5.13±0.41	4.97±0.30	4.92±0.30	4.48±0.41	0.000*
LP	4.39±0.32	4.69±0.21	4.79±0.33	5.37±0.27	0.0008
RLP	1.89±0.14	2.09±0.09	2.12±0.16	2.29±0.12	0.000*
CLP	3.82±0.33	4.13±0.21	4.23±0.19	4.83±0.28	0.000

*:P<0.05, **:P<0.01

As shown in Table 1, there were no statistically significant differences in terms of age among 4 groups. Except for AL and CCT, the differences of the other measured parameters between cataract group and each of other groups were statistically significant (P<0.05, respectively). As shown in Table 2，Compared with APAC group or CPACG group, the AL of cataract group was significantly longer, ACD and AD were significantly shallower, the value of LP, CLP and RLP were significantly smaller.

Further investigation with logistic regression analysis, the parameter AD and the range of lens zonula dehiscence showed the most dramatically statistical significance in all groups' individually comparison (P=0.034).

Table 2: Comparison of biometry parameters in different groups

	Mean difference (P-value)					
	APAC vs ASAC-LS	CATA vs ASAC-LS	CPACG vs ASAC-LS	CATA vs APAC	CPAC vs CPACG	CATA vs CPACG
AL	-0.80827(0.002) **	2.23638(0.902)	-0.66763(0.016) *	3.044643(0.000) **	-0.140642(0.945)	4.904001(0.000) **
CCT	16.01786(0.212)	32.53571(0.012) *	-21.42593(0.001) **	16.517857(0.214)	-4.708069(0.083) **	8.290212(0.780)
ACD	0.388887 (0.001) **	0.131764(0.000) **	-0.51779(0.000) **	-0.928750(0.000) **	-0.128902(0.127)	-0.799848(0.000)**
AD	0.398697 (0.002) **	0.246555 (0.000) **	-0.152756(0.000) **	-0.647857(0.000) **	-0.128862(0.035) *	-0.518995(0.000) **
LT	-0.17181(0.526)	0.65895(0.000) **	-0.22342(0.256)	0.487143(0.000) **	-0.051614(0.936)	0.435529(0.000)**
LP	0.305305 (0.000) **	0.998816(0.000) **	-0.40608(0.001) **	-0.682857(0.000) **	-0.100774(0.325)	-0.582083(0.000) **
CLP	0.31512(0.009) **	0.601708(0.000) **	-0.41585(0.001) **	-0.701964(0.000) **	-0.100734(0.058)	-0.601230(0.000) **
RLP	0.20384(0.000) **	0.4047594(0.000) **	-0.23708(0.000) **	-0.200923(0.000) **	-0.033242(0.678)	-0.167681(0.000) **

CATA: cataract; *:P<0.05, **:P<0.01

Table 3: Area under the receiver operating characteristic curve (AUROC), sensitivity, specificity, and cutoff value in ASAC-LS and APAC subjects.

	AUROC	Sensitivity, Specificity	Cutoff
CCT	0.506	0.857, 0.352	517
AD	0.827	0.718, 0.824	1.455
ACD	0.836	0.786, 0.765	1.985
LP	0.804	0.768, 0.824	4.5375
RLP	0.892	0.929, 0.824	1.9804
CLP	0.798	0.714, 0.765	4.0325

(LP= ACD+1/2LT, RLP= [ACD +1/2LT] /AL ×10, CLP= AD+1/2LT. $P<0.05$ was considered statistically significant).

Discussion

The main mechanism of PACG is considered as pupillary block. Increased resistance of aqueous humor flow between the iris and anterior lens surface leads to angle closure. A short axial length (AL) of the globe, thicker lens, anteriorly placed lens, are the main dangerous factors[13].

Traumatic or spontaneous lens dislocation can cause acute angle closure. The features of zonular instability include iridodonesis, decentration of the nucleus, phacodonesis, the lens equator exposure, and vitreous prolapse in the AC. In clinic, due to the risk of iatrogenic angle-narrowing and elevated intraocular pressure, angle-closed eyes usually do not undergo pharmacologic pupil dilation[14]. Due to relaxation or lens zonula dehiscence, the anterior capsule of the lens can attach or adhere to the posterior surface of the iris [1]. The lens and/or vitreous hernia can cause pupil block, leading to an increase in posterior chamber pressure; consequently, the iris is pushed against and closes the anterior angle, resulting in increased IOP. Its clinical manifestations are very similar to those of APAC and, thus, is prone to misdiagnosis. The literature also suggested that the major form of the secondary glaucoma associated with lens subluxation was the open-angle type[15].

We analyzed the clinical features of a group of patients with acute secondary angle closure due to lens dislocation, monocular onset, and acute anterior chamber shallowing. Compared with the APAC, CPACG, and cataract groups, the anterior chamber depth of patients with acute angle closure due to lens dislocation was significantly shallower, even less than 0.66mm. The result showed that AD was a sensitive indicator, because it was statisticlly significant in all groups' individually comparison. Therefore, whenever small anterior chamber depth is observed during clinical diagnosis of patients with APAC, it is necessary to devote attention to acute secondary angle closure caused by lens factors. It has been reported that the anterior chamber depth is significantly different between the involved eye and the contralateral eye in patients with acute angle closure due to LS[16]. The calculated parameters -LP, CLP and RLP also showed significant difference in multiple comparison results and also were sensitive indicators of four groups.

The RLP (AUROC: 0.892) , ACD (AUROC: 0.836), AD (AROC: 0.827) , LP (AUROC: 0.804), CLP (AUROC: 0.798), CCT (AUROC: 0.506) were high power of discrimination. LT in our study was not a sensitive value to distiguish APAC from ASAC-LS. While in primary angle closure patients, LT was a powerful value [12].

In this study, data from the contralateral eyes were incomplete; therefore, anterior chamber depth was not compared between the two eyes.

Patients with angle-closure glaucoma usually exhibit a shorter ocular axial length. However, the ocular axial length in the group of patients with acute angle closure caused by ASAC-LS was not significantly different from that in the cataract group, but was longer than that in the APAC and CPACG groups. It has been reported that LS patients have the longest ocular axial length among the population with acute angle closure. Other causes of acute angle closure include iris bombe, pupil block, and plateau iris [17-18].

Among the four groups of patients, lens thickness in the ASAC-LS group was the greatest, and was significantly different from that in the cataract and the CPACG groups; therefore, lens thickness was not sufficient to diagnose the four diseases. As a result, the parameter of lens position (LP) (defined as the sum of anterior chamber depth and ½ lens thickness) was introduced in this study. Calculations indicated that there was significant difference between any two groups. Some studies[19] in the literature used lens vault (defined as the perpendicular distance between the anterior lens pole and the horizontal line joining the two scleral spurs) measured using UBM as an indicator of lens morphology and found that lens vault increases in patients with unstable suspensory ligaments of the lens.

When the lens is subluxated, the lens zonule dehisence has a large effect on the position of the lens. In this group, the dehisence was recorded during surgery and was found to correlate with AD. Therefore, for occult LS, which does not have clear clinical manifestations and does not have a very high UBM diagnosis rate in our data.

The diagnostic accuracy was 98.0% with 25 MHz UBM and slightly subluxated lens eyes could be detected[20].

AD can be used as one of the indirect determinant indicators.

In summary, we retrospectively analyzed biometric characteristics of the anterior segment of patients with acute angle closure secondary to occult LS. Several points should be addressed during diagnosis and treatment. For younger patients with acute angle-closure glaucoma, it is necessary to exclude lens zonula relaxation caused by abnormal lens development; otherwise, the patients would be misdiagnosed with APAC rather than acute secondary angle-closure glaucoma due to lens dislocation and undergo peripheral iridotomy or glaucoma filtering surgery, which not only increases the risk for complications, such as intraoperative vitreous herniation, postoperative shallow anterior chamber and even malignant glaucoma, but also reduces the success rate of the operation. When applicable, UBM should be used to observe whether the suspensory ligament of the lens is severed or simply relaxed. The anterior chamber

depth should be measured: a short depth (< 1.25 mm) is highly indicative of abnormality in the lens zonula dehiscence or relaxation, and the depth should be compared with that of the contralateral eye. Lens thickness should be measured and, if it is > 5.13 mm, abnormal suspensory ligament of the lens should be suspected. Meanwhile, LP and CLP can be calculated for differential diagnosis.

Limitations of the present study include the absence of a biometric comparison of the lateral eyes in each group of patients. LS900 can only be used to measure the patients with no serious opacity of cataracts.

Conclusions

For patients with acute angle-closure glaucoma, it is necessary to exclude lens zonula relaxation. A short depth (< 1.25 mm) and a thick lens thickness (> 5.13 mm) are crisis of lens subluxation in our data. LP and CLP can be helpful for differential diagnosis between angle closed glaucoma and cataract.

List Of Abbreviations

LS: lens subluxation

IOP: intraocular pressure (IOP)

ASAC-LS: acute secondary angle closure induced by len subluxation

APAC: acute primary angle closure

CPACG: chronic primary angle closed glaucoma

CCT: central corneal thickness

AD: aqueous depth

ACD: anterior chamber depth

LT: lens thickness

UBM: ultrasound biomicroscope

LP: lens position

CLP: corrected anterior chamber depth

RLP: relative lens position

AL: axial length

CATA: cataract

Declarations

Ethics approval

This research followed the tenets of the Declaration of Helsinki, informed consent was obtained from the subjects after explanation of the nature and possible consequences of the study and proof of publication. This study was approved by the ethics committee of Tianjin Medical University Eye Hospital.

Consent for publication

Written consent for publication was obtained from the participants.

Availability of data and material

The datasets used and/or analysed during the current study are available from the corresponding author on reasonable request.

Competing interests

The authors declare that they have no competing interests.

Funding

This work was supported by grants from Natural Science Foundation of Tianjin Medical University (2016KYZM16), Scientific and Clinical Research Fund of Ophthalmology Institute of Tianjin Medical University Eye Hospital (15YKYJS001).

Authors' contributions

X.X.L. designed and supervised the study; H.L.Y. analyzed data; L.W, L.Y.J and T.F. drafted the manuscript; L.A.H. performed research; all authors read and approved the final manuscript.

Acknowledgements

Special thanks to Richard Lee, Jin Yang, Yuan Liu from Bascom Palmer eye institute for valuable discussions of the paper.

References

1. Lee JW, Wong BK, Yick DW, Wong IY, Yuen CY, Lai JS. Primary acute angle closure: long-term clinical outcomes over a 10-year period in the Chinese population. Int Ophthalmol. 2014; 34:165-9.
2. Suwan Y, Jiamsawad S, Tantraworasin A, Geyman L, Supakontanasan W, Teekhasaenee C. Qualitative and quantitative evaluation of acute angle-closure mechanisms. BMC Ophthalmol. 2017; 17:246.

3. Lowe RF, Clark BA. Posterior corneal curvature. Correlations in normal eyes and in eyes involved with primary angle-closure glaucoma. Br J Ophthalmol. 1973; 57: 464-70.
4. Lowe RF. Aetiology of the anatomical basis for primary angle-closure glaucoma. Biometrical comparisons between normal eyes and eyes with primary angle-closure glaucoma. Br J Ophthalmol. 1970; 54:161-9.
5. Tarongoy P, Ho CL, Walton DS. Angle-closure glaucoma: the role of the lens in the pathogenesis, prevention, and treatment. Surv Ophthalmol. 2009; 54:211-25.
6. Foster PJ, Buhrmann R, Quigley HA, Johnson GJ. The definition and classification of glaucoma in prevalence surveys. Br J Ophthalmol. 2002; 86:238-42.
7. Cheng JW, Zong Y, Zeng YY, Wei RL. The prevalence of primary angle closure glaucoma in adult Asians: a systematic review and meta-analysis. PLoS One 2014; 9:e103222.
8. Mancil RM, Mancil GL, King E, Legault C, Munday J, Alfieri S, et al. Improving nighttime mobility in persons with night blindness caused by retinitis pigmentosa: A comparison of two low-vision mobility devices. J Rehabil Res . 2005; 42:471-86.
9. Weinreb RN, Aung T, Medeiros FA. The pathophysiology and treatment of glaucoma: a review. JAMA. 2014; 311:1901-11.
10. Bian AL, Zhao JL, Zhou Q, Zhang Y, Liu XL, Mao J. [Long-term outcomes of laser peripheral iridectomy for primary angle closure glaucoma]. Zhonghua Yan Ke Za Zhi. 2009; 45:1099-104.
11. Mok KH, Lee VW. Synechial angle closure pattern in Chinese chronic primary angle-closure glaucoma patients. J Glaucoma. 2001;10:427-428.
12. Razeghinejad MR, Banifatemi M. Ocular biometry in angle closure. J Ophthalmic Vis Res. 2013;8 (1):17-24.
13. Allingham RR, Freedman SF, Moroi SE, Rhee DJ, Shields MB. Shields Textbook of Glaucoma. Philadelphia: Wolters Kluwer Health; 2012.
14. Arimura S, Takamura Y, Takihara Y, Matsumura T, Tomomatsu T, Inatani M. Determinants of anterior chamber angle narrowing after mydriasis in the patients with cataract. Graefes Arch Clin Exp Ophthalmol. 2015;253: 307-12.15.
15. Inatani M, Tanihara H, Honjo M, Kido N, Honda Y. Secondary glaucoma associated with crystalline lens subluxation. J Cataract Refract Surg. 2000; 26:1533-6.
16. Atalay E, Nongpiur M E, Baskaran M, Sharma S, Perera S A, Aung T. Biometric Factors Associated With Acute Primary Angle Closure: Comparison of the Affected and Fellow Eye. Invest Ophthalmol Vis Sci. 2016;57:5320-25.
17. Moghimi S, Zandvakil N, Vahedian Z, Mohammadi M, Fakhraie G, Coleman AL, et al. Acute angle closure: qualitative and quantitative evaluation of the anterior segment using anterior segment optical coherence tomography. Clin Exp Ophthalmol.2014; 42: 615-22.
18. Luo L, Li M, Zhong Y, Cheng B, Liu X. Evaluation of secondary glaucoma associated with subluxated lens misdiagnosed as acute primary angle-closure glaucoma. J Glaucoma. 2013; 22: 307-10.

19. Kwon J, Sung K R. Factors Associated With Zonular Instability During Cataract Surgery in Eyes With Acute Angle Closure Attack. Am J Ophthalmol. 2017;183:118-24.
20. Shi M, Ma L, Zhang J, Yan Q. Role of 25 MHz Ultrasound Biomicroscopy in theDetection of Subluxated Lenses. J Ophthalmol. 2018; 17:2018:3760280.

Figures

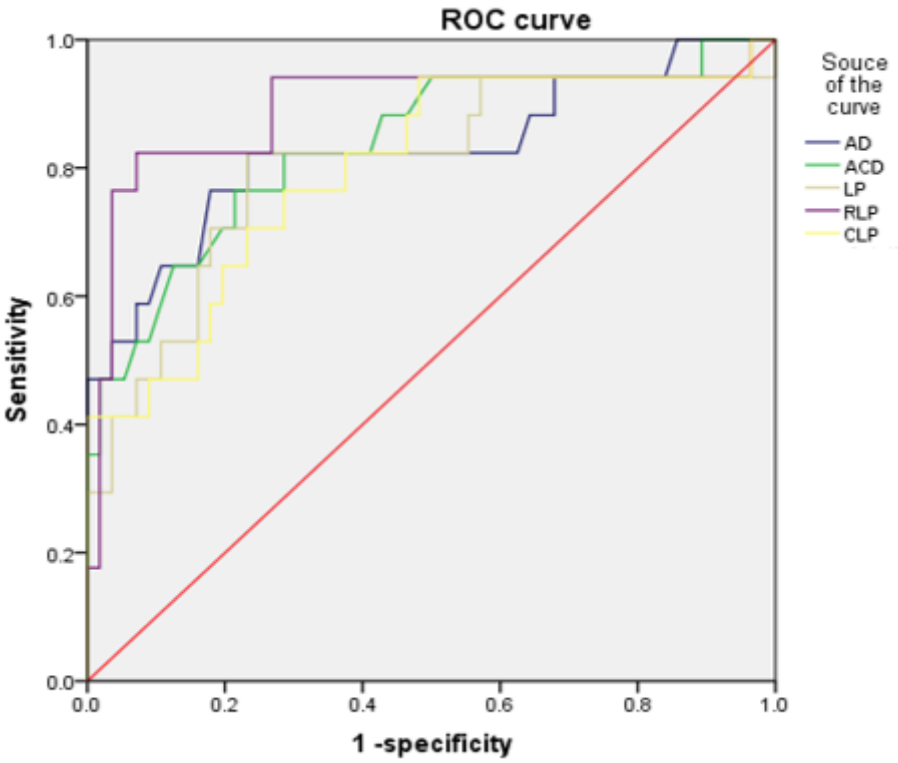

Figure 1

ROC curves plotting sensitivity against one-specificity. In our study, AD is the best value to distiguish APAC from ASAC-LS