Distally based peroneal artery perforator-plus fasciocutaneous flap in the reconstruction of soft tissue defects over the distal forefoot: a retrospectively analyzed clinical trial

Ping Peng
Second Xiangya Hospital
Zhaobiao Luo
Second Xiangya Hospital
Guohua Lv
Second Xiangya Hospital
Jiangdong Ni
Second Xiangya Hospital
Jianwei Wei
Second Xiangya Hospital
Zhonggen Dong (doctordong@csu.edu.cn)
the Second Xiangya Hospital Central South University https://orcid.org/0000-0002-3457-6425

Research article

Keywords: ankle, forefoot, surgical flaps, peroneal artery, perforator flap

Posted Date: July 21st, 2020

DOI: https://doi.org/10.21203/rs.3.rs-43530/v1

Version of Record: A version of this preprint was published on October 21st, 2020. See the published version at https://doi.org/10.1186/s13018-020-02019-4.

Abstract

Background: Distally based peroneal artery perforator-plus fasciocutaneous (DPAPF) flaps are widely used for reconstructing soft-tissue defects of the lower extremity. However, large studies on this topic, especially DPAPF flaps use for reconstruction of defects over the distal forefoot, are scarce. Herein, we describe our experience on the reconstruction of defects over the distal forefoot using DPAPF flaps.

Methods: Between February 2005 and August 2019, 56 DPAPF flaps were used to reconstruct soft-tissue defects in the forefoot. The ankles were fixed in dorsiflexion using a Kirschner wire. Patient factors and flap factors were compared between the “survival” and “partial necrosis” groups.

Results: Overall, 47 flaps had survived completely in one stage. Partial necrosis developed in nine flaps, with only one remnant defect covered using a local flap. The distance between the pivot point and recipient area was reduced by fixing the ankles in dorsiflexion. The partial necrosis rate of the DPAPF flaps with the top edge located in the 8th zone was significantly lower than that in the 9th zone ($p < 0.05$).

Conclusions: In combination with fixing of the ankles in dorsiflexion using a Kirschner wire, DPAPF flap is a good option in reconstructing a defect over the distal forefoot.

Introduction

Although modern medicine is evolving rapidly, covering soft-tissue defects in the lower extremities remains a clinical challenge. The reverse sural artery flap was first described by Masquelet et al. [1]. Free flap transfer and pedicle perforator flap transfer are currently widely performed. However, owing to the advantages such as reliability, simplicity, and no need for microvascular anastomosis, the distally based sural flap is an excellent option and widely utilized in reconstructive surgery for covering defects in the lower extremities [2–4].

Generally, the forefoot is defined as the area of the foot beyond the tarsometatarsal joints. The forefoot has the following unique peculiarities: the skin and soft tissues are thinner and non-elastic; the mobility is limited; it is important for ambulation; and it is difficult to perform vascularization in this area [5, 6]. After an open injury of the forefoot, the wound usually includes exposure of the tendons, joints, and bones. Clinical treatment is difficult through covering the defect in this area; amputation is sometimes needed in severe cases, which leads to great pain and shock to the patient's mental and physical health. Some authors have reported successfully covering the defect in small patient populations over the distal forefoot using the distally pedicled sural fasciocutaneous flap [3, 6]. However, there are no reports on the reconstruction of these defects using the flap in a large sample size. Therefore, we describe our experience on the reconstruction of the defects over the distal forefoot using the distally based peroneal artery perforator-plus fasciocutaneous (DPAPF) flap in a considerable sample size.

Methods

We retrospectively reviewed the cases of soft-tissue defect reconstruction over the distal forefoot using DPAPF flaps. Between February 2005 and August 2019, 56 patients underwent surgeries at our hospital. They provided written informed consent for publishing the treatment and follow-up data. Approval was obtained from the ethics committee of Central South University. The procedures used in this study adhere to the tenets of the Declaration of Helsinki.

Before the surgery, the patients underwent routine examinations and health status assessments. Color Doppler ultrasonography was performed to assess the quality of the peroneal artery and mark the location of the peroneal artery perforator. We excluded patients in whom the defects were due to diabetes mellitus (DM) or peripheral vascular disease (PVD). We also excluded those in whom the defects were repaired using a perforator pedicle-based sural flap.

In this study, the farthest point of the defects repaired using DPAPF flaps lay in the distal forefoot, which was defined as the area beyond the midpoint of the metatarsal bones. The possible risk factors [7]—including patient and flap factors—for partial necrosis of the flaps were analyzed. The degree of satisfaction with the flap appearance was classified as satisfied and unsatisfied. In patients with more than 6 months of follow-up postoperatively, the reconstruction outcomes of the flaps were assessed according to the criteria described previously [8].

Operative technique

Thorough debridement is the most important step in the management of such defects. Before designing the flap, the ankle was fixed in dorsiflexion using a Φ2.0 or Φ3.0 Kirschner wire. The procedure was helpful in shortening the distance from the pivot point to the recipient area (Fig. 1). After designing the DPAPF flap, the perforator located at the pivot point was explored. Other harvest procedures have been described in detail elsewhere [9]. The small saphenous vein should be included in the flap because it contributes to the survival of the flap [4]. Because of the non-elastic skin over the dorsum of the foot, the passage from the pivot point to the defect was incised through the lateral approach and a skin strip was designed overlying the adipofascial pedicle to decrease the compression of the subcutaneous tunnel and the pedicle [6, 10]. All the donor sites of the DPAPF flaps were resurfaced with skin grafts. Three weeks after the operation, the Kirschner wire was removed.

Statistical analysis

All the data were analyzed using the statistical software package SPSS (Version 17.0; SPSS Inc., Chicago, IL). Data of the continuous variables were analyzed using Student's *t*-test and expressed as mean ± standard deviation. The categorical data were analyzed using Fisher's exact test and expressed as a constitute ratio. $P < 0.05$ was considered to indicate statistical significance.

Results

The average age of the patients was 37.4 years (range: 2–81). The defects were mainly caused by trauma (87.5%, 49/56), while the non-traumatic causes included chronic osteomyelitis (n = 6) and soft-tissue tumor (n = 1). The constitute ratios of patient factors (Table 1) and continuous variables of the DPAPF flaps (Table 2) did not show significant differences between the survival and partial necrosis flap groups ($p > 0.05$).

Table 1
Demographic and clinical characteristics of the patients in both groups.

Variable	**Survival Flaps (n = 47) N (%)**	**Partial Necrosis Flaps (n = 9) N (%)**	***p****
Age (years)			0.725
≤ 40	25 (86.2)	4 (13.8)	
> 40	22 (81.5)	5 (18.5)	
Sex			0.385
Male	38 (86.3)	6 (13.6)	
Female	9 (75.0)	3 (25.0)	
Etiology of the defect			0.583
Trauma	40 (81.6)	9 (18.4)	
Non-traumatic	7 (100.0)	0 (0.0)	

* Fisher's exact test

Table 2
Comparisons of continuous variables in both groups

Parameters*	**Survival Flaps (n = 47)**	**Partial Necrosis Flaps (n = 9)**	***t***	***p***
Fascial pedicle (cm)				
Length	10.52 ± 3.86	8.89 ± 4.57	1.130	0.264
Width	4.30 ± 0.57	4.17 ± 0.35	0.666	0.508
Skin island (cm)				
Length	13.06 ± 3.61	13.44 ± 3.14	-0.295	0.769
Width	8.87 ± 1.67	9.28 ± 2.06	-0.639	0.526
Total length (cm)	23.59 ± 4.18	22.33 ± 4.52	0.813	0.420
Length-to-width ratio	5.52 ± 0.92	5.36 ± 1.02	0.464	0.645
*The values are expressed as mean ± standard deviation.				

Of the 56 flaps, partial necrosis was observed in nine (16.1%) cases. There was no case of complete necrosis of the flap. The only remnant defect (1.8%) was repaired using a local flap. Six remnant defects were successfully repaired using skin grafting, and in two other cases, the remnant defects were repaired with secondary suturing.

The pivot points of the DPAPF flaps were located at 3.5-9.0 cm above the tip of the lateral malleolus. Length-to-width ratio (LWR) ≥ 5:1 and skin island width ≥ 8 cm were found in 82.1% (46/56) and 76.8% (43/56) of the overall DPAPF flaps, respectively. The constitute ratios of these indicators did not show any significant difference ($p > 0.05$) between the partial necrosis and survival flap groups (Table 3).

Table 3
Comparisons of the constituent ratios of pivot point, length-width ratio (LWR), width of the skin island, and top-edge location

	Survival Flaps (n = 47) N (%)	**Partial Necrosis Flaps (n = 9) N (%)**	***p****
Pivot point (above the tip of the lateral malleolus)			1.000
≤7 cm	41 (83.7)	8 (16.3)	
>7 cm	6 (85.7)	1 (14.3)	
Length-to-width ratio			0.656
< 5:1	8 (80.0)	2 (20.0)	
≥5:1	39 (84.8)	7 (15.2)	
Width of the skin island			1.000
<8 cm	11 (81.8)	2 (18.2)	
≥8 cm	36 (83.7)	7 (16.3)	
Top-edge location			0.005
8th zone	35 (94.6)	2(5.4)	
9th zone	12 (63.2)	7(36.8)	
* Fisher's exact test			

When without fixation of the ankle in dorsiflexion, there were 10 DPAPF flaps with the top edge lying above the popliteal fossa crease; while the remaining most flaps had the top edge would located in the 9th zone. However, by fixing the ankles in dorsiflexion, the length of the fascial pedicle was reduced to approximately 2.35 ± 0.58 cm (range: 1.5–3.5), the total length of the flap was simultaneously shortened by the same amount as the length of the fascial pedicle. In the present study, the top edge of all the flaps was located in the 8th zone (66.1%, 37/56) or the 9th zone (33.9%, 19/56) of the calf. Partial necrosis rate of the DPAPF flaps in the 8th zone was significantly lower than that in the 9th zone ($p = 0.005$) (Table 3).

The average elevation time for the DPAPF flaps was approximately 33 minutes. The average area of the skin island was 119.7 cm^2 (range: 8 × 5.5 cm^2-22 × 13 cm^2). The donor sites of all the flaps were covered with a free skin graft. During a mean postoperative follow-up of 17.2 months (range: 2 weeks-119 months), no infection or skin necrosis was observed at the donor or recipient sites. The sensation on the lateral aspect of the foot was relatively preserved and none of the patients complained of the loss of sensation. There were no neurotrophic ulcers. There were no cases of unacceptable pain or atrophy in the ankle.

A total of 44 (78.6%) patients in the study were satisfied with the flap appearance (Fig. 2). There were 48 (85.7%) flaps with more than 6 months of follow-up postoperatively. The reconstruction outcomes of the 48 flaps were evaluated, which were excellent in 38 cases, good in eight cases, and fair in 2 cases (Fig. 3).

Discussion

Mehrotra et al. were the first to describe a perforator-plus flap in detail [11]. The DPAPF flap is similar to the distally pedicled sural fasciocutaneous flap in some features. However, the unique characteristics of the DPAPF flap are as follows: 1) a sizable perforator from the peroneal artery is located at the pivot point, and the flap receives dual blood supply and venous outflow; and 2) the role of the perforator is dominant [11, 12]. However, the reliability of these flaps remains the main concern. The highest necrosis (including complete and partial) rate of the distally based sural flap was 35.7% (25/70) [10]. In the last decade, various necrosis rates of the distally based sural flap in studies with relative large sample sizes ($n \geq 40$) were reported to be 3.9% (2/51) by As'adi et al. [13], 8.3% (13/156) by Gill et al. [4], 8.8% (9/102) by Dhamangaonkar et al. [14], 11.8% (9/76) by Herlin et al. [15], 17.2% (15/87) by Raza et al. [16], 20.5% (9/44) by Dai et al. [17], 22.3%(33/148) by Schmidt et al. [18], 30.6%(36/85) by Perumal et al. [19]. In the present study, the sample size was relatively large and there were no cases of complete necrosis of the flap. The partial necrosis rate was 16.1% (9/56), and only one (1.7%) remnant defect was covered with a local flap. Forty-seven (83.9%) flaps completely survived within one stage, while the other eight (14.3%) defects were reconstructed using the DPAPF flaps with simple skin grafting or suturing in the second stage. The results suggest that the DPAPF flaps are relatively reliable for reconstructing the defects in the distal forefoot. Once partial necrosis of the flap occurred, the remnant defects in most cases were covered successfully with a simple procedure. The DPAPF flap is particularly suited for the reconstruction of the defects over the distal forefoot for physicians who are not experienced with using free flaps or patients who are not eligible for undergoing reconstruction with a free flap [20, 21].

Forefoot is defined as the area beyond the tarsometatarsal joint, and it is of great importance in ambulation; however, performing vascularization of this area is frequently challenging [5]. The distal forefoot—the forefoot beyond the midpoint of the metatarsal bones—includes the weight-bearing area. The defects over the distal forefoot are more distal than those over other parts of the foot. Covering the soft tissue defects in this region is difficult. Some authors considered that the defects of the middle foot or the distal foot were covered restrictedly by the distally based sural flaps [22, 23]. However, the defects in the region were successfully managed with the distally based sural flap in small simple sizes [2, 3, 6, 24, 25]. The cross-leg flap for that reconstruction of the defects over the distal forefoot is another safe alternative [26, 27]. However, the patients who receive the cross-leg flap have require addition nursing care and face difficulties in daily activities, which results in unavoidable reoperations. This will result in increased hospitalization costs, time to recovery, and psychological burden on the patients. Most of the pedicled or local flaps are difficult. This will result in increased hospitalization costs, time to recovery, and psychological burden on the patients. Most of the pedicled or local flaps are difficult to satisfy the requirements of regional repair because of confined dimensions and the rotating arc [5]. Free tissue transfer is an efficient way to reconstruct the defects of the distal forefoot, and it can be used to

reconstruct larger defects as well [28]. However, the procedure has some disadvantages, such as time limitation, requirement of additional equipment, increased technical complexity, sacrifice of the main vessel, trained microsurgeons and teams, postoperative monitoring requirements, and the need for a relatively longer learning curve [6, 20].

Some authors have reported the repair of defects over the distal forefoot using the distally based sural island flap, with the pivot point being 5–7 cm above the lateral malleolus [6, 29, 30]. However, other authors consider that the defects in the region should be covered with flaps with lower pivot points [13, 21]. The higher the pivot point is, the longer is the flap needed. In the present study, only three pediatric flaps were designed with the pivot points under 5 cm above the tip of the lateral malleolus. Seven flaps were designed with the pivot point above 7 cm from the tip of the lateral malleolus, while the pivot points of other flaps lay between 5 cm and 7 cm. Fixing the ankle in dorsiflexion with a Kirschner wire was the key point in this approach because it reduced the distance from the pivot point to the recipient area, which subsequently reduced the length of the fascial pedicle. Because the shape of the skin island was not changed, the total length of the DPAPF flap was also shortened as much as the length of the fascial pedicle.

The potential risk factors for necrosis of the DPAPF flaps, including patient and flap factors, were analyzed. The constitute ratios of the patient factors and continuous variables of the DPAPF flaps were comparable between the survival flaps and partial necrosis flaps ($p > 0.05$). It remains controversial if the age, smoking status, and history of DM and peripheral arterial disease (PAD) affect the survival of the flap [2, 10, 20, 31, 32]. Some authors reported that smoking was the strongest association with flap failure [20, 31]. In the present study, the patients were advised smoking cessation since admission to the hospital. Based on our experience, we suggest that the DPAPF flap is not suitable for defects arising due to severe DM or PAD.

Partial necrosis rates of reverse sural artery flaps were reported to increase significantly when the flaps had an LWR of 5:1 or greater, skin island width ≥ 8 cm, or the top edge of the flap was located in the 9th zone [7]. In the current study, the proportions of the aforementioned first two unfavorable conditions were 82.1% and 76.8%, respectively. However, compared with the survival flaps, the constitute ratios of the first two indicators were not significantly different in the partial necrosis flaps ($p > 0.05$). The top edge of the flap was a relevant factor that was associated with partial necrosis. In the present study, the top edge of all the flaps was located in the 8th zone (66.1%) or the 9th zone (33.9%). The partial necrosis rate of the DPAPF flaps located in the 8th zone (5.4%) was significantly lower than that of the flaps located in the 9th zone (36.8%) ($p < 0.05$). These findings suggest the following: (1) nearly a third of the DPAPF flaps with the top edge in the 9th zone, and the proportion of two other unfavorable conditions also is higher, the outcome of the DPAPF flaps for repairing the defects over the distal forefoot is acceptable; (2) when utilizing DPAPF flaps for repairing the defects over the distal forefoot, the location of the top edge in the 9th zone was the most relevant factor associated with flap failure; and (3) the DPAPF flaps with the top edge in the 8th zone were safer and more reliable in repairing the defects of the distal forefoot. The total length of the DPAPF flap was reduced with ankle fixation in dorsiflexion, which reduced the number of

flaps with the top edge in the 9th zone. Therefore, this procedure can prevent complications of the flaps to some extent.

The upper boundary of the reverse sural fasciocutaneous flaps is controversial [4, 15]. Chen et al. suggested that the proximity limitation of the flap should not be beyond 6 cm from the popliteal crease [2]. Some authors have reported the highest location of the flap being 1–2 cm or 1.5-4 cm away from the popliteal crease [25, 33]. However, other authors have reported using flaps with the proximal border near the popliteal crease in repairing the defects of the forefoot [14, 34]. Mojallal et al. reported that including the sural nerve did not enhance the perfusion of the sural flap; however, it increased the arc of rotation, and the distance of “Surgical Unsafe Zone” from the popliteal crease was 4.6 cm [35]. A limitation of this conclusion was that the study included fresh adult cadaver legs. In another previous study, the posterior aspect of the calf was divided into nine zones (zones 1–9) to accurately assess the proximity limitation of the DPAPF flap [7]. In the present study, the upper boundary of a DPAPF flap was located at popliteal crease, and the flap survived completely. On the posterior calf, an average of 3.2 true anastomoses connect the perforators without change in the caliber, which are parallel to the sural nerve [36]. This could explain why the DPAPF flaps can survive longer and more reliably. However, the proportion of partially necrotic DPAPF flaps was significantly more in the 9th zone. Venous supercharging [15, 37], ligating the short saphenous vein distally in the pedicle [38], or delay technology [32, 39, 40] are the common methods used to improve the success rate of the flaps. It is definitely worth exploring how to improve the success rate of the DPAPF flaps under such conditions and identifying the best solution following analyses and comparisons.

The external fixation device is a device that prevents complications of distally based sural flaps and facilitates postoperative care [10, 41]. However, it requires an additional nail for external fixation nursing care during the postoperative fixation period. The external fixation device is more expensive in our country. Fixing the ankle with external fixation increases the financial burden on the patients. Pallua et al. introduced the concept of reconstructing the defects in the distal forefoot using pedicle flaps and fixing the feet using a cast [5]. We did not use this approach because of difficulties in changing the dressings and the high risk of pressure sores of the heel. In the present study, the ankle was fixed in dorsiflexion using a Kirschner wire, which is cheaper and requires a more convenient dressing and nursing care. There was no case of infection of the ankle or nail. After three weeks of the operation, the Kirschner wire was pulled out after confirming the stability of the flaps. The period of ankle fixation was short; therefore, the function of the ankle was not affected.

The mean duration of DPAPF flap elevation was approximately 30 minutes, which highlights that the flap can be elevated easily and quickly, and the defects over the distal forefoot can be covered without microsurgical techniques and sacrificing major arteries of the lower extremities. The disadvantage was that the donor sites were closed by resurfacing with a skin graft, which may be related to the relatively larger dimensions of the defects. Most of the patients in this study were satisfied with flap appearance. In the present study, although a follow-up of eight weeks or three months was enough [8, 17], we evaluated

the reconstruction outcomes of the DPAPF flaps over more than 6 months of follow-up. The reconstruction outcomes were very satisfactory with only 2/48 cases having evaluated fair outcomes.

To the best of our knowledge, this is the first study to introduce the reconstruction of the defects over the distal forefoot with DPAPF flaps with the largest number of patients. A randomized controlled trial was not possible because this study was a retrospective review, which is a major limitation of the study. Another limitation is that only 56 cases were included in the study. Further studies with larger same sizes are required to improve the success rate of DPAPF flaps in the reconstruction of defects over the distal forefoot.

Conclusions

DPAPF flaps combined with ankle fixation in dorsiflexion with Kirschner wire is a better choice in reconstructing the defects over the distal forefoot within one stage. The procedure is simple, efficient, and quick. The DPAPF flap is reliable with satisfactory reconstruction outcomes and patient satisfaction. The location of the top edge of the DPAPF flap was the most relevant factor associated with partial necrosis in the setting of covering the defects over the distal forefoot; the DPAPF flaps with the top edge in the 8th zone are safer and more reliable than that in the 9th zone in reconstructing the defects in the region.

Abbreviations

DPAPF: Distally based peroneal artery perforator-plus fasciocutaneous; DM: Diabetes mellitus; PVD: Peripheral vascular disease; LWR: Length-to-width ratio.

Declarations

Ethics approval and consent to participate

This study was approved by the medical ethics committee of the Second Xiangya Hospital Central South University. All patients involved in this study gave informed written consent to participate.

Consent for publication

Written informed consent were obtained from all participants.

Availability of data and materials

Not applicable

Competing interests

The authors declare that they have no competing interests.

Funding

National Natural Science Foundation of China, Grant/Award Number: 81672188; Health and Family Planning Commission of Hunan Province, Grant/Award Number: B20180313.

Authors' contributions

All authors have made substantial contributions. PP and ZBL contributed to the study design, collected the data, analyzed the data, and prepared the manuscript. GHL and NJD contributed to the study design and critically appraised the manuscript. JWW contributed to the data analysis and reviewed the literature. ZGD contributed to the study design and data analysis and was the chief investigator of the study. All authors contributed to data interpretation.

Acknowledgements

Not applicable.

References

1. 1. Masquelet AC, Romana MC, Wolf G. Skin island flaps supplied by the vascular axis of the sensitive superficial nerves: anatomic study and clinical experience. Plast Reconstr Surg. 1992;89:1115-21.
2. 2. Chen SL, Chen TM, Wang HJ. The distally based sural fasciomusculocutaneous flap for foot reconstruction. J Plast Reconstr Aesthet Surg. 2006;59:846 – 55.
3. 3. Grandjean A, Romana C, Fitoussi F. Distally based sural flap for ankle and foot coverage in children. Orthop Traumatol Surg Res. 2016;102:111-6.
4. 4. Gill NA, Hameed A. The sural compendium: reconstruction of complex soft-tissue defects of leg and foot by utilizing the posterior calf tissue. Ann Plast Surg. 2012;69:203-8.
5. 5. Pallua N, Di Benedetto G, Berger A. Forefoot reconstruction by reversed island flaps in diabetic patients. Plast Reconstr Surg. 2000;106:823-7.
6. 6. Lee HI, Ha SH, Yu SO, Park MJ, Chae SH, Lee GJ. Reverse sural artery island flap with skin extension along the pedicle. J Foot Ankle Surg. 2016;55:470-5.
7. 7. Wei JW, Dong ZG, Ni JD, Liu LH, Luo SH, Luo ZB, Zheng L, He AY. Influence of flap factors on partial necrosis of reverse sural artery flap: a study of 179 consecutive flaps. J Trauma. 2012;72:744 – 50.

8. 8. Boyden EM, Kitaoka HB, Cahalan TD, An KN. Late versus early repair of Achilles tendon rupture. Clinical and biomechanical evaluation. Clin Orthop Relat Res. 1995;317:150-8.
9. 9. Dong ZG, Wei JW, Ni JD, Liu LH, Luo ZB, Zheng L, He AY. Anterograde-retrograde method for harvest of distally based sural fasciocutaneous flap: report of results from 154 patients. Microsurgery. 2012;32:611-6.
10. 10. Baumeister SP, Spierer R, Erdmann D, Sweis R, Levin LS, Germann GK. A realistic complication analysis of 70 sural artery flaps in a multimorbid patient group. Plast Reconstr Surg. 2003;112:129 – 40.
11. 11. Mehrotra S. Perforator-plus flaps: a new concept in traditional flap design. Plast Reconstr Surg. 2007;119:590-8.
12. 12. Luo Z, Lv G, Wei J, Ni J, Liu L, Peng P, Dong Z. Comparison between distally based peroneal and posterior tibial artery perforator-plus fasciocutaneous flap for reconstruction of the lower extremity. Burns. 2020;46:225 – 33.
13. 13. As'adi K, Salehi SH, Shoar S. Early reconstruction of distal leg and foot in acute high-voltage electrical burn: does location of pedicle in the zone of injury affect the outcome of distally based sural flap? Ann Plast Surg. 2017;78:41 – 5.
14. 14. Dhamangaonkar AC, Patankar HS. Reverse sural fasciocutaneous flap with a cutaneous pedicle to cover distal lower limb soft tissue defects: experience of 109 clinical cases. J Orthop Traumatol. 2014;15:225-9.
15. 15. Herlin C, Bekara F, Bertheuil N, Carloni R, Dast S, Sinna R, Chaput B. Venous supercharging reduces complications and improves outcomes of distally based sural flaps. J Reconstr Microsurg. 2017;33:343 – 51.
16. 16. Raza MS, Nazir U, Ansari HH, Khan FA. Non-islanded distally based sural artery flap: a reliable solution for an unreliable flap. J Coll Physicians Surg Pak. 2016;26:310-4.
17. 17. Dai J, Chai Y, Wang C, Wen G, Liu S, Zhang W. Comparative study of two types of distally based sural neurocutaneous flap for reconstruction of lower leg, ankle, and heel. J Reconstr Microsurg. 2013;29:125 – 30.
18. 18. Schmidt K, Jakubietz M, Djalek S, Harenberg PS, Zeplin PH, Jakubietz R. The distally based adipofascial sural artery flap: faster, safer and easier? A long-term comparison of the fasciocutaneous and adipofascial method in a multimorbid patient population. Plast Reconstr Surg.2012;130:360-8.
19. 19. Perumal R, Bhowmick K, Reka K, Livingston A, Boopalan PRJVC, Jepegnanam TS. Comparison of reverse sural artery flap healing for traumatic injuries above and below the ankle joint. J Foot Ankle Surg. 2019;58:306 – 11.
20. 20. Daar DA, Abdou SA, David JA, Kirby DJ, Wilson SC, Saadeh PB. Revisiting the reverse sural artery flap in distal lower extremity reconstruction: a systematic review and risk analysis. Ann Plast Surg. 2020;84:463 – 70.

21. 21. Li Y, Xu J, Zhang XZ. Lowering the pivot point of sural neurofasciocutaneous flaps to reconstruct deep electrical burn wounds in the distal foot. Burns. 2013;39:808 – 13.
22. 22. Zhu YL, Wang Y, He XQ, Zhu M, Li FB, Xu YQ. Foot and ankle reconstruction: an experience on the use of 14 different flaps in 226 cases. Microsurgery. 2013;33:600-4.
23. 23. Chang SM, Li XH, Gu YD. Distally based perforator sural flaps for foot and ankle reconstruction. World J Orthop. 2015;6:322 – 30.
24. 24. Al-Qattan MM. A modified technique for harvesting the reverse sural artery flap from the upper part of the leg: inclusion of a gastrocnemius muscle "cuff" around the sural pedicle. Ann Plast Surg. 2001;47:269 – 74.
25. 25. Ayyappan T, Chadha A. Super sural neurofasciocutaneous flaps in acute traumatic heel reconstructions. Plast Reconstr Surg. 2002;109:2307-13.
26. 26. Zgonis T, Cromack DT, Stapleton JJ. Utilizing a crossover reverse sural artery flap for soft tissue reconstruction of the plantar forefoot after a severe degloving injury. Int J Low Extrem Wounds. 2007;6:114-9.
27. 27. Gözü A, Ozyiğit T, Ozsoy Z. Use of distally pedicled sural fasciocutaneous cross-leg flap in severe foot and ankle trauma: a safe alternative to microsurgery in very young children. Ann Plast Surg. 2005;55:374-7.
28. 28. Zhu YL, He XQ, Wang Y, Lv Q, Fan XY, Xu YQ. Traumatic forefoot reconstructions with free perforator flaps. J Foot Ankle Surg. 2015;54:1025-30.
29. 29. Jeng SF, Wei FC. Distally based sural island flap for foot and ankle reconstruction. Plast Reconstr Surg. 1997;99:744 – 50.
30. 30. Jeng SF, Wei FC, Kuo YR. Salvage of the distal foot using the distally based sural island flap. Ann Plast Surg. 1999;43:499–505.
31. 31. Parrett BM, Pribaz JJ, Matros E, Przylecki W, Sampson CE, Orgill DP. Risk analysis for the reverse sural fasciocutaneous flap in distal leg reconstruction. Plast Reconstr Surg. 2009;123:1499 – 504.
32. 32. Roberts HJ, DeSilva GL. Can sural fasciocutaneous flaps be effective in patients older than 65? Clin Orthop Relat Res. 2020;478:734-8.
33. 33. Hassanpour SE, Mohammadkhah N, Arasteh E. Is it safe to extract the reverse sural artery flap from the proximal third of the leg? Arch Iran Med. 2008;11:179 – 85.
34. 34. Pan HT, Zheng QX, Yang SH, Wu B, Liu JX. Versatility of reverse sural fasciocutaneous flap for reconstruction of distal lower limb soft tissue defects. J Huazhong Univ Sci Technolog Med Sci. 2014;34:382-6.
35. 35. Mojallal A, Wong C, Shipkov C, Bailey S, Rohrich RJ, Saint-Cyr M, Brown SA. Vascular supply of the distally based superficial sural artery flap: surgical safe zones based on component analysis using three-dimensional computed tomographic angiography. Plast Reconstr Surg. 2010;126:1240-52.

36. 36. Taylor GI, Chubb DP, Ashton, MW. True and “Choke” anastomoses between perforator angiosomes: Part I. Anatomical location. Plast Reconstr Surg. 2013;132:1447-56.
37. 37. Li B, Chang SM, Du SC, Zhuang L, Hu SJ. Distally based sural adipofascial turnover flap for coverage of complicated wound in the foot and ankle region. Ann Plast Surg. 2020;84:580-7.
38. 38. Herlin C, Sinna R, Hamoui M, Canovas F, Captier G, Chaput B. Distal lower extremity coverage by distally based sural flaps: Methods to increase their vascular reliability. Ann Chir Plast Esthet. 2017;62:45–54.
39. 39. Yousaf MA, Abidin ZU, Khalid K, Haq AU, Khalid FA, Tarar FA, Asif MU, Tarar MN. Extended islanded reverse sural artery flap for staged reconstruction of foot defects proximal to toes. J Coll Physicians Surg Pak. 2018;2:126-8.
40. 40. Cui Z, Zhang X, Shou J, Yin G. Repeated reverse sural fasciocutaneous flap is an effective surgical strategy for repairing long segmental soft tissue defects of the tibia. J Int Med Res. 2019;47:5003-9.
41. 41. Noack N, Hartmann B, Küntscher MV. Measures to prevent complications of distally based neurovascular sural flaps. Ann Plast Surg. 2006;57:37–40.

Figures

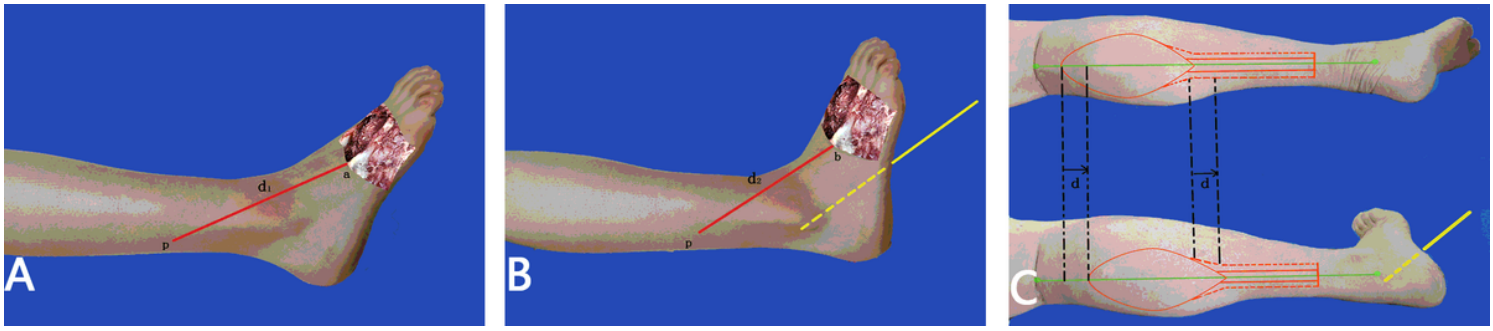

Figure 1

Schematic diagram of the DPAPF flap design in the two conditions. a The ankle is in a relaxed state. b The ankle is fixed in dorsiflexion using a Kirschner wire. The distance between the pivot point and the recipient area was shortened. c When the ankle is fixed in dorsiflexion using a Kirschner wire, the length of the adipofascial pedicle was reduced to “d” cm. Because the location of the pivot point and the shape of the skin island are constant, the total length of the flap also reduces to “d” cm. p: pivot point; point a or point b is where the defect is closest to the pivot point; d1 and d2 represent the shortest distances from the pivot point to the defect. d = d1 – d2. Yellow line: Kirschner wire.

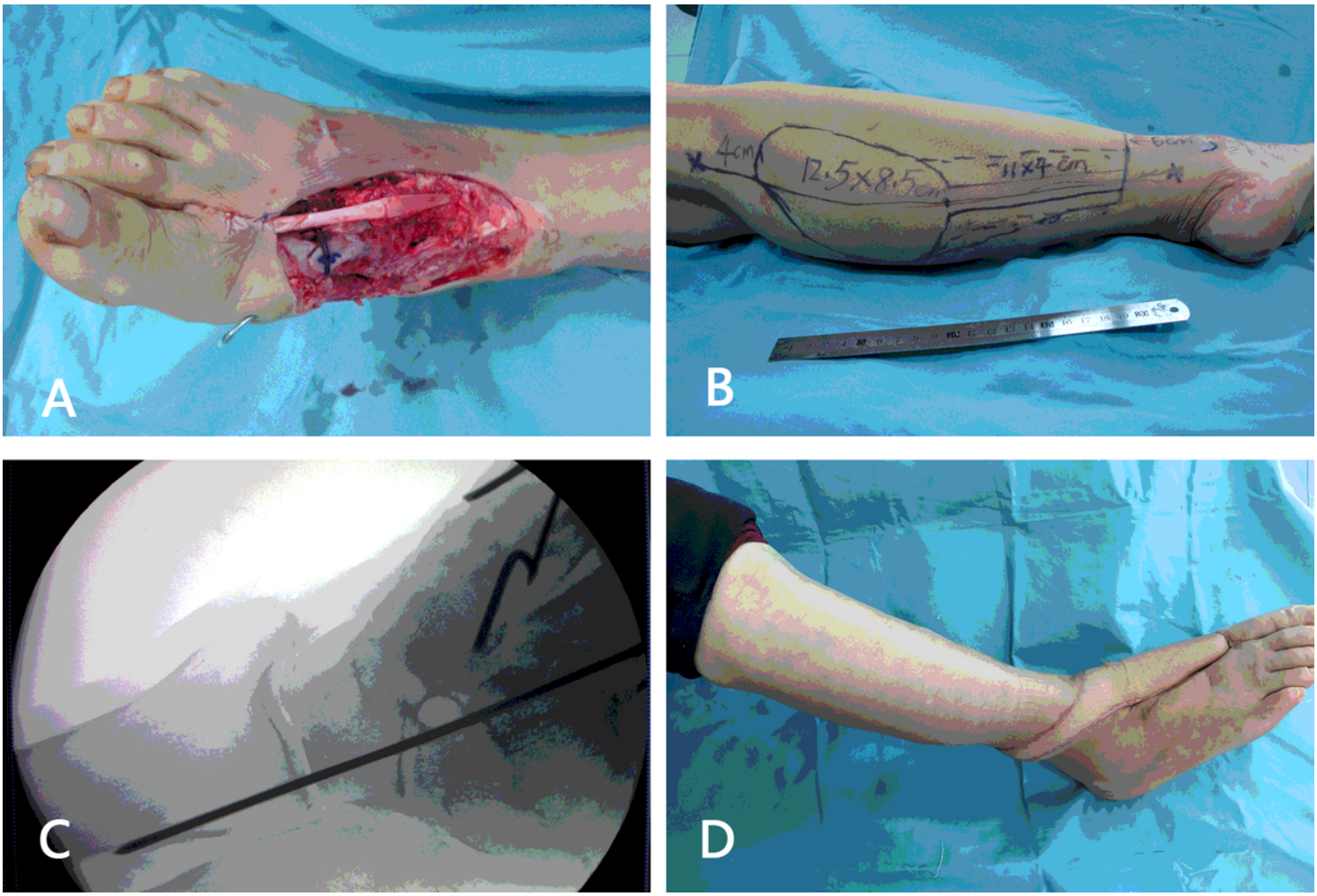

Figure 2

A 63-year-old woman had a traumatic soft-tissue defect over the distal forefoot. a Image of the defect after thorough debridement. The most distal part of the defect was beyond the midpoint of the metatarsal bone, which required reconstruction. b Design of a DPAPF flap. c Intraoperative fluoroscopy confirmed that the ankle was fixed in dorsiflexion with a Kirschner wire. d Outcomes of the flap at 17 months postoperatively.

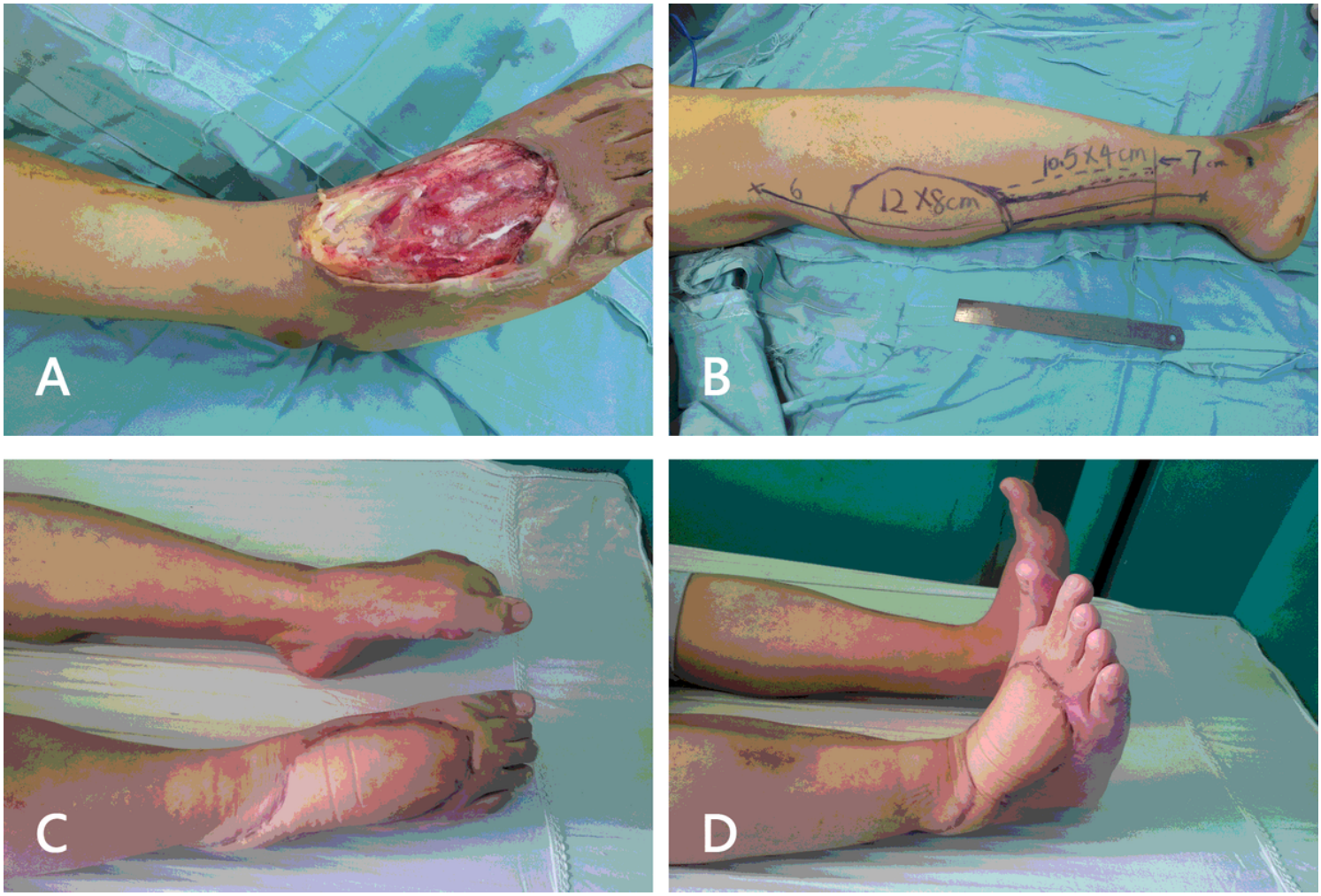

Figure 3

A 32-year-old man had a traumatic soft-tissue defect over the distal forefoot. a Image of the defect after thorough debridement. The most distal part of the defect was beyond the midpoint of the metatarsal bone, which required reconstruction. b Design of a DPAPF flap. c and d Appearance and reconstruction outcomes at 13 months postoperatively.