Clinical efficacy of treating the first metacarpal base fracture by closed reduction and percutaneous parallel K-wire interlocking fixation

Wu Wang
Xiangya Hospital Central South University
Min Zeng
Xiangya Hospital Central South University
Junxiao Yang
Xiangya Hospital Central South University
Long Wang
Xiangya Hospital Central South University
Jie Xie (dr_xiejie@163.com)
Xiangya Hospital Central South University
Yihe Hu
Xiangya Hospital Central South University

Research Article

Keywords: Closed reduction, K-wire fixation, First metacarpal base fracture, Bennett fracture, Rolando fracture

Posted Date: April 24th, 2021

DOI: https://doi.org/10.21203/rs.3.rs-447849/v1

Version of Record: A version of this preprint was published at Journal of Orthopaedic Surgery and Research on July 14th, 2021. See the published version at https://doi.org/10.1186/s13018-021-02600-5.

Abstract

Objective: To explore the clinical efficacy of treating a first metacarpal base fracture by closed reduction and percutaneous parallel K-wire interlocking fixation between the first and second metacarpals.

Methods: Twenty patients treated by the above technique from October 2015 to December 2018 at our institution were retrospectively reviewed. The patients' average age was 36 years (range, 16–61 years). Eleven patients were extra-articular fractures and nine were intra-articular fractures. The mean follow-up period was 12 months (range, 10–18 months). At the final follow-up, the functional recovery of the injured hand was assessed and compared with that of the uninjured hand.

Results: All patients recovered well with no complications. In the extra-articular fracture group, the mean hand grip strength, pinch strength, and Kapandji score were 43.4 ± 7.0 kg, 9.1 ± 1.4 kg, and 9.5 ± 0.7 on the injured side and 41.7 ±6.8 kg, 8.7 ± 0.8 kg, and 9.7 ± 0.5 on the uninjured side, respectively, with no significant differences. In the intra-articular fracture group, the above indexes were 43.0 ± 6.5 kg, 9.0 ± 1.1 kg, and 9.3 ± 0.7 on the injured side and 42.1 ± 6.6 kg, 8.6 ± 1.1 kg, and 9.7 ± 0.5 on the uninjured side, respectively, also with no significant differences. The abduction and flexion-extension arc of the thumb on the injured hand were lower than those on the uninjured hand in both the extra-articular and intra-articular fracture groups, but the patients felt clinically well with respect to daily activities and strength.

Conclusion: The percutaneous parallel K-wire and the interlocking fixation technique is simple, effective, and economic for first metacarpal base fractures.

Background

First metacarpal base fractures account for 80% of thumb fractures and 20% of fractures involving the articular surface of the first carpometacarpal joint [1]. These fractures are generally classified into four types: extra-articular, Bennett, Rolando, and comminuted [2]. Rolando fractures are also a type of comminuted fracture; therefore, the latter two types are often grouped together.

Fractures at the base of the first metacarpal are often unstable and require surgical treatment [2]. Open reduction and internal fixation often damage the ligaments around the joint, affect the blood circulation and joint stability, leads to delayed healing of the fracture, and postoperative cicatrisation also affect joint function; therefore, closed reduction is considered superior to open reduction [3]. The classic closed reduction and percutaneous K-wire fixation for Bennett fractures is Wagner's method [4]. However, this procedure requires placement of a K-wire across the first carpometacarpal joint to fix the first metacarpal with the trapezium, which may increase the risk of traumatic arthritis.

Johnson [5] reported an operative technique that fixes the first and second metacarpals with one or two K-wires for first metacarpal base fractures. Van Niekerk and Ouwens [6] subsequently applied a parallel K-wire fixation technique but claimed that the results were unsatisfactory. However, Greeven et al. [7] reported that percutaneous intermetacarpal parallel K-wire fixation was safe and effective in the treatment of both intra-articular and extra-articular fractures of the first metacarpal base.

Our operative technique is a modification of the above procedures. It was performed to introduce this modified procedure and evaluate its efficacy in the treatment of first metacarpal base fractures.

Materials And Methods

Patients and clinical materials

The present study was approved by the ethics committee of our hospital, all operations were performed at our institution from October 2015 to December 2018 by a single orthopaedic surgeon using the modified intermetacarpal K-wire fixation technique. Twenty patients with closed first metacarpal base fractures underwent this modified procedure. The study population comprised 19 male patients and 1 female patient, and their average age was 36 years (range, 16–61 years). The fractures were present in 16 right hands and 4 left hands, and all patients were right-hand dominant. Thirteen patients were injured after falling, and seven were injured while fighting (Table 1). Radiographs were performed in all patients before admission, and the fractures were classified using the classic method established by Green and O'Brien (type I: Bennett fracture, type II: Rolando fracture, type IIIA: transverse extra-articular fracture, type IIIB: oblique extra-articular fracture, and type IV: epiphyseal fracture) [6]. Eleven patients had a first metacarpal base fracture that did not involve the joint surface (type IIIA, n = 4; type IIIB, n = 7), six had a Bennett fracture (type I), and three had a Rolando fracture (type II) (Table 1). Follow-up included regular radiographs and clinical visits at 4, 6, and 12 weeks postoperatively, clinical follow-up continued to one year after surgery, while the radiographs did not be obtained completely due to the reluctance to be exposed to radiation.

Surgical techniques and postoperative management

The procedure was performed under a brachial plexus block, and the injury-to-surgery interval ranged from 24 to 72 hours. The patient was placed on the operating bed with the injured limb outspread on the radioparent side table and the forearm in pronation. First, the assistant applied axial traction to restore the length of the first metacarpal. Abduction and pronation of the thumb were then applied to rectify the rotation displacement of the metacarpus. Most extra-articular fractures were satisfactorily reduced. For some fractures, however (especially Bennett and Rolando fractures), the surgeon needed to push the radial aspect of the first metacarpal base to assist in the reduction [8]. Second, a 1.6-mm K-wire was vertically drilled through the base of the first and second metacarpals close to the distal end of the fracture, and another 1.6-mm K-wire was then drilled through the neck of the first metacarpals parallel to the first K-wire to strengthen the fixation (Fig. 1a, b). Third, the end of the K-wires were bent to 90º toward each other, and the wires were sheathed with a section of infusion tube. Then they were strapped and fixed with silk thread to increase their stability and prevent rotation (Fig. 1c, d). An additional video file shows this in more detail [see Additional file 1, 2 online]. Fracture reduction was evaluated by fluoroscopy [9]. The criteria for acceptable fracture reduction were a <2-mm step of the articular surface and a <2-mm space between fracture blocks [10].

No patients received antibiotics postoperatively because antibiotics were used intraoperatively. The K-wires outside the skin were sterilised on postoperative day 2 and then once every 1 to 2 weeks unless the dressing was contaminated. Postoperative stability was evaluated by the thumb activity, and only two Rolando fractures required postoperative plaster fixation. Thumb flexion and extension exercises were performed immediately postoperatively, and the patients were able to perform simple pinching activities such as eating with tableware and writing with a pen (the patients with a Rolando fracture were able to perform such activities when the plaster was removed 3 to 4 weeks postoperatively) (Fig. 2).

Evaluation

Clinical data were collected preoperatively, postoperatively, and during follow-up. Evaluation measures included the operative time, K-wire removal time, complications, subjective force of the injured hand (0–10, where 10 = best), grip and pinch strength of the thumb, abduction and the flexion-extension arc of the thumb, visual analogue scale (VAS) score (0–10, where 0 = no pain), and effective range of motion score of the first carpometacarpal joint (Kapandji score) (0–10, where 10 = best) [11]. The pinch and grip strength of the hand were measured by a dynamometer

(Kayser Italia, Livorno, Italy) and were assumed to be 6% higher on the dominant than non-dominant side [12]. The range of thumb motion was measured by a goniometer.

All patients were followed up by the same senior orthopaedic surgeon, and radiographs were taken at 4 weeks to evaluate the fracture healing and determine the time of K-wire removal. Radiographs were then taken every 2 months until the fracture healed.

Statistical analysis

Quantitative variables are presented as mean and standard deviation. A paired-samples t test was used to compare the functional test results between the injured and uninjured hands. SPSS version 17.0 (SPSS Inc., Chicago, IL, USA) was used for the statistical analyses. Differences were considered statistically significant at $P < 0.05$.

Results

All patients underwent satisfactory reduction and fixation by closed means. Only one Bennett fracture had a 2-mm step and a 1-mm gap in the articular surface after surgical reduction (Fig. 5).

The mean operation time was 18 min (range, 10–35 min), and the operation time for patients with multiple fractures was obtained by estimation (Table 1). The mean follow-up time was 12 months (range, 10–18 months). Seventeen patients were followed up in the hospital and three patients were followed up by telephone and WeChat video (The range of motion of the thumb was measured with a protractor, The grip and pinch strength were measured by the dynamometer which was mailed by us). No infections occurred postoperatively, and no patients developed K-wire loosening or fracture displacement or malunion during the functional exercises. The plaster for the Rolando fractures was removed 3 to 4 weeks after the operation, and the K-wires were removed only when the fracture had stabilised and partially healed as shown on the radiographs; the mean removal time was 48 days (range, 35–60 days). No delayed union or nonunion occurred (Table 1). Most patients were not willing to undergo radiographic re-examination after 1 year, so the radiological evaluation results were not all obtained.

The mean grip and pinch strength were 43.4 ± 7.0 and 9.1 ± 1.4 kg in the extra-articular fracture group and 43.0 ± 6.5 and 9.0 ± 1.1 kg in the intra-articular fracture group, respectively. The mean radial abduction, palmar abduction, and flexion-extension arc were 64.1° ± 5.4°, 59.7° ± 6.1°, and 44.1° ± 4.8° in the extra-articular fracture group and 64.5° ± 3.4°, 60.4° ± 4.5°, and 43.8° ± 4.0° in the intra-articular fracture group, respectively. The mean Kapandji score and VAS score were 9.5 ± 0.7 and 0.4 ± 0.5 in the extra-articular fracture group and 9.3 ± 0.7 and 0.9 ± 0.8 in the intra-articular fracture group, respectively (Tables 2 and 3). The abduction and the flexion-extension arc of the thumb on the injured hand were significantly lower than those on the uninjured hand in both the extra-articular and intra-articular fracture groups ($P < 0.05$), but the Kapandji score, grip strength, and pinch strength were not significantly different between the injured and uninjured hands in either the extra-articular or intra-articular fracture group ($P > 0.05$) (Tables 2 and 3). All patients were able to return to their original work or hobbies, and their VAS scores were all <2 and subjective strength scores were all >8. Representative cases are shown in Figures 3 to 5.

Discussion

Treatment of the first metacarpal basal fracture is relatively troublesome, which involves dislocation is particularly challenging [13]. However, the closed reduction and percutaneous K-wire fixation can obtain satisfactory curative effect in both Bennett fractures and Rolando fracture [14-17].

Numerous technique of closed reduction and percutaneous K-wire fixation of the first metacarpal basal fracture were reported [4-8,18,19]. Although the result of parallel K-wires fixation between the first and second metacarpal reported by Van Niekerk and Ouwens in 1989 seemed unsatisfactory[6], the concept of minimally invasive and reliable fixation are worthy of recommended. Therefore, the modified techniques were more or less influenced by them, and a good curative effect has been obtained in the subsequent application [7]. Our technique is a further modify of the parallel K-wire fixation technique between first and second metacarpal for the first metacarpal basal fracture. The highlights of our technique is the end of K-wires were bent to 90º toward each other, then the wires were sheathed with a section of infusion tube, and were strapped with silk thread. This simple operation enables the parallel K-wire to form a stable frame structure similar to the external fixator, coupled with the support of the second metacarpal, a stable rectangular frame can be formed.

In Van Niekerk and Ouwens' report [6], only 14 of the 19 intra-articular fractures were successfully treated by closed reduction and parallel K-wire fixation, and 3 of the 23 patients had poor recovery that affected their daily life and hobbies. While, Greeven et al. [7] in 2012 reported that they achieved good results with the application of this technique, only one patient with an extra-articular fracture experienced functional limitations and could not engage in their previous hobby; however, the patient was able to return to work. The follow-up result obtained by Greeven et al. [7] was obviously better than that obtained by Van Niekerk and Ouwens [6], who performed this surgical technique earlier. This difference may be related to the maturity of the surgical techniques.

In our study, all 20 patients were able to return to their original work or previous activity or hobby, and although their thumb movement declined after 1 year, they were satisfied with the strength, range of motion, and symptoms of their hand. These good clinical results may be related to our modification of the surgical technique, the bending of the K-wire, and the interlocking fixation, which enhanced the stability; thus, postoperative plaster fixation could be largely avoided (the rate of plaster use in our study was 2/20 [10%], while it was 12/25 [48%] in the report by Greeven et al. [7]). Therefore, the functional exercises performed immediately postoperatively promoted rehabilitation of our patients' hand function (Fig. 2).

Wagner's method is a classical percutaneous K-wire fixation for Bennett fractures [4]. However, the K-wire is placed throughout the first carpometacarpal joint and may damage the joint surface; moreover, it is difficult to drive the K-wire diagonally into the first metacarpal base, and repeated drilling may damage the joint and cause a new fracture. In addition, fixation of only the base of the first and second metacarpals is still unstable; therefore, postoperative plaster-assisted fixation is indispensable. Whereas, our technique of drilling parallel K-wires through the first and second metacarpals is easy to perform, it can form a stable rectangular frame, maintains the length of the first metacarpal, and resists axial rotation; thus, it is more stable than longitudinal K-wire fixation [20]. Furthermore, our technique of parallel K-wires fixation can avoid direct damage to the joint, and has a lower infection rate than the plate fixation [21]. Greeven et al. [7] reported that 3 of 25 cases developed needle infection and were cured by oral antibiotics. However, none of the 20 patients in the present study developed an infection. This difference may be related to the health education of the patients and the strict bandaging and care of the exposed K-wire after the surgery. Interestingly, Potenza et al. [22] also applied this parallel K-wire fixation technique in the treatment of fifth metacarpal neck fractures and achieved satisfactory results.

Duan et al. [19] recently introduced a frame structure to treat comminuted fractures of the first metacarpal base. The structure was made of multiple K-wires and bone cement and also served as a type of external fixator. However, the operation was complex, the damage to the metacarpal was also difficult to avoid, the reduction was difficult to maintain while the cement sets; moreover, the appearance was cumbersome, and the application of bone cement increased the medical costs. Adi et al. [8] reported the use of trapezoidal K-wire fixation between the first and second

metacarpals in the treatment of first metacarpal base fractures. The K-wires were also bent and fixed, but the fixation was use a special locking device. However, it was difficult to avoid K-wire deviation and slippage when they were drilled into the metacarpal shaft at an acute angle. Additionally, the use of special locking devices also increased the medical cost, and the removal was inconvenient. Coincidentally, Shafific S [23] used a self-made external fixator (parallel K-wires) for metacarpal and phalanx fractures, the locking fixation of the K-wires was also use a commercial device (locking ball /Jurgan ball), it was a nice innovation, nevertheless, the medical costs is also not low, the fixation and subsequent removal operations seems not easy either. Whereas, our method is easy to operate, has a good stability, the use of infusion tube and silk thread is very cheap, when remove the K-wires, just need cut the stitches.

The only problem of our technique is that movement of the first metacarpal can be restricted by the fixation, and the thumb motion may therefore decline after the surgery [6]. This phenomenon was observed in our study, and the solution is to open the thumb and maximise the space between the first and second metacarpals during the operation [8].

Our study had several limitations. First, this was a retrospective, observational trial, although the number of cases reached the statistical requirements, it was still low, the follow-up was short. Second, we obtained data mainly through comparison of the injured and uninjured hands, and although we adjusted for the dominant hand in the data analysis, we still cannot exclude the influence of the dominant hand. Third, traumatic osteoarthritis was not evaluated because 1-year postoperative radiographs were unavailable for some patients, and evaluation of this complication requires long-term follow-up to be meaningful [24]. This is worthy of discussion in future studies.

Conclusion

It is simple and effective for treatment of first metacarpal base fractures by the modified technique of percutaneous parallel K-wire fixation. The K-wire interlocking fixation technique can resist axial rotation and maintain stability; thus, it is beneficial for hand exercises and function recovery.

Abbreviations

K-wire: kirshner wire; VAS: Visual analog scale

Declarations

Ethics approval and consent to participate

This study was performed following the principles of the Declaration of Helsinki and the National Ethics Guidelines Statement. Informed consent was obtained from all participants.

Consent for publication

All patients' data were published with their informed consent.

Availability of data and materials

Not applicable.

Competing interests

The authors declare that they have no competing interests

Funding

None.

Authors' contributions

The authors read and approved the final manuscript.

Acknowledgements

Not applicable.

References

[1] Weinzweig N and Gonzalez MH. Metacarpal and phalangeal fractures. Plastic surgery secrets. Philadelphia: Hanley & Belfus Inc. 1999;p:467-72.

[2] Liverneaux PA, Ichihara S, Hendriks S, Facca S, Bodin F. Fractures and dislocation of the base of the thumb metacarpal. J Hand Surg Eur. 2015;40 (1):42-50.

[3] Greeven APA, Van Groningen J, Schep NWL, Van Lieshout EMM, Verhofstad MHJ. Open reduction and internal fixation versus closed reduction and percutaneous fixation in the treatment of Bennett fractures: A systematic review. Injury. 2019;50(8):1470-7.

[4] Wagner CJ. Method of treatment of Bennett's fracture dislocation. Am J Surg. 1950;80:230-1.

[5] Johnson EC. Fracture of the base of the thumb: a new method of fixation. JAMA .1944;126:27-8.

[6] Van Niekerk JL, Ouwens R. Fractures of the base of the first metacarpal bone: results of surgical treatment. Injury. 1989;20(6):359-62.

[7] Greeven APA, Alta TDW, Scholtens REM, de Heer P, Van der Linden FM. Closed reduction intermetacarpal Kirschner wire fixation in the treatment of unstable fractures of the base of the first metacarpal. Injury. 2012;43(2): 246-51.

[8] Adi M, Miyamoto H, Taleb C, Zemirline A, Gouzou S, Facca S, et al. Percutaneous fixation of first metacarpal base fractures using locked K-wires: a series of 14 cases. Tech Hand Up Extrem Surg. 2014;18(2):77-81.

[9] Greeven AP, Hammer S, Deruiter MC, Schipper IB. Accuracy of fluoroscopy in the treatment of intra-articular thumb metacarpal fractures. J Hand Surg Eur. 2013;38:979-83.

[10] Cullen JP, Parentis MA, Chinchilli VM, Pellegrini VD Jr. Simulated Bennett fracture treated with closed reduction and percutaneous pinning. A biomechanical analysis of residual incongruity of the joint. J Bone Joint Surg Am.1997;79.

[11] Angst F, Drerup S, Werle S, Herren DB, Simmen BR, Goldhahn J. Prediction of grip and key pinch strength in 978 healthy subjects. BMC Musculoskelet Disord. 2010;11:94.

[12] Chung KC, Pillsbury MS, Walters MR, Hayward RA. Reliability and validity testing of the Michigan hand outcomes questionnaire. J Hand Surg Am.1998;23: 575-87.

[13] Jupiter JB, Hastings H, Capo JT. The treatment of complex fractures and fracture-dislocation of the hand. Instr Course Lect. 2010;59:333-41.

[14] Huang JI, Fernandez DL. Fractures of the base of the thumb metacarpal. Instr Course Lect. 2010;59:343-56.

[15] Kamphuis SJM, Greeven APA, Kleinveld S, Gosens T, Van Lieshout EMM, Verhofstad MHJ. Bennett's fracture: Comparative study between open and closed surgical techniques. Hand Surg Rehabil. 2019;38(2):97-101.

[16] Marsland D, Sanghrajka A, Goldie B. Static monolateral external fixation for the Rolando fracture: a simple solution for a complex fracture. Annals of the Royal College of Surgeons. 2012;94(2):112-5.

[17] Niempoog S, Waitayawinyu T. Comminuted Rolando's fracturess: treatment with modified wrist external fixator and transmetacarpal pinning. J Med Assoc Thai. 2007;90(1):182-7.

[18] Vichard P, Tropet Y, Nicolet F. Longitudinal pinning of fractures of the base of the first metacarpal. Ann Chir Main. 1982;1:301-6.

[19] Duan W, Zhang X, Yu Y, Zhang Z, Shao X, Du W. Treatment of comminuted fractures of the base of the thumb metacarpal using a cemented bone-K-wire frame. Hand Surg Rehabil. 2019;38(1):44-51.

[20] Levy V, Mazzola M, Gonzalez M. Intra-articular fracture of the base of the first metacarpal bone: treatment through a volar approach. Hand (NY). 2018;13: 90-4.

[21] Fusetti C, Meyer H, Borisch N, Stern R, Santa DD, Papaloĩzos M. Complications of plate fixation in metacarpal fractures. J Trauma. 2002;52(3):535-9.

[22] Potenza V, Caterini R, De Maio F, Bisicchia S, Farsetti P. Fractures of the neck of the fifth metacarpal bone. Medium-term results in 28 cases treated by percutaneous transverse pinning. Injury. 2012;43(2):242-5.

[23] Shafific S. A Simple Phalangeal External Fixator Using Kirschner Wires and Locking Balls: No Need for Cement or Rubber Bands. J Hand Surg Am. 2016; 41(7):e217-21.

[24] Eaton RG, Littler JW. Ligament reconstruction for the painful thumb carpometacarpal joint. J Bone Joint Surg Am. 1973;55(8):1655-66.

Tables

Table 1 Patient characteristics

No.	Sex	Age	Fracture side	Trauma mechanism	Fracture type	Operation time (min)	Cast	K-wire removal(days)	complication
1	M	38	R	Fall	Bennett	22	No	40	None
2	M	34	L	Fighting	Bennett	15	No	55	None
3	M	28	R	Fall	Rolando	25	Yes	60	None
4	M	36	R	Fighting	Extra transverse	20	No	42	None
5	M	44	R	Fall	Extra oblique	10	No	50	None
6	M	61	R	Fall	Extra oblique	18	No	36	None
7	M	45	R	Fall	Rolando	30	Yes	56	None
8	M	30	L	Fighting	Bennett#	35	No	58	None
9	M	22	R	Fighting	Extra transverse	11	No	53	None
10	M	16	R	Fall	Bennett	16	No	35	None
11	M	26	R	Fall	Bennett	13	No	38	None
12	M	42	R	Fall	Extra oblique	14	No	40	None
13	M	33	L	Fighting	Extra oblique	20	No	45	None
14	M	37	R	Fall	Bennett	23	No	52	None
15	F	40	R	Fall	Extra transverse	15	No	54	None
16	M	50	L	Fall	Extra oblique	18	No	48	None
17	M	43	R	Fall	Extra oblique	12	No	44	None
18	M	35	R	Fighting	Rolando	22	No	50	None
19	M	38	R	Fall	Extra oblique	15	No	49	None
20	M	20	R	Fighting	Extra transverse	12	No	47	None

Average age(35.9±10.6) years, Average operation time (18.3±6.5)min, Average K-wire removal time (47.6±7.4) days

Multi-fracture patient, Representative cases are No. 3,5 and 8

Table 2 Outcomes of the extra-articular fractures			
	Injured side	Uninjured side	*P*-value
Radial abduction(º)	64.1±5.4	68.6±3.9	<0.001*
Palmar abduction(º)	59.7±6.1	64.3±4.3	0.001*
Flexion-Extension arc(º)	44.1±4.8	49.2±4.4	<0.001*
Kapandji score	9.5±0.7	9.7±0.5	0.082
Grip strength (kg)	43.4±7.0	41.7±6.8	0.173
Pinch strength (kg)	9.1±1.4	8.7±0.8	0.126
Subjective force	9.4±0.8		
Pain (VAS)	0.4±0.5		
Data for motion and strength are expressed as mean±SD. * is statistically significant Strength was assumed to be 6% higher on the dominant side than the opposite side VAS: visual analog scale (0-10) Subjective force (0-10)			

Table 3 Outcomes of the intra-articular fractures			
	Injured side	Uninjured side	*P*-value
Radial abduction(º)	64.5±3.4	68.0±3.9	0.003*
Palmar abduction(º)	60.4±4.5	64.0±3.5	0.001*
Flexion-Extension arc(º)	43.8±4.0	49.1±4.4	<0.001*
Kapandji score	9.3±0.7	9.7±0.5	0.282
Grip strength (kg)	43.0±6.5	42.1±6.6	0.730
Pinch strength (kg)	9.0±1.1	8.6±1.1	0.311
Subjective force	9.1±1.1		
Pain (VAS)	0.9±0.8		
Data for motion and strength are expressed as mean±SD. * is statistically significant Strength was assumed to be 6% higher on the dominant side than the opposite side VAS: visual analog scale (0-10) Subjective force (0-10)			

Figures

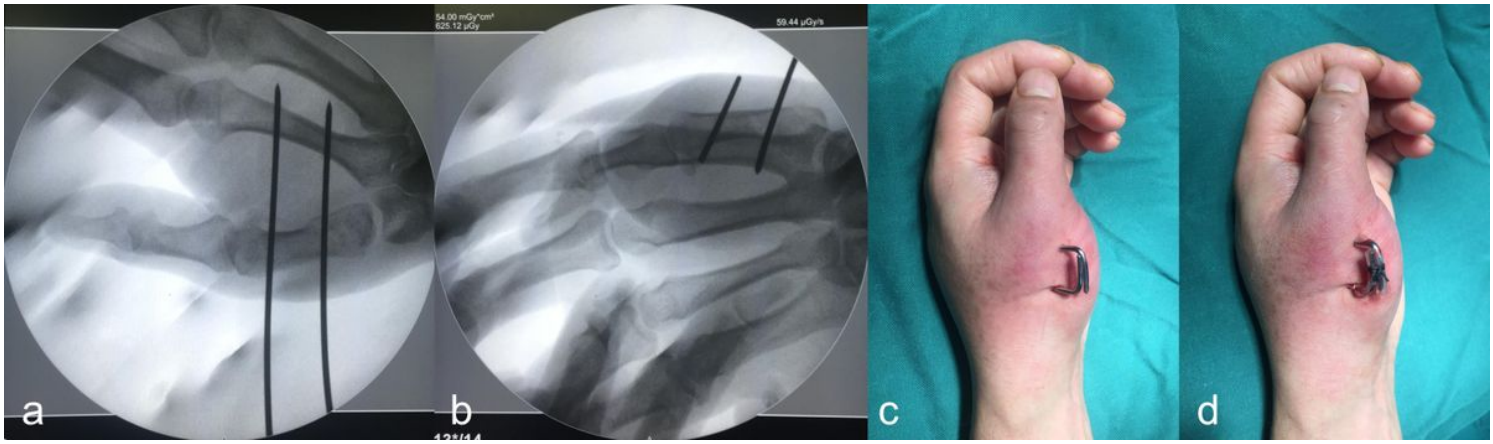

Figure 1

Intraoperative fluoroscopy and the appearance of the fracture after closed reduction and K-wire fixation. (a, b) Frontal and lateral radiographs of Patient 5. (c, d) Operative appearance of Patient 8

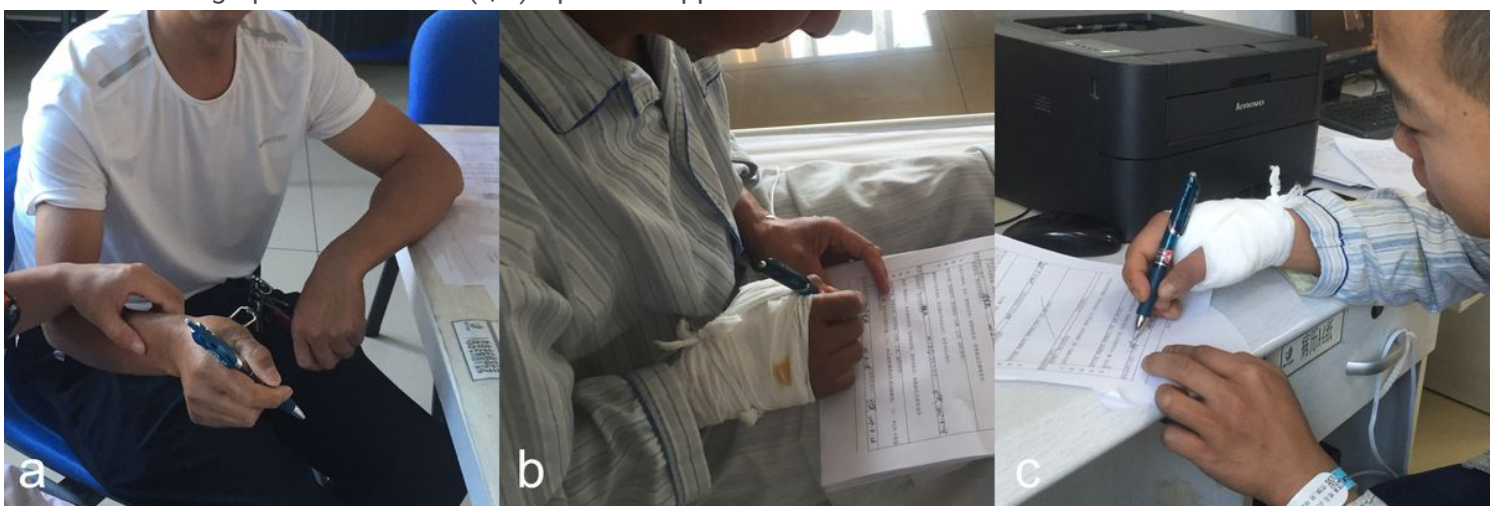

Figure 2

Functional exercises were performed immediately after surgery. The patients' daily life, including eating and writing, was unaffected. (a, b) Patient 8. (c) Patient 9

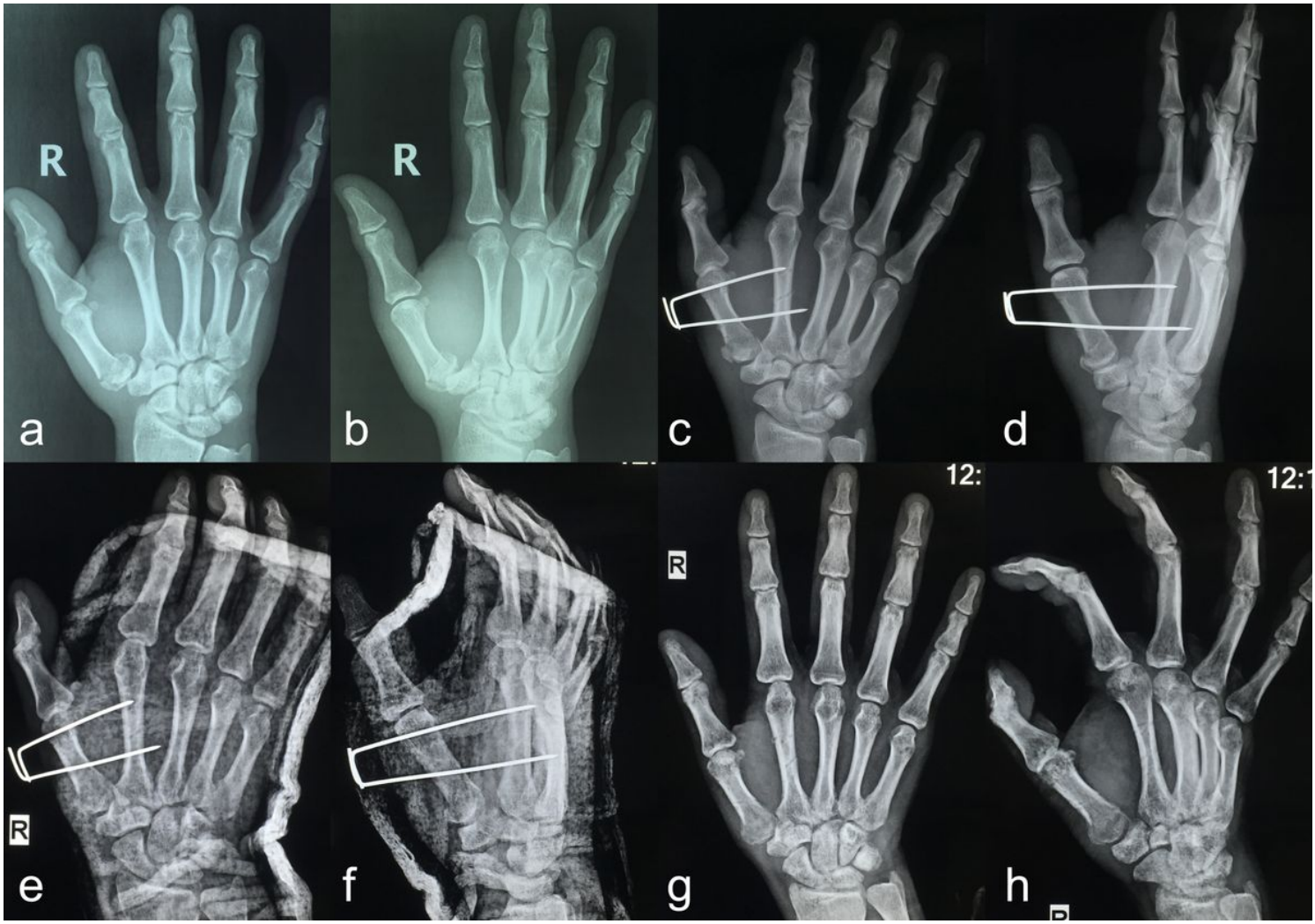

Figure 3

Representative case of a Rolando fracture (Patient 3). (a, b) Preoperative radiographs. (c, d) One-day postoperative radiographs. (e, f) Four-week postoperative radiographs before the plaster was removed. (g, h) Eight-week postoperative radiographs after the K-wire was removed. The radiographs show that the fracture has healed

Figure 4

Representative case of an extra-articular fracture (Patient 5). (a, b) Preoperative radiographs. (c, d) One-day postoperative radiographs. (e, f) Eight-week postoperative radiographs before the K-wire was removed. (g-i) Appearance during the operation. (j-l) Functional appearance after 6 months. (m-o) Functional appearance after 1 year. The abduction and bending ability of the thumb were significantly lower on the injured than uninjured side 6 months postoperatively, but the difference was not significant 1 year postoperatively

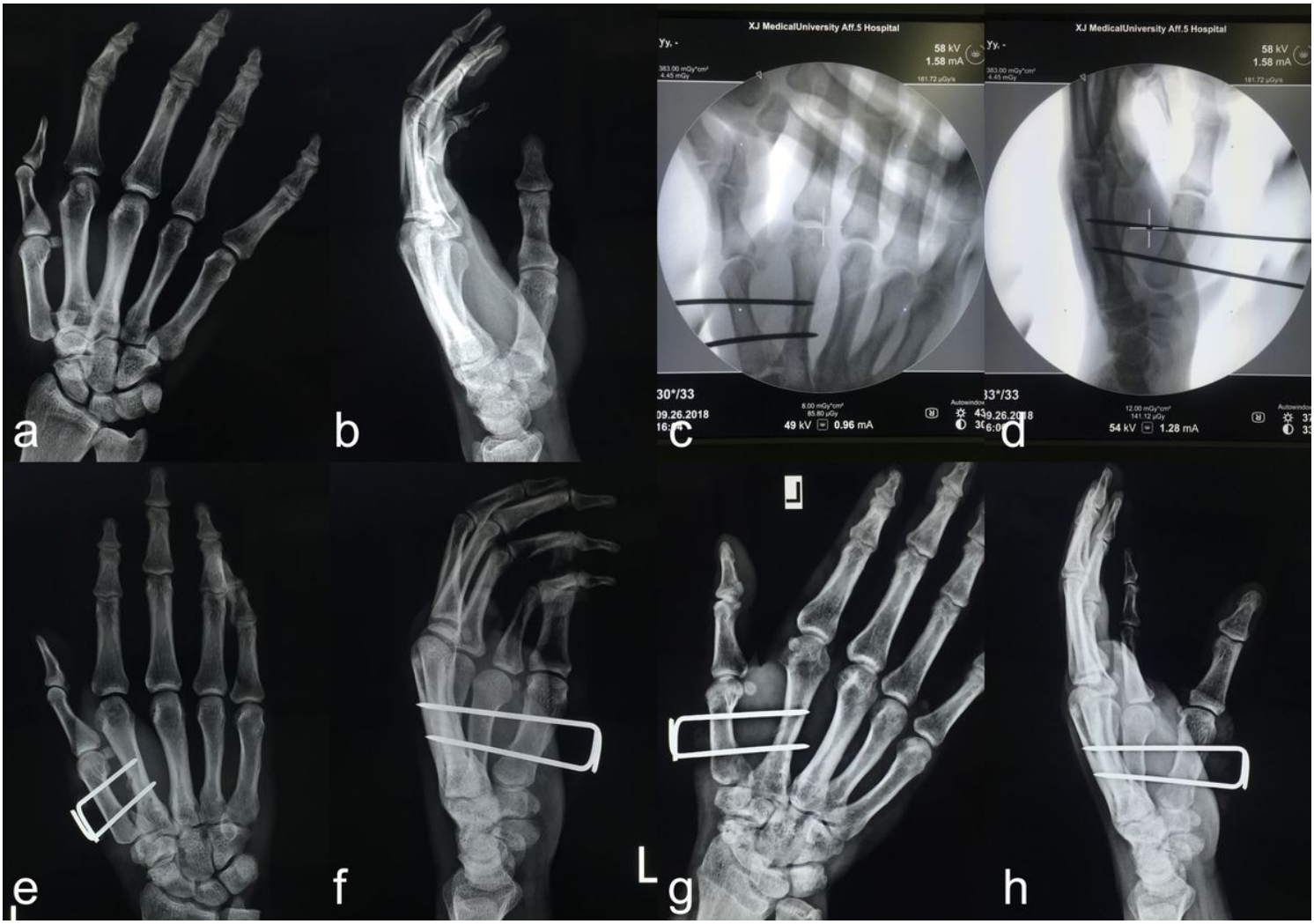

Figure 5

Representative case of a Bennett fracture (Patient 8). (a, b) Preoperative radiographs. (c, d) Fluoroscopic images after intraoperative reduction and fixation. (e, f) One-day postoperative radiographs. A 2-mm step and a 1-mm gap were present in the articular surface. (g, h) Six-week postoperative radiographs before the K-wire was removed. The fracture had almost healed, the gap between the fracture blocks had disappeared, and the articular step was not obvious

Supplementary Files

This is a list of supplementary files associated with this preprint. Click to download.

- Additionalfile1.mp4
- Additionalfile2.mp4