Effects and Long-Term Outcomes of Partial Anterior Myometrial Resection and Reconstruction Under Tourniquet and/or Prophylactic Abdominal Aorta Balloon Occlusion in Patients with Placenta Percreta: A Retrospective Cohort Study

Huidan Zhao
The First Affiliated Hospital of Zhengzhou University
Xianlan Zhao
The First Affiliated Hospital of Zhengzhou University
Chen Chen
The First Affiliated Hospital of Zhengzhou University
Ya Tao
The First Affiliated Hospital of Zhengzhou University
Rui Xia Guo (grxcdxzzu@163.com)
The First Affiliated Hospital of Zhengzhou University https://orcid.org/0000-0002-8847-2488

Research Article

Keywords: placenta accreta spectrum (PAS), placenta percreta, abdominal aorta, balloon occlusion

Posted Date: August 30th, 2021

DOI: https://doi.org/10.21203/rs.3.rs-448583/v1

Abstract

Purpose: Placenta percreta is the most serious subtype of placenta accreta spectrum (PAS) disorders. In this study, we propose a new procedure for controlling intraoperative bleeding. We aimed at evaluating the effect and long-term outcomes of Partial Anterior Myometrial Resection and Reconstruction under tourniquet and/or prophylactic abdominal aorta balloon occlusion in patients with placenta percreta.

Methods: This was a retrospective study involving pregnant patients with clinically confirmed placenta percreta who delivered by cesarean section between January 1st, 2018 and June 30th, 2020. A total of 334 pregnant women were recruited in this study. The 142 women that were subjected to this new method were regarded as the observation group while 194 pregnant women that were treated with other sutures were regarded as the control group. Demographic characteristics, placental accreta score, estimated blood loss (EBL), operative time, blood transfusion rate and volume, neonatal weight, post-operative hospital stays and costs were evaluated. Short-term complications, including fever, hematoma, thrombus, bladder rupture and ICU transfer rate, as well as long-term outcomes including breast feeding, menstruation, intrauterine adhesion, and chronic abdominal pain among others were followed up in the outpatient clinic and by phone calls.

Results: For all cases, EBL in the observation and control groups were 1200 (687~1812) ml and 1300 (800~2500) ml; operative time were 99.5 (84.0~120.0) min and 109.0 (83.8~143.0) min; while lengths of postoperative hospital stays were 4 (4~7) and 5 (4~7.5) days, respectively. The observation group exhibited significantly better outcomes than the control group. There were no significant differences in placental percreta scores, costs, blood transfusion volume, neonatal weight, fever, hematoma, thrombus, bladder rupture and ICU transfer rates between the two groups. All patients, except one in control group, had preserved uterus. There were no statistically significant differences in short-term and long-term complications between the two groups.

Conclusions: When combined with prophylactic abdominal aorta balloon occlusion and/or tourniquet, Partial Anterior Myometrial Resection and Reconstruction is highly effective in reducing intraoperative blood loss and hysterectomy in placental percreta. However, we should pay attention to short-term and long-term complications, especially to the complications associated with aorta balloon occlusion.

Background

With implementation of the 2-child policy in China, an increasing number of women with advanced maternal ages are choosing to have another child. A continuous increase in cesarean delivery rates has resulted in a substantial rise in women with prior cesarean delivery scars [1]. Moreover, applications of assisted reproductive technologies have significantly increased. These risk factors contribute to placenta accreta spectrum (PAS) disorders. Placenta accreta spectrum is associated with a very high risk of obstetric and pediatric complications, especially postpartum hemorrhage (PPH), which often leads to secondary complications including shock, coagulopathy, disseminated intravascular coagulation (DIC), multi-organ failure (MOF), and even death [1, 2]. Moreover, placenta accreta spectrum is likely to induce uterine rupture, uterine hysterectomy, preterm labor and neonatal respiratory distress syndrome. Various uterus compression sutures for clinical management of placental previa accreta have been reported, each with varying advantages and complications [3–9]. Based on the invasive depth of the trophoblast, three subtypes have been differentiated: placenta accreta, placenta increta and placenta percreta [1]. The invasive villous tissue penetrates to or through the uterine serosa and, in some cases, to the adjacent organs in the placenta percreta sites. Therefore, placenta percreta is the most serious subtype of placental accreta and easily leads to severe maternal and fetal complications. In this study, we propose a new procedure referred to as Partial Anterior Myometrial Resection and Reconstruction (PAMRR) for treating placenta percreta. This strategy focuses on bleeding of the anterior myometrium, which is the most common and serious part of placenta that is affected. We evaluate the effects and follow-up outcomes of this method.

Methods

Study participants

A total of 925 pregnant women with singleton and placental accreta spectrum and who were subjected to cesarean section at the first affiliated Hospital of Zhengzhou University from January 2018 to June 2020 were involved in this study. There were 336 cases of placental percreta. A total of 142 pregnant women were subjected to PAMRR, while 194 pregnant women were treated with other suture methods (control group). These suture methods included figure of eight suture, coarctation suture, and simple continuous suture among others.

Before surgery, we performed ultrasonic and Magnetic Resonance Imaging (MRI) examination to all PAS suspected patients. Data about the placenta, including its localization, thickness, loss of hypoechoic retroplacental zone and numerous large and irregular lacunae in the placenta, abnormal uterine bulging, dark intraplacental bands on T2-weighted images, heterogeneous signal intensity and disorganized placental vasculature were recorded. Inclusion criteria: All the patients were confirmed by ultrasound and MRI as well as clinical diagnosis. i. PAS score under ultrasound ≥ 10. Placental accreta score refers to the scoring system designed by Peking University Third Hospital [10] (**Figure 1**); ii. Placenta percreta confirmed by MRI [1] (**Figure 2**); iii.Surgical manifestations (FIGO grade 3a, 3b and 3C) [11], such as invasion of placental villi into the uterine serosa, urinary bladder or broad ligament, vaginal wall, pelvic sidewall or any other pelvic organ. Pregnant women who met all the above criteria were diagnosed with placental percreta. Cases with large areas of placental percreta were included in this study. The exclusion criteria were: i. PAS score under ultrasound <10; ii. Patients with severe obstetric complications and serious internal and surgical diseases, including cardiac disease, liver disease or pre-eclampsia; iii. Patients with twins or multiple pregnancy. All surgical procedures were performed by the same surgeon, Xianlan Zhao, with several assistants that remained unchanged. The whole process was managed by our multidisciplinary team, including doctors who were experts in ultrasound, MRI, anesthesiology, invasive technology and obstetrics. At 42 days after surgery, patients were returned to the outpatient clinic of the hospital. Clinical follow-ups were made by phone calls at three months, six months, one year and two years after surgery.

Surgical procedures

Based on clinical evidence, individual schedules were made for every patient. The schedules considered gestational week to pregnancy termination, the amount of prepared blood, and the necessity for placing a prophylactic abdominal aorta balloon among others. For the following three cases, the abdominal aorta balloon was preset before surgery: i. Patients with more than one previous cesarean section; ii. Severe abdominal adhesion in previous cesarean section predicted the difficulty of tourniquet placement during this operation; iii. Patients with cervical involvement as indicated by ultrasound or MRI. Surgical procedures were performed in the Digital subtraction angiography (DSA) room. Before cesarean section, the interventional doctor inserted a 5F balloon catheter into the distal abdominal aorta beneath the opening of the renal arteries through the right femoral artery. After confirming the good position of the balloon, cesarean section was performed, **Figure 3**.

i. The primary incision was recut, and the scar was removed from all patients that had been subjected to at least one C-Section before. Majority of the cases were transverse incisions of the lower abdomen while minority of the cases were longitudinal incisions. To expose the upper border of the placenta, our incision was about 3 cm longer than the previous one.

ii. Uterine incision was performed transversely over the upper border of the placenta, which is obvious after opening the abdomen. As shown in **Figure 4.A**, there were engorged and tortuous vessels on the serosa surface corresponding to the area of the placental increta beneath. To minimize bleeding, the incision was pulled tightly by the surgeon and the first assistant to maintain some tension.

iii. After delivering the fetus, the uterus was immediately exteriorized by the first assistant whose left hand pulled the anterior wall and the right hand dragged the fundus in the abdominal cavity. Then, we checked whether there was adhesion between the uterus and abdominal wall. The adhesion should be separated before opening the uterus.

iv. The aortic balloon that had been placed below the kidney artery before cesarean section was inflated by simultaneous delivery to occlude blood flow to the uterus. Meanwhile, we put a tourniquet as low as possible at the lower segment of the uterus to further block blood flow to the uterus. It was challenging to establish a tourniquet on patients with serious adhesions in which the aortic balloon was crucial and irreplaceable. Both treatments significantly reduced the amount of bleeding.

v. We pushed down the bladder and partially resected the anterior myometrium with the placenta unseparated (**Figure 4.B)**. All of our patients had placenta percreta covering a large area. The bladder was pushed down to a horizontal line of internal cervix os or to the accreta area if the posterior wall of the bladder muscle layer was invaded. The anterior myometrial from the lower lip of the uterine incision to the area 1 cm above the cervix was resected using a scalpel or scissor together with the bulk of implanted placenta. Due to the prophylactic abdominal aorta balloon and/or tourniquet, bleeding hardly ever occurred during this process. At the same time, the interventional doctor injected 1.2 ml of saline into the balloon to block the abdominal aorta.

vi. A single continuous suture was made along the lower lip of the uterine incision, as shown in **Figure 4.C**. Since the new-formed lower lip was one part of placenta in the deeply implanted area that was full of tortuous vessels, which can cause massive bleeding in a short time, this single continuous suture significantly minimized the bleeding. Other hemostatic methods were performed on the placental bed to prevent bleeding, including the area around the internal cervix os and the area where the placenta could not be excised. The figure-of-eight suture was the first choice for us. In the absence of active bleeding points, the tourniquet was removed. After tourniquet removal, the new bleeding site was sutured again. Based on hemostasis, the saline in the balloon was gradually extracted until the balloon was completely deflated.

vii. The lower transverse incision at the uterine was sutured in one layer in the common way, or two layers if necessary. As shown in **Figure 4.D,** this area was still permeated with tortuous vessels. In cases in which suturing the second layer was considered dangerous, we preferred monolayer suturing.

viii. The balloon catheter was removed after surgery. When necessary, uterine arterial ligation was performed on patients with consistent vaginal bleeding.

Demographic characteristics including age, gravidity, time of previous c-sections, gestational age and placenta accreta score were recorded. We also recorded the perioperative information of patients, including estimated blood loss (EBL), operative time, blood transfusion type and volume, neonatal weight, postoperative hospital stay period, costs and whether they had uterine arterial embolism (UAE) and ICU transfer. Autologous blood transfusion technology was performed for all study participants based on their wishes.

Short-term prognosis was evaluated. Short-term follow-ups for all patients at the clinic and in the outpatient department were performed 42 days after the operation. Short-term complications included bladder injury, fever (temperature ≥37.3 °C), late puerperal hemorrhage, pyometra, peritonitis, uterine necrosis, sepsis and perioperative infection, hematoma around the puncture location, false aneurysm, arteriovenous fistula and thrombus. Patients with an abdominal aorta arterial balloon were subjected to an echo examination after surgery to determine whether there was thrombus in the vessels (arteries, from the common iliac artery to the dorsalis pedis artery, and veins from the dorsalis pedis vein to the common iliac vein) of the pelvis and extremities.

Long-term follow ups were done by phone. Long-term follow-up was performed at three months, six months, one year, and at two years after surgery. Breast feeding situation, menstrual quantity, menstrual period, chronic pelvic pain, intrauterine adhesion and lower extremity discomfort were assessed. There was one pregnant case after PAMRR.

Statistical analysis

The SPSS 25.0 software was used for data analysis. Age, number of pregnancies, previous cesarean section times, gestational weeks, placenta accreta score, cost, operation time, EBL, CRBC transfusion, autologous blood transfusion, postoperative hospital stay and neonatal weights were measurement data. Age, cost and neonatal weights were normally distributed and were presented by mean ± standard deviation ($\bar{x} \pm s$). The independent sample t-test was used for

between group comparisons. Data for the other indicators did not conform to normal distribution, and were presented by median (25th -75th percentile) [M (p25-p75)]. The rank sum test was used for inter group comparisons. The remaining statistical indicators were count data, expressed by frequency or percentage, and the chi square test was used for inter group comparisons. $p \leq 0.05$ was set as the threshold for statistical significance.

Results

The 336 study participants had complete placenta previa. The characteristics of the study participants are shown in Table 1. Mean ages of the PAMRR group and the control group were 32.6±4.4 years, 32.0±5.0 years. The median number of gestational times for both groups was 4 while the number of previous C-sections for both groups was 1. The median gestational age of delivery for both groups was 35 weeks. The median placental accreta scores for both groups were 12. The above outcomes were not statistically significant between the two groups. Emergency C-section was performed because of prenatal vaginal bleeding in 11 cases (6 in the PAMRR group and 5 in the control group). The rest of the 325 cases were planned procedures. The procedural costs for the PAMRR and control groups were 35,891±12,821 and 40,123±31,402 RMB, respectively. The cost was lower in the PAMRR group than in the control group. All the differences were not statistically significant.

Perioperative data of patients is shown in Table 2. Procedures were performed under tourniquet in 108 cases, and under prophylactic abdominal aorta balloon occlusion (PABO) in 104 cases of the PAMRR group. Seventy-five cases were treated using both strategies, while 5 cases were treated using neither of the methods. In the control group, the procedures were performed under tourniquet in 138 cases, and under PABO in 136 cases. Ninety-nine cases were treated using both strategies, while 19 cases were treated by neither of the methods. The EBL in the observation and control groups were 1200 (687~1812) ml and 1300 (800~2500) ml; operative times were 99.5 (84.0~120.0) min and 109.0 (83.8~143.0) min; the lengths of postoperative hospital stays were 4 (4~7) and 5 (4~7.5) days, respectively. The observation group exhibited significantly better outcomes than the control group. There were 78 cases in the control group and 53 cases in the PAMRR group who chose autologous blood transfusion technology. The volumes of transfusion were 393 (233~648) and 661 (222~932) ml, respectively. Moreover, there were 122 cases in the control group and 77 cases in the PAMRR group who were subjected to allogeneic blood transfusion with the volume of transfusion being 400 (0~800) and 800 (0~1200) ml, respectively, which was less in the PAMRR group than in the control group, but the difference was not significant.

Postoperative data of the patients are shown in Table 3. There were 6 cases (2 in the PAMRR group and 4 in the control group) whose uterine arteries were embolized to stop bleeding. However, all uteruses, except one in the control group, were successfully preserved. Bladder injury occurred in 4 patients of the control group and in 3 cases of the PAMRR group. Muscle layers of the bladder were invaded by placenta in 7 patients. The injury happened when pushing down the bladder and while separating the reflection between the bladder and uterus. One patient that used a urinary catheter for 18 days to improve bladder healing was confirmed with a urinary fungal infection. In the other 6 patients with a urinary catheter, it remained in place for 3 to 14 days. Tube ligation was performed on 111 patients, based on their wishes and the risk of next pregnancy, while 31 patients refused peripartum sterilization. Six patients were sent to the intensive care unit (ICU) because of hemorrhagic shock or unstable vital signs. There was no maternal mortality in both groups.

Follow-up

Follow-up findings from the study participants are shown in Tables 3 and 4. There were no significant differences in all complications.

Short-term complications

Thirty-one patients (12 in the PAMRR group and 19 in the control group) developed a fever after surgery (37.3℃ < axillary temperature). However, there were no cases that were complicated by pelvic abscess, purulent secretion or any other symptom of pelvic or uterine infection. Therefore, the fever was considered to be postoperative absorption heat or a moderate inflammatory reaction. Due to appropriate antibiotic administration, temperature recovered to normal before discharge.

Seven cases (4 in the PAMRR group and 3 in the control group) had hematoma around the puncture location, 5 of which were small and disappeared before discharge. The hematoma was larger than 10 cm in the other 2 patients. Full recovery was confirmed in one of the two cases. However, the patient had a very low platelet count with extensive subcutaneous ecchymosis. The other patient had schizophrenia and was lost to follow-up. Compression on the puncture location could not be effectively performed because of schizophrenia, which was probably the main reason for hematoma.

Out of the 240 cases who placed aorta abdominalis thrombus was found in 10 (4 cases in the PAMRR group and 6 cases in the control group). Total incidence rate of thrombus in all the subjects was 4.2%. Thrombus in seven cases (3 in the PAMRR group and 4 in the control group) was in the artery around the puncture location, including external iliac artery, common femoral artery, superficial femoral artery and deep femoral artery, while 3 cases (1 in the PAMRR group and 2 in the control group) were in the accompanying vein, including external iliac vein, common femoral vein, and superficial femoral vein, which could have been caused by compression in case of hemorrhages. Because of extensive external iliac artery and common femoral artery, one patient was treated by arteriotomy with embolectomy. Catheter-directed thrombolysis was provided for 3 patients while the other 6 cases were treated with thrombolysis by urokinase combined with LMWH anti-coagulation. These patients were followed up for 12-37 months, and they all had good prognoses, except one patient who felt numb in the right knee and ankle 30 months after surgery.

There were no cases of pyometra, peritonitis, uterine necrosis, sepsis or perioperative infection of any other system. Moreover, there was no late puerperal hemorrhage, false aneurysm, or arteriovenous fistula.

Long-term complications

Up to December 31st 2020, 15 of the 142 patients in the PAMRR group and 18 of the 194 patients in the control group were lost during follow-up while the other 127 patients in the PAMRR group and 176 patients in the control group were successfully followed-up by phone for 3 to 38 months after surgery by the same doctor, Huidan Zhao. Long-term follow-up data of the patients are presented in Table 4.

Menstruation for 291 patients (170 in the PAMRR group and 121 in the control group) resumed. In more than half of the patients, menstruation resumed within 5 months. After surgery, menstrual quantity was decreased in 34 patients (22 in the control group and 12 in the PAMRR group). Moreover, menstrual quantity reduced by more than half in 8 of the 34 cases, however, transvaginal ultrasonic examination for all the 34 patients was normal. Menstrual period shortened for 11 cases (7 in the control group and 4 in the PAMRR group), at the same time, menstrual quantity decreased in all the 11 patients. Prolonged menstrual cycle was reported in 20 cases (12 in the control group and 8 in the PAMRR group) and ranged from 3 to 12 days. Scar diverticulum was diagnosed in 6 cases by transvaginal ultrasound, while 14 patients were normal.

Nine patients exhibited light chronic pain in the lower abdomen and other uncomfortable symptoms, including 3 cases during intercourse and 1 case before urination.

Intrauterine adhesion was found in two patients. Surgical procedures for these two cases had been performed under tourniquet and prophylactic abdominal aorta balloon occlusion. Irregular vaginal bleeding occurred every month after menstruation and lasted for 8-9 days, accompanied by chronic pain in the lower abdomen. Adhesion was detected by transvaginal ultrasound and was diagnosed by hysteroscopy examination. Separation of intrauterine adhesions was performed under hysteroscopy.

Lower extremity discomfort was found in 9 patients (6 in the control group and 3 in the PAMRR group). They had all been subjected to abdominal aorta balloon. The major symptoms were slight sense recession, numbness and soreness in the leg, knee or ankle, which arose from maintaining the same posture for a long time, staying in cold weather or exercising for a long period of time. One patient was diagnosed with thrombosis at the puncture location. Vessel radiography and ultrasonic examination were normal after treatment. The remaining 8 cases were confirmed by normal ultrasound performance during routine inspection two days after surgery.

After surgery, two women (1 in the control group and 1 in the PAMRR group) with placenta percreta were able to get pregnant and deliver again. We emphasized on the risk of the next pregnancy, but they declined sterilization. The placenta of the patient in the PAMRR group was located at the posterior wall, far away from the internal os of the cervix. The placenta of the other case was located in the anterior wall of the uterus without placenta previa. Elective caesarean section with sterilization was successfully performed at full term gestation. Both of them exhibited good prognoses.

Discussion

The main risk associated with placenta accreta is massive obstetric hemorrhage. To reduce immediate hemorrhage and ensure maternal and infant safety, it has been suggested that non-conservative operations, such as cesarean hysterectomy, should be performed [1, 2]. However, iatrogenic injuries to pelvic organ support systems and nerves during these procedures could be associated with pelvic floor dysfunctions, such as urinary dysfunctional symptoms, including urgency, retention, obstruction and especially sexual problems [12, 13]. Maintaining the uterus under the safety premise is very important. As the number of patients with placenta previa accreta increase, many conservative management procedures and uterus compression sutures have been developed to minimize uterine bleeding. These procedures include one-step conservative surgery, distinguished B-Lynch surgical technique, multiple square suture, parallel vertical compression suture, multiple 8 compression suturing, and Triple-P procedures among others [3–5, 7, 14–16]. Every compression suture has its corresponding indications and advantages, with the main performance of uterine atony, placenta previa or placenta accreta.

Based on the outcomes of our procedure and the success rate of conservative treatment in our study, the conservative method of uterine reservation with placenta separation is preferred for patients with stable vital signs, without rapid uncontrolled massive bleeding and without serious infections. However, the choice of a suitable procedure should be based on complete communication with patients and specific evaluation by the multidisciplinary team. Our method aimed at extensive placenta percreta. Prophylactic devascularization achieved by aortic arterial balloon occlusion and/or tourniquet before surgery can reduce the risk of intraoperative blood loss and prevent the occurrence of severe postpartum hemorrhage [17–25].

We found that, compared to the control group, PAMRR could significantly shorten the operation time, reduce perioperative blood loss and shorten postoperative hospital stays. It reduced hospitalization costs and the amounts of autologous blood transfusion; however, the difference was not significant. There were no significant differences in postoperative complications such as UAE hemostasis, fever, thrombosis, puncture site hematoma, bladder injury, ICU admission and hysterectomy. First, the eroded defective anterior lower uterus segment and bulk of the placenta without detachment were removed, which reduced homeostasis area and shortened homeostasis time, consequently reducing bleeding volume. Second, once the partial anterior uterus myometrium had been resected, the internal os of the cervix was easier to expose, facilitating the next surgical homeostasis suture that was applied to this area. Third, only the eroded unfunctional uterus tissue was excised and the normal myometrium was preserved as much as possible. After reconstruction, the incision was the same as in a traditional C-section. Compared to other operations, this method has the advantages of less trauma.

The “Triple-P procedure" proposed by British researchers Chandraharan E et al. involves perioperative placental localization, pelvic devascularization, placental non-separation with myometrial excision and reconstruction of the uterine wall, which effectively preserves the uterus [4]. Our procedure is similar to the Triple-P procedure, but with some differences. First, in the Triple-P procedure, occlusion balloon catheters are placed in the bilateral internal iliac artery, and are required to puncture both sides of the femoral artery. In our proposed procedure, occlusion balloon catheters are placed in the abdominal aorta artery, and are only needed to puncture one side of the femoral artery. This process is associated with a lower risk of thrombosis and leads to more effective devascularization. Second, for some patients, occlusion balloon and tourniquet were used simultaneously, which can achieve maximum occlusion for blood supply to the uterus. Third, we pushed down the bladder, exposed the lower segment of the uterus and excised as mush placenta with the eroded unfunctional

uterine tissue as possible. The Triple-P procedure does not indicate how to deal with the bladder. Fourth, a single continuous suture was performed on the lower lip of the uterine incision, which was one part of placental percreta area and was full of tortuous vessels. This step can significantly reduce the bleeding.

Based on the standard of placenta accreta spectrum [1, 2], termination of pregnancy at 34–36 weeks for patients with regular perinatal care in our hospital was recommended. For the other patients included in the study, it was after more than 36 weeks, because: i. Irregular perinatal care in other hospitals, and gestational age at the time of referral being more than 36 weeks; ii. After fully explaining the advantages and disadvantages of the method to patients, they paid too much attention to the complications of premature infants and refused to be operated before 36 weeks.

Long-term complications associated with conservative treatment for placenta percreta have not been clearly elucidated. For previous sutures, long-term complications cannot be easily identified due to insufficient cases and unsustainable follow-ups. We have implemented this procedure for about eight years. Changes in menstrual and lower extremity discomforts cannot be ignored. Menstrual volumes of 34 pregnant women decreased after surgery, however, there was no significant difference between the PAMRR and control groups. The decrease in menstrual volumes could be associated with extensive invasion of the endometrium by placenta percreta, destruction of the basement layer of endometrium and incomplete repair after operation. It may not be associated with the anterior wall of the uterus which was severely damaged in the resection part of PAMRR. The decrease in menstrual volume did not harm women without reproductive requirements. Six cases of scar diverticulum were detected by transvaginal ultrasound in 20 women with prolonged menstruation, in which follow-up drugs or surgical treatment was required.

Two patients with successful deliveries after conservative treatment of placenta accreta predicted the possibility of a subsequent pregnancy. However, the risk of recurrent placenta accreta and postpartum hemorrhage should be cautiously evaluated in future. Lower limb complaints were found in quite a few cases. The reason why lower limb complaints were reported by patients with normal echo performance was unclear. We inferred two possible reasons. First, it may be relative to the ischemic injury to the femoral nerve. Second, although vessel radiography and echo examination did not reveal thrombosis in the big artery, it was unclear whether there was small thrombosis in the peripheral artery.

With advances in medical technology, more and more interventional procedures, including temporal balloon occlusion of internal iliac artery [26], common iliac artery [27, 28] or abdominal aorta artery [20, 21] and embolization of uterine artery or internal iliac artery are being developed and are being applied in obstetric diseases. The advantages of these procedures have been elucidated, however, their disadvantages have not been clearly established. Complications of interventional radiological procedures, including thrombus formation, pseudoaneurysm, and arterial rupture among others have been reported. However, most of these complications have been detailed in case reports and long-term outcomes have rarely been recorded or reported [28–31]. We concluded that even if imaging examination of the vessels of pelvis and lower extremities returns absolutely normal results, after interventional surgery, patients can still present uncomfortable symptoms for a long period of time. Hematoma and thrombosis are not rare, as reported in previous studies. Therefore, indications of interventional measures should be carefully considered.

Conclusions

In summary, when combined with tourniquet and/or prophylactic abdominal aorta balloon occlusion, Partial Anterior Myometrial Resection and Reconstruction (PAMRR) is highly effective in reducing intraoperative blood loss and hysterectomy in patients with placenta percreta. It is a safe and effective surgical alternative to peripartum hysterectomy. However, the complications associated with abdominal aorta balloon occlusion should be evaluated.

Abbreviations

PAS: Placenta accreta spectrum; EBL: Estimated blood loss; DIC: Disseminated intravascular coagulation; MOF: Multi-organ failure; PPH: Postpartum hemorrhage; PAMRR: Partial Anterior Myometrial Resection and Reconstruction; MRI: Magnetic Resonance Imaging; DSA: Digital subtraction angiography; ICU: Intensive care unit.

Declarations

Our manuscripts contain the following sections: ethics approval and consent to participate, consent for publication, availability of data and materials, competing interests, funding, authors' contributions, acknowledgements, code availability and authors' information.

Acknowledgements

Not applicable.

Code availability

Not applicable.

Authors' contributions

HZ: Data collection, Manuscript writing, Operation performed. XZ: Data collection, Manuscript writing, Operation performed. CC: Data analysis. YT: Figure editing. RG: Project development, Manuscript editing.

Funding

No specific funding obtained.

Availability of data and materials

We would like to share the database upon individual request.

Ethics approval and consent to participate

All procedures performed in studies involving human participants were in accordance with the 1964 Helsinki Declaration and were in accordance with the ethical standards of the institutional research committee (Ethics Committee of the First Affiliated Hospital of Zhengzhou University, 2019-KS-YXKJJ014). All the subjects were informed of the study purpose. Written informed consent was obtained for each patient.

Consent for publication

The patient who was pregnant and delivered a baby after the surgery described in the manuscript granted written informed consent to publish.

Conflict of interest

All authors declare no conflict of interest.

References

1. Jauniaux E, Ayres-de-Campos D, Diagnosis FPA, Management Expert Consensus P. FIGO consensus guidelines on placenta accreta spectrum disorders: Introduction. Int J Gynaecol Obstet. 2018 ;140(3):261-4. https:// doi.org/10.1002/ijgo.12406.
2. Jauniaux E, Alfirevic Z, Bhide AG, Belfort MA, Burton GJ, Collins SL, et al. Placenta Praevia and Placenta Accreta: Diagnosis and Management: Green-top Guideline No. 27a. BJOG. 2019;126(1):e1-e48. https:// doi.org/10.1111/1471-0528.15306
3. C BL, Coker A, Lawal AH, Abu J, Cowen MJ. The B-Lynch surgical technique for the control of massive postpartum haemorrhage: an alternative to hysterectomy? Five cases reported. Br J Obstet Gynaecol. 1997;104(3):372-5. https:// doi.org/10.1111/j.1471-0528.1997.tb11471.x
4. Chandraharan E, Rao S, Belli AM, Arulkumaran S. The Triple-P procedure as a conservative surgical alternative to peripartum hysterectomy for placenta percreta. Int J Gynaecol Obstet. 2012;117(2):191-4. https:// doi.org/10.1016/j.ijgo.2011.12.005
5. GT L, GR L, XF L, BP W. Funnel compression suture: a conservative procedure to control postpartum bleeding from the lower uterine segment. BJOG : an international journal of obstetrics and gynaecology. 2016;123(8):1380-5. https:// doi.org/10.1111/1471-0528.13685
6. JC S, KL L, J K, JH Y, MW L, CU Y. 'Nausicaa' compression suture: a simple and effective alternative to hysterectomy in placenta accreta spectrum and other causes of severe postpartum haemorrhage. BJOG : an international journal of obstetrics and gynaecology. 2019;126(3):412-7. https:// doi.org/10.1111/1471-0528.15410
7. YM H, CP C, HS C, TH S. Parallel vertical compression sutures: a technique to control bleeding from placenta praevia or accreta during caesarean section. BJOG : an international journal of obstetrics and gynaecology. 2005;112(10):1420-3. https:// doi.org/10.1111/j.1471-0528.2005.00666.x
8. JH C, HS J, CN L. Hemostatic suturing technique for uterine bleeding during cesarean delivery. Obstetrics and gynecology. 2000;96(1):129-31. https:// doi.org/10.1016/s0029-7844(00)00852-8
9. RG H, S A, PJ S. Uterine compression sutures: surgical management of postpartum hemorrhage. Obstetrics and gynecology. 2002;99(3):502-6. https:// doi.org/10.1016/s0029-7844(01)01643-x
10. Zhong YW, Zhang AQ, Wang Y, et al. Value of ultrasonic scoring system for predicting risks of placenta accreta. Chinese Journal of Perinatal Medicine 2016,19 9 705-709. https:// doi.org/ 10.3760/cma.j.issn.1007-9408.2016.09.014.
11. Jauniaux E, Ayres-de-Campos D, Langhoff-Roos J, Fox KA, Collins S, Diagnosis FPA, et al. FIGO classification for the clinical diagnosis of placenta accreta spectrum disorders. Int J Gynaecol Obstet 2019; 146(1):20-24. https:// doi.org/10.1002/ijgo.12761
12. Selcuk S, Cam C, Asoglu MR, Kucukbas M, Arinkan A, Cikman MS, et al. Effect of simple and radical hysterectomy on quality of life - analysis of all aspects of pelvic floor dysfunction. Eur J Obstet Gynecol Reprod Biol. 2016 Mar;198:84-8. https:// doi.org/10.1016/j.ejogrb.2016.01.008
13. Dedden SJ, van Ditshuizen MAE, Theunissen M, Maas JWM. Hysterectomy and sexual (dys)function: An analysis of sexual dysfunction after hysterectomy and a search for predictive factors. Eur J Obstet Gynecol Reprod Biol. 2020 Apr;247:80-4. https:// doi.org/10.1016/j.ejogrb.2020.01.047
14. Palacios-Jaraquemada JM. One-Step Conservative Surgery for Abnormal Invasive Placenta (Placenta Accreta–Increta–Percreta). In: Arulkumaran S, Karoshi M, Keith LG, Lalonde AB, B-Lynch C, eds. A Comprehensive Textbook of Postpartum Hemorrhage. An essential clinical reference for Effective Management 2nd Edition. London: Sapiens Publishing GLOWM; 2012:263–271.
15. Shazly SA, Badee AY, Ali MK. The use of multiple 8 compression suturing as a novel procedure to preserve fertility in patients with placenta accreta: case series. Aust N Z J Obstet Gynaecol. 2012 Aug;52(4):395-9. https:// doi.org/10.1111/j.1479-828X.2012.01449.x
16. Huang G, Zhou R, Hu Y. A new suture technique for cesarean delivery complicated by hemorrhage in cases of placenta previa accreta. Int J Gynaecol Obstet. 2014 Mar;124(3):262-3 https:// doi.org/ 10.1016/j.ijgo.2013.10.003
17. Wei X, Zhang J, Chu Q, Du Y, Xing N, Xu X, et al. Prophylactic abdominal aorta balloon occlusion during caesarean section: a retrospective case series. Int J Obstet Anesth. 2016;27:3-8. https:// doi.org/ 10.1016/j.ijoa.2015.12.001
18. Xie L, Wang Y, Luo FY, Man YC, Zhao XL. Prophylactic use of an infrarenal abdominal aorta balloon catheter in pregnancies complicated by placenta accreta. J Obstet Gynaecol. 2017;37(5):557-61. https:// doi.org/ 10.1080/01443615.2017.1291588
19. Duan XH, Wang YL, Han XW, Chen ZM, Chu QJ, Wang L, et al. Caesarean section combined with temporary aortic balloon occlusion followed by uterine artery embolisation for the management of placenta accreta. Clin Radiol. 2015;70(9):932-7. https:// doi.org/10.1016/j.crad.2015.03.008

20. Wu Q, Liu Z, Zhao X, Liu C, Wang Y, Chu Q, et al. Outcome of Pregnancies After Balloon Occlusion of the Infrarenal Abdominal Aorta During Caesarean in 230 Patients With Placenta Praevia Accreta. Cardiovasc Intervent Radiol. 2016;39(11):1573-9. https:// doi.org/10.1007/s00270-016-1418-y
21. Wang YL, Duan XH, Han XW, Wang L, Zhao XL, Chen ZM, et al. Comparison of temporary abdominal aortic occlusion with internal iliac artery occlusion for patients with placenta accreta - a non-randomised prospective study. Vasa. 2017;46(1):53-7. https:// doi.org/10.1024/0301-1526/a000577
22. Zeng C, Yang M, Ding Y, Yu L, Deng W, Hu Y, et al. Preoperative infrarenal abdominal aorta balloon catheter occlusion combined with Bakri tamponade reduced maternal morbidity of placenta increta/percreta. Medicine (Baltimore). 2017;96(38):e8114. https:// doi.org/10.1097/ MD.0000000000008114
23. Chen L, Wang X, Wang H, Li Q, Shan N, Qi H. Clinical evaluation of prophylactic abdominal aortic balloon occlusion in patients with placenta accreta: a systematic review and meta-analysis. BMC Pregnancy Childbirth. 2019;19(1):30. https:// doi.org/10.1186/s12884-019-2175-0
24. Ikeda T, Sameshima H, Kawaguchi H, Yamauchi N, Ikenoue T. Tourniquet technique prevents profuse blood loss in placenta accreta cesarean section. J Obstet Gynaecol Res. 2005;31(1):27-31. https:// doi.org/ 10.1111/j.1447-0756.2005.00247.x
25. Meng JL, Gong WY, Wang S, Ni XJ, Zuo CT, Gu YZ. Two-tourniquet sequential blocking as a simple intervention for hemorrhage during cesarean delivery for placenta previa accreta. Int J Gynaecol Obstet. 2017;138(3):361-2. https:// doi.org/10.1002/ijgo.12199
26. Carnevale FC, Kondo MM, de Oliveira Sousa W, Jr., Santos AB, da Motta Leal Filho JM, Moreira AM, et al. Perioperative temporary occlusion of the internal iliac arteries as prophylaxis in cesarean section at risk of hemorrhage in placenta accreta. Cardiovasc Intervent Radiol. 2011;34(4):758-64. https:// doi.org/ 10.1007/s00270-011-0166-2
27. Minas V, Gul N, Shaw E, Mwenenchanya S. Prophylactic balloon occlusion of the common iliac arteries for the management of suspected placenta accreta/percreta: conclusions from a short case series. Arch Gynecol Obstet. 2015;291(2):461-5. https:// doi.org/10.1007/s00404-014-3436-9
28. Shih JC, Liu KL, Shyu MK. Temporary balloon occlusion of the common iliac artery: new approach to bleeding control during cesarean hysterectomy for placenta percreta. Am J Obstet Gynecol. 2005;193(5):1756-8. https:// doi.org/10.1016/j.ajog.2005.08.033
29. Chouliaras S, Hickling DJ, Tuck JS. Thromboembolism of the leg following prophylactic balloon occlusion of the uterine arteries. BJOG. 2009;116(9):1278-9. https:// doi.org/10.1111/j.1471-0528.2009.02217.x
30. Gagnon J, Boucher L, Kaufman I, Brown R, Moore A. Iliac artery rupture related to balloon insertion for placenta accreta causing maternal hemorrhage and neonatal compromise. Can J Anaesth. 2013;60(12):1212-7. https:// doi.org/10.1007/s12630-013-0038-0
31. Bishop S, Butler K, Monaghan S, Chan K, Murphy G, Edozien L. Multiple complications following the use of prophylactic internal iliac artery balloon catheterisation in a patient with placenta percreta. Int J Obstet Anesth. 2011;20(1):70-3. https:// doi.org/10.1016/j.ijoa.2010.09.012

Tables

Table 1. Comparation of demographic characteristics of the patients with placenta percreta in two groups

Group	n	Age (years, $\bar{x} \pm s$)	Gravidity [M(P_{25}-P_{75})]	Previous c-sections [$M(P_{25}$-$P_{75})$]	gestational age [wk, $M(P_{25}$-$P_{75})$]	Placenta accreta Score* [$M(P_{25}$-$P_{75})$]	Emergency c-section [n (%)]
PAMRR	142	32.6±4.4	4(3~5)	1(1~2)	35(34.1~35.8)	12(11~14)	6(4.23)
Control	194	32.0±5.0	4(3~5)	1(1~2)	35(33.7~35.8)	12(11~13)	5(2.58)
Statistic Value		1.06	1.08	0.72	0.34	0.96	0.70
P value		0.292	0.19	0.47	0.73	0.34	0.40

*Placental accreta score refers to the scoring system designed by Peking University Third Hospital.

Table 2. Comparation of perioperative data of the patients with placenta percreta treated by two different procedures

Group	Costs [RMB, $\bar{x} \pm s$)]	Tourniquet [n (%)]	PABO [n (%)]	Operative time [min $M(P_{25}$-$P_{75})$]	Estimated blood loss[ml $M(P_{25}$-$P_{75})$]	CRBC transfusion [ml, $M(P_{25}$-$P_{75})$]	Autologous blood transfusion [ml $M(P_{25}$-$P_{75})$]	Length of postopera hospital s [day, M(P2 P75)]
PAMRR	35891±12821	108(76.1)	104(73.2)	99.5(84.0~120.0)	1200(687~1812)	400(0~800)	393(233~648)	4(4~7)
Control	40123±31402	138(71.1)	136(70.1)	109.0(83.8~143.0)	1300(800~2500)	800(0~1200)	661(222~932)	5(4~7.5)
Statistic Value	1.26	1.01	0.40	2.09	2.06	1.41	1.85	3.31
P value	0.21	0.31	0.53	0.04*	0.04*	0.16	0.06	0.001*

*P 0.05. PABO: abdominal aorta balloon occlusion; CRBC: concentrated red blood cells.

Table 3. Comparation of postoperative follow-up data of the patients with placenta percreta treated by two different procedures

Group	UAE [n (%)]	Fever [n (%)]	Hematoma [n (%)]	Thrombus [n (%)]	Bladder injury [n (%)]	Hysterectomy [n (%)]	ICU admission [n (%)]
PAMRR	2(1.4)	12(8.5)	4(2.8)	4(2.8)	3(2.1)	0(0)	2(1.4)
Control	4(2.1)	19(9.9)	3(1.2)	6(3.1)	4(2.1)	1(0.5)	4(2.1)
Statistic Value	0.20	0.18	0.65	0.02	0.01	0.73	0.20
P Value	0.62	0.67	0.42	0.88	0.97	0.39	0.62

UAE: uterine artery embolism

Table 4. Comparation of long-term follow-up data of the patients with placenta percreta treated by two different procedures

Variables	PAMRR n(%)	Control n(%)	χ^2	*P* value
Long-term follow-up			0.15	0.69
Succeeded	127(89.4)	176(90.7)		
Lost	15(10.6)	18(9.3)		
Time after the procedure				
more than 2 years	49(34.5)	63(32.5)	0.15	0.69
more than 1 year	113(79.6)	148(76.3)	0.51	0.48
more than six months	127(89.4)	176(90.7)	0.15	0.69
Breast feeding situation			0.29	0.59
Artificial feeding	14(11.0)	23(13.1)		
Breast feeding	113(89.0)	153(86.9)		
Menstruation restored			0.34	0.56
Yes	121(95.3)	170(96.6)		
No	6(4.7)	6(3.4)		
Time of menstruation resumed			0.79	0.67
5 months	67(52.8)	98(55.7)		
5-10 months	42(33.1)	50(28.4)		
10 months	18(14.1)	28(15.9)	.	
Menstrual quantity			0.67	0.71
Increase	5(4.1)	6(3.5)		
Same	104(86.0)	142(83.5)		
Decrease	12(9.9)	22 (12.9)		
Menstrual period (days)			0. 16	0.93
Longer	8(6.6)	12(7.0)		
Same	109(90.1)	151(88.8)		
Shorter	4(2.7)	7(4.1)		
Intrauterine adhesion	1(0.8)	1(0.6)	0.05	0.82
Light chronic pain of abdomen	5(3.9)	4(2.3)	0.71	0.40
Lower extremity discomfort	3(2.4)	6(3.4)	0.28	0.60

Figures

Image not available with this version

Figure 1

Ultrasonograms of the participant a: Increased placental thickness under preoperative ultrasound examination; b: Loss of hypoechoic retroplacental zone and numerous large and irregular lacunae in the placenta; c: Absence of the lower muscle layer of uterus and Vessels with high velocity blood flow leading from the myometrium into the placental lacunae; d: Striking amount of color Doppler signal seen between the myometrium and the posterior wall of the bladder.

Image not available with this version

Figure 2

MRI images of the participant a: MRI coronal plane on T2-weighted images, showing thickened placenta, heterogeneous signal intensity; b: MRI sagittal plane, showing unclear boundary of placenta and uterine wall; c: MRI cross section, showing focal interruption of myometrium

Image not available with this version

Figure 3

Image of the balloon The balloon was placed into the distal abdominal aorta beneath the opening of the renal arteries.

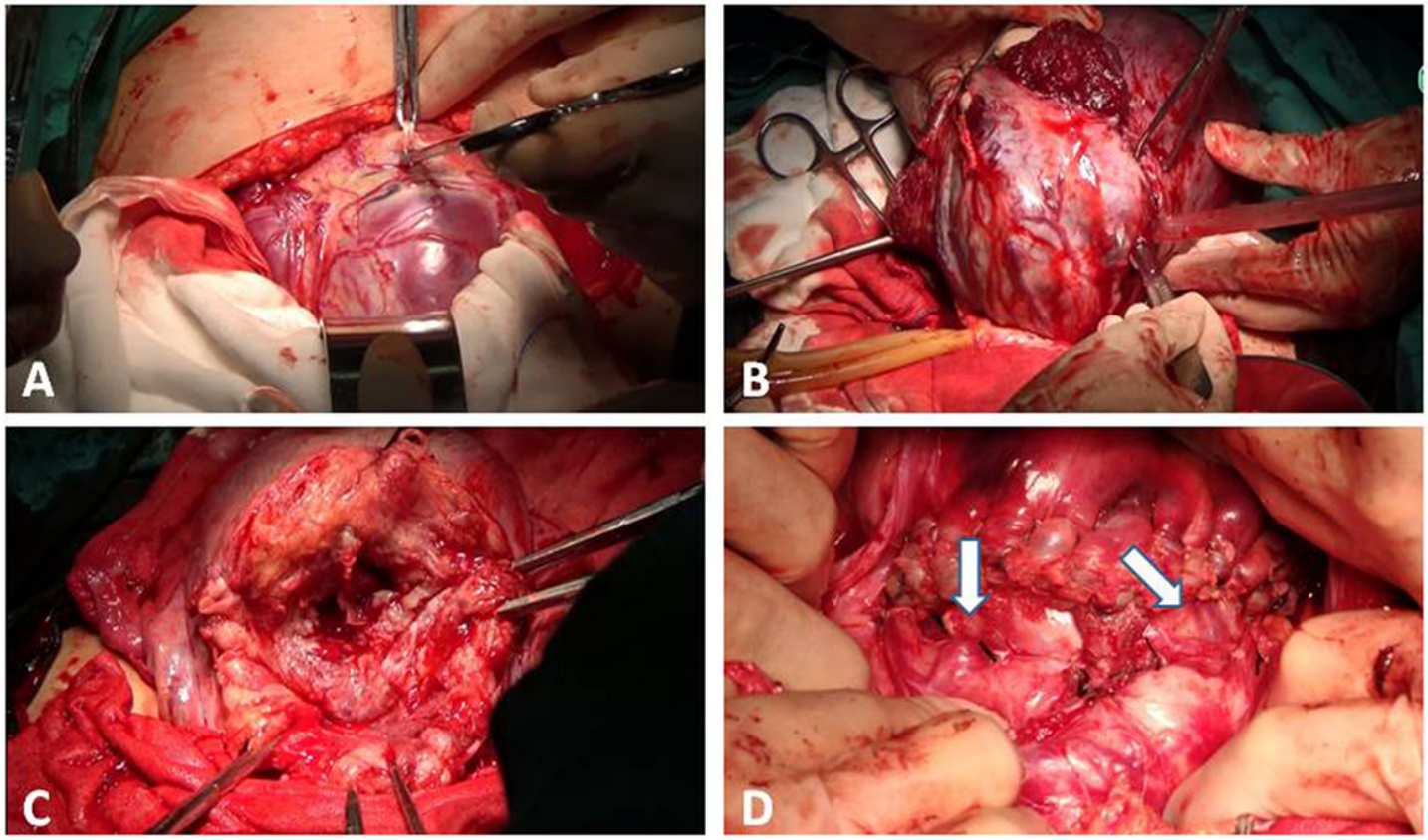

Figure 4

Process of the procedure A. The uterine incision was over the upper border of the placenta. B. A tourniquet was put as low as possible at the lower segment of the uterus. The bladder was pushed down and the anterior myometrium was partially resected with the placenta unseparated. C. A single continuous suture was made along the lower lip of the uterine incision. D. The lower transverse incision at the uterine was sutured in one layer. This area was still permeated with tortuous vessels (the arrow).