# Metastasis of missed cholangiocarcinoma in the left lobethrough abdominal wall laparoscopic port-site and umbilicus after laparoscopic cholecystectomy: case report and literature review

**Lesheng Huang**
Guangdong Hospital of Traditional Chinese Medicine
**Hongyi Li**
Guangdong Hospital of Traditional Chinese Medicine
**Jun Chen**
Guangdong Hospital of Traditional Chinese Medicine
**Jinghua Jiang**
Guangdong Hospital of Traditional Chinese Medicine
**Wanchun Zhang**
Guangdong Hospital of Traditional Chinese Medicine
**Tianzhu Liu** ( 153462964@qq.com )
Guangdong Hospital of Traditional Chinese Medicine https://orcid.org/0000-0001-6213-9356

**Case report**

**Keywords:** laparoscopic cholecystectomy, missed malignancies, cholangiocarcinoma, port-site metastasis, sister mary joseph's nodule

**Posted Date:** July 24th, 2020

**DOI:** https://doi.org/10.21203/rs.3.rs-45597/v1

# Abstract

**Introduction:** Laparoscopic cholecystectomy (LC) has been widely used by surgeons. However, a serious but rare condition may be happened, which is the missed diagnosis of intraperitoneal malignant tumor. If the malignancy exists, the changes of the abdominal environment or the laparoscopic operation might brought the cancer cells to the abdominal cavity or the abdominal wall. The missed laparoscopic malignant tumors are prone to metastasis, especially at the laparoscopic port-site. More extreme condition will be located in the navel, which is known as Sister Mary Joseph's nodule(SMJN).

**Case presentation:** A 63-year-old female who had undergone cholecystectomy and choledocholithotomy ten months ago was hospitalized for upper abdominal pain. Laboratory examination indicated that the most of tumor markers were increased. CT scan revealed that there was a diffused irregular and progressively enhanced mass around the left lobe bile duct, multiple enlarged lymph nodes in the abdominal cavity and multiple nodular lesions were found under the costal margin of the right upper abdominal wall, right lower abdominal wall and the umbilicus. Biopsy of the nodules under the original surgical scar showed an infiltrative or metastatic middle differentiated adenocarcinoma. So the diagnosis was left lobe cholangiocarcinoma of the liver, multiple lymph nodes metastasis in the abdominal cavity and multiple implant metastasis in abdominal wall laparoscopic port-site and umbilical.

**Conclusion:** In laparoscopic cholecystectomy, surgeons should not only focus on the local lesions, like gallstone in biliary system, but also look around other the tissues and organs to avoid missing the abdominal malignant tumor or other lesions. When atypical symptoms or abnormalities have been found pre-operation, all abdominal organs should be evaluated in detail to avoid missed diagnosis of potential malignant tumors. On the other hand, when there is a nodule in the umbilicus, all the organs and tissues in abdomen should be examined to find the potential malignant tumor. Finally, multiple cholelithiasis in the left lobe of the liver should be regarded as a high risk factor for cholangiocarcinoma.


# 1. Background

Laparoscopic cholecystectomy has been widely used in surgery. Compared with traditional laparotomy, laparoscopic surgery has advantages of less bleeding, minor wound and faster wound healing, however, laparoscopic surgery also has limitation in limited surgical field. Thus it is incapable to carry out effective exploration of the whole abdomen and may lead to some serious postoperative complications, one of them is missed diagnosis of intraperitoneal malignancies before and during laparoscopic (average incidence of missed diagnosis was 0.65%)[1–3].

The implantation and metastasis of the laparoscopic port-site after laparoscopic surgery is based on the premise that there is a malignant tumor in the abdominal cavity. Direct implantation, contamination of surgical instruments, aerosolization of tumor cells, chimney effect, excessive manipulation of tumor, pneumoperitoneum, hematogenous spread, local and systemic effects of carbon dioxide and decrease of abdominal blood flow caused of port-site could lead metastasis through laparoscopic port-site[4–8].

Umbilical metastasis, also known as Sister Mary Joseph's nodule(SMJN), was found by Mary Joseph Dempsey(1856–1939) who was the assistant surgeon of Dr.William Mayo at Mayo Clinic. He noticed that some patients with abdominal malignant tumor usually have nodular projections at the umbilicus, and may lead to be poor prognosis[9].

In general, missed diagnosis of abdominal malignant tumor before and during laparoscopic cholecystectomy is a rare condition. Herein, we report a case about the missed diagnosis of left lobe cholangiocarcinoma before and during the laparoscopic cholecystectomy and was found the metastasis in the abdominal wall laparoscopic port-site and umbilicus ten months later, along with a review of medical literature.

## 2. Case Description

A 63-year-old female who had undergone cholecystectomy and choledocholithotomy ten months ago was hospitalized for upper abdominal pain for more than five months. The patient had no jaundice in skin or eyes and had no fever. Physical examination presented that the surgical scars under the right costal margin and right lower abdominal wall with hard texture and poor mobility. The epigastric tenderness was positive.

Laboratory examination indicated that the most of tumor markers were increased as follow: CEA: 54.29 ng/ml(normal range: 0–5 ng/ml), CA19-9: 30.7 ng/ml (normal range: 0–30 ng/ml), CA125: 546.50 ng/ml (normal range: 0–25 ng/ml), CA15-3: 63.15ug/ml (normal range: 0-24ug/ml) and CA72-4: 259.1ug/ml (normal range: 0-6.9ug/ ml). The other laboratory indicators were no obvious abnormalities.

Non-enhanced computed tomography(CT) scan revealed that the left part of the liver was atrophic. There were multiple different sizes hepatolith surrounded by liquid density located in the left hepatic duct (Fig. 1A). The gallbladder was absence after surgery. Contrast-enhanced CT showed that there was a diffused irregular and progressively enhanced mass around the left lobe bile duct. The intrahepatic bile duct became widened as “soft rattan sign”. Multiple enlarged lymph nodes were seen in the abdominal cavity and multiple nodular lesions were found under the costal margin of the right upper abdominal wall, right lower abdominal wall and the umbilicus (Fig. 1B-D, Fig. 2A-D).

Biopsy of the nodules under the original surgical scar on the right upper abdominal wall showed an infiltrative or metastatic middle differentiated adenocarcinoma, while some mucinous adenocarcinoma were found in the soft tissue of the skin(Fig. 3A-B).

According to the imaging, pathological result and surgical history, the diagnosis of left lobe cholangiocarcinoma of the liver, multiple lymph nodes metastasis in the abdominal cavity and multiple implant metastasis in abdominal wall laparoscopic port-site and umbilical were made.

## 3. Discussion

The judgment of missed abdominal malignant tumor in laparoscopic cholecystectomy was according to the doubling time of tumor volume, the degree of cell differentiation and the natural course of disease. Generally speaking, the time of postoperative discovery of common abdominal malignant tumors, such as liver cancer and pancreatic cancer are 10 months, gastric cancer and colorectal cancer is one year[10].

In this case, laparoscopic cholecystectomy was performed, and metastatic nodules were found in the laparoscopic port-sites and umbilicus ten months later. The reason lies in the fact that the surgeons completed laparoscopic cholecystectomy without carrying out thorough radiology and laboratory examination to exclude the possibility of cholelithiasis with cholangiocarcinoma preoperatively. Due to the limitation of laparoscope on limited visual field and lack of attention to the left lobe lesions before and during operating, the left lobe cholangiocarcinoma was missed.

Reasonable and comprehensive preoperative evaluation, including radiology and laboratory examination, could apply more details, partly avoid the missed diagnosis, and improve the prognosis. At the gallstone consensus meeting, the National Institutes of health stressed that patients with atypical pain or dyspepsia need further examination to determine the cause of their symptoms[11]

From the current literature, we know that the best way to avoid the port-site metastasis is to avoid directly touching and slicing malignant tumors, and strictly follow the laparoscopic tumor operation specifications[7, 12, 13]. For this case, metastasis was still found in the port-site after laparoscopic cholecystectomy ten months later because of the mutual contaction of malignant tumor cells and Laparoscopic forceps in enterocoelia. The reason may be the deposition of malignant tumor cells in the injured site, and of course, the direct pollution of malignant tumor cannot be excluded. For the pathological report, radiology results and operation history, we could consider that the metastasis precisely origin from bile duct epithelial [14] and may relate to laparoscopic surgery.

Cholangiocarcinoma originated from the left lobe of the liver is closely related to cholelithiasis[15–17]. It is liable to induce cholangiocarcinoma under the stimulation of cholestasis, bacterial infection and inflammation caused by long-term cholelithiasis, but its onset is concealed and lack of specificity, which is easily covered by the symptoms of cholelithiasis and cholangitis[18]. The high density stones and the accompanying dilatation of bile duct may cause more difficult to distinguish the adjacent soft tissue lesions of cholangiocarcinoma, the thickening of the wall of chronic inflammatory bile duct and the invasion area of early cancer[19].

Histologically, cholangiocarcinoma can be divided into three types: nodular type, intraductal papillary type and bile duct wall infiltrating type. Clinically, nodular type is the most common type, and the latter two are relatively rare. The enhancement mode of nodular cholangiocarcinoma in multi-phase dynamic contrast-enhanced CT or magnetic resonance(MR) scan is presented as follow: the enhancement of tumor tissue in arterial phase, the enhancement of fibrous tissue in portal phase and delayed phase, and non-enhancement of necrotic focus[19]. Nodular type of cholangiocarcinoma has less missed diagnosis probability. The imaging features of the latter two are not typical, that may lead to higher risk of missed

and misdiagnosis[20]. Hepatic capsular shrinkage is also an imaging feature of cholangiocarcinoma with a low specificity for both benign and malignant liver lesions can occur[21].

Umbilical metastasis, also known as SMJN named by Dr. Hamilton Bailey[22].The most common pathological type of SMJN is adenocarcinoma[23]. The most common primary tumor sites are stomach for male, colon and female ovaries; other tumors sites such as pancreas, liver, biliary tract, fallopian tube and uterus also had been reported[24–26]. The routes of metastasis could be peritoneum, blood-borne artery, vein system, lymphatic vessel, and along the ligament of embryonic origin (round ligament, falciform ligament) or laparoscopic direct implantation[27]. Surgery and trauma increase the release of tumor cells into the blood circulation, and tissue damage has also been proved to promote the growth of tumor cells, these two factors may lead to abnormal metastasis of tumor eventually[28]. As in this case, it was metastasized to the umbilicus by laparoscopic surgery.

# 4. Conclusions

Firstly, on preoperative, the patients with atypical symptoms or abnormal findings should finish related radiology and laboratory examination to prevent the misdiagnosis of abdominal malignant tumors during laparoscopy. On the other hand, SMJN is an important manifestation of intraperitoneal malignant tumor metastasis and it should be treated with caution for the navel nodule. When it appears, all organs in the abdomen should be examined in detail by CT ,MRI or Positron Emission Tomography-Computed Tomography(PET-CT) scan to find the potential intraperitoneal malignant tumor. If necessary, a biopsy is appropriate. At last, the multiple cholelithiasis located in the left lobe of the liver is a high risk factor for intrahepatic cholangiocarcinoma.

- **Consent**

The patient gave informed consent and agreed with doctors to use her medical data for writing, teaching and publication purposes.

# Abbreviations

SMJN: Sister Mary Joseph's nodule; CT: computed tomography; MR:magnetic resonance; PET-CT: Positron Emission Tomography-Computed Tomography; H & E: hematoxylin and eosin

# Declarations

### Consent

The patient gave informed consent and agreed with doctors to use her medical data for writing, teaching and publication purposes.

### Compliance with Ethical Standards

This study was approved by the ethics committee of Guangdong Hospital of Traditional Chinese Medicine.

### Conflict of interest

The authors declare that they have no conflict of interest.

### Authors' contributions

LH & HL was involved in acquisition of data, preparing the figures and drafting the manuscript. JC and JJ designed and revised the manuscript. WZ was involved in analysis and interpretation of data. TL was involved in review and revise the manuscript. All authors have read and approved the final manuscript. LH & HL contributed equally to the article.

### Acknowledgements

We greatly appreciate the assistance of the staff of the Department of Hepatobiliary surgery, Guangdong Hospital of Traditional Chinese Medicine, and thank them for their efforts.

### Data availability statement

Some or all data, models, or code generated or used during the study are available from the corresponding author by request(TL, Email: 153462964@qq.com).

### Funding

This research received no specific grant from any funding agency in the public, commercial, or not-for-profit sectors.

## References

1. N J, T. M, and HariS S, *Original Article - Missed malignancies at laparoscopic cholecystecomy: A new emerging problem.* Indian Journal of Surgery (ISSN: 0972–2068) Vol 68 Num 1, 2006. **68**.
2. Gal I, et al. Laparoscopic cholecystectomy. Risk of missed pathology of other organs. Surg Endosc. 1998;12(6):825–7.
3. Slim K, et al. Malignant tumors missed at laparoscopic cholecystectomy. The American Journal of Surgery. 1996;171(3):364–5.
4. Kim ZG, et al. Impact of Laparoscopic CO2-insufflation on Tumor-associated molecules in cultured colorectal cancer cells. Surgical Endoscopy Other Interventional Techniques. 2002;16(8):1182–6.
5. Xu L, et al. [Analysis of Clavien-Dindo classification and its prognosis factors of complications after laparoscopic right hemicolectomy]. Zhonghua Wai Ke Za Zhi. 2018;56(12):900–5.
6. Emoto S, et al. Port-site metastasis after laparoscopic surgery for gastrointestinal cancer. Surg Today. 2017;47(3):280–3.

7. Wang Y-Y, et al., *Surgical Treatment of Port-Site Metastases After Laparoscopic Radical Resection of Gastrointestinal Tumors.* Journal of Laparoendoscopic & Advanced Surgical Techniques, 2020.
8. Pinho GZ, et al. Port-Site Metastasis of Undiagnosed Pancreatic Adenocarcinoma After Laparoscopic Radical Prostatectomy: Case Report and Literature Review. J Endourol Case Rep. 2018;4(1):144–6.
9. Fratellone PM, Holowecki MA. Forgotten node: a case report. World J Gastroenterol. 2009;15(39):4974–5.
10. Ren JI, Yong NI, Han Q, *Analysis of Missed Diagnosis of Malignant Tumor During Laparoscopic Cholecystectomy.* Journal of Hepatobiliary Surgery, 2012.
11. *NIH Consensus conference. Gallstones and laparoscopic cholecystectomy.* JAMA, 1993. **8**(269).
12. Schneider C, et al., *Efficacy of surgical measures in preventing port-site recurrences in a porcine model.* Surgical Endoscopy & Other Interventional Techniques, 2001. **15**(2): p. 121–125.
13. Reymond MA, Lippert H, Franklin ME, *Port Site Tumors: Means of Prevention.* Sages Manual, 2006: p. 393–401.
14. Rao S, et al., *Delayed presentation of port-site metastasis from an unknown gastrointestinal malignancy following laparoscopic cholecystectomy*. Singapore Med J, 2014. 55(5): p. e73-6.
15. Kirstein MM, Vogel A. Epidemiology and Risk Factors of Cholangiocarcinoma. Visc Med. 2016;32(6):395–400.
16. Kim HJ, et al. Hepatolithiasis and intrahepatic cholangiocarcinoma: A review. World J Gastroenterol. 2015;21(48):13418–31.
17. *Intra-hepatic and extra-hepatic cholangiocarcinoma:New insight into epidemiology and risk factors.* World Journal of Gastrointestinal Oncology, 2010(11): p. 12–21.
18. Aishima S, et al. Histological features of precancerous and early cancerous lesions of biliary tract carcinoma. J Hepato-Biliary-Pancreat Sci. 2014;21(7):448–52.
19. Chung YE, et al. Varying Appearances of Cholangiocarcinoma: Radiologic-Pathologic Correlation. RadioGraphics. 2009;29(3):683–700.
20. Joo I, Lee JM, Yoon JH. Imaging Diagnosis of Intrahepatic and Perihilar Cholangiocarcinoma: Recent Advances and Challenges. Radiology. 2018;288(1):7–13.
21. Blachar A, Federle MP, Brancatelli G. Hepatic capsular retraction: spectrum of benign and malignant etiologies. Abdom Imaging. 2002;27(6):690–9.
22. Bailey H. (1949). Demonstrations of physical signs in clinical surgery. 11th edn. Williams & Wilkins, B., p 227.
23. Agrawal V, et al. Umbilical nodule in cholangiocarcinoma. Sister Mary Joseph Nodule. Saudi J Gastroenterol. 2012;18(5):345–6.
24. Li Y, et al. Sister Mary Joseph's nodule in endometrial carcinoma: A case report. World J Clin Cases. 2019;7(20):3358–63.
25. Luu AM, et al. Surprising Twist in the Plot – Sister Mary Joseph's Nodule of Pancreatic Cancer Mimicking Wound Infection after Umbilical Hernia Repair. Journal of Gastrointestinal Cancer.

2019;50(1):113–5.
26. Pecollet M, et al., *[Umbilical nodules].* Rev Med Interne, 2019.
27. F C, P., *Sister Mary Joseph's nodule: a clinical and histologic study*. Journal of the American Academy of Dermatology, 1984. 4(10).
28. Zhang Z, et al. Umbilical metastasis derived from early stage rectal cancer: a case report. World J Surg Oncol. 2014;12:82.

# Figures

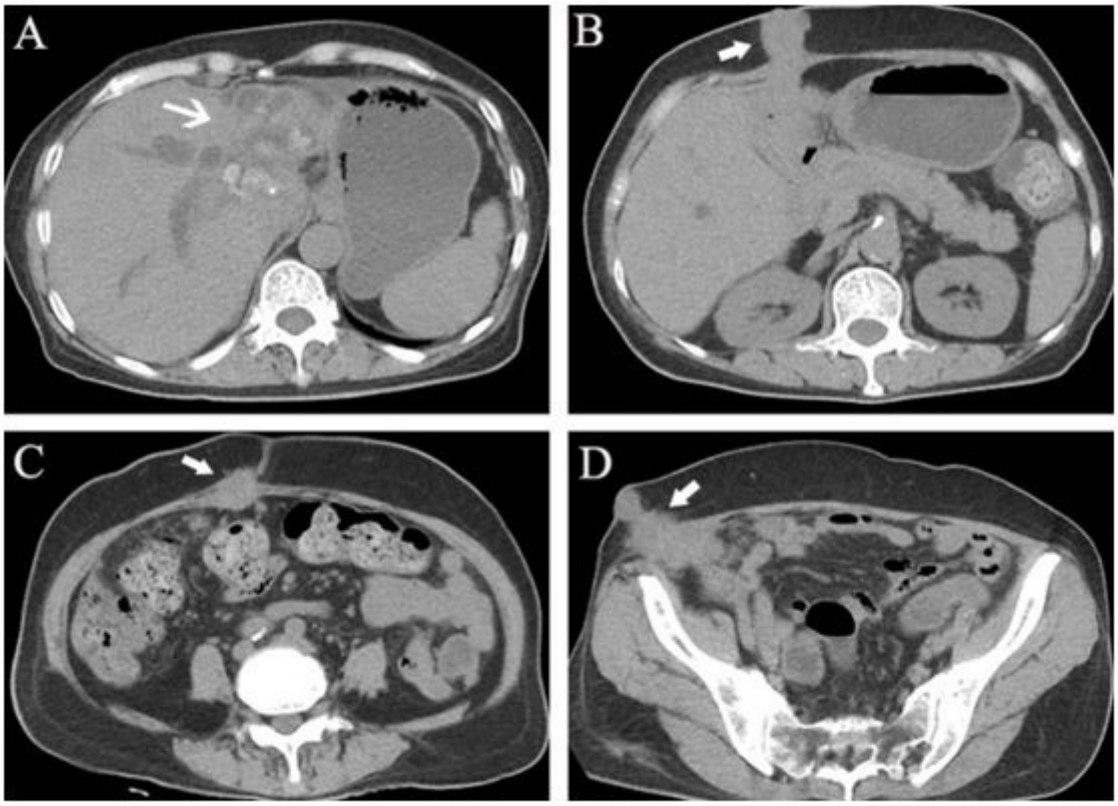


**Figure 1**

There are many stones of different sizes in the left lobe bile duct. The intrahepatic bile duct is soft rattan like expansion.

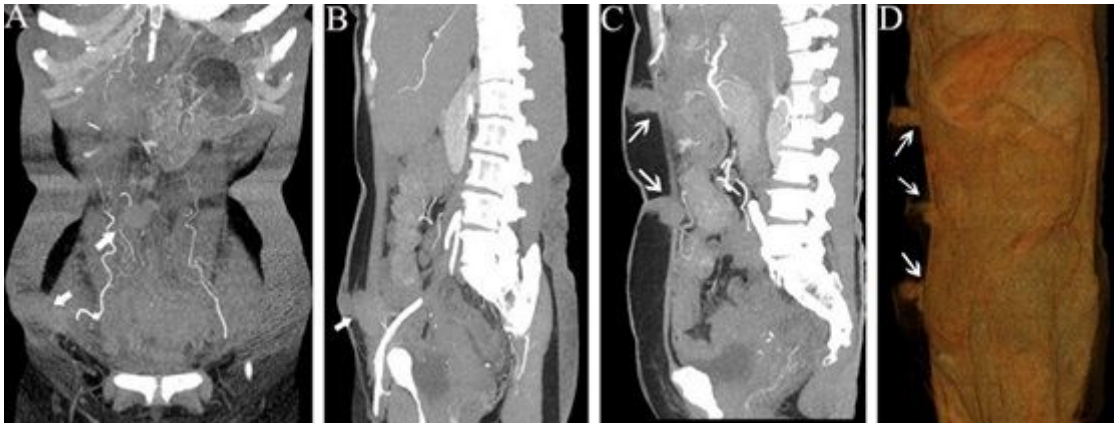


**Figure 2**

There were multiple metastatic nodule shadows in the right upper and lower abdominal wall laparoscopic trocar port site and umbilicus.

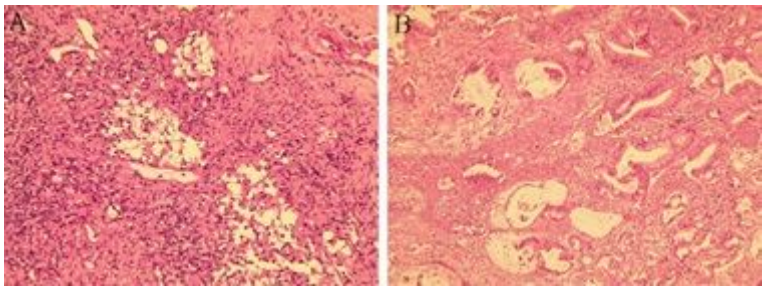


**Figure 3**

The tumor cells were arranged as Glandular tissue and infiltrative growth in the background of fibrous and fat tissue(A: H & E 40×, B:H & E 100×)