Increase of foreign body and harmful substance ingestion and associated complications in children: a retrospective study of 1199 cases from 2005 to 2017

Arne Speidel
Universitatsklinikum Ulm Klinik fur Kinder- und Jugendmedizin

Lena Woelfle
Universitatsklinikum Ulm Klinik fur Kinder- und Jugendmedizin

Benjamin Mayer
Universitat Ulm

Carsten Posovszky (Carsten.posovszky@uniklinik-ulm.de)
University Medical Center Ulm https://orcid.org/0000-0002-9487-8812

Research article

Keywords: Foreign body ingestion, food bolus impaction, caustic ingestion, children

Posted Date: July 23rd, 2020

DOI: https://doi.org/10.21203/rs.3.rs-45920/v1

Version of Record: A version of this preprint was published on December 18th, 2020. See the published version at https://doi.org/10.1186/s12887-020-02444-8.

Abstract

Background

Children with a history of caustic or foreign body ingestions (FBI) are frequently presented at the emergency department. An uncertain case history, the different objects and diverse clinical presentation may complicate or delay a proper management and cause serious complications.

Methods

A structured retrospective data analysis of patients presented in between January 2005 and December 2017 at the University Medical Centre Ulm was performed. All patients up to 17 years of age with food impaction, foreign body or harmful substance ingestion were included by selection of the corresponding International Statistical Classification of Diseases and Related Health Problems (ICD10-GM) codes. Descriptive statistics, parametric or non-parametric tests, and linear regression analysis were performed.

Result

In total, 1199 cases were analysed; mean age 3.3 years (SD 3.12; range 7 days to 16 years), male to female ratio 1.15:1, thereof 194 (16.2%) were hospitalized. The majority (n = 619) had no symptoms, 244 out of 580 symptomatic patients complained retching or vomiting. The annually recorded cases increased from 66 in 2005 to 119 in 2017 with a rise of the percentage of all emergency cases by 0.52% since 2010 to 1.34% in 2017. Most frequently, coins were ingested (18,8%). Radiopaque objects accounted for 47.6%, and sharp objects for 10.5% of the FBI, which were significantly more often ingested by girls ($p < 0.000015$ and $p < 0.000024$, respectively). Button battery ingestion was recorded in 63 cases with a significant annual increase ($R2 = 0.57$; beta = 0,753; $p < 0.003$). The annual rate of complications raised significantly ($R2 = 0.42$; beta = 0,647; $p < 0.017$).

Conclusion

Children with FBI are increasingly presented at emergency departments. Special attention is necessary to prevent serious complications, especially in asymptomatic children. Further preventive measures within the home environment are needed to stop this trend.

Background

Accidental caustic and foreign body ingestion (FBI) is common in children and up to 75% of children under six years of age are concerned as infants evaluate objects by tasting and swallowing [1–4]. Sometimes they may ingest the object or chemical substance at an unobserved moment and are presented because an object or liquid is missing or due to symptoms without any history [5]. The initial

assessment includes careful history-taking of symptoms, timing of presentation, type of foreign body or chemical agent, and associated conditions, complemented by physical examination assessing patient status, vital signs, airway evaluation and emergency conditions. Many kinds of objects and toxic substances are reported to be ingested including coins, toys, jewellery, button batteries, magnets, fish bones, household items, household cleaning substances, caustic soda, and many others as well as food impaction [6–9]. The management depends on the individual presentation of the patient, underlying oesophageal pathology, the ingested object or liquid and its localization as well as on the physician's clinical experience [4, 8]. Most objects will pass the gastrointestinal tract (GIT) spontaneously, especially if they have reached the small intestine at initial location and even up to 50% of large foreign bodies (FB) with a diameter over 30 mm may pass the GIT without intervention [10, 11]. However, FBs in the oesophagus or sharp and relatively large FBs will require an intervention, mostly rigid or flexible endoscopy and rarely by Foley catheter extraction, oesophageal bougienage, McGill forceps and magnetic catheter [1, 2, 12, 13]. Button batteries, multiple magnets and sharp objects need to be removed immediately to avoid serious complications [2, 4, 14–19]. Caustic agent ingestion is associated with high morbidity depending on the extend of injury at initial endoscopic evaluation [3, 8]. Food bolus impaction in children and adolescents may be a clinical feature of an underlying eosinophilic oesophagitis and not only needs a therapeutic but also a diagnostic endoscopy [20]. Depending on the objects and agents a variety of complications is associated ranging from mucosal abrasions, lacerations, perforations, mediastinitis, peritonitis, strictures to death [2, 21, 22]. Complications are more likely if the FB remains impacted for an extended period of time [2, 5].

Methods

We performed a structured retrospective review of medical records collected over 13 years (from January 2005 to December 2017) on paediatric patients presented with food bolus impaction and ingestion of foreign objects or chemical substances, at the Department of Paediatric and Adolescent Medicine, University Medical Center Ulm, Germany. It is the only Paediatric Hospital of a catchment area counting about 108.000 children. This study adheres to the ethical principles of the Declaration of Helsinki. It was approved by the institutional review board Ulm (No.399/17) and for the data presented here the requirement to obtain informed consent was waived.

In total, 2427 patients entries aged 0 to 17 years were selected by the corresponding International Statistical Classification of Diseases and Related Health Problems (ICD10-GM) codes including K22.1-3, T18.0-5, T28.5-9, T30.4, T52.0, T55, T60.8, T62.1-2, and T65.8-9 from the hospital database (Fig. 1). Episodes not corresponding to an accidental ingestion e.g. alcoholic intoxication, iatrogenic injuries, and erroneous coding were excluded and multiple presentations for the same event were merged.

Patient demographic information, associate conditions, type of foreign body or chemical substance, clinical symptoms, diagnostic and therapeutic management, and complications were collected from the electronic patient file and electronic database. The miscellaneous ingested foreign bodies, food boli and chemical substances were classified into 30 categories according to their characteristics (object type

(solid, liquid and others), object form and size (below or over 2*3 cm for infants, and below or over 3*5 cm in children > 1 year, and sharp), organic or anorganic, radiopaque or not, and object class (metal, plastic, wood, glass, food, drug, button battery, other batteries, coins, magnet, caustic solution, acid solution, oil, paper, plants, body parts, surfactant/cleanser, stone, and cigarette).

A literature research performed on June 15th 2020 using PubMed.gov. with the key words “foreign body”, “ingestion”, and “children” retrieved 1367 articles. Appropriate articles including retrospective studies, observational studies, randomised controlled trials, reviews and guidelines were selected.

All data were entered and arranged in a single database spreadsheet (Excel XP, Microsoft Corporation, USA). Categorical data were reported as count and percentage. Continuous data were reported as mean and standard deviation or median, minimum or maximum or range, according to data distribution. Further statistical analysis was performed using commercial statistical software (Statistical Package for Social Science (SPSS), version 26, IBM, Germany). To evaluate parametric data for independent samples, Student’s t-test were used. An inductive statistical evaluation of the nominal data was carried out using a chi-square test. This enabled the odds ratio to be calculated in suitable cases. Linear relationships between observed data over time were analyzed by linear regression model and the percentage of variance in the dependent variable was expressed by R-squared. An explorative p-value < 0.05 was considered statistically significant.

All authors had access to the study data and reviewed and approved the final manuscript.

Results

In total, 1199 cases were evaluated. The mean age was 3.3 years (median = 2.23, SD = 3.12; range = 16.97) with no significant variation in time (Supplemental Fig. 1). Thereof, 641 (53,3%) were male and 558 (46.5%) female, ratio 1.15:1, with a similar age distribution (mean age 3.17 and 3.45 years, respectively). Annually, 41 to 137 cases were assessed with a time averaged mean annual rate of 92 showing a significant increase over time (R2 = 0.79; beta = 0,886; p = 0.000054) (Fig. 2). The annual rate increased by 80% from 2005 to 2017 and reached an incidence of 11.1 per 10.000 children in the catchment area. This was also reflected by a raise of the percentage of all emergency cases by 0.52% since 2010 to 1.34% in 2017 (Supplemental Fig. 2). Admission to the hospital was necessary in 194 (16.2%) cases ranging from 7 to 22 per year (mean = 14.9) (Fig. 2) with a mean duration of hospitalisation of 2.99 days (median = 2.0; SD = 3.41; maximum 27d). Hospital admission was more frequent after food bolus impaction (42.1%) and button battery ingestion (38.1%), 24 cases each (supplemental table 1).

Most patients (n = 1102; 91.9%) were presented within the first 24 hours after ingestion. Comorbidities were documented in 127 cases (10.6%). Psychiatric disorders (n = 16), mental retardation (n = 13), condition after surgery of oesophageal atresia (n = 7) and eosinophilic oesophagitis (n = 2) or other conditions (n = 101) were registered. Food bolus impaction was associated with a higher rate of comorbidities (21.1%).

Solid foreign bodies were specified in 921, soft or flexible in 67 (e.g. sponge, leaf), and liquids in 151 cases. In 65 (5.4%) episodes the ingested object was not specified. Mostly inorganic objects were swallowed (1018; 84.9%). Many objects were referred to as radiopaque FB (n = 571; 47.6%), and predominantly ingested by girls (n = 305; p = 0.000015). Similarly, sharp objects (n = 126; 10.5%) were frequently swallowed by girls (n = 81; p = 0.000024). Coins (n = 226), metallic objects (n = 197) and cleaning agents (n = 148) were the most common types of accidentally swallowed objects and liquids (table 1). Food bolus impaction accounts for 57 (4.8%) and button batteries for 63 (5.3%) episodes (table 1). Button battery ingestion was recorded in 63 cases with a significant annual increase (R2 = 0.57; beta = 0,753; p < 0.003) and affects mostly toddlers that are significantly younger (mean age 2.79 years; median 1.87; SD 2.40; range 11.64) than those with coin ingestion (p < 0.05; effect size 0.214). Children swallowing cleanser are significantly younger (mean age 2.5 years) than those with coin, metal, plastic or drug ingestions (p < 0.05). There was no significant annual increase of hazardous ingestions (R2 = 0.11; beta=-0,336; p = 0.262), but girls were more often affected (52.5%) in this group.

Medical imaging was performed in half of the cases (n = 603; 50.3%) with a significant rise of the annual examination rate (R2 = 0.79; beta = 0,886; p = 0.000054). In girls, imaging was performed significantly more often (n = 313; p = 0.00017). Most commonly x-ray examination of the chest (n = 452; girls n = 243) and abdomen (n = 186; girls n = 90), followed by oesophagus contrast roentgenoscopy in 29 cases and others (n = 33) including magnet resonance imaging (MRI), computer tomography (CT), or ultrasound were conducted. In 393 cases the FB could be clearly determined, 260 were located proximal and 133 distal of the flexura duodenojejunalis. FB were typically localized by x-ray (n = 350; 86.6%).

Symptoms were documented in 619 cases (51.6%), mostly retching and vomiting (n = 244), followed by coughing fits (n = 152), pain (n = 133), hypersalivation (n = 44), dysphagia (n = 30) and miscellaneous complaints (e.g. abnormalities of behaviour, respiratory problems, globus sensation, bleeding) (table 2). Medical complaints were significantly less frequent if the FB localizes distal of the flexura duodenojejunalis (odds ratio 0.44; 95%CI 0.29–0.68, p < 0.05) (supplemental table 2). An oesophageal position of the FB was frequently associated with symptoms (83.9%). Most patients with food bolus impaction presented symptoms (93%). Object associated symptoms and complications are summarized in table 3.

Complications were retrieved in 65 cases (5.4%) with a significant rise of the annual rate (R2 = 0.42; beta = 0,647; p = 0.0017). Most patients had mucosal injuries of various degree, frequently superficial (n = 56), followed by deeper caustic tissue damage (n = 11), necrosis (n = 10), perforation (n = 5), but no fistulation. Fever (n = 10), and other complications (n = 12) were associated, but no death occurred.

The primary management was awaiting spontaneous passage for the most FBI, reassurance of the parents and guidance to undertake faecal follow up observations. Depending on the patient status, symptoms, localisation of the FB, and suspected fixed, sharp or harmful FB therapeutic interventions were required. Interventional removal was performed in 126 cases including rigid esophagoscopy (n = 59) and flexible esophagogastroduodenoscopy (n = 54), others (e.g. colonoscopy, McGill forceps) (n = 9) or

surgery (n = 4). Successful recovery of the FB was documented in 128 cases including 49 by flexible upper endoscopy (90.7%), 48 by rigid esophagoscopy (81.3%), 4 by surgery, and 27 miscellaneous retrievals (e.g. colonoscopy, manual oral or rectal recovery, vomiting). Surgery was performed due to oesophageal impaction of a button battery with fistulation, multiple magnets (n = 14) ingested by a patient with a neurologic disease leading to bowel perforation and fever, bowel obstruction by a chestnut with obstructive ileus, and a migrated pistachio shell through the wall of the oesophagus into the mediastinum causing stridor.

Discussion

The analysis of 1199 accidental paediatric foreign body and chemical substance ingestions over thirteen years (2005–2017) at a German University Medical Centre revealed a significant increase in the annual case rate of 80% to about 11 per 10.000 children in the catchment area. This has also been reported in the United States with an annual increase of 91.5% from 9.5 in 1995 to 18 per 10.000 children with FBI in 2015 [7]. In contrast, considerably less FBI have been reported at Chiang Mai University in Thailand (only 194 cases from 2006 to 2017) with a population comparable to Ulm. This cannot be explained by different age limits (< 15 versus < 18 years) and the inclusion of ingestion of chemical substances in our study. Thus, other factors e.g. difficult access to medical care, fewer harmful items in the household, or better parental care may influence the observed lower frequency of FBI. The increase in our study affects all categories of objects and substances, many of them are increasingly used in German households. We observed an alarming increase of lithium button battery ingestions in infants which is associated with hospitalisation and major complications. This trend was already previously reported in comparable studies from the U.S. [23, 24].

Ingestion of foreign bodies or chemical substances is frequent among children below six years around the world [2, 3, 6, 25, 26]. A variety of foreign bodies is ingested of which coins appear the most common in our cohort like in many other studies [2, 7, 25, 27, 28]. However, the share was lower in our study (18%) compared to 49 to 88% reported by others, which may also reflect changes over time, differences in referral, selection and inclusion of the patients or classification and localization of objects as well as different diets and habits of the populations [2, 26, 28–30]. A retrospective observational study from Japan reported cigarettes be the most frequent FB (17%) in a cohort of younger children (median age 1 year 3 months) compared to only 2.3% registered cases in our study although the smoking prevalence in both countries are equivalent (WHO statistics data). In addition, the Yen coins are equivalent in size of 5 Cent to 2 Euro coins and should thus be as attractive for ingestion by toddlers [31]. Furthermore, the frequency of FBs in different categories vary between study populations, e.g. on second position fish bones were reported in Hong Kong [25], toys in the U.S.[7], plastics in Japan [31], and metallic objects in our study reflecting differences in the surrounding of children, the regional or cultural habits and age-dependent preferences in the investigated populations. The ingestion pattern also differs by sex, age and season (e.g. Christmas decoration)[7, 32]. We found, that girls are at risk for hazardous ingestion of sharp objects in our population. Another study showed that it is 2.5 times more likely that girls ingest jewellery or hair products compared to boys [7]. Here we also report relevant liquid ingestions of potential harmful

cleanser (12.3%), acid (2.7%) or base (0.6%). Caustic ingestions in children are mostly accidental and the severity depends on the type and quantity of the ingested substance [33].

A carefully obtained history, the type of ingestion and the level of suspicion will determine the course of action to avoid severe and life-threatening complications. In this study about sixteen percent of all patients required hospitalisation which is slightly more than in similar studies reporting around ten percent [7]. Twenty-two percent of patients with coin ingestion and more girls were hospitalized. The highest rate of complications was observed for button battery, glass and food ingestions. Others reported an increased prevalence of complications after sharp FB ingestion and a 4 to 8-fold increase of complications if the endoscopic retrieval of the oesophageal FB was performed later than 24 to 48 h after ingestion [34]. Serious complications and fatal outcomes have been reported for button battery ingestions [15, 16, 22]. Although we observed an annual increase of total cases and hazardous ingestions the number of patients admitted to the hospital was constant. In fact, the hospitalisation rate for coin ingestions was considerably lower in our cohort than the 55% reported in a European study [26].

In 2010, we implemented an algorithm for the diagnostic and therapeutic procedure at our hospital considering age of the patient, symptoms, size, type and location of radiopaque and radiolucent FB based on an interdisciplinary consent of the departments of radiology, paediatrics and adolescent medicine (including paediatric intensive care and paediatric gastroenterology), and ENT [35]. This may potentially influence the practice of admissions at our hospital and partially explain the constant number of hospitalized patients. In addition, the complication rate could be reduced by two percent from 6.8% before 2010 to 4.8%.

The majority of children are presented if a caregiver witnessed the ingestion of a FB or harmful substance by the child, an object is missing, or the child is symptomatic [30]. Presenting symptoms varied from the type and location of the ingested FB in our cohort, e.g. gagging, pain and coughing was frequently observed after coin ingestion. In contrast, a primary association with vomiting and drooling was reported in other studies after coin ingestions [2]. Patients with oesophageal FB mainly present drooling, vomiting and dysphagia especially if the FB is located in the first narrowing [36]. Still, most patients have a normal physical examination [30]. In children the diagnosis of FB ingestion may be complicated if the ingestion was not observed or the child is asymptomatic. Like in other studies about half of the patients were asymptomatic [6].

The European Society of Paediatric Gastroenterology and Nutrition (ESPGHAN) and European Society of Gastrointestinal Endoscopy (ESGE) recommend x-ray examination in all patients with suspected FB ingestion even without symptoms [19]. In our study, medical imaging was performed in half of the patients as nearly half of the objects were radiopaque. Imaging is important to confirm the presence, type, number and localisation of FB as well as detect complications e.g. perforation and guide the further management and follow-up if indicated [37]. X-ray of the chest and abdomen was frequently performed and detected the FB and its localization in 86%. Girls received significantly more medical imaging, particularly x-ray, inter alia due to ingestion of sharp objects. In fact, we observed an annual increase

particularly of x-ray investigations. Although hand held metal detectors (HHMD) have been shown to detect the majority of metallic FB and their localisation we did not use them in our department at that time [38]. It is proved that HHMD have a high sensitivity in detection of coins and seem to be a good early screening tool for a faster triage in the emergency room setting which may potentially reduce radiation exposure [39, 40].

The primary management was awaiting spontaneous passage for the most FBI, interventional removal was performed in 126 cases. The indication and timing of medical intervention to remove a foreign body was based on the location, size and type of the FB, duration of impaction, and patient symptoms according to our in-house standard with special attention towards button battery and magnet ingestion [35]. Initial localisation and size of the FB are determining factors of the likelihood of a spontaneous passage [2, 10]. Coins logged in the oesophagus may pass spontaneously if they are located in the distal one third of the oesophagus [41].

Removal of FB was mainly performed by rigid and flexible endoscopy according to the localization of the FB and symptoms of the patient and was successful in 81% and 90%, respectively. High success rates for rigid and flexible endoscopy have been reported in retrospective studies for oesophageal FB in children and adults with low rate of complications [12, 36, 42, 43]. The management of foreign body, food and toxic substance ingestions needs to be adapted for infants, e.g. smaller endoscopes with less than 6 mm diameter in children below ten kilo and paediatric-trained endoscopists are required [19, 44]. An algorithm on the usage of retrieval tools in foreign body ingestion and food impaction has been published [45]. Oesophageal food impaction is a frequent finding and requires special attention [46]. Removal is performed either en bloc or by a piecemeal approach using various grasping devices and after examining the oesophagus distal of the bolus also the push technique [17]. Food impaction is frequently associated with oesophageal pathology e.g. oesophageal atresia and eosinophilic esophagitis [47–49]. In addition, like in our study bowel obstruction or oesophageal perforation and fistulation by plants may require surgery. Magnet ingestion are rarely registered but frequently need surgery, especially children with neurological or psychiatric diseases have an increased risk [50, 51]. There is an alarming increase of magnet ingestions in emergency departments according to data from the National Electronic Injury Surveillance System (NEISS) [18].

We found a very low necessity of surgical interventions (0.3% of all, 2% of hospitalized cases, 3% of removed FB) in our cohort in contrast to 18% of hospitalized cases reported by others although providing paediatric surgery twenty-four-seven [52]. Some surgical interventions in historic cohorts may be prevented by experienced endoscopic removal nowadays [5]. After caustic ingestions in children mostly mild oesophageal lesions (88%) were identified and severe oesophageal lesions were associated with the presence of signs and symptoms (e.g. oral lesions, vomiting, dyspnoea, drooling, dysphagia, and hematemesis) [53]. Thus, endoscopy like in our study cohort could be avoided in absence of signs and symptoms [53].

This study again confirms the poor awareness of caregivers concerning the hazards of toys and household products for young children. In our study 9% of the children were presented more than 24 hours following ingestion, compared to 22% in a study from Pittsburgh of children who underwent esophagoscopy for suspected FB [30]. The lack of awareness for harmful situations requiring emergency care and prompt intervention may lead to serious complications, e.g. as observed with button batteries, pins and magnets [26]. Preventive measures, e.g. pressure on manufactures to package items appropriately for children below three years of age, effectively reduced toy ingestions in the U.S. in 2011 [7]. Furthermore, food and toys should not be marketed together to prevent children from ingestions of toys. Legal measures to protect children from the growing problem of unintentional button battery ingestion are required and should include child-resistant packaging for batteries, child-resistant closure of all consumer products that use button batteries, and warnings regarding the potential danger of ingestion [54, 55].

At the end, few limitations of this study should be underlined. Firstly, in a retrospective study design the conditions may not ideal and lack some relevant information not available from the electronic patient file. In addition, we only captured patients presented at our hospital which - as in many other studies - underrates the real frequency of accidental ingestions in children. In addition, comparability among related studies is limited as patient selection and categorization of objects may differ and age groups vary [2].

Conclusion

This study shows an alarming increase of children ingesting dangerous household items and liquids during the observation period of 13 years (2005–2017). This trend has to be stopped using primary preventive measures such as awareness training of caregivers throughout the population and elevated safety standards for childproof closures in toys and household objects and warnings regarding the potential danger of ingestion. Efforts for prevention of ingestion should particularly focus on the preschool toddler group. This might also require legal measures.

Necessary secondary prevention measures to lower the progress of injuries and complication rate due to FBI are fast and adequate diagnostic algorithms to ensure prompt removal if necessary as well as specific training of physicians on diagnostics and treatment.

Abbreviations

ENT ear, nose, throat

FB foreign body

FBI foreign body ingestion

Declarations

Availability of data

The datasets and analysis used during the current study are available from the corresponding author on reasonable request.

Conflict of interest/Competing interests

The authors declare no conflict of interest relevant to the manuscript.

There are no financial or non-financial competing interests

Authorship statement

C.P. is acting as the submission's guarantor and takes responsibility for the integrity of the work. A.S., and C.P. substantially contributed to conception and design of the study; A.S., and C.P. were involved in acquisition of data; A.S., and C.P. did analysis and interpretation of data; B.M., A.S. and C. P. statistical analysis; C. P. writing up of the first draft of the paper; A.S., B.M., and L.W. revising it critically for important intellectual content. All authors finally approved the version to be published.

Grant Support / Funding:

This work did not receive any funding.

References

1. Hesham AKH. Foreign body ingestion: children like to put objects in their mouth. World journal of pediatrics: WJP. 2010;6(4):301–10.
2. Jayachandra S, Eslick GD. A systematic review of paediatric foreign body ingestion: presentation, complications, and management. Int J Pediatr Otorhinolaryngol. 2013;77(3):311–7.
3. Kay M, Wyllie R. Caustic ingestions in children. Curr Opin Pediatr. 2009;21(5):651–4.
4. Lee JH. Foreign Body Ingestion in Children. Clin Endosc. 2018;51(2):129–36.
5. Witzleben AV, Reiter R, Hoffmann T, Posovszky C. Buried Foreign Body in the Esophagus - Unusual Cause of Dysphagia in a 2-Year-Old Child. Klin Padiatr. 2019;231(4):214–6.
6. Khorana J, Tantivit Y, Phiuphong C, Pattapong S, Siripan S. **Foreign Body Ingestion in Pediatrics: Distribution, Management and Complications**. *Medicina (Kaunas)* 2019, 55(10).
7. Orsagh-Yentis D, McAdams RJ, Roberts KJ, McKenzie LB. **Foreign-Body Ingestions of Young Children Treated in US Emergency Departments: 1995–2015**. *Pediatrics* 2019, 143(5).
8. Elshabrawi M, HH AK. Caustic ingestion in children. Expert Rev Gastroenterol Hepatol. 2011;5(5):637–45.
9. Reeves PT, Nylund CM, Krishnamurthy J, Noel RA, Abbas MI. Trends of Magnet Ingestion in Children, an Ironic Attraction. J Pediatr Gastroenterol Nutr. 2018;66(5):e116–21.

10. Lee JH, Lee JS, Kim MJ, Choe YH. Initial location determines spontaneous passage of foreign bodies from the gastrointestinal tract in children. Pediatr Emerg Care. 2011;27(4):284–9.
11. Yeh HY, Chao HC, Chen SY, Chen CC, Lai MW. Analysis of Radiopaque Gastrointestinal Foreign Bodies Expelled by Spontaneous Passage in Children: A 15-Year Single-Center Study. Front Pead. 2018;6:172.
12. Russell R, Lucas A, Johnson J, Yannam G, Griffin R, Beierle E, Anderson S, Chen M, Harmon C. Extraction of esophageal foreign bodies in children: rigid versus flexible endoscopy. Pediatr Surg Int. 2014;30(4):417–22.
13. Choe JY, Choe BH. Foreign Body Removal in Children Using Foley Catheter or Magnet Tube from Gastrointestinal Tract. Pediatr Gastroenterol Hepatol Nutr. 2019;22(2):132–41.
14. Jatana KR, Litovitz T, Reilly JS, Koltai PJ, Rider G, Jacobs IN. Pediatric button battery injuries: 2013 task force update. Int J Pediatr Otorhinolaryngol. 2013;77(9):1392–9.
15. Varga A, Kovacs T, Saxena AK. Analysis of Complications After Button Battery Ingestion in Children. Pediatr Emerg Care. 2018;34(6):443–6.
16. Krom H, Visser M, Hulst JM, Wolters VM, Van den Neucker AM, de Meij T, van der Doef HPJ, Norbruis OF, Benninga MA, Smit MJM, et al. Serious complications after button battery ingestion in children. Eur J Pediatrics. 2018;177(7):1063–70.
17. Committee ASoP, Ikenberry SO, Jue TL, Anderson MA, Appalaneni V, Banerjee S, Ben-Menachem T, Decker GA, Fanelli RD, Fisher LR, et al. Management of ingested foreign bodies and food impactions. Gastrointest Endosc. 2011;73(6):1085–91.
18. Abbas MI, Oliva-Hemker M, Choi J, Lustik M, Gilger MA, Noel RA, Schwarz K, Nylund CM. **Magnet ingestions in children presenting to US emergency departments**, **2002**–2011. *Journal of pediatric gastroenterology and nutrition* 2013, **57**(1):18–22.
19. Tringali A, Thomson M, Dumonceau JM, Tavares M, Tabbers MM, Furlano R, Spaander M, Hassan C, Tzvinikos C, Ijsselstijn H, et al. Pediatric gastrointestinal endoscopy: European Society of Gastrointestinal Endoscopy (ESGE) and European Society for Paediatric Gastroenterology Hepatology and Nutrition (ESPGHAN) Guideline Executive summary. Endoscopy. 2017;49(1):83–91.
20. De Matteis A, Pagliaro G, Corleto VD, Pacchiarotti C, Di Giulio E, Villa MP, Parisi P, Vassallo F, Ziparo C, Di Nardo G. **Eosinophilic Esophagitis in Children: Clinical Findings and Diagnostic Approach**. *Curr Pediatr Rev* 2019.
21. Geng LL, Liang CP, Chen PY, Wu Q, Yang M, Li HW, Xu ZH, Ren L, Wang HL, Cheng S, et al. Long-Term Outcomes of Caustic Esophageal Stricture with Endoscopic Balloon Dilatation in Chinese Children. Gastroenterol Res Pract. 2018;2018:8352756.
22. Gerner P, Pallacks F, Laschat M, Hermanns-Clausen M. [Health damages after ingestion of button batteries in childhood]. Bundesgesundheitsblatt Gesundheitsforschung Gesundheitsschutz. 2019;62(11):1354–61.
23. Litovitz T, Whitaker N, Clark L, White NC, Marsolek M. Emerging battery-ingestion hazard: clinical implications. Pediatrics. 2010;125(6):1168–77.

24. Sharpe SJ, Rochette LM, Smith GA. Pediatric battery-related emergency department visits in the United States, 1990–2009. Pediatrics. 2012;129(6):1111–7.
25. Cheng W, Tam PK. Foreign-body ingestion in children: experience with 1,265 cases. Journal of pediatric surgery. 1999;34(10):1472–6.
26. Gregori D, Scarinzi C, Morra B, Salerni L, Berchialla P, Snidero S, Corradetti R, Passali D, Group ES. Ingested foreign bodies causing complications and requiring hospitalization in European children: results from the ESFBI study. Pediatr Int. 2010;52(1):26–32.
27. Denney W, Ahmad N, Dillard B, Nowicki MJ. Children will eat the strangest things: a 10-year retrospective analysis of foreign body and caustic ingestions from a single academic center. Pediatr Emerg Care. 2012;28(8):731–4.
28. Crysdale WS, Sendi KS, Yoo J. Esophageal foreign bodies in children. 15-year review of 484 cases. Ann Otol Rhinol Laryngol. 1991;100(4 Pt 1):320–4.
29. Chinski A, Foltran F, Gregori D, Ballali S, Passali D, Bellussi L. Foreign bodies in children: a comparison between Argentina and Europe. Int J Pediatr Otorhinolaryngol. 2012;76(Suppl 1):76–9.
30. Sink JR, Kitsko DJ, Mehta DK, Georg MW, Simons JP: **Diagnosis of Pediatric Foreign Body Ingestion**: **Clinical Presentation**, **Physical Examination**, **and Radiologic Findings**. *The Annals of otology, rhinology, and laryngology* 2016, **125**(4):342–350.
31. Fujisawa J, Mutoh T, Kawamura K, Yonezawa R, Hirai M, Morioka I. **Age-Specific Differences in Foreign Bodies Ingested by Children: A Cohort Study of 252 Japanese Cases**. *Medicina (Kaunas)* 2020, 56(1).
32. Trout AT, Towbin AJ. Seasonal foreign bodies: the dangers of winter holiday ornamentation. Pediatric radiology. 2014;44(12):1610–6.
33. Arevalo-Silva C, Eliashar R, Wohlgelernter J, Elidan J, Gross M. Ingestion of caustic substances: a 15-year experience. Laryngoscope. 2006;116(8):1422–6.
34. Yuan J, Ma M, Guo Y, He B, Cai Z, Ye B, Xu L, Liu J, Ding J, Zheng Z, et al. Delayed endoscopic removal of sharp foreign body in the esophagus increased clinical complications: An experience from multiple centers in China. Medicine. 2019;98(26):e16146.
35. Schmid MB, Posovszky C, Neuwirth F, Galm C, Keck T. [Foreign body ingestion in children: recommendation for the diagnostic and therapeutic procedure]. Laryngo- rhino- otologie. 2010;89(2):73–6.
36. Rybojad B, Niedzielska G, Niedzielski A, Rudnicka-Drozak E, Rybojad P. Esophageal foreign bodies in pediatric patients: a thirteen-year retrospective study. ScientificWorldJournal. 2012;2012:102642.
37. Laya BF, Restrepo R, Lee EY. Practical Imaging Evaluation of Foreign Bodies in Children: An Update. Radiol Clin North Am. 2017;55(4):845–67.
38. Nation J, Jiang W. The utility of a handheld metal detector in detection and localization of pediatric metallic foreign body ingestion. Int J Pediatr Otorhinolaryngol. 2017;92:1–6.

39. Ramlakhan SL, Burke DP, Gilchrist J. Things that go beep: experience with an ED guideline for use of a handheld metal detector in the management of ingested non-hazardous metallic foreign bodies. Emerg Med J. 2006;23(6):456–60.
40. Lee JB, Ahmad S, Gale CP. Detection of coins ingested by children using a handheld metal detector: a systematic review. Emerg Med J. 2005;22(12):839–44.
41. Waltzman ML, Baskin M, Wypij D, Mooney D, Jones D, Fleisher G. A randomized clinical trial of the management of esophageal coins in children. Pediatrics. 2005;116(3):614–9.
42. Tseng CC, Hsiao TY, Hsu WC. Comparison of rigid and flexible endoscopy for removing esophageal foreign bodies in an emergency. Journal of the Formosan Medical Association = Taiwan yi zhi. 2016;115(8):639–44.
43. Shinhar SY, Strabbing RJ, Madgy DN. Esophagoscopy for removal of foreign bodies in the pediatric population. Int J Pediatr Otorhinolaryngol. 2003;67(9):977–9.
44. Committee ASoP, Lightdale JR, Acosta R, Shergill AK, Chandrasekhara V, Chathadi K, Early D, Evans JA, Fanelli RD, Fisher DA, et al. Modifications in endoscopic practice for pediatric patients. Gastrointest Endosc. 2014;79(5):699–710.
45. Ergun E, Ates U, Gollu G, Bahadir K, Yagmurlu A, Cakmak M, Aktug T, Dindar H, Bingol-Kologlu M: **An algorithm for retrieval tools in foreign body ingestion and food impaction in children**. *Diseases of the esophagus: official journal of the International Society for Diseases of the Esophagus / ISDE* 2020.
46. Sebastian van As AB, Yusof AM, Millar AJ, Susy Safe Working G. Food foreign body injuries. Int J Pediatr Otorhinolaryngol. 2012;76(Suppl 1):20–5.
47. Hiremath GS, Hameed F, Pacheco A, Olive A, Davis CM, Shulman RJ: **Esophageal Food Impaction and Eosinophilic Esophagitis**: **A Retrospective Study**, **Systematic Review**, **and Meta-Analysis**. *Digestive diseases and sciences* 2015, **60**(11):3181–3193.
48. Krishnan U. Eosinophilic Esophagitis in Children with Esophageal Atresia. Eur J Pediatr Surg. 2015;25(4):336–44.
49. Williams P, Jameson S, Bishop P, Sawaya D, Nowicki M. Esophageal foreign bodies and eosinophilic esophagitis–the need for esophageal mucosal biopsy: a 12-year survey across pediatric subspecialties. Surg Endosc. 2013;27(6):2216–20.
50. De Roo AC, Thompson MC, Chounthirath T, Xiang H, Cowles NA, Shmuylovskaya L, Smith GA. **Rare-earth magnet ingestion-related injuries among children**, **2000**–2012. *Clinical pediatrics* 2013, **52**(11):1006–1013.
51. Liu S, Li J, Lv Y. Gastrointestinal damage caused by swallowing multiple magnets. Front Med. 2012;6(3):280–7.
52. Yalcin S, Karnak I, Ciftci AO, Senocak ME, Tanyel FC, Buyukpamukcu N. Foreign body ingestion in children: an analysis of pediatric surgical practice. Pediatr Surg Int. 2007;23(8):755–61.
53. Betalli P, Falchetti D, Giuliani S, Pane A, Dall'Oglio L, de Angelis GL, Caldore M, Romano C, Gamba P, Baldo V, et al. Caustic ingestion in children: is endoscopy always indicated? The results of an Italian multicenter observational study. Gastrointest Endosc. 2008;68(3):434–9.

54. Prevention CfDCa. **Injuries from Batteries Among Children Aged < 13 Years — United States, 1995–2010**. *MMWR Morbidity and mortality weekly report* 2012, 61(34).
55. Litovitz T, Whitaker N, Clark L. Preventing battery ingestions: an analysis of 8648 cases. Pediatrics. 2010;125(6):1178–83.

Tables

Table 1: Distribution pattern of all ingested objects, chemical substances and food

object	frequency(n)	percentage (%)
coin	226	18,8
metallic object	197	16,4
surfactants/cleanser	148	12,3
plastic	107	8,9
drug	99	8,3
glass	74	6,2
not classified	65	5,4
button battery	63	5,3
food	57	4,8
plant	33	2,8
cigarette	25	2,1
acid	20	1,7
oil	18	1,5
stone	16	1,3
magnet	15	1,3
battery	14	1,2
wood	11	0,9
base	7	0,6
paper	2	0,2
body part	2	0,2
total	1199	100

Table 2: Distribution pattern of all registered symptoms

symptom	frequency (n)	percentage (%)
choking/gagging	244	29,5
other (e.g. globus sensation)	225	27,2
cough	152	18,4
pain	133	16,1
drooling	44	5,3
dysphagia	30	3,6
total	828	100

Table 3: Object associated symptoms and complications (percentage of symptoms and complications in relation to all registered cases for each object/substance, and percentage distribution of each symptom)

manifestation	coin	metallic	cleanser	plastic	drug	glass	button battery	food	plant
amount	n=226	n=197	n=148	n=107	n=99	n=74	n=63	n=57	n=33
age (mean/median/SD)	3,72/3,01/2,39	3,75/2,33/3,88	2,5/1,61/2,96	3,67/2,61/3,18	3,49/2,35/3,47	3,1/2,47/2,48	2,79/1,87/2,4	4,3/2,32/4,1	2,56/2,11/2,33
symptomatic	n=157 (56,2%)	n=93 (47,2%)	n=79 (53,4%)	n=57 (53,3%)	n=29 (29,3%)	n=34 (45,9%)	n=16 (25,4%)	n=53 (93,0%)	n=10 (30,3%)
complications	n=7 (3,1%)	n=7 (3,6%)	n=5 (3,4%)	n=4 (3,7%)	n=0 (0,0%)	n=8 (10,8%)	n=17 (27,0%)	n=6 (10,5%)	n=1 (3,0%)
choking/gagging	n=56 (35,7%)	n=25(26,9%)	n=39 (49,4%)	n=30 (52,6%)	n=10 (34,5%)	n=9 (26,5%)	n=6 (37,5%)	n=21 (39,6%)	n=4 (40,0%)
pain	n=40 (25,5%)	n=29 (31,2%)	n=9 (11,4%)	n=14 (24,6%)	n=3 (10,3%)	n=6 (17,6%)	n=1 (6,3%)	n=14 (26,4%)	n=2 (20,0%)
cough	n=34 (21,7%)	n=31 (33,3%)	n=20 (25,3%)	n=16 (28,1%)	n=1 (3,4%)	n=8 (23,5%)	n=4 (25,0%)	n=17 (32,1%)	n=0 (0,0%)
drooling	n=14 (8,9%)	n=2 (2,2%)	n=4 (5,1%)	n=6 (10,5%)	n=0 (0,0%)	n=1 (2,9%)	n=2 (12,5%)	n=13 (24,5%)	n=0 (0,0%)
dysphagia	n=9 (5,7%)	n=1 (1,1%)	n=0 (0,0%)	n=2 (3,5%)	n=0 (0,0%)	n=2 (5,9%)	n=1 (6,3%)	n=10 (18,9%)	n=0 (0,0%)
other	n=39 (24,8%)	n=25 (26,9%)	n=35 (44,3%)	n=23 (40,3%)	n=16 (55,2%)	n=15 (44,1%)	n=6 (37,5%)	n=25 (47,2%)	n=4 (40,0%)

Figures

Figure 1

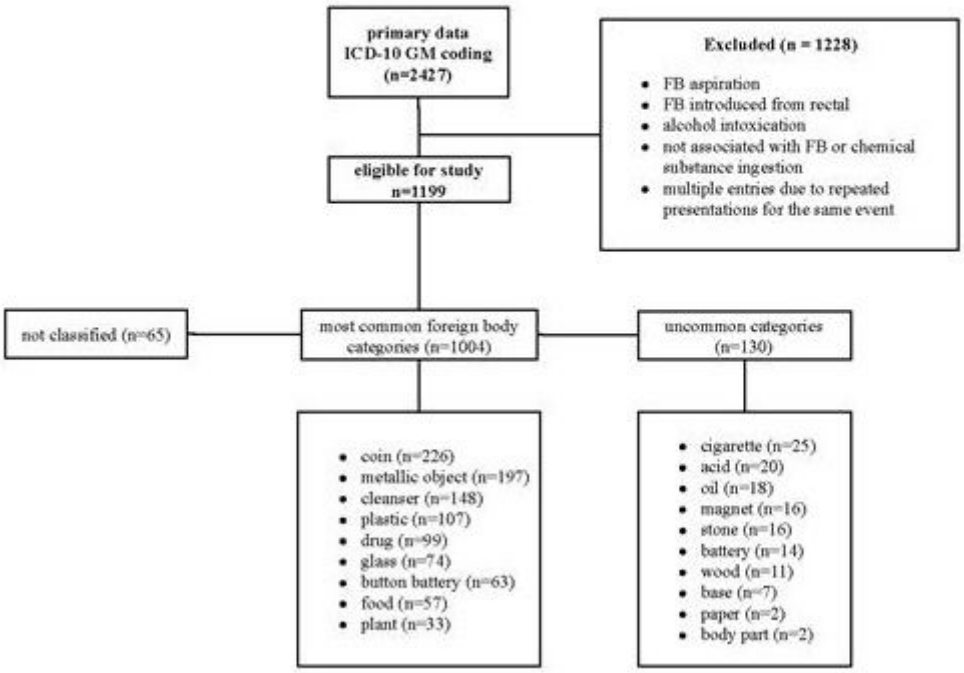

Figure 1

Flowchart depicting study selection criteria

figure 2

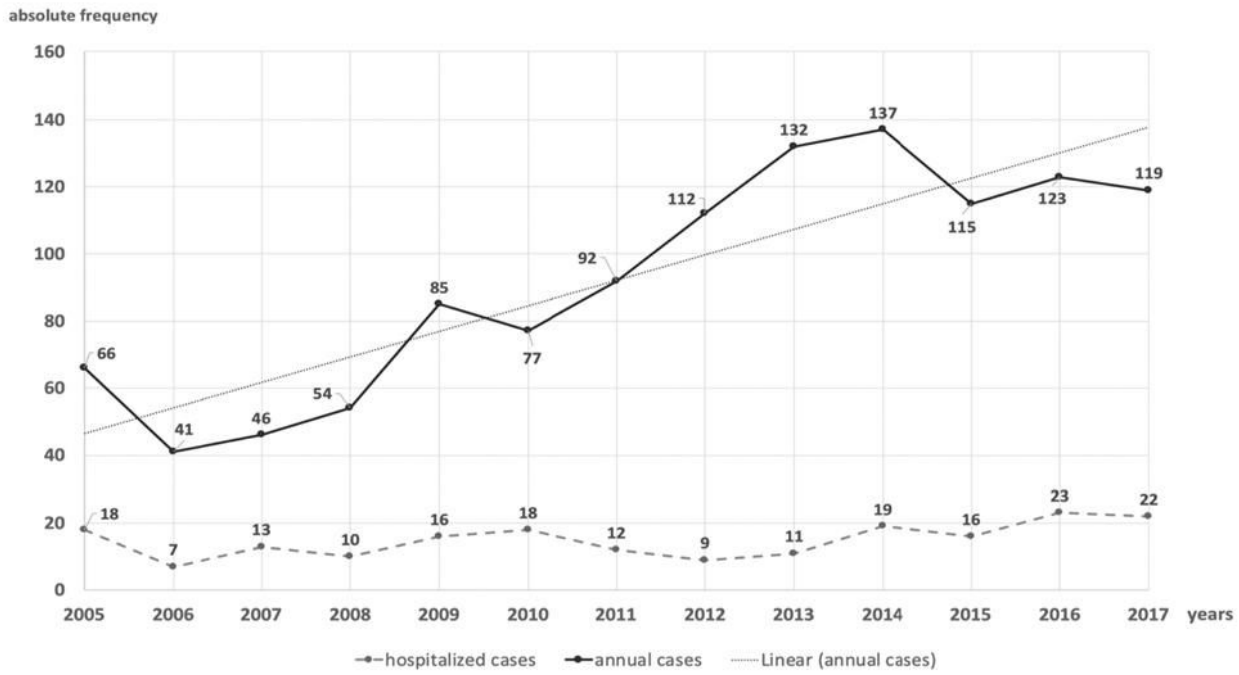

Figure 2

Annual cases (black line) of children presenting with food bolus impaction, ingestion of foreign bodies or chemical substances at the Emergency Department from 2005 to 2017 and number of hospitalized patients (dashed grey line). Linear regression analysis (fine dotted grey line) revealed R squared of 0.79 (beta=0,886; p=0.000054).

Supplementary Files

This is a list of supplementary files associated with this preprint. Click to download.

- supplemantalfigure2.pdf
- supplementalfigure1.pdf
- supplementaltable2.pdf
- supplementaltable1.pdf