Clinical Efficacy Evaluation of Full-endoscopic Foraminoplasty and Discectomy Under General Anesthesia in the Treatment of L5-S1 Disc Herniation

Dongfang Meng
Henan University of Traditional Chinese Medicine https://orcid.org/0000-0001-7933-3016

Lihe Wang
Henan University of Traditional Chinese Medicine

Tao Wang
Henan University of Traditional Chinese Medicine

Ji Tu
University of New South Wales

Chenyang Du
Henan University o Traditional Chinese Medicine

Huiying Li (li-huiying@163.com)
The first affiliated hospital of Henan university of traditional Chinese medicine

Research article

Keywords: full endoscopy, general anesthesia, lumbar disc herniation

Posted Date: October 12th, 2020

DOI: https://doi.org/10.21203/rs.3.rs-45982/v1

Abstract

Background: Percutaneous transforaminal endoscopic discectomy (PTED) is a minimally invasive surgical method for the treatment of spinal diseases. However, the operation procedure relied on the radiative interventional technology, and was conducted under local anesthesia.

Method: From June 2016 to December 2019, we performed a newly developed full-endoscopic visualized foraminoplasty and discectomy under general anesthesia in 30 patients with L5/S1 LDH. In this retrospective study, the outcomes and neurological complications of this approach were evaluated.

Results: The mean visual analog scale (VAS) and Oswestry Disability Index (ODI) were significantly improved after surgery. The postoperative MRI reexamination revealed that the degree of intervertebral disc degeneration of each subject was improved significantly to different degrees as compared with that before surgery. The learning curve showed operative time rapidly decreased over the earlier cases, and then tapered to a steady state in the latter cases.

Conclusions: Full-endoscopic foraminoplasty and discectomy under general anesthesia is efficient and safe for the treatment of the L5-S1 disc herniation.

Trial registration: N/A

Background

Chronic osphyalgia or osphyalgia accompanied by lower limb pain is the common symptom of spinal degenerative diseases. These manifestations are mainly caused by compression of the nerve root due to lumbar disc herniation. A variety of methods to treat the above symptoms are currently explored by clinical orthopedists. Percutaneous transforaminal endoscopic discectomy (PTED) for the treatment of chronic pain in waist and legs has been put forward and rapidly and widely adopted in clinical treatment in recent years. It has the advantages of less trauma, less bleeding, fast recovery, and less impact on spinal stability. With the advancement in the technique, PELD has realized direct decompression from outside of the disc as compared to previous indirect decompression from the inside of the disc. The most commonly used PTED in clinical practice is percutaneous lumbar discectomy (PELD), which was initially used in the treatment of lumbar disc herniation (LDH) [1–2]. The surgical efficacy of this approach is satisfactory as rated by both doctors and patients. With the improvement of surgical instruments, the methods of surgical approach have also been optimized continuously. In the case of patients with lumbar disc herniation, surgical indications and postoperative efficacies have been expanded and improved by optimizing previous indirect decompression from the inside of the disc to direct decompression from the outside of the disc. Herein, we have also optimized the treatment of many such patients based on this technology.

Methods

Patient Population

A total of 30 patients with L5-S1 LDH in our department were enrolled. Full-endoscopic visualized foraminoplasty and discectomy were performed under general anesthesia in the First Affiliated Hospital of Henan University of Traditional Chinese Medicine from March 2018–2019.

Inclusion criteria: Single-level lumbar disc herniation at L5-S1, verified by magnetic resonance imaging (MRI) and computed tomography (CT); unilateral radiating leg pain with or without positive Lasegue sign; clinical symptoms and signs in accordance with imaging changes; failure of standard conservative treatment conducted for at least 12 weeks. Exclusion criteria: Vertebral infection, vertebral tumor, spinal canal stenosis, lumbar spondylolisthesis, and a history of surgery at the same level.

Observation indicators

The operation time, the visual analog scale of lower limbs (VAS-L), visual analog scale of back (VAS-B), and Oswestry disability index (ODI) [3] before surgery, 1 day, and 1 week after surgery were used for clinical evaluation.

Statistical analysis

All data were analyzed by SPSS21.0 statistical software, and relevant graphs were constructed using Microsoft Excel. The measurement data were expressed as mean ± standard deviation and the preoperative and postoperative data were analyzed by paired sample t-test, while the enumeration data were compared using the rank-sum test or X^2 test. P-value <0.05 indicates statistical significance.

Surgical Procedure

We have studied and applied the operation technique of Professor Yang from the Union Hospital Affiliated to the Huazhong University of Science and Technology [15]. The preoperative images (Figure 1) were firstly evaluated, the operation was performed under general anesthesia, and the posterior interlaminar space approach was adopted. The patient was in the lateral position, with limb of the affected site on the top and flexion of bilateral knees and hips to fully open the interlaminar space. The anteroposterior and lateral X-ray films of the corresponding segments were obtained by C-arm fluoroscopy to accurately locate the intervertebral pore. The syringe needle was inserted into the skin to locate the point where the needle entered the L5-S1 intervertebral space vertically from the back of the lumbar [16]. The anteroposterior X-ray film indicated that the positioning needle was in the middle of the affected side of the intervertebral space, while the lateral X-ray film indicated that the positioning needle was at the level of the posterosuperior margin of S1. The puncture target and direction were determined according to the X-ray films to ensure the accuracy of the surgery site.

After positioning, a longitudinal incision of about 1 cm was made along the direction of the spine with the registration point as the center. After the pencil-shaped puncture rod was inserted into the interlaminar space, the working cannula and the operating endoscope were inserted slowly along the puncture rod into the interlaminar space. All subsequent operation procedures were performed under the premise of continuous irrigation and endoscopic visualization. The inferior zygapophysis of the L5 vertebral body and the lower margin of the lamina were found under the direct vision of the endoscope. If the interlaminar space was small, a part of zygapophysis at foramen intervertebral could be enlarged by grinding with an abrasion drill under the endoscope (Figure 2). Then, the blue forceps removed a part of the ligamentum flavum into the spinal canal, lamina rongeur enlarged the crevasse of the ligamentum flavum to fully expose the tissues in the spinal canal, the bipolar radiofrequency scalpel separated the tissues in the spinal canal to fully expose the nerve root, dural sac, and annulus fibrosus, the sleeve was rotated into the spinal canal to protect the nerve root, annulus fibrosus fenestration was performed on the outer margin of the nerve root, the working sleeve was guided to the annulus fibrosus opening, and full endoscopic resection of the nucleus pulposus was performed to ensure complete decompression of the nerve root. During this process, the nerve root was clearly identified, and no free intervertebral disc tissue or active bleeding was observed before the end of the operation. (Figure 3) Finally, bipolar radiofrequency scalpel was adopted to control the bleeding, the external annulus plasty of the intervertebral disc was performed, and the incision was closed without additional drainage at the end.

Results

The learning curve showed operative time rapidly decreased over the earlier cases, and then tapered to a steady state in the latter cases (Fig. 4).

The mean visual analogy scale (VAS) score and Oswestry disability index (ODI) score postoperatively improved significantly compared with preoperative scores ($P < 0.05$; Table 1).

Table 1
Comparison of VAS and ODI scores before and after surgery

	Before surgery	1 day after surgery	1 week after surgery	Statistical value	Improvement value
VAS score of low back pain (N = 30)	6.80 ± 0.714	2.10 ± 0.885*	1.73 ± 0.640#	t = 30.590 P ≤ 0.05	4.90 ± 1.274
VAS score of bilateral lower limbs (N = 30)	6.93 ± 0.785	1.90 ± 0.662*	1.70 ± 0.651#	t = 29.507 P ≤ 0.05	5.23 ± 0.971
ODI score (N = 30)	64.57 ± 9.183	36.57 ± 10.321*	33.42 ± 9.198#	t = 26.405 P ≤ 0.05	31.13 ± 6.458

*: compared to that before surgery; #: compared to that 1 day after surgery. N represents the number of patients included in the statistical analysis. Both the statistical value and the improvement value were comparative analysis results of indicators 1 week before surgery and after surgery.

The postoperative MRI reexamination revealed that the degree of intervertebral disc degeneration of each subject was improved significantly to different degrees as compared with that before surgery ($P < 0.05$; Table 2).

Table 2
Comparison of degree grade of intervertebral disc degeneration before and after surgery

	Grade I-II	Grade III	Grade IV	Grade V
Before surgery	1	5	15	9
1 week after surgery	3	8	17	2
Z	-2.269			
P value	0.023			

Discussion

Currently, there are several surgical methods for lumbar disorders [4–6], and minimally invasive surgery has developed rapidly in recent years. Owing to its advantages, the methods and approaches of minimally invasive treatment under anesthesia have put forward. However, the basic application of minimally invasive technology is to remove the nucleus pulposus tissue. If the indications are to be expanded to the minimally invasive treatment, full-endoscopic technology for the treatment of lumbar spinal stenosis and partial lumbar spondylolisthesis is valuable. Then, minimally invasive fusion technology is the ultimate choice [7–8], which requires us to expand the operation indications and reduce intraoperative fluoroscopy to avoid unnecessary operation hazards due to general anesthesia. In more

than three years, we have operated on about 100 cases with satisfactory results. None of the patients presented complications of intraoperative and postoperative nerve injury. However, general anesthesia also has some disadvantages, such as the requirement for solid anatomical basis and microscopic identification ability of the surgeon. Nonetheless, these characteristics are essential for a surgeon utilizing minimally invasive approach.

The development of PTED has gone through two stages. The first stage was Yeung Endoscopic Spine System (YESS) technology, proposed by Yeung et al.[9] and entered through Kambin safety triangle[10]. It was characterized by disc decompression from the inside to the outside, which determined the limitations of this technology deeming it only applicable to inclusive disc herniation and disc herniation under ligaments. Thereafter, the second stage was TESSYS technique [11], which directly decompressed and released the nerve root through the foramen intervertebral and further expanded the indications of PTED. Thus, it could be used for intervertebral foramen stenosis, lateral recess stenosis, the stenosis of the spinal canal stenosis, intervertebral disc herniation, and nucleus pulposus into the spinal canal due to intervertebral disc herniation. Because of its direct target to remove the protruding nucleus pulposus and the confirmed postoperative decompression effect, this technique has been widely used in several types of lumbar disorders [12]. However, the traditional TESSYS technique could be performed under local anesthesia, due to which, the patients felt unbearable intraoperative pain and the operation had to be interrupted. Moreover, local anesthesia inevitably reduces indications of the operation, which could not fully meet the surgical method of final lumbar fusion. Also, local anesthesia needs repeated puncture positioning and fluoroscopy and long repeated fluoroscopy is bound to bring radiation hazard to medical personnel. Therefore, we selected different body positions to remove the nucleus pulposus and other tissues under general anesthesia for patients with different segments of LDH and satisfactory results were achieved.

Different from the traditional TESSYS technology of PTED, we adopted the fully visible endoscopy technology in the operation, i.e., after positioning by fluoroscopy, all operations were completed under the direct vision of endoscope after the insertion of the interforaminal lens into the operation channel. There are two main positions of PTED: prone and lateral. Both positions have their own advantages and disadvantages; either was adopted according to our needs. For patients with L5-S1 intervertebral disc herniation, due to the block of bilateral iliac spine, the access to the foramen intervertebral is relatively difficult [13], but for this segment, the posterior intervertebral space is large. If prone position was adopted for this segment, the waist protrudes backward with nothing under the chest and abdomen to fully open the posterior intervertebral space. Due to the minimal invasiveness of PTED, the operation space is narrow, and hemostasis is difficult [14]. The needle is inserted from bilateral sites to reduce the pressure; however, the abdominal pressure is increased, the risk of abdominal viscera injury is increased, and the risk of bleeding is increased.

Conclusions

Our procedure provides a direct approach for surgeons. Overall, full-endoscopic visualized foraminoplasty and discectomy under general anesthesia is efficient and safe for the treatment of L5-S1 disc herniation. However, further prospective, randomized, controlled studies should be conducted to assess the clinical outcomes.

Abbreviations

PTED Percutaneous transforaminal endoscopic discectomy

LDH lumbar disc herniation

VAS visual analogy scale

ODI Oswestry Disability Index

CT computed tomography

YESS Yeung Endoscopic Spine System

Declarations

Ethics approval and consent to participate:

The study have been approved by the Ethics Committee of the First Affiliated Hospital of Henan University of traditional Chinese Medicine. Consent form have been provided and signed by all participants.

Consent for Publication:

Included in patient's hospital records. Patient agreed to necessary clinical information being used in this article. Patient signed a consent to publish all relevant clinical data and images provided. A copy of a written signed consent is available for review by the editors the journal.

Availability of data and material:

The data that support the findings of this study are available on request from the corresponding author. The data are not publicly available due to their containing information that could compromise the privacy of research participants.

Competing interests:

The authors declare that they have no competing interests.

Funding:

This study was funded by the first batch of Youth Talent Training Project in Henan Province and the Special Project for Scientific Research of Traditional Chinese Medicine in Henan Province (2018JDZX052).

Authors' contributions:

DFM draft the manuscript and design the study; LHW and TW collect the clinical data; JT design the study and revised the manuscript. CYD revised the manuscript. HYL providing the funding and design the study.

Acknowledgements:

Not applicable

References

1. Schubert M. Hoogland Thomas. Endoscopic transforaminal nucleotomy with foraminoplasty for lumbar disk herniation. [J]. Operative Orthopadie und Traumatologie,2005,17(6).
2. Tao X-Z, Jing L, Li J-H. Therapeutic effect of transforaminal endoscopic spine system in the treatment of prolapse of lumbar intervertebral disc.[J]. European review for medical and pharmacological sciences,2018,22(1 Suppl).
3. Fairbank JC, Couper J, Davies JB, et al. The Oswestry low back pain disability questionnaire. Physiotherapy. 1980;66:271–3.
4. Lauferman L, Dip M, Halac E, et al. Waiting list outcome of PELD /MELD exceptions: a single-center experience in Argentina. PediatrTransplant, 2018 Jan 3. [Epub ahead of print].
5. Wang HW, Zhou Y, Li CQ, et al. Risk factors for failure of single-level percutaneous endoscopic lumbar discectomy. J NeurosurgSpine. 2015;23(3):320–5.
6. Hurday Y, Xu B, Guo L, et al. Radiographic measurement for transforaminal percutaneous endoscopic approach (PELD). EurSpine J. 2016;26(3):635–45.
7. Tang S, Jin S, Liao X, et al. Transforaminal Percutaneous Endoscopic Lumbar Decompression by Using Rigid Bendable Burr for Lumbar Lateral Recess Stenosis: Technique and Clinical Outcome[J]. Biomed Research International, 2018, 2018:1–7.
8. Goyal A, Kerezoudis P, Alvi MA, et al. Outcomes following Minimally Invasive Lateral Transpsoas Interbody Fusion for Degenerative Low-Grade Lumbar Spondylolisthesis: A Systematic Review[J].

Clinical Neurology and Neurosurgery, 2018: S0303846718300659.

9. Yeung AT. Minimally Invasive Disc Surgery with the Yeung Endoscopic Spine System (YESS).[J]. Surgical technology international,1999,8.
10. Fanous Andrew A, Tumialán Luis M, Wang Michael Y. Kambin's triangle: definition and new classification schema. [J]. Journal of neurosurgery. Spine,2019.
11. Pan Zhimin H, Yoon Y, Seong CK. Efficacy of Transforaminal Endoscopic Spine System (TESSYS) Technique in Treating Lumbar Disc Herniation. [J]. Medical science monitor: international medical journal of experimental and clinical research,2016,22.
12. Pan Fumin S, Bin, Chy Surendra K, Yong Zhiyao L, Xiaoming B, Zhaoyu L, Zhonghan Z, Jianguang. Wu Desheng. Transforaminal endoscopic system technique for discogenic low back pain: A prospective Cohort study. [J]. International journal of surgery (London, England),2016,35.
13. Soo ES, Chiang LSang-Ho,LWei, Erken H, Yener. A novel preoperative trajectory evaluation method for L5-S1 transforaminal percutaneous endoscopic lumbar discectomy. [J]. The spine journal: official journal of the North American Spine Society,2018,18(7).
14. Pan Mingming L, Sucheng QL, Haiqing M, Bin M, Feng Z. Yang Huilin. Percutaneous Endoscopic Lumbar Discectomy: Indications and Complications. [J]. Pain physician,2020,23(1).
15. Wenbin H, Yukun Z, Xinghuo Wu, Yong G, Shuai L, Shuhua WKun,Y. Yang Cao. Full-Endoscopic Visualized Foraminoplasty and Discectomy Under General Anesthesia in the Treatment of L4-L5 and L5-S1 Disc Herniation. [J]. Spine,2019,44(16).
16. Cha YD, Choi JK, Yang CW, Lim HK, Heo GA, Kim BG. Relationship between first dorsal sacral foramen and lumbar facet joint connecting line in South Korea populations: Retrospective study. Medicine. 2017;96(29):e7544.

Figures

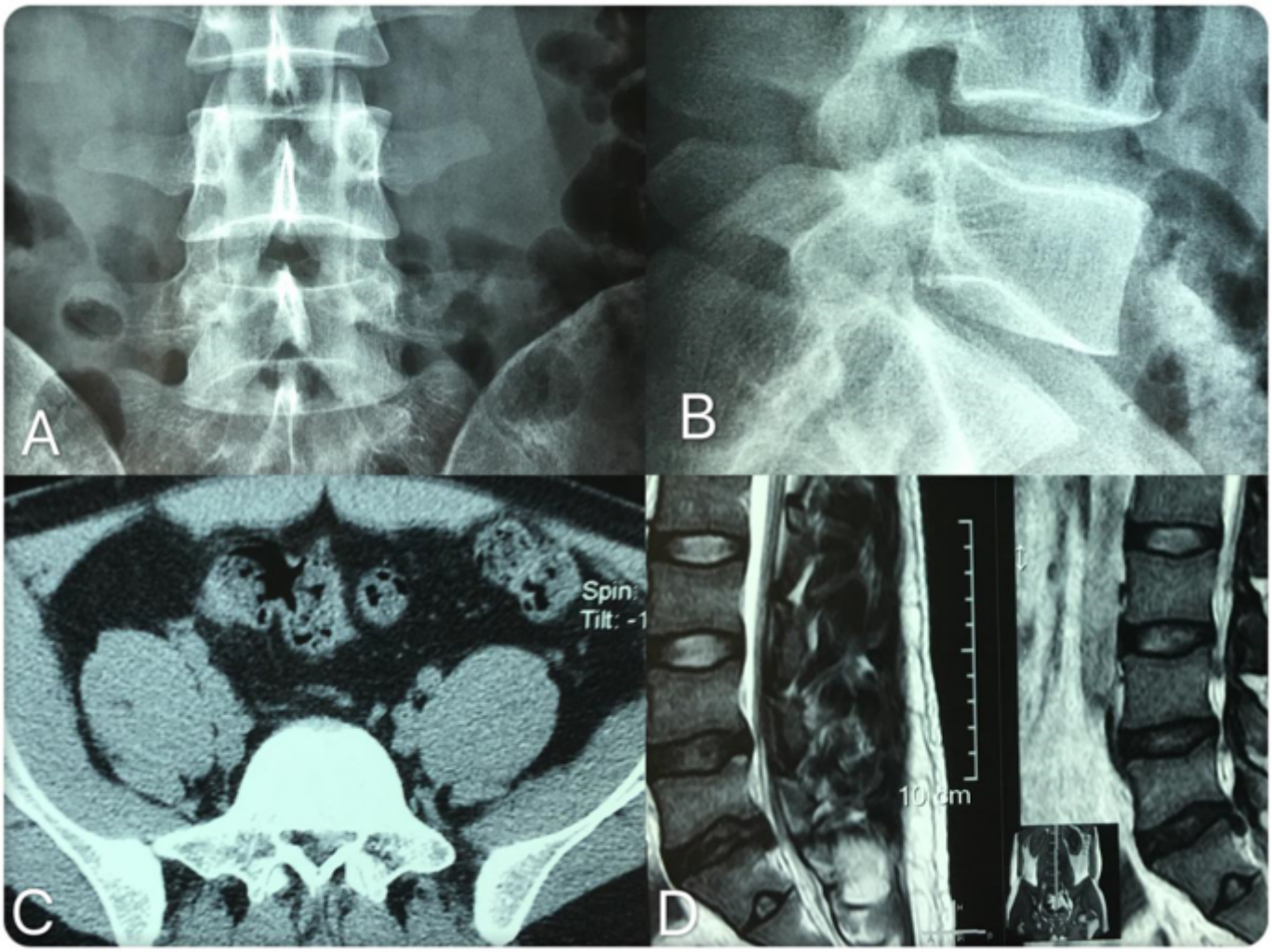

Figure 1

Preoperative imaging evaluation.

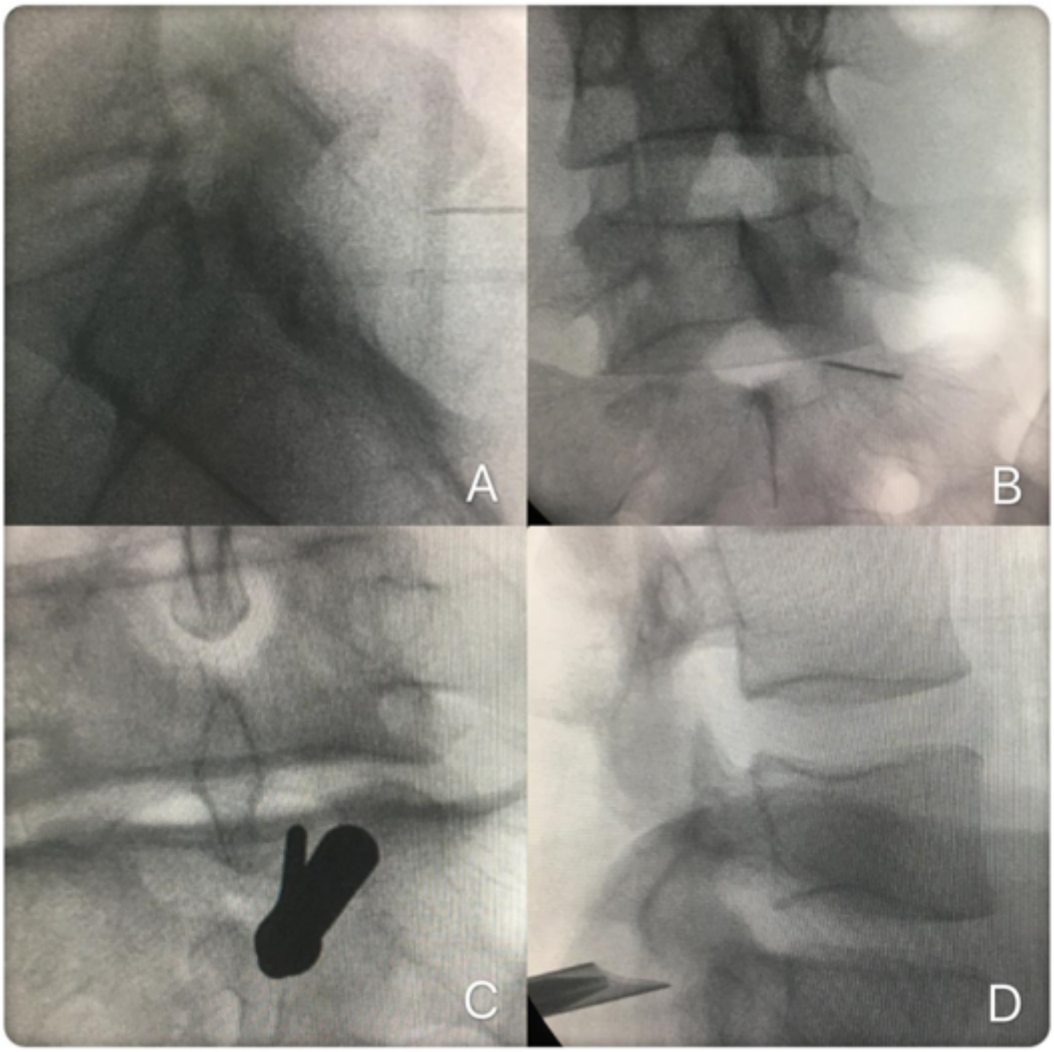

Figure 2

Intraoperative localization.

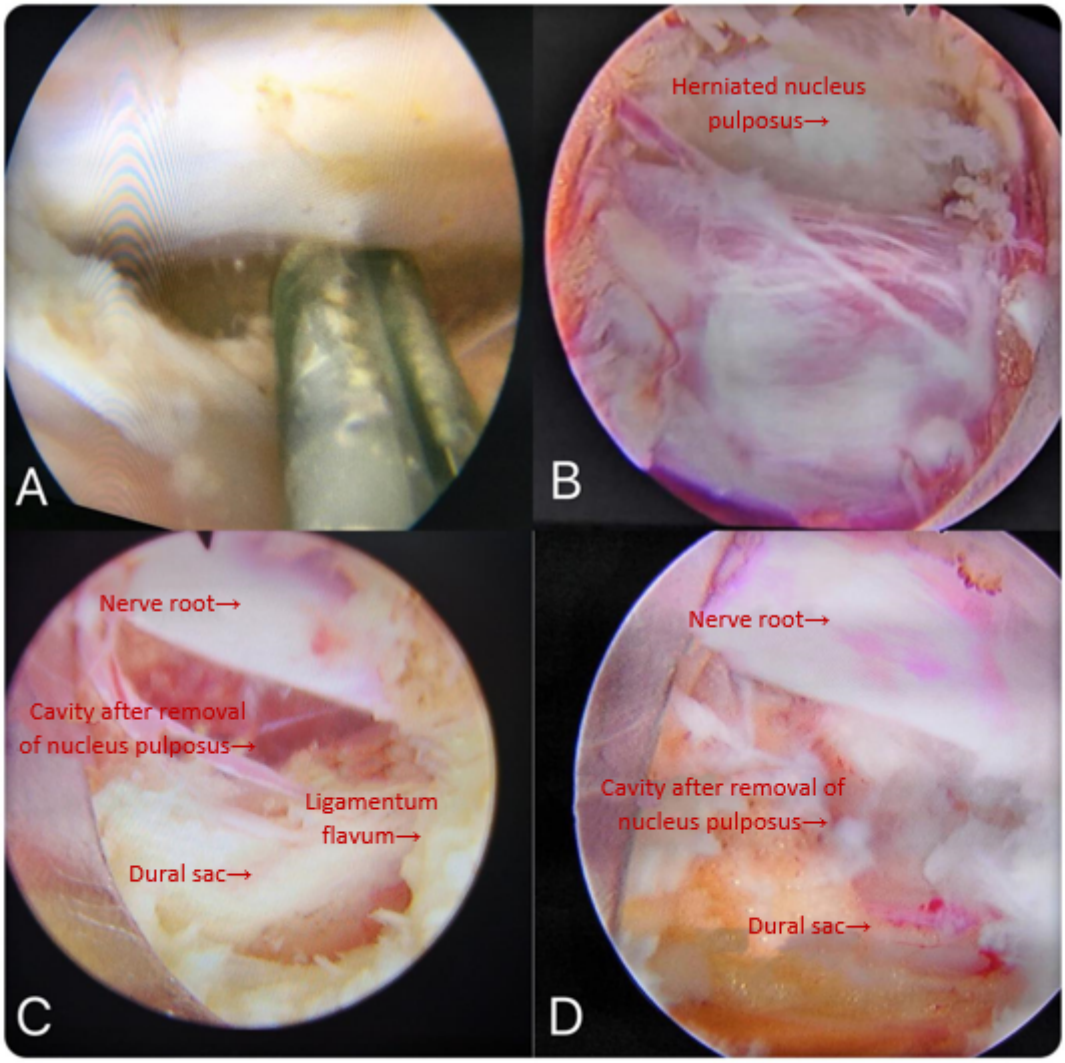

Figure 3

Removal of nucleus pulposus under intraoperative fully visible endoscopy.

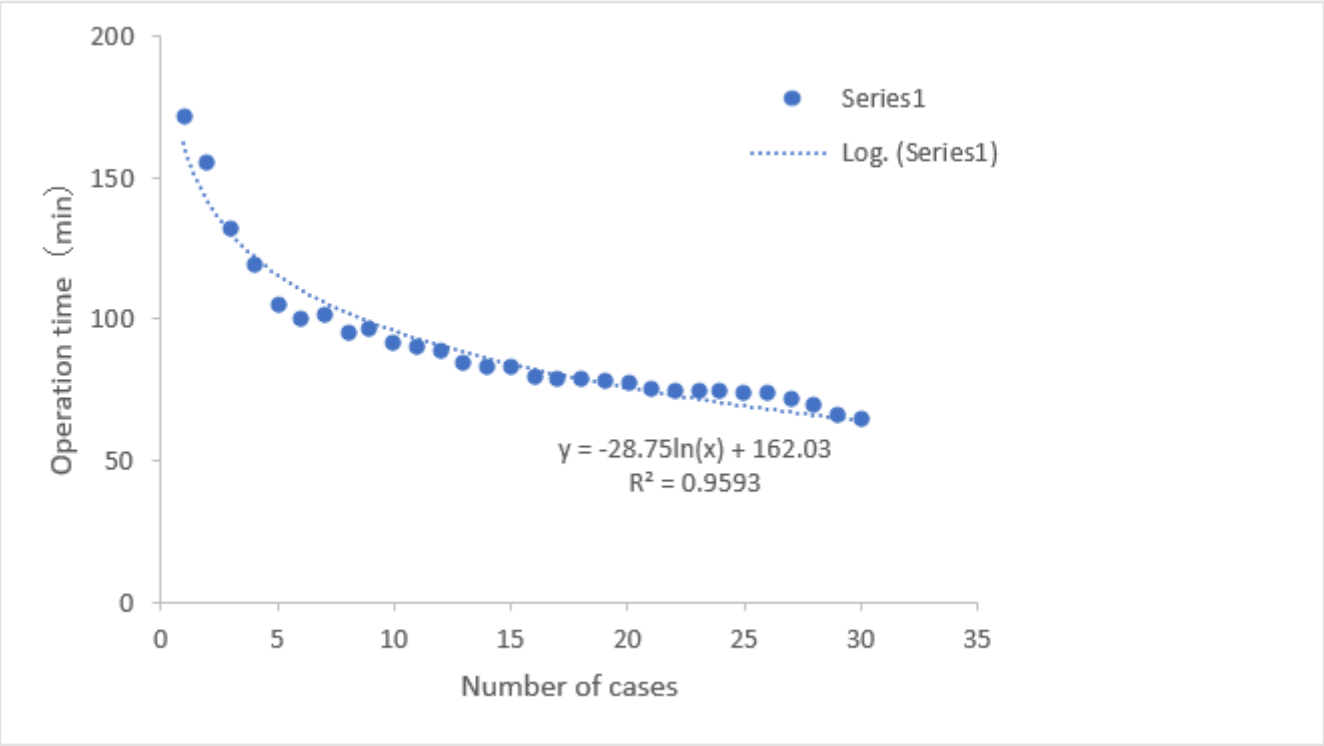

Figure 4

Learning curve of discectomy of foraminoplasty by endoscopy under general anesthesia.