Left Ventricular Free Wall Rupture in A Middle-Aged Woman

Fernando Fonseca Gonçalves (fernando.fonseca.goncalves@gmail.com)
Centro Hospitalar de Tras-os-Montes e Alto Douro https://orcid.org/0000-0002-2624-0921

João Pedro Monteiro
Centro Hospitalar de Vila Nova de Gaia Espinho EPE

Fátima São Neves
Centro Hospitalar de Vila Nova de Gaia Espinho EPE

José Ilídio Moreira
Centro Hospitalar de Tras-os-Montes e Alto Douro

Case report

Keywords: Myocardial infarction, ventricular rupture, cardiac tamponade, cardiac surgery.

Posted Date: July 29th, 2020

DOI: https://doi.org/10.21203/rs.3.rs-45995/v1

Abstract

Background: Ventricular free wall rupture is an uncommon but potentially fatal mechanical complication following a myocardial infarction.

Case presentation: We report a case of a 51 year-old female admitted in our emergency department in cardiogenic shock, in which echocardiography was fundamental in the diagnosis of a left ventricle free wall rupture with tamponade. In this case, removal of pericardial clots with subsequent hemodynamic improvement and the presence of a strong adhesion between the pericardial layers at the rupture site were sufficient for the short-term surgical treatment. The patient remained stable and was discharged fifteen days later.

Conclusions: Although being a rare presentation, this unconventional surgical approach might be useful in this kind of cases.

Background

Ventricular free wall rupture is a rare complication of a myocardial infarction, with a incidence of approximately 3% [1]. The elderly and patients with anterior myocardial infarctions or without coronary reperfusion have higher rates of free wall ruptures. Mortality in these cases is high due to the development of electromechanical dissociation, tamponade and cardiogenic shock. Urgent surgical treatment is usually necessary and life-saving.

Case Presentation

A 51 year-old female, smoker and with familial hypercholesterolemia, was found prostrated after one week referring epigastric pain. She was admitted in the emergency room with severe hypotension and an electrocardiogram showing sinus tachycardia, low voltage and Q waves and ST segment elevation from V1 to V6. An emergent transthoracic echocardiogram revealed akinesia of the apex, all distal segments of all walls and of the entire anterior wall of the left ventricle, rupture of the distal segment of the posterolateral left ventricular wall (Fig. 1A and video 1) and an apical thrombus (Fig. 1B). There was also a large circumferential pericardial effusion filled with echogenic content, continuously compressing the right heart chambers (Fig. 1C). Patient was stabilized with rapid volume administration and noradrenaline and transferred to the operating room. As soon as the pericardium was opened, large clots were found and removed and the hemodynamic profile immediately improved (Fig. 2 and video 2). A large portion of the parietal pericardium was found strongly adherent to the visceral layer in the distal posterolateral region of the left ventricle, where the rupture probably occurred, and was left this way. Only a fibrinogen and thrombin coated sealing matrix was placed at this level. One day after surgery heparin perfusion was started and progressive partial resolution of the intracavitary thrombus was achieved. The patient remained asymptomatic and hemodynamically stable and was discharged fifteen days later with a non-vitamin K oral anticoagulant.

Discussion

Although left ventricular free wall rupture is more typical of older patients, we report a case of a middle-aged woman. The presence of familial hypercholesterolemia, in which cardiovascular diseases manifest earlier in life, and the prolonged time of myocardial ischemia without coronary reperfusion may justify this presentation. Moreover, female patients tend to be more affected than men, as they generally have more severe first myocardial infarctions [2, 3].

Echocardiography is the first line investigation exam for the diagnosis of free wall rupture, since it is easily accessible and can make a fast diagnosis. The main echocardiographic findings are pericardial effusion with or without intrapericardial echoes and signs of tamponade.

About one third of free wall ruptures are subacute and are characterized by a slow bleeding into the pericardial space [4]. These cases are associated with lower mortality rate since patients can survive longer until surgical treatment. In this patient, this was probably the mechanism that led to the development of intrapericardial thrombus until the rupture was contained by pericardial adhesion and fibrosis. The definitive treatment of a myocardial rupture is emergent surgical repair, usually with a pericardial patch or epicardial sutures. Less often, aneurismectomy with ventricular wall reconstruction is performed [5]. In this case, however, a type III myocardial rupture was found with a large pericardial symphysis naturally containing the rupture and for this reason only a fibrinogen and thrombin coated sealing matrix was placed for stabilization.

Conclusion

We report a case of a patient with rupture of the left ventricle free wall admitted with a cardiac tamponade caused by large intrapericardial blood clots. Emergent surgical approach was mandatory but the finding of a spontaneously contained rupture led to the decision of not advancing to any kind of anatomical surgical repair. Although being a rare presentation, this unconventional surgical approach might be useful in this kind of cases.

Declarations

ETHICS APPROVAL AND CONSENT TO PARTICIPATE

Not applicable.

CONSENT FOR PUBLICATION

Patient consent was acquired for publication.

AVAILABILITY OF DATA AND MATERIALS

Data sharing is not applicable to this article as no datasets were generated or analysed during the current study.

COMPETING INTERESTS

All the authors have no conflicts of interest to declare.

FUNDING

This work was not supported by any kind of funding source.

AUTHORS' CONTRIBUTION

All authors contributed in this work and approve it. FG has written the article, JP and FN provided data and JM reviewed the work.

ACKNOWLEDGEMENTS

Not applicable.

References

1. Pineda-De Paz DO, Hernández-del Rio JE, González-Padilla C, Esturau-Santaló RM, Romero-Palafox J, Grover-Paez F, et al. Left ventricular free-wall rupture, a potentially lethal mechanical complication of acute myocardial infarction: an unusual and illustrative case report. BMC Cardiovasc Disord. 2019 Dec 3;19(1):80.
2. Dellborg M, Held P, Swedberg K, Vedin A. Rupture of the myocardium. Occurrence and risk factors. Heart. 1985 Jul 1;54(1):11–6.
3. Hutchins KD, Skurnick J, Lavenhar M, Natarajan GA. Cardiac Rupture in Acute Myocardial Infarction. Am J Forensic Med Pathol. 2002 Mar;23(1):78–82.
4. Raitt MH, Kraft CD, Gardner CJ, Pearlman AS, Otto CM. Subacute ventricular free wall rupture complicating myocardial infarction. Am Heart J. 1993 Oct;126(4):946–55.
5. Amir O, Smith R, Nishikawa A, Gregoric ID, Smart FW. Left ventricular free wall rupture in acute myocardial infarction: a case report and literature review. Texas Hear Inst J. 2005;32(3):424–6.

Figures

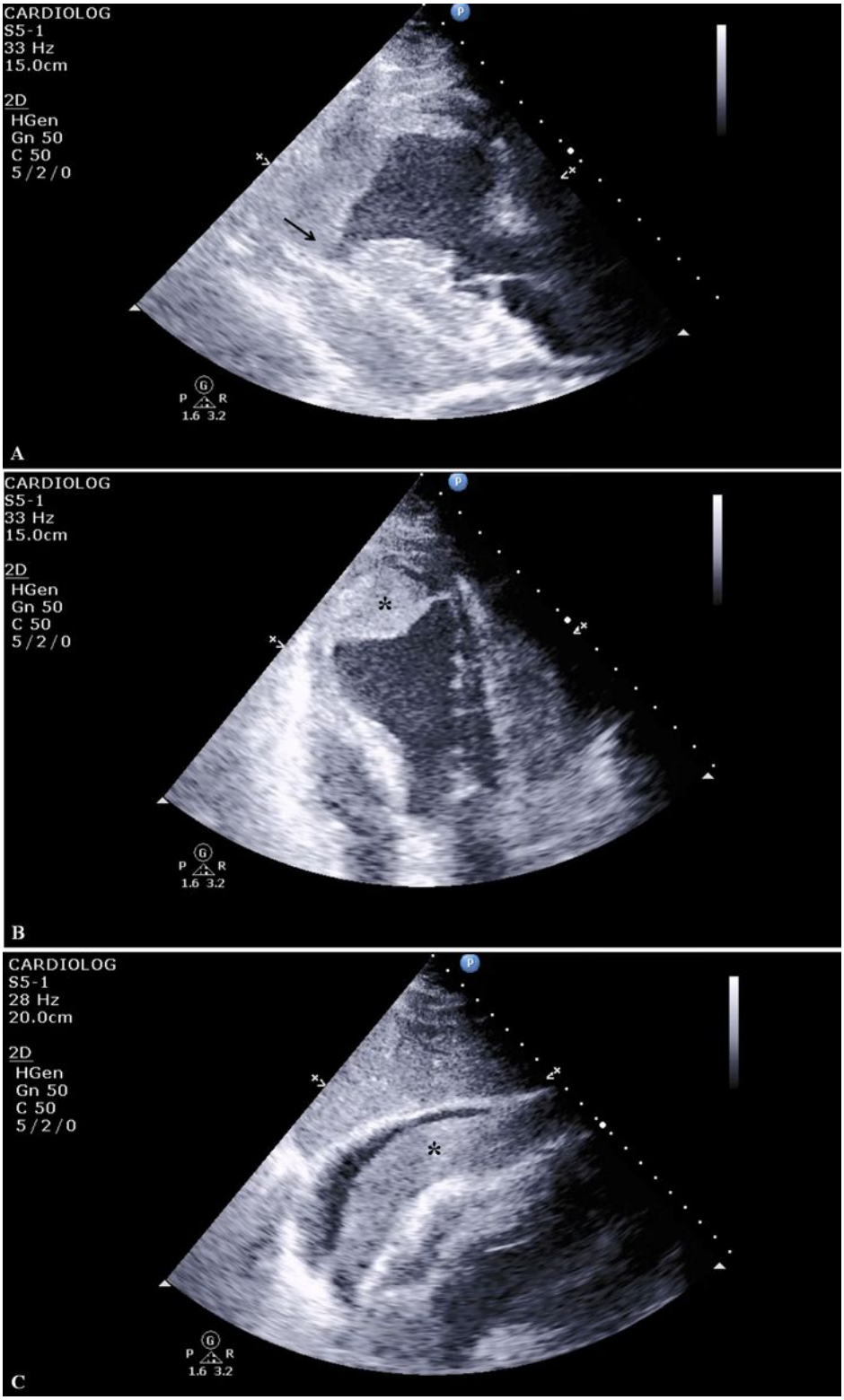

Figure 1

Echocardiography imaging acquired at the emergency room. A: Left parasternal window showing the probable rupture site at the distal portion of the posterior wall (arrow). B: Four chamber window revealing a large apical thrombus (asterisk). C: Subcostal window showing a large echogenic structure compressing the right heart chambers (asterisk).

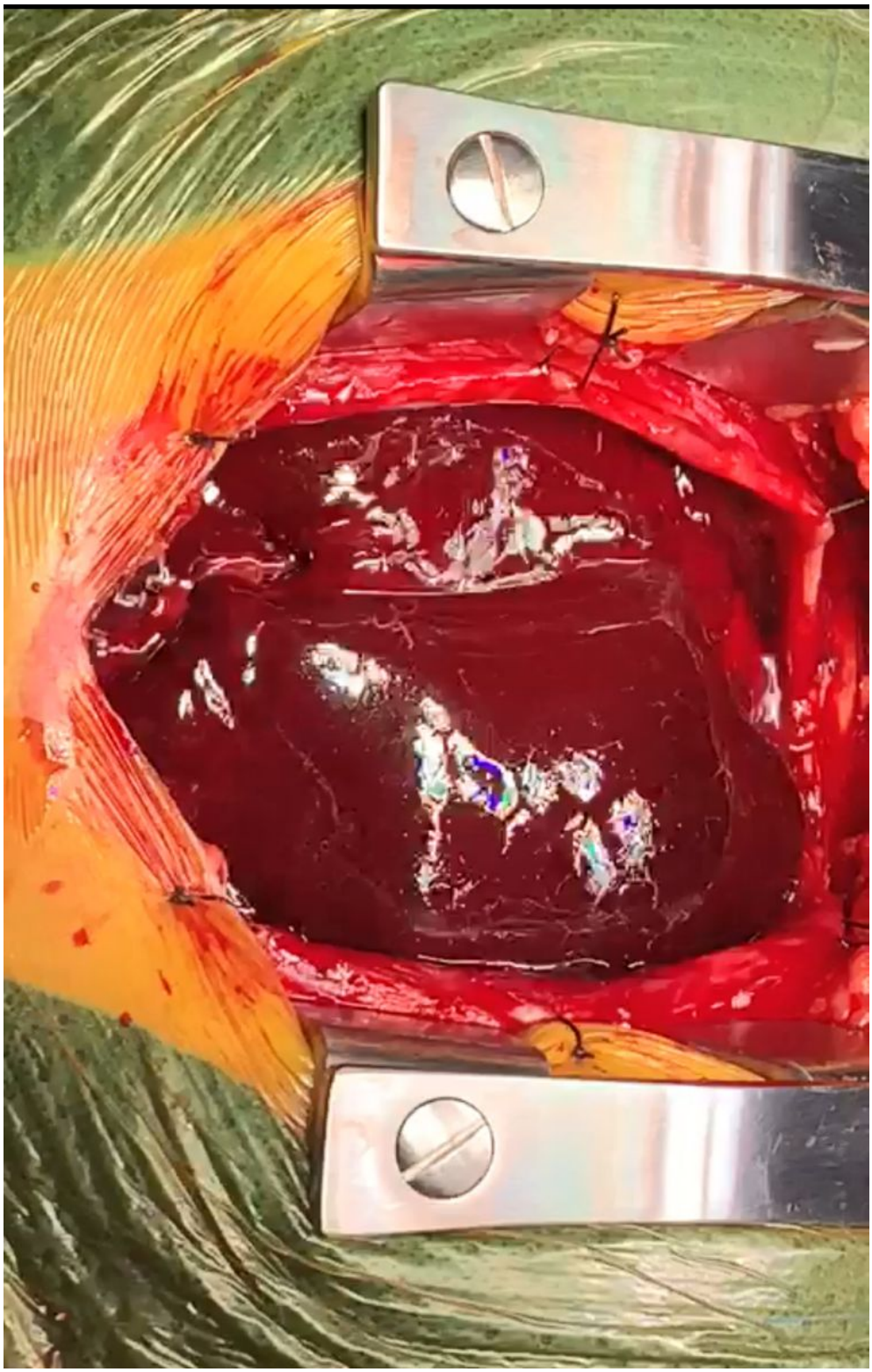

Figure 2

Surgical view of large blood clots surrounding the heart.

Supplementary Files

This is a list of supplementary files associated with this preprint. Click to download.

- Videolegends.docx
- CARChecklist.pdf
- Video1.avi
- Video2.avi