Absorbable suture can be effectively and safely used to close the mesenteric defect in a gastric bypass Sprague-Dawley Rat Model

Libin Yao
Department of General Surgery, the Affiliated Hospital of Xuzhou Medical University
https://orcid.org/0000-0001-8274-2857

Ponnie Robertlee Dolo
The Affiliated Hospital of Xuzhou Medical University

Yong Shao
Xuzhou Medical College Affiliated Hospital

Chao Li
Xuzhou Medical College Affiliated Hospital

Jason Widjaja
Xuzhou Medical College Affiliated Hospital

Jian Hong
Xuzhou Medical College Affiliated Hospital

Xiaocheng Zhu (zhuxccf@163.com)

Research article

Keywords: mesenteric defect; peterson's space; non-absorbable suture; absorbable suture

Posted Date: September 5th, 2019

DOI: https://doi.org/10.21203/rs.2.13908/v1

Version of Record: A version of this preprint was published on January 10th, 2020. See the published version at https://doi.org/10.1186/s12893-019-0671-9.

Abstract

Background: To observe if absorbable suture can effectively and safely be used to close the mesenteric defect after Roux-en-Y reconstruction. Methods: Rats were randomly assigned to 5 experimental groups according to different suture materials used in closing the mesenteric defects (Peterson's space) after Roux-en-Y gastric bypass. Group A (control group), Group B (non-absorbable suture, Prolene suture), Group C (biological glue), Group D (non-absorbable suture, polyester suture) and Group E (absorbable suture). All rats were followed up for 8 weeks postoperatively and underwent laparotomy to observe the degree of adhesion and closure of the mesenteric defect. Results: No significant difference was found in the decrease in food intake and body weight among all groups. No internal hernia (IH) occurred in any group. The mesenteric defects of Group A remained completely visible without any closure or adhesion. Multiple gaps were found between Prolene suture and the mesentery along the suture line in Group B. The mesenteric defects of Group C were complete closed with multiple adhesions of the small intestine and the greater omentum. The mesenteric defects had closed completely in both Group D and Group E. Average adhesion score of Group A and Group B was 0 and 0.33±0.52 respectively. Average adhesion score was higher in group C (3.83±0.41) than the other groups (p□0.05). Group D and E had similar average adhesion score, 3.17±0.41 and 3.00±0.00 respectively. Conclusion: Absorbable sutures can be effectively and safely used to close the mesenteric defect in a rat model.

Background

Internal hernia (IH) after abdominal surgery is not an uncommon clinical complication. It can occur many years after primary surgery or throughout life. It has serious consequences once it occurs; often requiring extensive intestinal resection. Therefore, it is essential to avoid the occurrence of IH. Most studies suggested that routine closure of mesenteric defect could reduce the risk of IH and also reduced mortality [1-7]. However, there is no uniform standard as to what sutures should be used for closing the mesenteric defect so far. Most surgeons prefer to close mesenteric defect using non-absorbable sutures which is even recommended by the ASMBS (American Society for Metabolic and Bariatric Surgery) [8]. The reason for not using absorbable sutures is mainly due to concerns that the mesenteric defect may reopened once the absorbable sutures are absorbed after surgery, potentially leading to the occurrence of intra-abdominal hernia. With the development of surgical sutures, absorbable sutures have been used extensively in clinical practice due to their good tensile strength, tissue compatibility and absorbability [9, 10]. However, whether absorbable sutures can effectively and safely be used in closing mesenteric defect is unknown.

In this study, we established a Rat model of Roux-en-Y gastric bypass and used different sutures to close mesenteric defect (Peterson's space) in order to explore the effectiveness and safety of using absorbable sutures to close mesenteric defect.

Methods

Study design

This study was approved by the ethics committee of Xuzhou Medical University Research Animal Centre. All applicable institutional and national guidelines of the People's Republic of China for the care and use of animals were followed.

30 male Sprague-Dawley obese rat (weight 350-380g and 8-10 weeks old) purchased from Xuzhou Medical University Research Animal Center were randomly divided into 5 groups (N=6). Rats in all groups underwent Roux-en-Y gastric bypass (RYGB). After gastrointestinal reconstruction during the RYGB, the roux limb mesenteric defect (Peterson's space) were managed using different methods and suture materials: (A) No intervention/closure, *control group*; (B) Closure using *non-absorbable prolene suture group* (Ethicon Prolene Polypropylene Suture 4-0); (C) Closure using *biological glue group* (Compon/kangpaite biological adhesive, Beijing); (D) Closure using *non-absorbable polyester suture group* (Ethicon Polyester suture 4-0); (E) Closure using *absorbable suture group* (Covidien Polysorb Braided Absorbable Suture 4-0). All rats were followed up for 8 weeks postoperatively.

Rodents in captivity are known to live for up to 3 years; making every day in the life of a rat equivalent to 35 human days [11]. Therefore 8 weeks in rodent will equate to approximately 5.4 human years. We therefore believe that 8 weeks was reasonable to assessing changes following the closure of the mesentery defect.

Following the end of the study, the rats were safely and ethically euthanized through overdose of isoflurane. Isoflurane exposure was continued for approximately one-minute after breathing stops.

Preoperative care

Rats were housed individually under constant ambient temperature and humidity on a 12 hours day/night cycle. Rats were allowed free access to normal chow. The study was approved by the ethics committee of Xuzhou Medical University Research Animal Center.

Surgical Procedure

After overnight fasting, at approximately nine a.m. rats were sedated with 5% Chloral Hydrate 0.5ml/100g through intraperitoneal injection. Under strict sterile condition, the rat was placed on the operating table and the incision site (mid-abdomen) cleaned with 5% povidone iodine without hair removal. An approximately 5cm mid-line incision was made. RYGB was performed in similar fashion as describe in our previous study [12]. Briefly, a 20% gastric pouch was created around the cardia. Biliopancreatic and roux-limb were 15 and 10 cm respectively. After RYGB reconstruction, the roux-limb mesenteric defect (Peterson's space, Fig. 1) in group B, C, D and E were closed using 4-0 non-absorbable suture (Ethicon Prolene Polypropylene Suture), biological glue, 4-0 non-absorbable suture (Polyester suture) and 4-0 absorbable suture (Covidien Polysorb Braided Absorbable Suture) respectively. In the glue group, we took extreme care to avoid spillage during the application of the glue, and the intestine and surrounding tissue were pull away; only release after the glue was completely dried. Peterson's space of the group A was left

unclosed as control group. Ceftriaxone (75mg/kg) injected intraperitoneally as antimicrobial prophylaxis before closing the abdomen. The abdomen was closed in two layer using a 3-0 non-absorbable suture. Operation time was 30±10 minutes for each rat in all groups. Rats were placed on a heating pad following surgery awaiting recovery from anesthesia. All rats were allowed free access to ad libitum with normal chow and tap water beginning 24 hours after surgery.

All rats underwent a laparotomy 8 weeks after surgery to observe whether the mesentery defect was successfully closed and the changes in suture materials. The roux limb mesenteric defect (Peterson's space) in all rats in each group were visually inspected to ascertain the degree of adhesion. The degree of adhesion is determined by a semi-quantitative grading method combine Blauer and Linsky's [13, 14]; adhesion scoring system: 0 = no adhesion; 1 = thin adhesion band, easy to separate, or adhesion on the suture plane ≤50%; 2 = thick adhesion band and adhesion on the suture plane 50%; 3 = complete adhesion on the suture plane and difficult to separate; 4 = more than 1 area of thick adhesion zone, adhesion between intestine and/or abdominal wall.

Statistics

All data are expressed as mean ± standard deviation (SD). Differences between the groups were assessed by one-way analysis of variance (ANOVA, LSD post-test). P 0.05 was assumed significant difference. Statistics were performed using SPSS, version 18.0, statistical software (SPSS Inc, Chicago, IL).

Results

Operative Results

The RYGB model was created in all rats in each group. All rats survive the surgery and follow-up for 8 weeks.

Food Intake and Body weight

Food intake and body weight decrease significantly in all surgical groups. Food intake decline by 25.9% ± 6.7%, 24.9% ± 6.3%, 24.4% ± 4.9%, 25.2% ± 4.6% and 26.7% ± 4.2% in Group A, B, C, D and E respectively. Decrease in bodyweight were 13.9% ± 2.1%, 14.2% ± 1.4%, 15.9% ± 5.3%, 14.6% ± 5.1% and 14.8% ± 3.8%, in Group A, B, C, D and E respectively at 8 weeks after surgery. There was no significant difference in all groups about food intake and body weight decrease. (Fig. 2)

IH and adhesion of the Mesenteric defects

All rats underwent a laparotomy 8 weeks after surgery. No IH was found in any rats and all anastomosis were remain intact in all groups.

The Peterson's space remains completely visible without any closure or adhesion at 8 weeks after surgery in the Group A (control group). Even though the defect remains completely visible, we did not find any internal herniation. We also did not find any bowel adhesion or obstruction (Fig. 3 A). In group B (non-absorbable prolene suture), we found multiple gaps formed between the suture and mesentery along the suture line. The gaps range from 0.5mm to 2mm. The suture material was also visibly present with little adhesion to the mesentery in some places along its course. We also did not find any adhesion of the small intestine or adjacent structures along the suture line (Fig. 3 B). A complete closure of the Peterson's space was found in Group C (Glue). However, there were multiple adhesions of the small intestine and the greater omentum throughout the area of the glue application. Nevertheless, there were no visible internal herniation or bowel obstruction (Fig. 3 C). During Laparotomy 8 weeks after closure with non-absorbable suture in Group D (non-absorbable polyester suture), we found that the mesenteric defect had closed completely. However, the suture was still present. Additionally, there were multiple adhesions along the suture plane (Fig. 3 D). While we also found that the mesenteric defect was completely closed in Group E (absorbable suture). And the suture had completely absorbed leaving a smooth plane along the line of suture. The adhesions between mesenteries near sutures were tight (Fig. 3 E).

The group C (Glue) showed highest average adhesion score (3.83±0.41) among all groups. Group A had no any adhesion and adhesion score were all 0, similar results were in group B. The group D and E had similar average adhesion score, 3.17±0.41 and 3.00±0.00 respectively, there were no significant difference between two groups ($p > 0.05$). But both were lower than group C ($p < 0.05$) (Fig. 4).

Discussion

In this study, our results showed that absorbable suture can safely and effectively be used to close the mesenteric defect (Peterson's space). In our experiment we also found that the mesenteric defect was completely closed in the absorbable and non-absorbable (Group D non-absorbable polyester suture) sutures groups, as well as the glue group but not in the prolene group (Group B, non-absorbable prolene suture) when the rats were sacrificed 8 weeks after surgery. The mesenteric defect in the control group was still opened with almost no adhesion in the Peterson's space.

Many materials are used to close mesenteric defects, including various non-absorbable sutures, stapler, biological glue, hernia mesh, hernia clips and so on [4, 6, 8, 15-17]. Some surgeons are accustomed to closing the mesenteric defects using prolene sutures because of its non-absorbability and smoothness, but our experiment results indicated that adhesion in prolene group was minimum, and importantly, we found gaps formed between the suture and mesentery along the suture line likely indicating that using prolene sutures may not be safe to close the mesenteric defect probably because of the light tissue response and little adhesion. Moreover, this situation is likely exacerbated by the weight loss and decrease in mesentery fat that occurs after bariatric surgery. Using another non-absorbable suture (4-0 Polyester suture) we found a complete closure and adhesion of the mesenteric defect although the suture was still present.

Non-absorbable sutures (prolene) may lead to some small gap formation between the suture and the mesentery due to the decrease of mesenteric fat following weight loss in gastric bypass, which may also be a potential risk for postoperative internal hernia formation. We want to emphasize that IH may still occurred after operation irrespective of the suture material due to improper suture technique.

Biological glue can also be used to close mesenteric defect based on findings in this study. However, the use of glue was associated with surrounding tissue and intestinal adhesion in the area glue applied. The average adhesion score in the glue group was the highest among all groups. Therefore, it is feasible to use the glue to close the mesenteric defect, but the risk of intestinal and surrounding tissue adhesion is high, likely because it is difficult to control the amount of glue during application. However, Mark Magdy et al closed Petersen's space using bioabsorbable mesh with fibrin glue fixation with a good result [16].

It is unknown about whether absorbable suture can be effectively and safely used to close mesenteric defects. The purpose of this study was to try to explore this problem. The results of absorbable suture group showed a complete closure of the mesentery defect with the sutures completely absorbed leaving a smooth plane along the sutured line. There were no visible bowel adhesions or internal herniation. This indicates that absorbable sutures are safe and effective in closing mesenteric defects. Gumbs et al [18] analyzed 152 patients in whom laparoscopic Roux-en-y gastric bypass (LRYGB) was performed. They recorded jejunojejunal anastomotic obstruction occurred in 7 patients due to small intestine adhesion which was attributed to the Dacron suture. Their study therefore indicated that non absorbable suture is not a good selection to close the jejunojejunal mesenteric leaves defect.

No matter what suture is used, the closure of the mesenteric defect ultimately depends on the adhesion between mesentery. Comparing all methods used in our experiment, applying absorbable suture to close the mesenteric defect is safe, effective, and feasible. Moreover, the absorbable suture may be superior to the non-absorbable suture and glue to close the mesenteric defect, because it did not cause extra adhesions of intestine or formed small gap between the suture and the mesentery due to a complete absorption 8 weeks after surgery.

Here we need to emphasize that different absorbable sutures require different time of absorption. The absorbable time of the absorbable suture used in our experiment is about 2 months, so it is unknown if other absorbable sutures (shorter or longer absorbable time) could be safely used in closing mesenteric defect. We think a suture with too short absorbable time (one or two weeks) may not be suitable for closing mesenteric defects, because adhesions between mesentery may not formed or not be firm in such a short period of time.

Limitations

The obvious shortcoming of this study is the use of animal model to perform the experiment which cannot completely represent humans, and absence of internal hernia in any group may be due to the small number of rats and short follow up, so long term results need to be further studied. Although we have used absorbable sutures to close the mesenteric defect in dozens of patients with radical

gastrectomy and no IH was found after more than one year of follow-up, large clinical trial of multi-center study is needed to clarify the safety and effectiveness of absorbable sutures used to close mesenteric defects.

Conclusion

In conclusion, we have demonstrated that the application of absorbable sutures to close mesenteric defect is safe and feasible and may be superior to other suture materials based on findings in our experimental study. Therefore, we believed absorbable sutures can be effectively and safely used to close mesenteric defect as well as non-absorbable sutures.

Declarations

Ethics approval and consent to participate: Not applicable.

Consent for publication: Not applicable.

Availability of data and materials: The datasets used and/or analysed during the current study are available from the corresponding author on reasonable request.

Competing interests:

LB. Y. declare that he has no competing interests

P.R.D. declare that he has no competing interests

Y.S. declare that he has no competing interests

C.L. declare that he has no competing interests

J.W. declare that he has no competing interests

J.H. declare that he has no competing interests

XC. Z. declare that he has no competing interests

Funding: This work was supported by the *science and technology program project of Xuzhou* (KC17201).

Authors' contributions:

LBY, PRD and XCZ conceived and designed the experiment. LBY, PRD, JW and JH carried out the animal experiment. LBY, PRD, YS, CL, JW and JH collected the experimental data. LBY, PRD, YS and CL analyzed the data. LBY and PRD wrote the manuscript JW and XCZ revised the manuscript. All authors read and approved the final manuscript.

Acknowledgements: Not applicable.

References

1. Kimura H, Ishikawa M, Nabae T, Matsunaga T, Murakami S, Kawamoto M, Kamimura T, Uchiyama A: Internal hernia after laparoscopic gastrectomy with Roux-en-Y reconstruction for gastric cancer. Asian journal of surgery 2017, 40(3):203-209.
2. Geubbels N, Lijftogt N, Fiocco M, van Leersum NJ, Wouters MW, de Brauw LM: Meta-analysis of internal herniation after gastric bypass surgery. The British journal of surgery 2015, 102(5):451-460.
3. de la Cruz-Munoz N, Cabrera JC, Cuesta M, Hartnett S, Rojas R: Closure of mesenteric defect can lead to decrease in internal hernias after Roux-en-Y gastric bypass. Surgery for obesity and related diseases : official journal of the American Society for Bariatric Surgery 2011, 7(2):176-180.
4. Coleman MH, Awad ZT, Pomp A, Gagner M: Laparoscopic closure of the Petersen mesenteric defect. Obesity surgery 2006, 16(6):770-772.
5. Laessle C, Fink J, Kusters S, Seifert G, Hoppner J, Marjanovic G: [Internal Hernia Following Laparoscopic Roux-Y Gastric Bypass - a Challenge not only for the General Surgeon]. Zentralblatt fur Chirurgie 2017, 142(1):20-22.
6. Liu CL, Lo CM, Chan SC, Fan ST, Wong J: Internal hernia of the small bowel after right-lobe live donor liver transplantation. Clinical transplantation 2004, 18(2):211-213.
7. Stenberg E, Szabo E, Agren G, Ottosson J, Marsk R, Lonroth H, Boman L, Magnuson A, Thorell A, Naslund I: Closure of mesenteric defects in laparoscopic gastric bypass: a multicentre, randomised, parallel, open-label trial. Lancet (London, England) 2016, 387(10026):1397-1404.
8. Ninh T. Nguyen RPB, John M. Morton, Jaime Ponce, Raul J. Rosenthal: The ASMBS Textbook of Bariatric Surgery, vol. 1, 215. New York: Springer; 2015.
9. Gierek M, Kusnierz K, Lampe P, Ochala G, Kurek J, Hekner B, Merkel K, Majewski J: Absorbable sutures in general surgery - review, available materials, and optimum choices. Polski przeglad chirurgiczny 2018, 90(2):34-37.
10. Togo S, Kubota T, Takahashi T, Yoshida K, Matsuo K, Morioka D, Tanaka K, Shimada H: Usefulness of absorbable sutures in preventing surgical site infection in hepatectomy. Journal of gastrointestinal surgery : official journal of the Society for Surgery of the Alimentary Tract 2008, 12(6):1041-1046.
11. Sengupta P: The Laboratory Rat: Relating Its Age With Human's. International journal of preventive medicine 2013, 4(6):624-630.
12. Dolo PR, Yao L, Li C, Zhu X, Shi L, Widjaja J: Preserving Duodenal-Jejunal (Foregut) Transit Does Not Impair Glucose Tolerance and Diabetes Remission Following Gastric Bypass in Type 2 Diabetes Sprague-Dawley Rat Model. Obesity surgery 2018, 28(5):1313-1320.
13. Blauer KL, Collins RL: The effect of intraperitoneal progesterone on postoperative adhesion formation in rabbits. Fertility and sterility 1988, 49(1):144-149.

14. Linsky CB, Diamond MP, Cunningham T, Constantine B, DeCherney AH, diZerega GS: Adhesion reduction in the rabbit uterine horn model using an absorbable barrier, TC-7. The Journal of reproductive medicine 1987, 32(1):17-20.
15. Kristensen SD, Floyd AK, Naver L, Jess P: Does the closure of mesenteric defects during laparoscopic gastric bypass surgery cause complications? Surgery for obesity and related diseases : official journal of the American Society for Bariatric Surgery 2015, 11(2):459-464.
16. Magdy M, Suh H, Kuzinkovas V: Novel technique using a bioabsorbable prosthesis with fibrin glue fixation to prevent a Petersen's space hernia. Journal of surgical case reports 2017, 2017(12):rjx246.
17. Kristensen SD, Naver L, Jess P, Floyd AK: Effect of closure of the mesenteric defect during laparoscopic gastric bypass and prevention of internal hernia. Danish medical journal 2014, 61(6):A4854.
18. Gumbs AA, Duffy AJ, Chandwani R, Bell RL: Jejunojejunal anastomotic obstruction following laparoscopic Roux-en-Y gastric bypass due to non-absorbable suture: a report of seven cases. Obesity surgery 2006, 16(1):12-15.

Figures

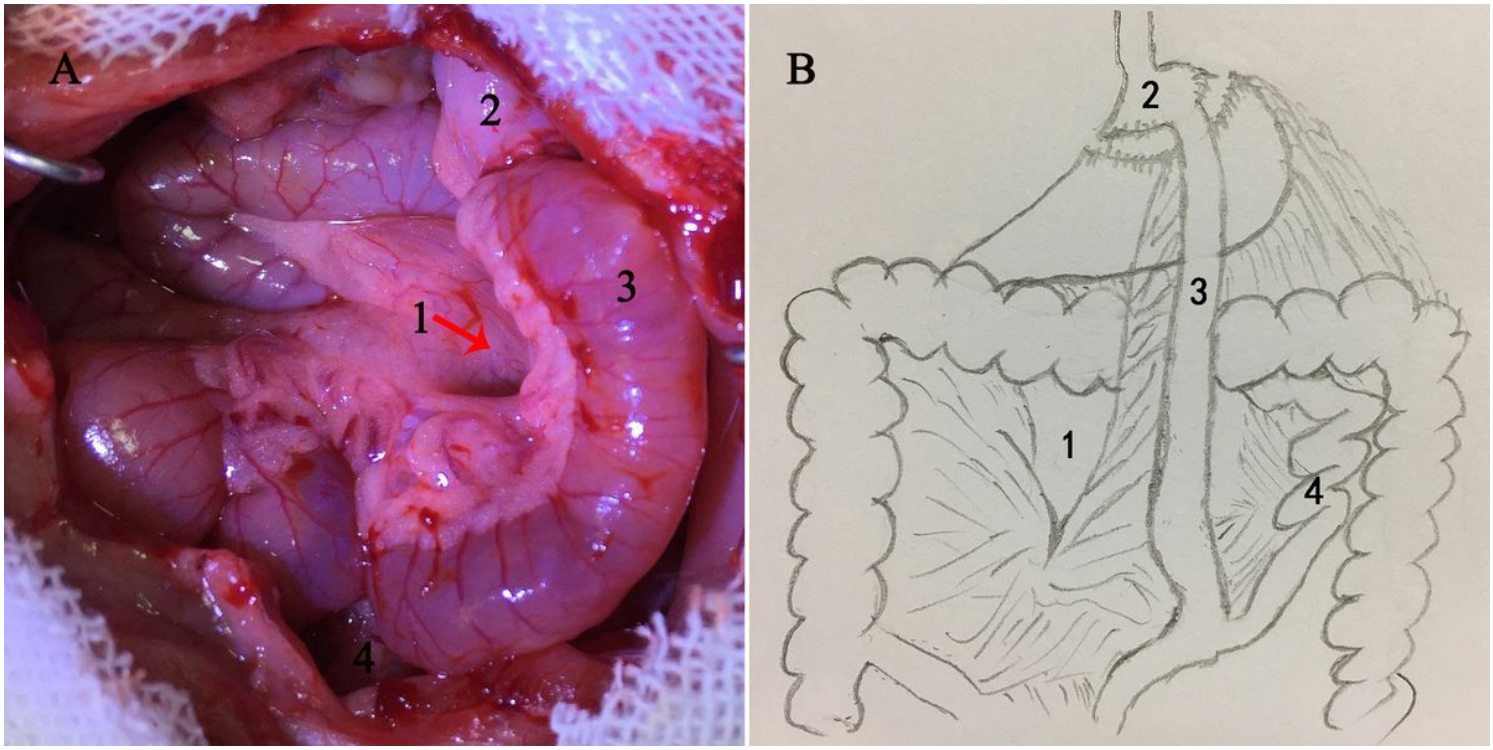

Figure 1

Illustrations of Peterson’s space formed in Roux-en-Y gastric bypass (RYGB). (A) RYGB surgery of rats (B) Sketch of RYGB surgery. 1. Peterson’s space 2. Small stomach pouch 3. Roux-limb 4. Biliopancreatic limb.

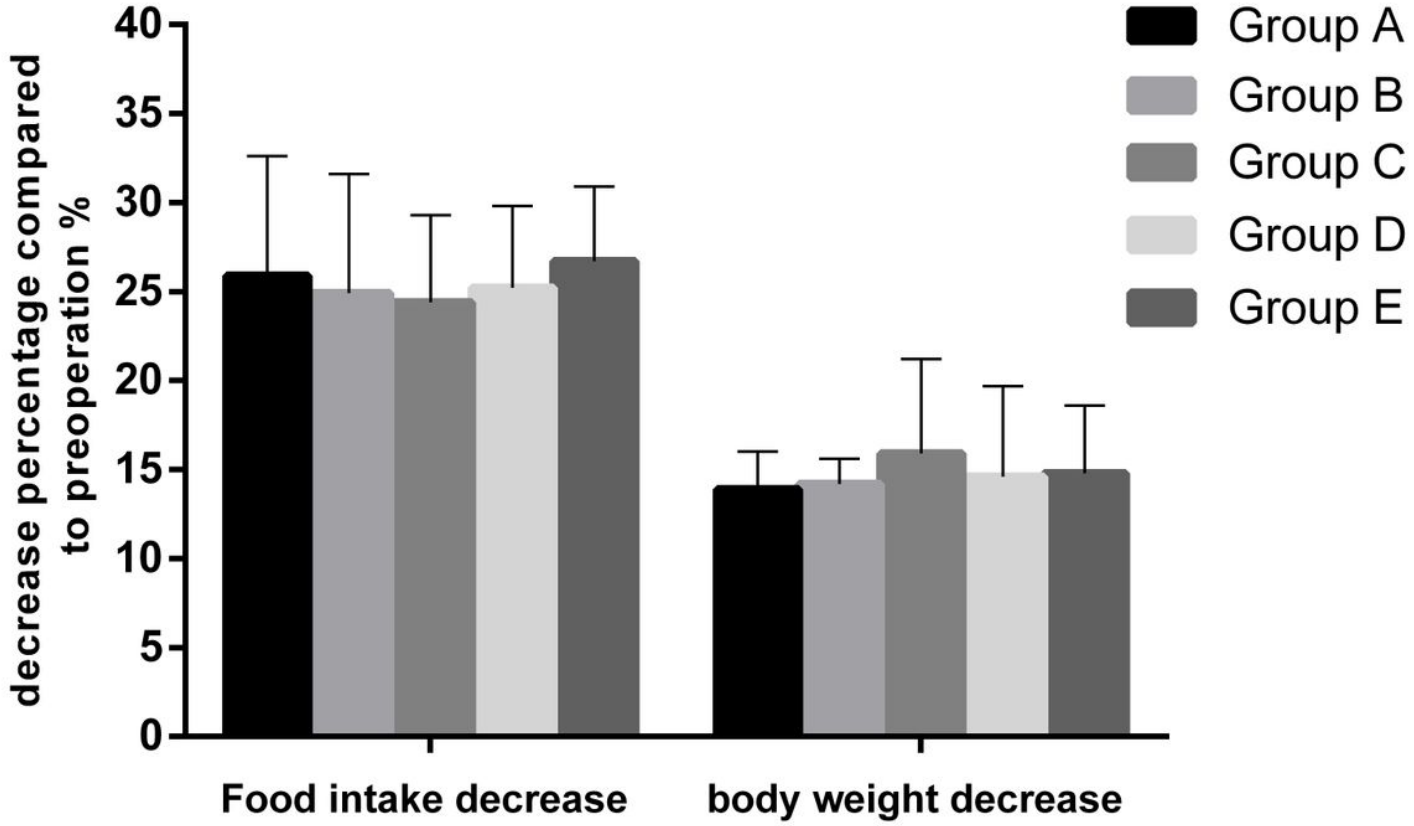

Figure 2

Food intake and body weight decrease 8 weeks after surgery. The data showed no significant difference was found in food intake and body weight decrease among all groups. Group A (Control group), Group B (non-absorbable Ethicon Prolene Polypropylene Suture), Group C (biological glue, Compon/kangpaite biological adhesive, Beijing), Group D (non-absorbable Ethicon Polyester Suture), Group E (absorbable Covidien Polysorb Braided Absorbable Suture).

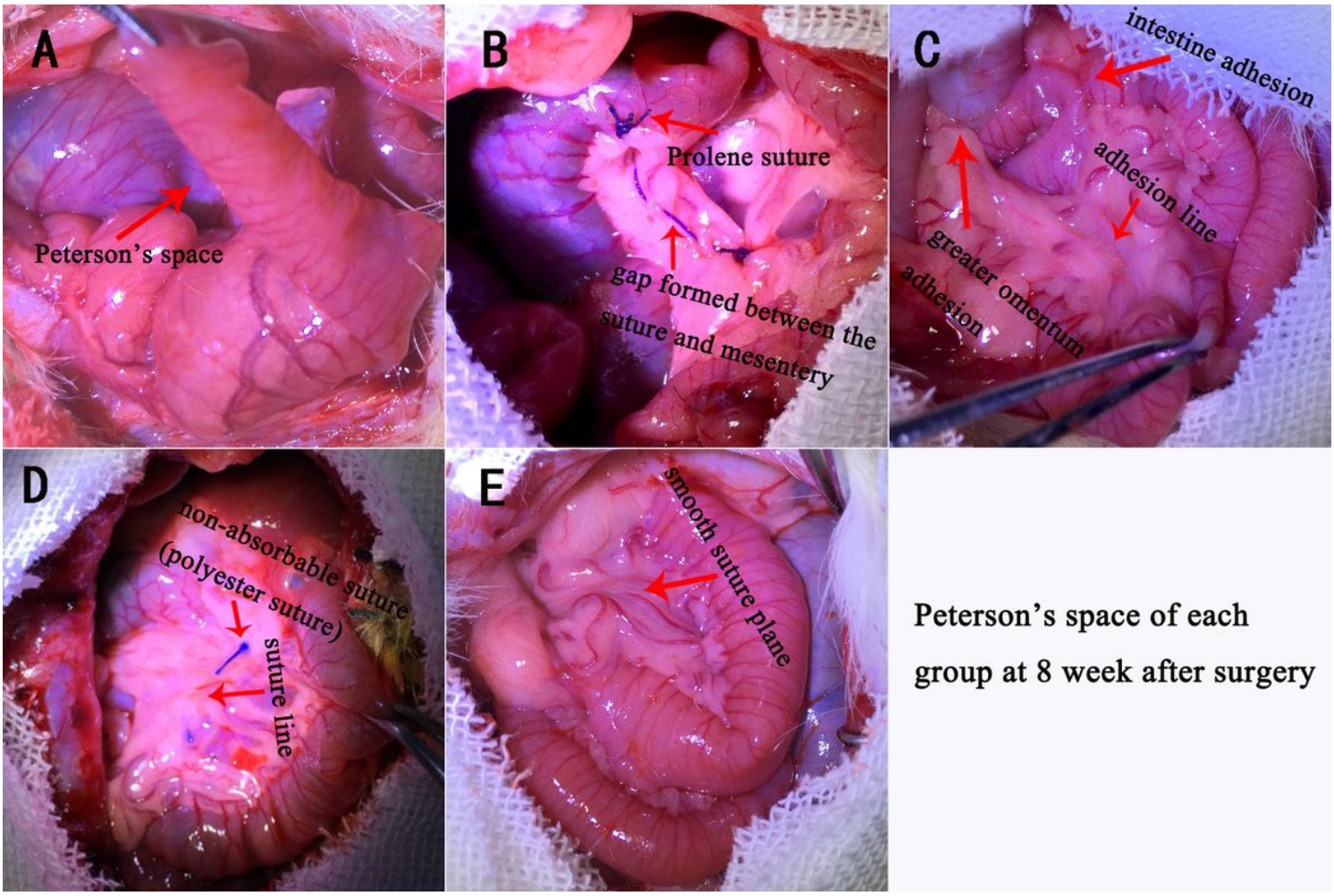

Figure 3

The results of mesenteric defect (Peterson's space) of each group at 8 weeks after surgery. No IH was found in any group. (A) Control group. The Peterson's space remains completely visible without any closure or adhesion. (B) Prolene suture group. Multiple gaps were found between prolene suture and the mesentery along the suture line. The gaps range from 0.5mm to 2mm. The suture material was visibly present with little adhesion to the mesentery. (C) Glue group. The Peterson's space was complete closure and multiple adhesions of the small intestine and the greater omentum throughout the area of the glue application. (D) Non-absorbable suture group (Polyester suture). The Peterson's space had closed completely. The suture was still present, and adhesions along the suture plane was found. (E) The Peterson's space was completely closed and the suture had completely absorbed leaving a smooth plane along the line of suture. The adhesions between mesentery near sutures were tight.

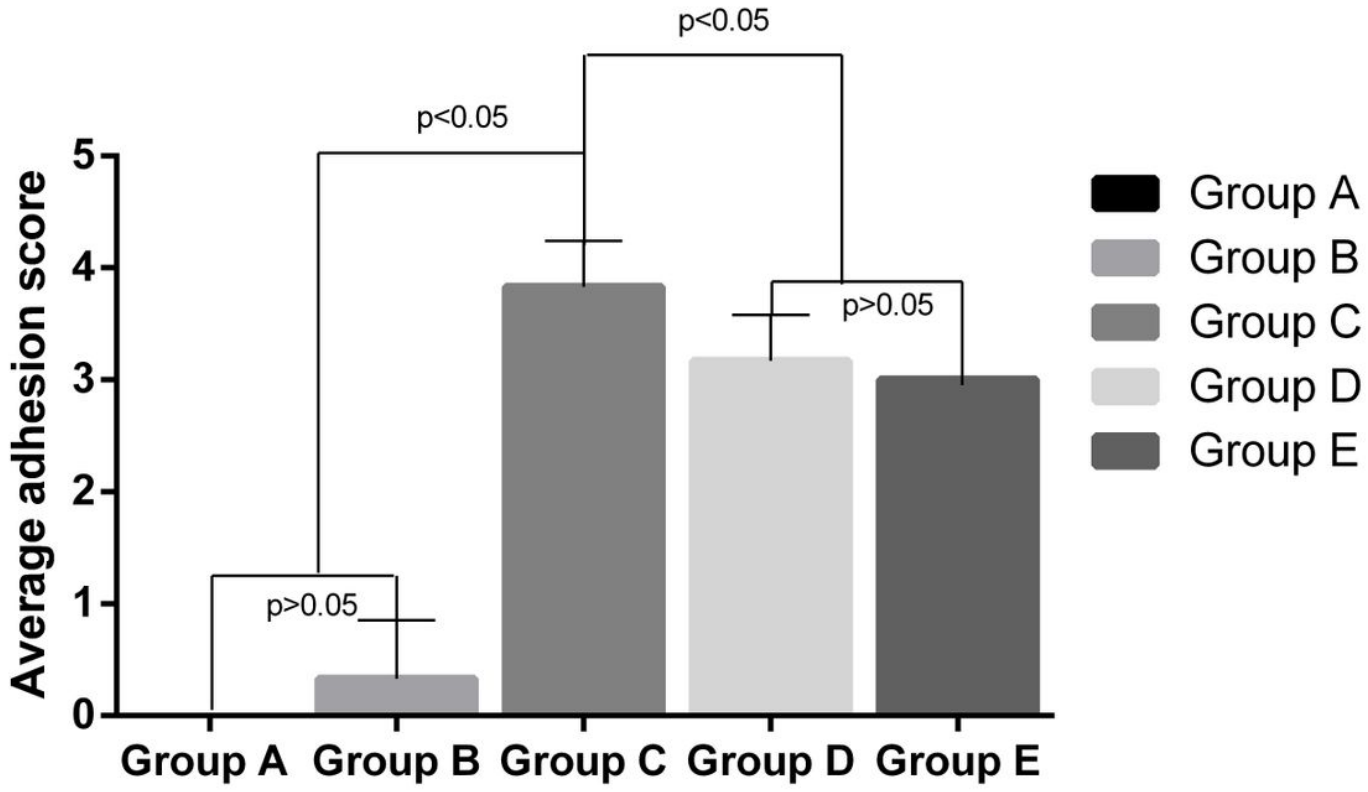

Figure 4

Average adhesion score of each group. Average adhesion scores of Group A and B were 0 and 0.33±0.52 respectively (p□0.05). The group C showed the higher adhesion score of 3.83±0.41compared to the other groups (p□0.05). Group D and E had similar adhesion scores of 3.17±0.41 and 3.00±0.00 respectively (p□ 0.05). Group A (Control group), Group B (non-absorbable Ethicon Prolene Polypropylene Suture), Group C (biological glue, Compon/kangpaite biological adhesive, Beijing), Group D (non-absorbable Ethicon Polyester Suture), Group E (absorbable Covidien Polysorb Braided Absorbable Suture).

Supplementary Files

This is a list of supplementary files associated with this preprint. Click to download.

- supplement1.pdf