Metastasis of the Right Thigh From Cholangiocarcinoma: A Case Report

Hongwei Qian
Shaoxing People's Hospital https://orcid.org/0000-0002-6724-9826

Zhikun Huang
Shaoxing People's Hospital

Peitu Ren (13806750572@163.com)
https://orcid.org/0000-0002-6371-3185

Xuezheng Sun
Shaoxing People's Hospital

Case report

Keywords: Cholangiocarcinoma, Skeletal muscle metastasis, Perineural invasion

Posted Date: July 29th, 2020

DOI: https://doi.org/10.21203/rs.3.rs-46113/v1

Abstract

Background: Cholangiocarcinoma (CCA) is a type of malignant tumor that arises from the epithelium of the bile ducts. CCA can invade and metastasize to other tissues in a variety of ways but distal skeletal muscle metastasis is extremely rare.

Case presentation: We present a case of metastasis of the right thigh from cholangiocarcinoma.

Conclusion: Perineural invasion may be a pathway of distant metastasis in CCA that has not been not widely recognized. We advocate the complete removal of tumor with dissection of the nerve plexus around major vessels.

Introduction

Cholangiocarcinoma (CCA) is a type of malignant tumor that arises from the epithelium of the bile ducts,which generally refers to extrahepatic cholangiocarcinoma(EHCCA). There has been an increase in the early detection rate of CCA due to recent improvements in imaging technology, but the treatment effect is still very poor[1, 2]. CCA can invade and metastasize to other tissues in a variety of ways such as lymphatic metastasis, nerve metastasis, direct invasion, etc. The common sites of metastasis are local lymph nodes, liver, lungs, and bones. Soft tissue metastasis of the right thigh is extremely rare. Here, we present a case of metastasis of the right thigh from CCA.

Case Report

A 71-year old woman was admitted to our hospital on January 1, 2019,with complaints of yellow skin and sclera, yellow urine, and upper abdominal discomfort for 2 weeks. Laboratory examination: liver function: ALT 85. U/L AST U/L GGT 722. U/L TBIL 36.4umol/L, DBIL 29.9umol/L; Blood routine: WBC 7×10^9 /L, N 72%, Hb 130.5 g/L. Tumor marker: CA199 244.93u/ml, CA50 94.16iu/ml, CEA 4.0 ng/ml. B-ultrasonography, CT, and MRI showed space-occupying lesions in the middle and upper segment of the common bile duct, therefore the operation of pancreatoduodenectomy and partial hepatectomy was performed with the suspected diagnosis of bile duct malignant tumor. The postoperative pathological diagnosis was poorly differentiated adenocarcinoma of bile duct, involving pancreatic tissue, cystic duct, and focal nerve, no vascular infiltration or lymph node metastasis was found (Fig. 1).

After discharge, the patient was then subjected to chemotherapy with gimeracil and oteracil porassium capsules(50 mg bid PO d1-14, q21d),but itchy skin and obvious edema of lower extremities occurred during the treatment. At 9 months after operation the patient had shown very obvious swelling of the right thigh, with local pain and limited activity. After a period of outpatient treatment, the symptoms were not significantly relieved, so she was re-admitted to our hospital on December 6, 2019. Physical examination: temperature 36.5 °C, pulse 85 bpm, respiration 19 bpm, blood pressure 152/81 mmHg. The patient was emaciated but had no jaundice. The heart and lungs were normal. The abdomen was flat and soft, with no tenderness or enlarged liver, spleen, or mass was palpable. The right thigh was severely

swollen, with dilated superficial veins and obvious local tenderness (Fig. 2). Laboratory examination: Blood routine: WBC 6.2 × 10^9/L, N 69%, Hb 6.1 g/L. Liver function: ALT 13. U/L AST 17. U/L GGT 38. U/L TBIL 9.6umol/L, DBIL 4.8umol/L; Tumor marker: CA199 1184.83u/ml, CA50 179.8iu/ml, CA125 70.5u/ml. B-ultrasound showed that there was no deep vein stenosis or occlusion of the lower extremities and the blood flow was unobstructed (Fig. 3A). No new tumors in the liver or surrounding organs were found by abdominal CT examination, while MRI examination of the right thigh showed two intermuscular soft tissue signals. The parenchymal components of the masses showed isointense T1W(figure 3B) and slightly high T2W signals figure 3C , and the sizes of the two tumors were about 157 mm × 123 mm, and 112 mm × 87 mm. The larger lesion with multiple irregular cystic foci oppressed the thigh muscles, which led to atrophy of the muscles. And local invasive bone and muscle showed plaque high signals on MRI (Fig. 3D). According to the MRI findings, the image diagnosis was soft tissue malignant tumor, and postoperative metastasis of cholangiocarcinoma was first considered.

To further confirm the diagnosis of the lower right mass, a fine-needle biopsy was performed for pathological examinations and immunohistochemistry. Immunohistochemical staining demonstrated tumor cells with CK19(+), CKpan(+) EMA(+) Vim(-) Ki-67 (+30%) CgA(-) SMA(-) DM(-) Syn(-) CD7(+) CD34(-) CD31(-) (Fig. 7), and the pathological diagnosis was postoperative metastasis of cholangiocarcinoma. The results of the pathological immunohistochemical examination of the masses in the right lower limb were consistent with those after radical resection of cholangiocarcinoma, in particular the results of CK19 + CK7(+) Ki-69 +, and confirmed the diagnosis of metastasis of right thigh from cholangiocarcinoma.

Symptomatic treatment was provided to the patient after the pathological diagnosis, as she refused to receive surgical resection, systemic chemotherapy, local radiotherapy, or particle implantation radiotherapy. After discharge, the patient was treated with Chinese herbal medicine and painkillers, but the effect was not good. With the extremely rapid growth of the tumor in the right lower limb, the patient died of systemic failure 3 months later.

Discussion

Distant metastasis of cholangiocarcinoma is a late manifestation of malignant tumors, with extremely poor prognosis and short survival time. CCA can invade and metastasize to other tissues in a variety of ways, primarily through the lymphatic vasculature system, but the incidence of skeletal muscle metastases is very low(less than 1% of metastases of hematogeneous origin), despite the skeletal muscle accounting for approximately 50% of the total body mass and its rich blood supply[3]. There are very few reports of distant skeletal muscle metastasis of cholangiocarcinoma, and the cases of soft tissue metastasis of lower extremities with a definite pathological diagnosis are rarer.

Only 6 cases of metastases to skeletal muscle from cholangiocarcinoma have been reported in the world literature[4], the main reason for the lack of relevant reports is the poor prognosis of cholangiocarcinoma, but under-diagnosis may also contribute to the low incidence, as the most cases of skeletal muscle

metastases are asymptomatic, nonspecific, and in hidden locations[5]. Cases like ours with obvious clinical symptoms are quite rare. But in fact the incidence of skeletal metastasis is not that low, in 194 autopsies performed at the Marque de Valdecilla National Medical Center, almost 20% of the patients with carcinoma had muscle metastasis[6]. With the progress of imaging, the detection of skeletal muscle metastasis also increases. MRI plays an important role in the diagnosis of skeletal muscle metastasis and is considered to be the gold standard for imaging of skeletal muscle disease[7]. Skeletal muscle metastasis usually has a lowintense to isointense signal in T1W and high signal intensity in T2W[8], and in our case, the parenchymal components of the masses showed isointense T1W and slightly high T2W signals.

The reason for this low skeletal muscle metastatic rate is not well understood, but some factors have been considered to be implicated in the rarity of soft tissue metastases: (1)lactic acid produced by skeletal muscle[9]; (2)varying tissue pressure in skeletal muscle and the influence of β adrenergic receptors[10];(3)protease inhibitors located in the basement membrane[11]; (4)the constant movement of skeletal muscles[3]; (5)the antitumor activity of lymphocytes or natural killer cells within the skeletal muscle[12]. EHCCA can spread through any of the following ways: direct invasion, peritoneal seeding, hematogenous metastasis, lymphatic metastasis, and perineural invasion, but the pathway of distant skeletal muscle metastasis of cholangiocarcinoma is not clear yet. In our case, the pathological diagnosis was poorly differentiated adenocarcinoma of bile duct, with cystic duct, pancreatic tissue, and focal nerve infiltration, but no vascular infiltration or lymph node metastasis was found. Therefore, we think that perineural invasion may play an important role in this case of skeletal muscle metastasis. Perineural invasion is quite common in EHCCA, reported occurring in about 80% of patients with EHCCA[13]. Zhang et al.[14] treated the perineural invasion as an independent risk factor in cholangiocarcinoma, presenting worse recurrence and survival outcomes. Perineural invasion is an important pathological feature of cholangiocarcinoma, characterized by tumor cells surrounding nerve fibers and entering the perineurium or neural fascicles. Li et at.[15] thought perineural invasion is a pathway of distant metastasis in CCA that has not been not widely recognized, and can occur in the absence of lymphatic or vascular involvement. In our case, the perineural invasion may be a route for the local spread and distant skeletal muscle metastasis, associated with the poor prognosis.

Conclusion

Therefore, in an effort to improve prognosis, the complete removal of tumor with dissection of the nerve plexus around major vessels should be advocated when skeletonizing the hepatoduodenal ligament.

Abbreviations

CCA
Cholangiocarcinoma; EHCCA:Extrahepatic Cholangiocarcinoma.

Declarations

Ethics approval and consent to participate

The report was approved by the Ethics Committee of Shaoxing people's Hospital, reference number 2020Ethics clearance NO(76).

Consent for publication

Written informed consent for publication of the clinical details and clinical images was obtained from the patient and the relative of the patient.

Availability of data and materials

All data generated or analyzed during this study are included in this manuscript.

Competing interests

The authors declare that they have no competing interests.

Authors' contributions

HQ collected the clinical data and wrote the manuscript, ZH was the treatment plan maker and consulted the relevant literature to analyze the case. HQ and ZH contributed equally to this work. XZ and PR participated in the whole treatment process and sorted out the relevant medical records of the case.

Acknowledgements

Not applicable.

References

[1] Khan AS, Dageforde LA. Cholangiocarcinoma[J]. Surg Clin North Am, 2019, 99(2): 315-335. https://doi.org/10.1016/j.suc.2018.12.004

[2] Khan SA, Davidson BR, Goldin R, et al. Guidelines for the diagnosis and treatment of cholangiocarcinoma: consensus document[J]. Gut, 2002, 51 Suppl 6: VI1-9. https://doi.org/10.1136/gut.51.suppl_6.vi1

[3] Kwon OS, Jun DW, Kim SH, et al. Distant skeletal muscle metastasis from intrahepatic cholangiocarcinoma presenting as Budd-Chiari syndrome[J]. World J Gastroenterol, 2007, 13(22): 3141-3143. https://doi.org/10.3748/wjg.v13.i22.3141

[4] Lee J, Lee SW, Han SY, et al. Rapidly aggravated skeletal muscle metastases from an intrahepatic cholangiocarcinoma[J]. World J Gastroenterol, 2015, 21(6): 1989-1993.

https://doi.org/10.3748/wjg.v21.i6.1989

[5] Cione GP, Arciero G, De Angelis CP, et al. [Intrahepatic cholangiocarcinoma: case report][J]. Suppl Tumori, 2005, 4(3): S46-47.

[6] Acinas Garcia O, Fernandez FA, Satue EG, et al. Metastasis of malignant neoplasms to skeletal muscle[J]. Rev Esp Oncol, 1984, 31(1): 57-67.

[7] Pretorius ES, Fishman EK. Helical CT of skeletal muscle metastases from primary carcinomas[J]. AJR Am J Roentgenol, 2000, 174(2): 401-404. https://doi.org/10.2214/ajr.174.2.1740401

[8] Suto Y, Yamaguchi Y, Sugihara S. Skeletal muscle metastasis from lung carcinoma: MR findings[J]. J Comput Assist Tomogr, 1997, 21(2): 304-305. https://doi.org/10.1097/00004728-199703000-00027

[9] Seely S. Possible reasons for the high resistance of muscle to cancer[J]. Med Hypotheses, 1980, 6(2): 133-137. https://doi.org/10.1016/0306-9877(80)90079-1

[10] Yoshimura Y, Isobe K, Koike T, et al. Metastatic carcinoma to subcutaneous tissue and skeletal muscle: clinicopathological features in 11 cases[J]. Jpn J Clin Oncol, 2011, 41(3): 358-364. https://doi.org/10.1093/jjco/hyq199

[11] Pauli BU, Schwartz DE, Thonar EJ, et al. Tumor invasion and host extracellular matrix[J]. Cancer Metastasis Rev, 1983, 2(2): 129-152. https://doi.org/10.1007/BF00048966

[12] Sudo A, Ogihara Y, Shiokawa Y, et al. Intramuscular metastasis of carcinoma[J]. Clin Orthop Relat Res, 1993, (296): 213-217.

[13] Murakami Y, Uemura K, Sudo T, et al. Perineural invasion in extrahepatic cholangiocarcinoma: prognostic impact and treatment strategies[J]. J Gastrointest Surg, 2013, 17(8): 1429-1439. https://doi.org/10.1007/s11605-013-2251-0

[14] Zhang Z, Zhou Y, Hu K, et al. Perineural invasion as a prognostic factor for intrahepatic cholangiocarcinoma after curative resection and a potential indication for postoperative chemotherapy: a retrospective cohort study[J]. BMC Cancer, 2020, 20(1): 270. https://doi.org/10.1186/s12885-020-06781-w

[15] Li CG, Huang ZQ, Wei LX, et al. [Perineural invasion in hilar cholangiocarcinoma and distribution of nerve plexuses around porta hepatis][J]. Zhonghua Yi Xue Za Zhi, 2012, 92(38): 2699-2702.

Figures

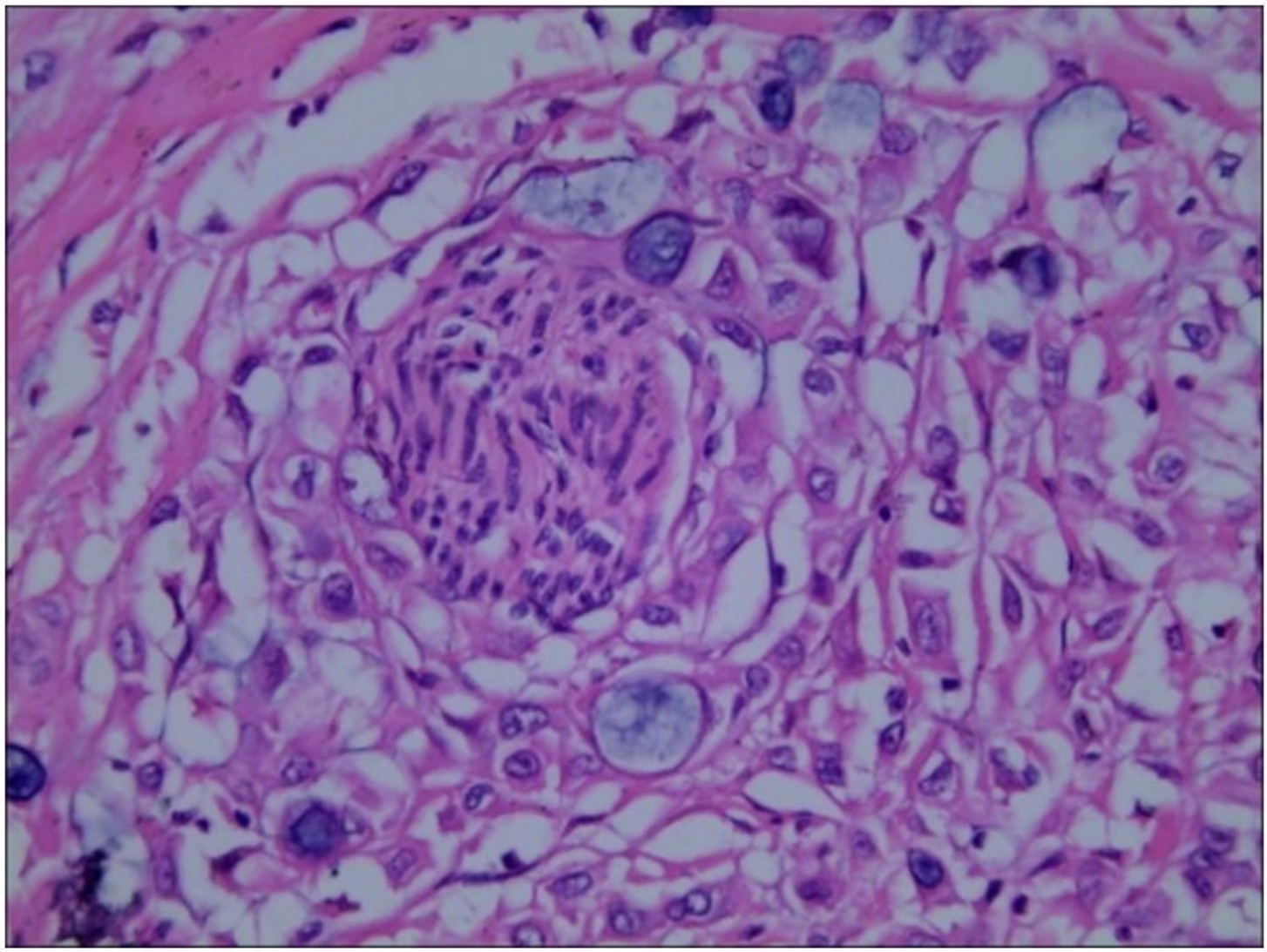

Figure 1

The tumor invaded nerve tissue (HE staining, 400×).

Figure 2

Pathological changes of swelling soft tissue in the right thigh.

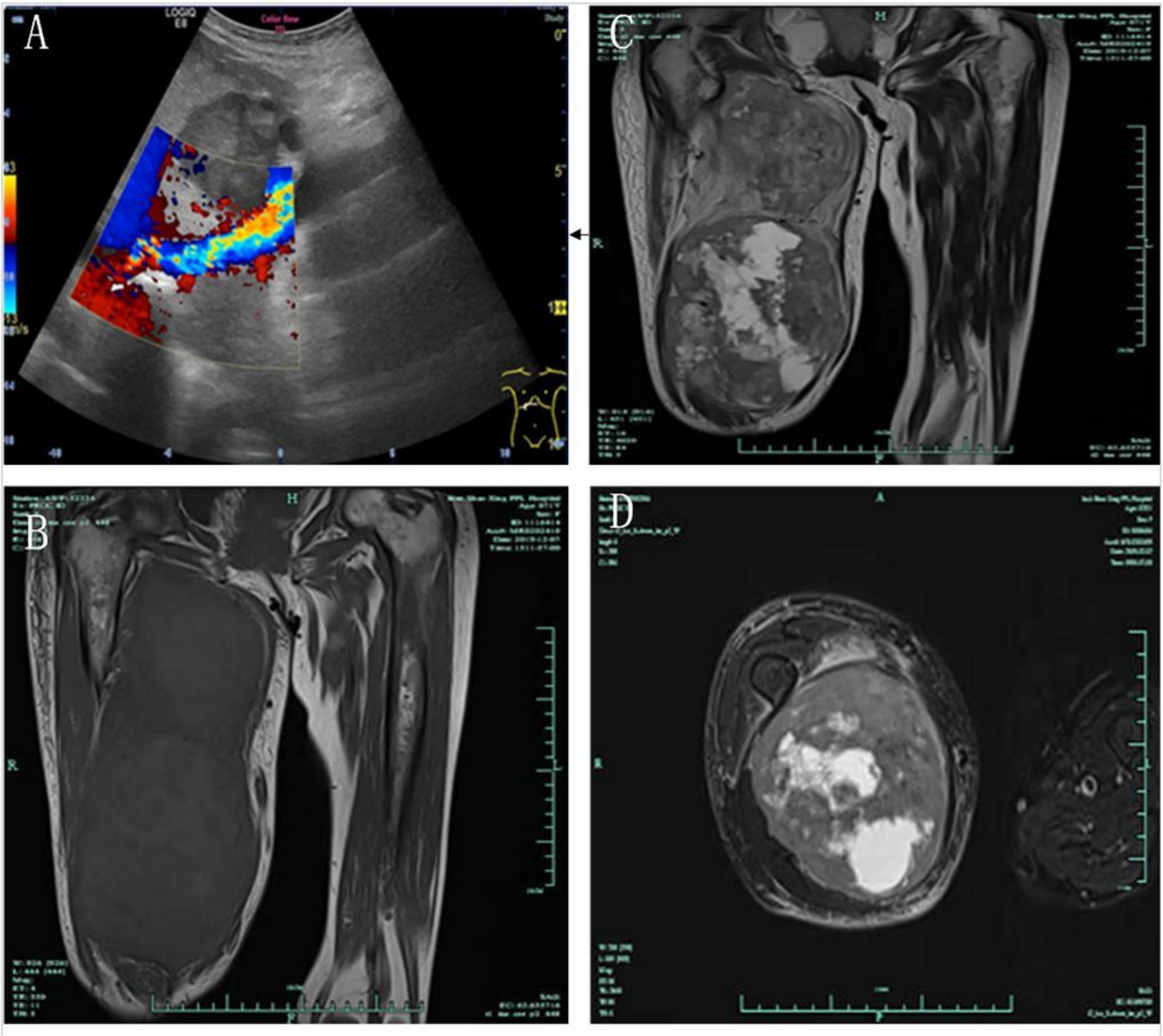

Figure 3

B-ultrasound showed that there was no deep vein stenosis or occlusion of the lower extremities and the blood flow was unobstructed(A). MRI showed two intermuscular soft tissue signals, and the parenchymal components of the masses showed isointense T1W(B) and slightly high T2W signals(C). Local invasive bone and muscle showed plaque high signals on MRI(D).

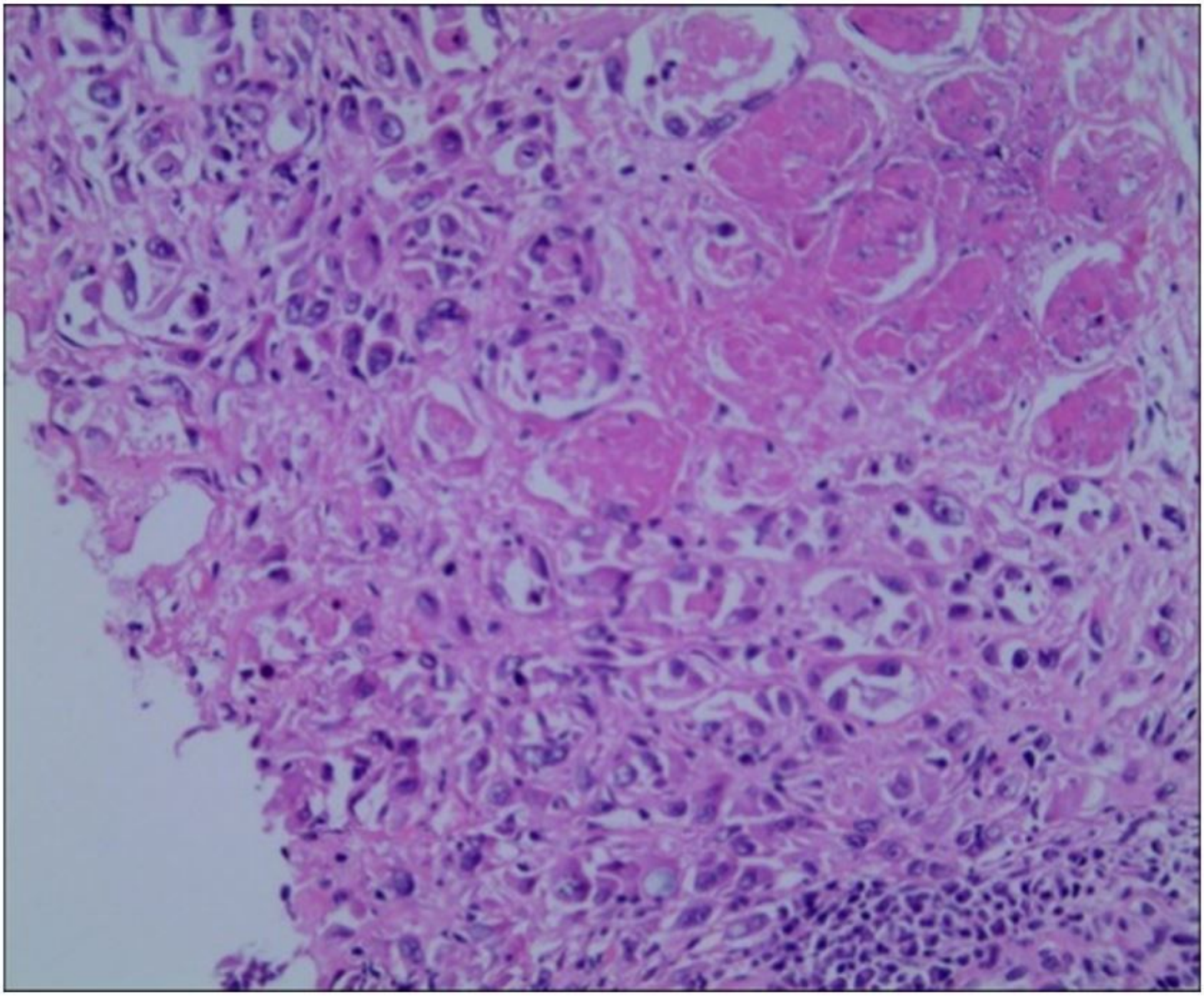

Figure 4

Pathological examination of right thigh tumor showed metastatic poorly differentiated carcinoma and invasion of striated muscle (HE staining, 200×).