The Difficulty of Severe Post-liposuction Infragluteal Deformity Correction by Autologous Fat Transplantation: A Case Report

Mingzi Yang
The 15th Department, Plastic Surgery Hospital, Chinese Academy of Medical Sciences and Peking Union Medical College

Yunpeng Gu
The 15th Department, Plastic Surgery Hospital, Chinese Academy of Medical Sciences and Peking Union Medical College

Jingjing Sun
The 15th Department, Plastic Surgery Hospital, Chinese Academy of Medical Sciences and Peking Union Medical College

Qianwen Lv
The 15th Department, Plastic Surgery Hospital, Chinese Academy of Medical Sciences and Peking Union Medical College

Yue Qi
The 15th Department, Plastic Surgery Hospital, Chinese Academy of Medical Sciences and Peking Union Medical College

Ji Jin
The 15th Department, Plastic Surgery Hospital, Chinese Academy of Medical Sciences and Peking Union Medical College

Zhenjun Liu
The 15th Department, Plastic Surgery Hospital, Chinese Academy of Medical Sciences and Peking Union Medical College

Zuoliang Qi
The 16th Department, Plastic Surgery Hospital, Chinese Academy of Medical Sciences and Peking Union Medical College

Guie Ma (Maguie15@163.com)
Plastic Surgery Hospital, Chinese Academy of Medical Sciences and Peking Union Medical College

---

Case report

Keywords: liposuction, fat transplantation, post-liposuction deformity

Posted Date: May 7th, 2021

DOI: https://doi.org/10.21203/rs.3.rs-466896/v1

Abstract

Background: Overaggressive liposuction of the infragluteal region can lead to iatrogenic infragluteal fold deformity and result in aesthetic defect of gluteal contour.

Case presentation: We report a case of using autologous fat transplantation to correct severe post-liposuction infragluteal fold deformity. In the process of reconstruction, the patient experienced fat graft over absorbed, fat graft translocation and gluteal ptosis aggravation. Despite multiple operations, the effect of fat transplantation is limit.

Conclusions: Severe post-liposuction infragluteal deformity is very difficult to correct. We suggest that the infragluteal region should be reserved as possible during liposuction to avoid deformity.

Background

Contour deformity is the most common complication of liposuction, with an incidence up to 20% [1–3]. The infragluteal fold is one of the key elements which determine the gluteal contour and recognized as an important characteristic of female beauty [4]. Overaggressive liposuction of the infragluteal region can lead to iatrogenic infragluteal fold deformity and result in aesthetic detraction of gluteal contour [5]. Severe infragluteal fold deformity can be difficult in correction. Here we present a case with iatrogenic deformity of the infragluteal fold region underwent multiple reconstructive surgeries for correction but the result was not quite satisfactory.

Case Presentation

A 37-year-old woman presented with infragluteal deformity after overaggressive gluteal and posterior thigh liposuction in a different institution. The deformity displayed at both side, including depression, multiple and asymmetric folds, and gluteal ptosis (Fig. 1). Correction options were discussed with the patient. While dermolipectomy or flap reconstruction was not acceptable, liposuction and fat transplantation were performed.

Surgical Technique

The patient was marked in the standing position. The donor sites of fat included flanks, abdomen and lateral thighs. The fat was aspirated by suction-assisted liposuction. Fat transplantation was performed at the completion of liposuction in the prone position. The incisions for fat transplantation were designed in the infragluteal folds invisibility whenever possible. The fat was injected through 1.2-2.0 mm cannulas as the cannula was withdrawn. After operation, the patient was instructed to avoid local pressure to the fat transplanted region for at least 3 months to prevent postoperative fat translocation.

Process of Reconstruction

A total of five reconstructive operations were performed. The fat transplantation region and volume of each operation is shown in Fig. 2. Four months after the 1st operation, the fat graft was almost entirely absorbed and little improvement of the deformity was seen (Fig. 3). Three months after the 2nd operation, the multiple infragluteal fold on the left side was slightly weakened. However, the fat graft downward translocated and led to a convexity deformity (Fig. 4). Three months after the 3rd operation, the gluteal contour on the lateral view was improved, and the convexity deformity caused by the 2nd operation was corrected. Nevertheless, the fat graft translocated to the lateral and distributed at the hip area (Fig. 5). Six months after the 4th operation, the multiple infragluteal fold was further improved to a small extent (Fig. 6). Finally, 8 months after the 5th operation, despite that the multiple and asymmetric folds were significant improved, the infragluteal crease lines were extend, and an appearance of severe gluteal ptosis presented (Fig. 7).

Summarily, after the 5 reconstructive surgeries, the depression deformity, multiple and asymmetric fold deformity were partially corrected but not quite satisfactory, and the gluteal ptosis was aggravated in appearance. In the process of reconstruction, the patient experienced fat graft over absorbed, fat graft translocation, infragluteal crease extension and gluteal ptosis aggravation. The outline of the reconstructive process is shown in Fig. 8.

Discussion And Conclusions

According to previous reports, the correction of post-liposuction infragluteal fold deformity mainly depends on flap reconstruction, liposhifting and autologous fat transplantation [5–8]. Flap reconstruction is efficient in severe cases of infragluteal fold deformity [5], but the low patient's acceptance of sequel scar limits its application. Liposhifting is a technique which free the subcutaneous fat by stab incisions and cannulas and shift the surrounding fat to correct depression deformities without liposuction or fat injection [6]. However, this procedure may be insufficient to correct large deformities with severe adherence. In regard to the case we presented, fat transplantation was considered as the optimal option for refusing flap reconstruction. However, the result was still not quite satisfactory after multiple operations.

As far as we are concerned, the difficulty in correction of the post-liposuction infragluteal deformity may mainly relate to the subcutaneous scar. In anatomically, the infragluteal fold region is described as an adherence zone, in which the superficial fascia tissue fuse and firmly adherent to the deep gluteal fascia at the lack of deep layer fat [9, 10]. This is critically important in formation of the infragluteal fold and caudal gluteal border [10]. While in the case of overaggressive liposuction, the superficial fascia is almost substituted by scar tissue and the dense fibrous attachment to underlying deep fascia is broken [11]. The fat graft is difficult to be filled and survival into scar tissue, thus the volume maintain is hard to predict. This would result in the inefficient of fat transplantation. Moreover, for the loss of attachment between scar and deep fascia, the transplanted fat would hardly contact to the adjacent healthy tissue. Inevitably, the fat graft is prone to translocation, for instance downward and lateral translocation presented in our patient, even if avoid local pressure to the transplantation region as possible after operation. Therefore,

the effect of fat transplantation in the correction of severe post-liposuction infragluteal deformity is limited.

Expect for the multiple infragluteal folds, the correction of gluteal ptosis after overaggressive liposuction could be more difficult. The post-liposuction gluteal ptosis may be associated with the destruction of conjunctive fibrous which sustaining the buttocks, and the subsequent skin laxity by soft tissue volume reduction [11]. Generally, the evaluation of gluteal ptosis is determined by the length of infragluteal crease and the amount of sagging tissue passing over the infragluteal fold [4, 12–13]. In the respect of our patient, after the 5th fat transplantation, although the soft tissue volume of infragluteal region was supplemented, without intact sustaining structures, the increased volume and redundant skin sagged and the infragluteal crease were extend. As a result, the gluteal ptosis was aggravated. Therefore, we recognize that fat transplantation is problematic in improving sever post-liposuction gluteal ptosis.

In conclusion, the post-liposuction infragluteal deformity is very difficult to correct. It is important to recognize that the subcutaneous scar formation, conjunctive fibrous destruction and soft tissue volume reduction after liposuction may result in infragluteal deformity; and the effect of fat transplantation is limit while dealing with serve deformity. In our opinion, the infragluteal region should be reserved as possible during liposuction to avoid deformity.

Declarations

Ethics approval and consent to participate

All procedures performed in studies involving human participants were in accordance with the ethical standards of the institutional and/or national research committee and with the 1964 Helsinki declaration and its later amendments or comparable ethical standards. For this type of study formal consent is not required.

Consent for publication

Informed consent was obtained from the patient included in the study.

Availability of data and materials

All data generated or analysed during this study are included in this published article.

Competing interests

The authors declare that they have no competing interests.

Funding

This work was supported by the Medical and Health Science Innovation Project of the Chinese Academy of Medical Sciences (Medical Big Data Information Collection and Analysis Evaluation, Fund No. 2016-

12M-2-004).

Authors' contributions

Gui-e Ma, Mingzi Yang and Yunpeng Gu designed this study. Mingzi Yang and Yunpeng Gu completed the article. Jingjing Sun, Qianwen Lv, Yue Qi, Ji Jin and Zhenjun Liu helped to collect data for this study. Zuoliang Qi and Gui-e Ma revised the article. Mingzi Yang and Yunpeng Gu have contributed equally to this work and should be regarded as co-first authors.

Acknowledgements: Not applicable.

References

1. Ca´rdenas-Camarena L. Lipoaspiration and its complications: a safe operation. Plast Reconstr Surg. 2003;112:1435-1441.
2. Wu S, Coombs DM, Gurunian R. Liposuction: Concepts, safety, and techniques in body-contouring surgery. Cleve Clin J Med. 2020;87:367-375.
3. Stephan PJ, Kenkel JM. Updates and advances in liposuction. Aesthet Surg J 2010;30(1):83-97.
4. Mendieta CG, Sood A. Classification System for Gluteal Evaluation: Revisited. Clin Plast Surg. 2018;45:159-177.
5. Seles M, Huemer GM. Utilization of bilateral infragluteal flaps for correction of overaggressive gluteal liposuction. Ann Plast Surg. 2014;72:270-273.
6. Saylan Z. Liposhifting instead of lipofilling: treatment of postlipoplasty irregularities. Aesthet Surg J. 2001;21:137-141.
7. Pereira LH, Nicaretta B, Sterodimas A. Correction of liposuction sequelae by autologous fat transplantation. Aesthetic Plast Surg. 2011;35:1000-1008.
8. Pereira LH, Sterodimas A. Correction for the iatrogenic form of banana fold and sensuous triangle deformity. Aesthetic Plast Surg. 2008;32:923-927.
9. Almutairi K, Gusenoff JA, Rubin JP. Body Contouring. Plast Reconstr Surg. 2016;137:586e-602e.
10. Da Rocha RP. Surgical anatomy of the gluteal region's subcutaneous screen and its use in plastic surgery. Aesthetic Plast Surg. 2001;25:140-144.
11. Centeno RF, Young VL. Clinical anatomy in aesthetic gluteal body contouring surgery. Clin Plast Surg. 2006;33:347-358.
12. Gonzalez R. Etiology, definition, and classification of gluteal ptosis. Aesthetic Plast Surg. 2006;30:320-326.
13. Oh CH, Jang SB, Kang CM, Shim JS. Buttock Lifting Using Elastic Thread (Elasticum(®)) with a New Classification of Gluteal Ptosis. Aesthetic Plast Surg. 2018;42:1050-1058.

Figures

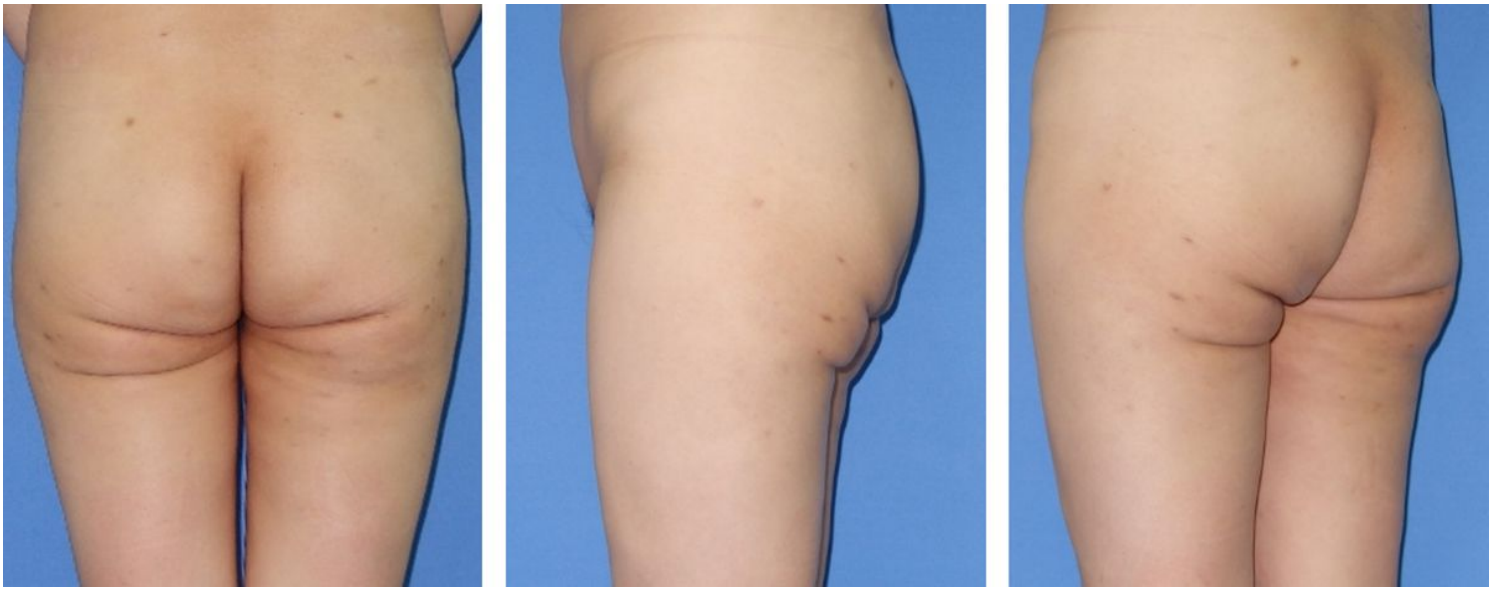

Figure 1

Pre-reconstruction view of the 37-year-old woman with iatrogenic infragluteal deformity.

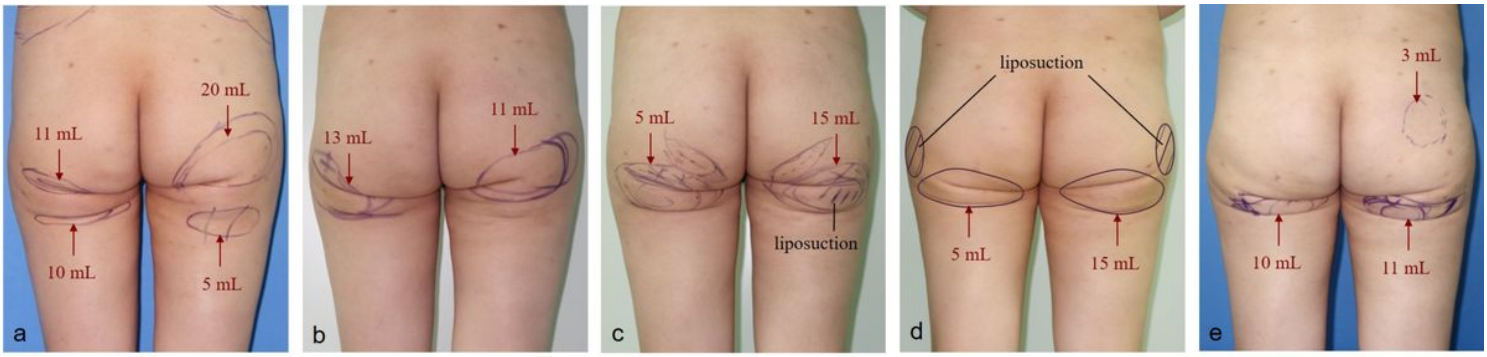

Figure 2

Fat transplantation region and volume of each reconstructive operation. a. The 1st operation. b. The 2nd operation. c. The 3rd operation. d. The 4th operation. e. The 5th operation.

Figure 3

Postoperative view of the patient 4 months after the 1st reconstructive operation. Little improvement was seen of the deformity.

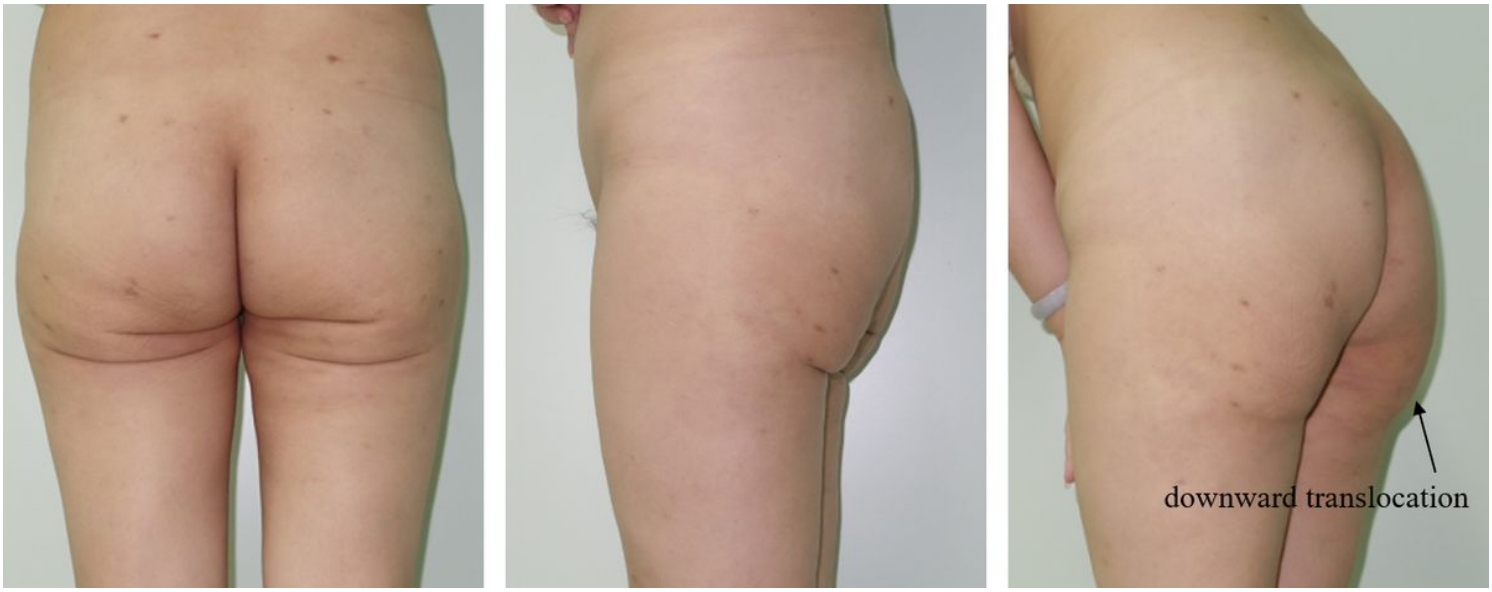

Figure 4

Postoperative view of the patient 3 months after the 2nd reconstructive operation. The multiple infragluteal fold on the left side was slightly weakened. The arrow indicates that the downward translocation of fat and the convexity deformity.

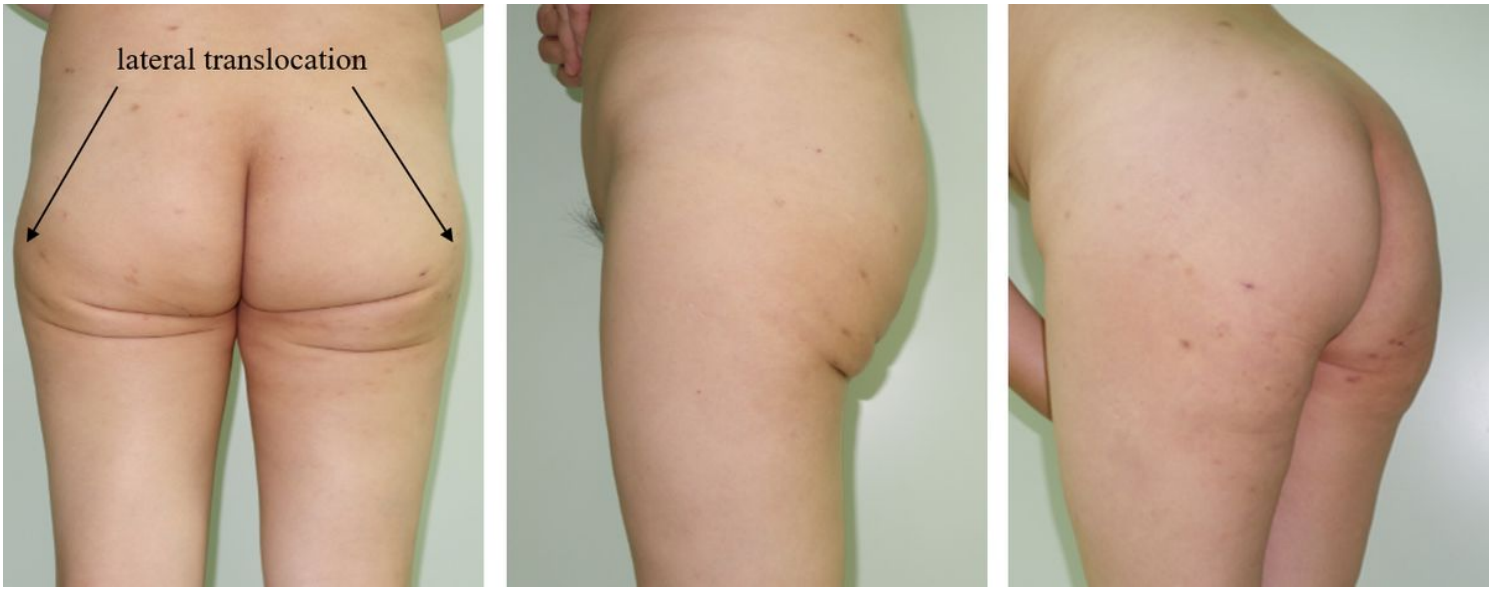

Figure 5

Postoperative view of the patient 3 months after the 3rd reconstructive operation. The gluteal contour was improved and the convexity deformity caused by fat downward translocation was corrected. The arrow indicates the lateral translocation of fat.

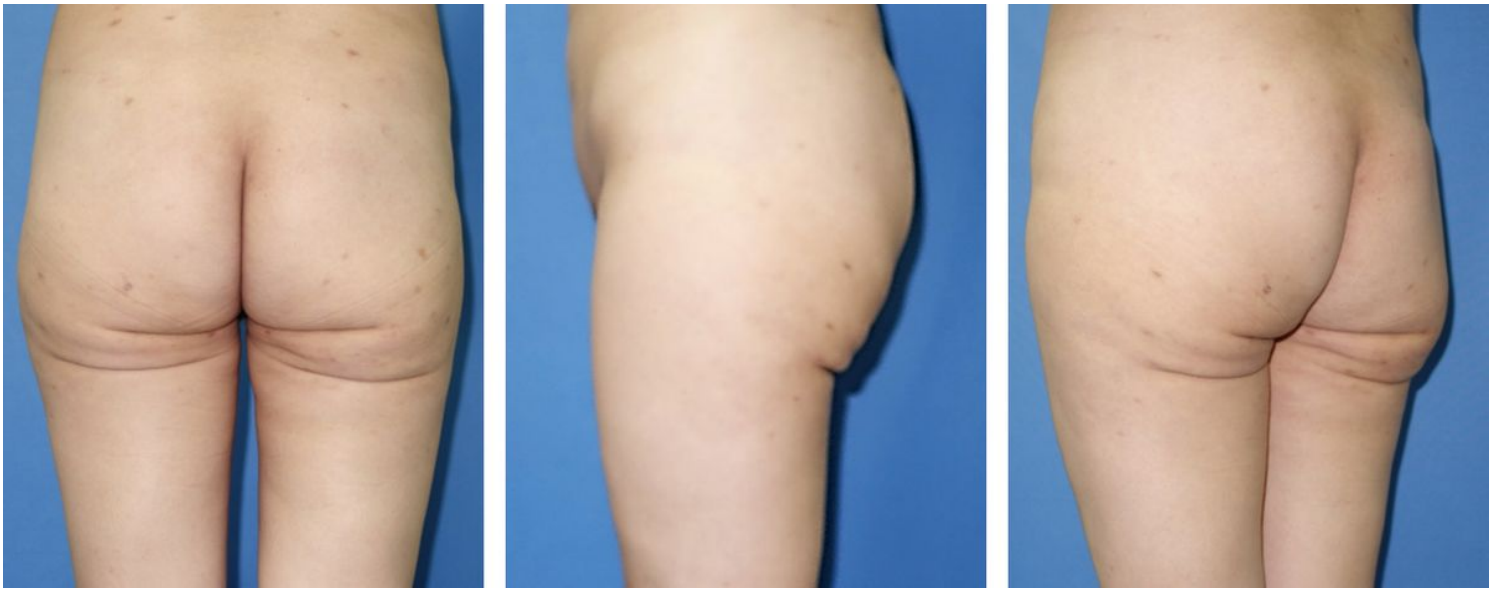

Figure 6

Postoperative view of the patient 6 months after the 4th reconstructive operation. The multiple infragluteal fold was further improved to a small extent.

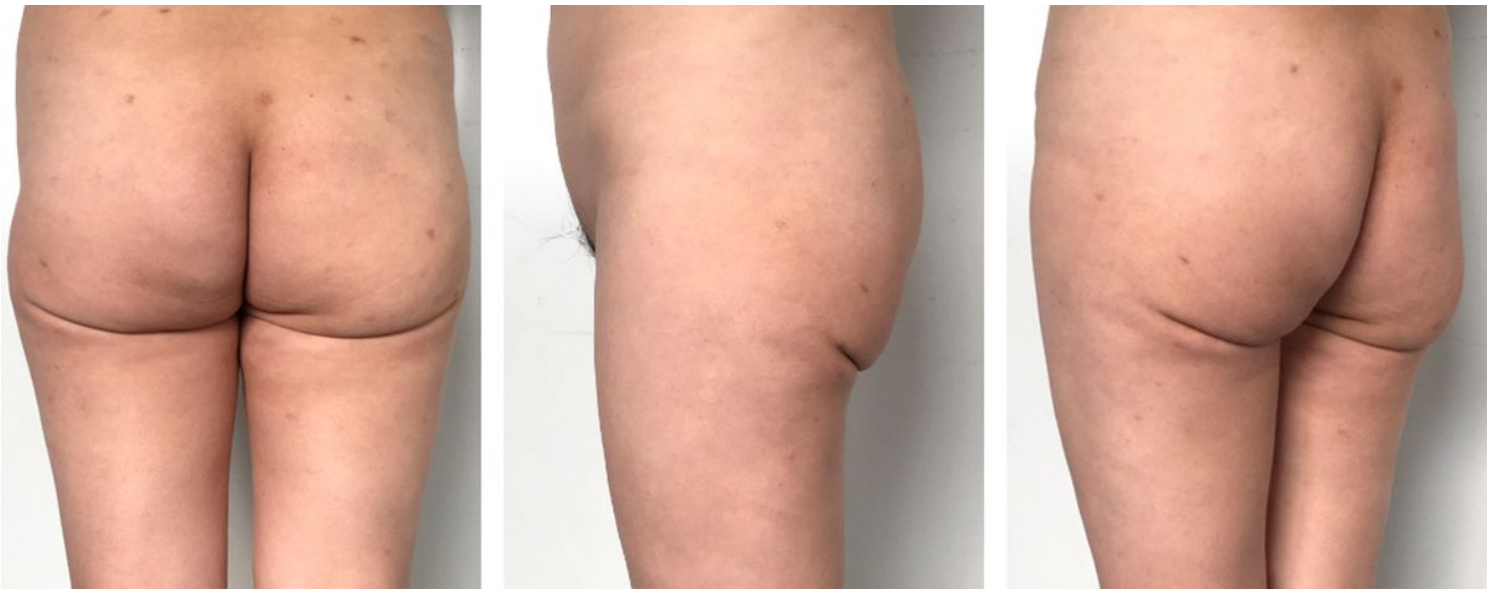

Figure 7

Postoperative view of the patient 8 months after the 5th reconstructive operation. The multiple and asymmetric folds were significant improved. The infragluteal crease lines were extend and the gluteal ptosis was aggravated in appearance.

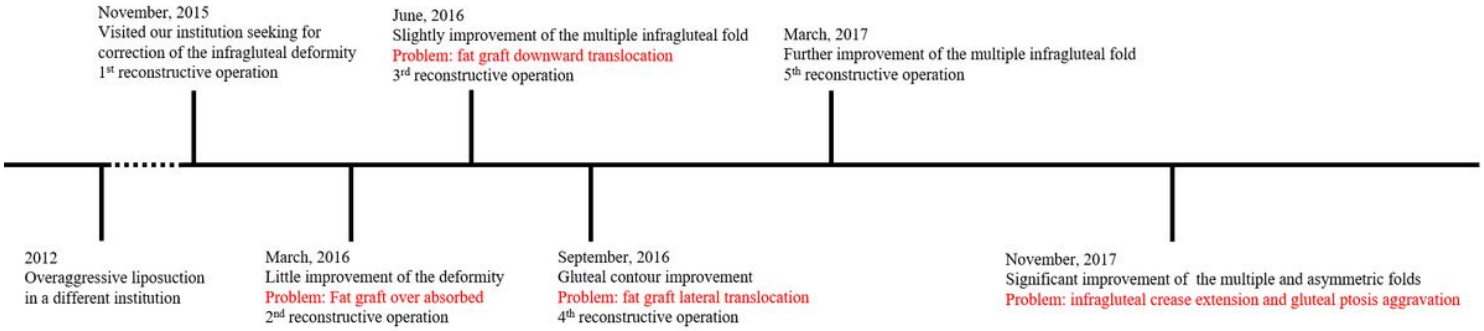

Figure 8

The outline of the reconstructive process.