The correlation study on mandibular deviation and cervical vertebrae posture in patients with mandibular asymmetry

Yuxin Guan
Shanxi Medical University
Pengfei Tian
Shanxi Medical University
Bing Li
Shanxi Medical University School and Hospital of Stomatology
Xiuping Wu (gyx3698g@163.com)
Shanxi Medical University School and Hospital of Stomatology

Research Article

Keywords: Mandibular deviation, Cervical vertebrae posture, CBCT

Posted Date: May 5th, 2021

DOI: https://doi.org/10.21203/rs.3.rs-467365/v1

Title page

The correlation study on mandibular deviation and cervical vertebrae posture in patients with mandibular asymmetry

Yuxin Guan[1], Pengfei Tian[1], Bing Li[2] and Xiuping Wu[2*]

[1] Department of Orthodontics, School of Dentistry, Shanxi Medical University, Taiyuan, China.
[2] Department of Orthodontics, Shanxi Medical University School and Hospital of Stomatology, Taiyuan, China.

[*]Correspondence: gyx3698g@163.com
[2] Department of Orthodontics, Shanxi Medical University School and Hospital of Stomatology, Taiyuan, China.

The correlation study on mandibular deviation and cervical vertebrae posture in patients with mandibular asymmetry

Yuxin Guan[1], Pengfei Tian[1], Bing Li[2] and Xiuping Wu[2]

Abstract

Background: To explore the degree of skeletal mandibular deviation and the change of mandible position in patients with mandibular deformity and its correlation with cervical posture in patients with jaw deformity using CBCT and to provide the reference for clinical diagnosis and treatment planning.

Methods: CBCT images from 30 adult patients with skeletal mandibular deviation and 30 adult

---

[*]Correspondence: gyx3698g@163.com
[2]Department of Orthodontics, Shanxi Medical University School and Hospital of Stomatology, Taiyuan, China
[*]Correspondence: gyx3698g@163.com
[2]Department of Orthodontics, Shanxi Medical University School and Hospital of Stomatology, Taiyuan, China

individuals with facial symmetry were analyzed and imported in Invivo 5 to reconstruct a 3D hard-tissue surface model. A reference frame was set up and 20 measurements of the mandible and cervical vertebrae were performed to calculated. The difference between the three-dimensional position of the mandible and the posture of cervical spine were analyzed in patients with mandibular asymmetry and normal people.

Results: Compared with the normal maxillofacial symmetry groups, there were significant differences in the degree of skeletal mandibular asymmetry and cervical deviation in the mandibular deviation groups($P < 0.05$). A strong positive, linear correlation was found in patients with mandibular deviation between the deviation of the mandible and cervical vertebrae posture.

Conclusion: There is an inherent correlation between the occurrence of mandibular deviation and the deflection of cervical posture, and they interact on each other. The deformity of mandible affects the three-dimensional posture of the cervical vertebra and can cause different degrees of cervical deflection. The degree of mandible deviation and cervical vertebrae posture in patients with mandibular asymmetry are greater than those in individuals with facial symmetry. Compared with the patients with normal jaw, the deformity among the patients with skeletal mandibular asymmetry has a tendency to tilt forward and bend forward. The abnormal posture of the cervical spine will also affect the three-dimensional position of the mandible, causing the lower 1/3 of the face to appear facial asymmetry with the deflection of the head and neck posture.

Keywords: Mandibular deviation, Cervical vertebrae posture, CBCT

Background

The pursuit of facial esthetics has become the main motivation for many patients to seek orthodontic treatment. Facial symmetry is deemed to be one of the most important features of facial esthetics [1]. Recently, more and more patients come to see the doctor due to mandibular deviation. The mandibular deviation not only affects the facial appearance, but also leads to occlusal interferences, which then causes temporomandibular disorders, and even causes neck pain and other symptoms [2, 3]. Previous studies have shown that in the clinical examination of mandibular deformity, asymmetric mandible structure shows such important characteristics as varying degrees of facial asymmetry structure, temporomandibular joint disorder, bilateral masticatory muscle balance disorders as well as abnormal head–neck posture [4]. This can result in patients with mandibular asymmetry suffer from such signs and symptoms as head, neck, shoulder and upper back pain, and

even causes unbalanced trunk muscle strength, which is well established in the literature [5]. The results of the previous studies have confirmed that such patients were often accompanied by abnormal morphology of cervical vertebrae, head, neck, shoulder and back muscle pain, myotonia and other symptoms [3, 6-8]. Therefore, the aim of this study was to investigate the correlation between mandibular deviation and cervical vertebrae posture using CBCT, which would provide reference for clinical diagnosis and treatment planning.

Methods

Subjects and Measurements

From 2017 to 2019, 30 adult subjects (thirteen males and seventeen females, aged 18 to 40 years; mean age, 22 years) only with skeletal mandibular deviation were consecutively recruited in mandibular deviation group. Inclusion criteria were as follows: the mandible was defined as having lateral jaw deformity when the vertical distance from the chin ridge to the craniofacial midline exceeded 2 mm [9, 10]. All patients with no history of orthodontic treatment exhibited clinically recognizable unilateral mandibular and the midline of upper and lower jaw was not consistent. Additionally, participants with maxillofacial deformity, surgical history, orthodontic history, systemic genetic disease, condylar hypertrophy, tumor history, trauma and infection history were excluded from the study.

30 healthy volunteers (16 men, 14 women; age 18 to 31 years) were participated to form the facial symmetry group, who were no mandibular asymmetry with a menton deviation less than 2 mm and no obvious facial deformity, while having a complete dentition and a normal relationship of overbite and overjet. Midline of upper dentition was coincident with down dentition. patients gave verbal and written consent for the publication of these results. The samples′ demographic characteristics are presented (Table 1).

All subjects were scanned by the same CBCT (KAVO 3D eXam Vision) with standard regulation of 120 kV, 5 mA, field of view 17cm×13cm, 0.250 mm resolution, and the 7-second scan. The CBCT scans with a wide field of view covering nasion to menton, and a slice thickness of 1 mm or less, were retrieved from the database. The CBCT scans were made with each subject sitting in a vertical position, with Frankfort horizontal plane parallel to the ground and the midsagittal plane perpendicular to it.

In order to ensure the reliability of image data, CBCT image collection of all subjects was completed by the same roentgenologist with rich experience. The CBCT data in digital imaging and communication in medicine (DICOM) format was imported to Invivo 5（Anatomage, San Jose, USA）to reconstructed into 3D images. A three-dimensional reference plane was established (Figure 1). Eighteen landmarks and twenty measurements were identified in order to evaluate degrees of mandibular and cervical vertebra deviation (Table 2-4 and Figure 2,3).

Statistical analysis

All data were implemented with GraphPad Prism 5(USA， GraphPad Software) for statistical analysis. Descriptive statistics were carried out for all studied variables. Data normality was assessed by means of the Shapiro-Wilk normality test. The mean and standard deviation of the linear measurements of mandibular asymmetry analysis were generated， with a level of significance set at $P<0.05$. An independent-sample t-test was performed to compare the linear measurements of mandibular deviation group and facial symmetry group. For mandibular deviation group, differences were calculated by subtracting the linear measurements on the deviated side from the contralateral side of mandible. For facial symmetry group, differences were defined as right side minus left side. Pearson Correlation analysis was carried out to investigate the relationships between menton deviation and cervical vertebra posture.

Results

Symmetry analysis of mandible position

Results analysis of normal facial symmetry groups: (1) The degree of chin deflection were less than 2mm, with an average of 0.73±0.52mm. (2) There were no statistical difference in the distance between CoR and CoL to MSP, MHP and CP ($P>0.05$). (3) There were no statistical difference in the distance between GoR and GoL to MSP, MHP and CP ($P>0.05$). In the normal facial symmetry groups, the results of the distance of the mandible to MSP, MHP and CP showed that the position of condylar, mandibular ramus and mandibular body on both sides have a high degree of symmetry in three-dimensional direction. It indicates that the left and right sides of the mandible in normal adults were symmetrical (Table 5).

Results analysis of mandibular deviation groups: (1)The degree of chin deflection were more

than 2mm, with an average of 3.87±1.73mm. Compared with facial symmetry groups, there were statistical difference. (2) There were statistical difference in the distance between CoR and CoL to MSP, MHP and CP ($P<0.05$) and the affected side were greater than the healthy. (3) There were statistical difference in the distance between GoR and GoL to MSP, MHP and CP ($P<0.05$) and the affected side were greater than the healthy. In the mandibular deviation groups, the results of the distance of the mandible to MSP, MHP and CP showed that the position of condylar, mandibular ramus and mandibular body on both sides were significantly different in three-dimensional direction. The displacement of the mandible was backward, upward and outward to the affected side and forward, downward and inward toward the healthy side, resulting in the deviation of the mandible relative to the middle of the craniofacial surface and showing asymmetrical on the left and right sides (Table 6-8).

Changes in the cervical posture

There were significant differences in the degree of cervical deflection, tilt and curvature in the mandibular deviation groups compared with facial symmetry groups ($P<0.05$). The degrees of the second, third and fourth cervical vertebrae deviation in the mandibular deviation groups were greater than those in the facial symmetry groups. While the degrees of the second, third and fourth cervical vertebrae inclination in the mandibular deviation groups were lower than those in the facial symmetry groups. It indicated that the cervical vertebrae in patients with jaw deflection had a tendency to tilt forward. And the degrees of the second, third and fourth cervical vertebrae curvature in the mandibular deviation groups were significantly higher than those in the facial symmetry groups. It suggested that the cervical vertebrae in patients with mandibular deviation had a tendency to bend forward (Table 7).

Correlation between mandibular deviation and cervical posture

There was a certain correlation between the degree of mandibular deviation and the degree of cervical vertebrae deflection, forward inclination and anterior curvature. With the increase of the chin deviation, the cervical vertebrae deflection, tilt and curvature also showed a significant increase trend (Table 9 and Figure 4-6).

Discussion

The position of the mandible is deflective relative to the middle od the face and the morphology of both sides of the mandible is asymmetrical, which is called mandibular deviation. It is a kind of facial symmetrical deformity commonly seen in clinical practice, which mainly involves the lower part of the face and dental arches. While the middle and upper 1/3 of the face were less affected by mandibular deflection, which was mainly manifested as horizontal and vertical asymmetry [9]. The mandibular deviation will not only cause malocclusion, but even cause the imbalance of the muscle force between the head, neck and shoulder muscle groups, leading to the facial symmetry deformity and resulting in the deviation of posture, and seriously destroy the balance of the function of the oral and maxillary system and the aesthetic appearance [10,11]. This study focused on the comprehensive evaluation of the changes in cranial and maxillofacial and neck anatomical structures of patients with mandibular deformity from the three-dimensional direction, and explored the correlation between the degree of mandibular deviation and the degree of cervical skewness, as well as the degree of forward tilt and anterior curvature.

Considerations for the selection of research objects in this experiment

1.Ages: the reason for choosing adult patients is that a large number of scholars have confirmed that the degree of mandibular deviation in patients with facial asymmetry deformity will become more serious with the increase of age. The degree of mandibular deformity will not be stable until the mandibular bone growth and development is completed and approaching adulthood [12]. In addition, some studies have shown that in patients with mandibular deviation, the abnormal facial muscle function of children is less, and the asymmetry of bilateral muscle movement is better than that of adults [13]. Therefore, the selection of adult patients with more obvious manifestation of mandibular deviation is conducive to the study. 2.Gender: previous studies have shown that there is no gender difference in the muscle strength of cranio-maxillofacial muscle groups [14]. 3.Mandibular deflection type: In this study, patients with skeletal jaw deviation were selected for the study. Due to a certain compensatory mechanism in the body, soft tissue will cover up the asymmetry of the mandible to some extent so that the deflection is not obvious [15]. Moreover, the pathogenesis of

facial deviation in patients with dental and functional jaw deviation is quite different from that in patients with skeletal jaw deviation. If it is included in the study, the experimental results will be biased and the credibility of the results will be affected. To sum up, it is an important step for the success of this study to accurately screen out patients with skeletal mandibular deviation that meet the research criteria from patients with mandibular deviation.

Characteristics of three-dimensional mandibular position in patients with deflection

In the past, it was widely believed that the significant differences in the morphological development of the left and right condylar neck and mandibular ramus in adult patients with mandibular deviation were the main pathogenesis causing mandibular deviation and facial asymmetrical deformity [16,17]. However, the previous studies on the deflection deformity mainly focused on the change of the three-dimensional shape of the mandible, less attention was paid to the change of the position of the mandible. In addition, previous morphological studies on patients with mandible deviation showed that there was no significant morphological change in the mandible of adult patients with mandible deviation [18,19]. Therefore, this study mainly measured the changes of mandible position to explore the three-dimensional characteristics of mandible in patients with jaw deformity. The results of the measurements of the three-dimensional position of condyle and mandibular ramus in patients with mandibular deviation showed that in adult patients with mandibular asymmetry, the left and right sides of the mandible were asymmetrical, and the spatial position of the mandible changed, and the displacement of condyle process was more obvious, which was manifested as backward, upward and outward displacement to the affected side, and forward, downward and inward displacement to the healthy side. Some scholars also confirmed that the balance of occlusion on both sides was closely related to the symmetry of condyle morphology and position on the left and right sides. The occurrence of mandibular deviation would lead to the reconstruction of condyle, and the function of oral and maxillary system could be coordinated by changing its morphology and position in the articular fossa [20]. This was consistent with our experimental results. The reason for this result might be that the occlusal function of patients with mandibular deviation was often accompanied by abnormality, which in turn affects the remodeling of temporomandibular joint [21,22]. Due to the existence of occlusal abnormality, different muscle forces are exerted on the condylar both on the affected side and the uninjured side during the functional movement of the

mandible, leading to adaptive reconstruction and joint adaptive displacement of the temporomandibular joint, especially on the surface of the condyle, in order to maintain the stability of the oral and maxillary system function [23,24].

Characteristics of cervical postures in patients with mandibular deviation

The results of this experiment showed that the three-dimensional postures of the cervical vertebrae in adult patients with mandibular deviation were abnormal compared with those in normal adults. The degree of the upper cervical spine deviation increased in turn, and showed a trend of forward tilt and forward bending. At present, the mechanism of head and neck posture deviation caused by mandible deviation is not yet clear. The stability of head and neck position depends on the joint maintenance of muscles and ligaments attached to both sides and the cervical spine and on the balance and coordination of the interaction between these anatomical structures [25,26]. Previous studies have suggested that the disorder of muscle function was closely related to the maxillofacial development and malocclusion [27,28]. Therefore, it is speculated that the long-term mandibular deviation may cause abnormal muscle regulation function of the maxillofacial muscles attached to the mandible, especially the masticatory muscles that maintain the posture of the mandible and participate in the movement of the mandible, thus leading to muscle imbalance [29-30]. There is a close relationship between the cervical muscles and the masticatory muscles. And they are connected as a whole through the postural muscle chain. Therefore, when chewing is abnormal, the muscles around the neck will also be affected, even involving the muscles on both sides of the trunk to maintain body balance. Long-term muscle imbalance will lead to changes in the physiological curvature of the cervical vertebra, and then the tilt of the head and neck posture to adapt to the deviation of mandible, which will eventually lead to the imbalance of the body posture [31-33]. In conclusion, there is a close relationship between masticatory muscles and cervical muscles, and masticatory system disorders and cervical spine dysfunction are often associated with each other.

To test the hypothesis, in future experiments, we will use EMG to further study the symmetry and coordination changes of head, neck and shoulder muscles during mandibular postural position and mandibular functional movement in patients with deviation so as to provide a clearer understanding of the internal relationship between mandibular deviation and the anatomical structure of the neck, and clarify the pathogenesis of mandibular deviation.

Conclusion

This study demonstrates the occurrence of mandibular deviation deformity is intrinsically related to the abnormality of cervical posture, and they influence each other. The mandibular deformity affects the three-dimensional posture of the cervical vertebra and can cause different degrees of cervical deflection. The degree of mandible deviation and cervical vertebrae posture in patients with mandibular asymmetry are greater than those in individuals with facial symmetry. And posture changes of patient's cervical vertebra were in the forward and flexion position compared with individuals with facial symmetry.

Table 1. Demographic characteristics of the sample

Table 2. Description of points used in this study.

Table 3. Planes in three-dimensional cephalometric analysis.

Table 4. Measurements in three-dimensional cephalometric analysis.

Table 5. Analysis of symmetry of the mandibular position in facial symmetry groups(mm)

Table 6. Analysis of symmetry of the mandibular position in mandibular deviation groups(mm)

Table 7. Comparison of the degree of mandible and cervical vertebra deviation between mandibular deviation groups and facial symmetry groups

Table 8. Comparison of mandibular position symmetry between mandibular deviation groups and facial symmetry groups(mm)

Table 9. Correlation between the mandibular deviation and cervical posture

Figure 1. A three-dimensional reference plane was established. HP: Horizontal plane was constructed as the plane through left orbital (OrL), right orbital (OrR) and right potion (PoR); MSP: Median sagittal plane was designed as the plane through nasion (N) and basion (Ba) and perpendicular to horizontal plane; CP: Perpendicular to horizontal plane and median sagittal plane, Coronal plane was through nasion (N).

Figure 2. Mandibular measure items (a) in coronal plane (b) in median sagittal plane a, b, the degree of deviation of the left and right mandibular angles from the median sagittal plane, GoL-MSP/ GoR-MSP; c, d, the degree of deviation of the left and right mandibular angles from the menton horizontal plane, GoL-MHP/ GoR-MHP; e, the degree of deviation of the chin, Me-MSP; f, the degree of deviation of the right condylar from the median sagittal plane, CoR-MSP; g, the degree of deviation of the right condylar from the menton horizontal plane, CoR-MHP;

Figure 3. Cervical vertebra measure items (a) in coronal plane (b) in median sagittal plane a, the degree of deviation of the 2th, 3th, 4th cervical vertebra from the median sagittal plane, C2-MSP, C3-MSP, C4-MSP; b, Angle measurements. (1) Cervical inclination: the crossing angle between Cp and HP, Cp-HP; (2) Cervical curvature: The crossing angle between CSP and OPP, CSP-OPP.

Figure 4. The correlation between menton deviation and 2nd cervical vertebra deviation.

Figure 5. The correlation between menton deviation and 3nd cervical vertebra deviation.

Figure 6. The correlation between menton deviation and 4nd cervical vertebra deviation.

Abbreviations

CBCT: Cone beam computed tomography;

DICOM: Digital Imaging and Communications in Medicine;

Acknowledgments

Not applicable.

Authors' contributions

Yuxin G collect data, perform experiment and draft the manuscript. Pengfei T participate in experimental design. Xiuping W and Bing L give the experimental guidance and guide to correct the manuscript. All authors read and approved the final manuscript.

Funding

This study was supported by grant from Key research and development project of Shanxi Province.

Availability of data and materials

The datasets used and/or analyzed during the current study are available from the corresponding author on reasonable request.

Ethics approval and consent to participate

This retrospective study was approved by the Ethics in Research Committee of Dental School, University of Shanxi Medical University, Taiyuan, China. Informed consent was obtained from all subjects. All methods were carried out in accordance with relevant guidelines and regulations.

Consent for publication

Not applicable.

Competing interests

The authors declare that there is not any conflict of interest.

Author details

[1] Department of Orthodontics, School of Dentistry, Shanxi Medical University, Taiyuan, China.
[2] Department of Orthodontics, Shanxi Medical University School and Hospital of Stomatology, Taiyuan, China.

References

1. Kim H J, Hong M, Daegu H, Korea. Analysis of dental compensation in patients with facial asymmetry using cone-beam computed tomography. American Journal of Orthodontics and Dentofacial Orthopedics. 2019;156(4):493-501.

2. Ben-Bassat Y, Yitschaky M, Kaplan L, Brin I. Occlusal patterns in patients with idiopat hic scoliosis. American Journal of Orthodontics & Dentofacial Orthopedics. 2006;130(5):62 9-633.

3. Oguri Y, Yamada K, Fukui T, Hanada K, Kohno S. Mandibular movement and frontal craniofacial morphology in orthognathic surgery patients with mandibular deviation and pro trusion. Journal of Oral Rehabilitation. 2010;30(4):392-400.

4. Perinetti G, Contardo L, Biasati AS, Perdoni L, Castaldo A. Dental malocclusion and body posture in young subjects: A multiple regression study. Clinics. 2010;65(7).

5. Festa F, Tecco s. Cervical spine curvature and craniofacial morphology in an adult Cau casian group: a multiple regression analysis. European Journal of Orthodontics. 2007;29(2): 204-9.

6. Thiesen G, Gribel BF, Freitas MPM, Oliver DR, Kim KB. Mandibular asymmetries and associated factors in orthodontic and orthognathic surgery patients. The Angle Orthodontist. 2018:111517-785.1.

7. Gateno J, D Alfi, Xia JJ, Teichgraeber JF. A Geometric Classification of Jaw Deformities. Journal of Oral & Maxillofacial Surgery Official Journal of the American Association of Oral & Maxillofacial Surgeons. 2015;73(12):S26-S31.

8. Economou, Stalo, Stoustrup, Peter, Kristensen, Kasper, et al. Evaluation of facial asymmetry in patients with juvenile idiopathic arthritis: Correlation between hard tissue and soft tissue landmarks. American Journal of Orthodontics & Dentofacial Orthopedics. 2018;153(5):662.

9. Chung KR, Kim SH, Choo HR, Kook YA, Cope JB. Distalization of the mandibular dentition with mini-implants to correct a Class III malocclusion with a midline deviation. Am J Orthod Dentofacial Orthop. 2010;137(1):135-146.

10. Cao HL, Kang MH, Lee JY, Park WJ, Choung PH. Quantification of three-dimensional facial asymmetry for diagnosis and postoperative evaluation of orthognathic surgery. Maxillofacial Plastic and Reconstructive Surgery. 2020;42(1):17.

11.Hideki K, Norihisa H, Hiroki F, Shiga M, Kawamoto T, Moriyama K. Comprehending the three-

dimensional mandibular morphology of facial asymmetry patients with mandibular prognathism. Progress in orthodontics. 2017;18(1):43.

12. Song G, Zong X, Guo X, Zhao J, Jin X. Single-Stage Mandibular Curved Ostectomy on Affected Side Combined with Bilateral Outer Cortex Grinding for Correction of Facial Asymmetry: Indications and Outcomes. Aesthetic Plastic Surgery. 2019;43(3):733-741.

13.Choi JW, Lee JY. Clinical Application of the Surgery-First Approach to Facial Asymmetry[M]// The Surgery-First Orthognathic Approach. 2021.

14.Gateno J, Alfi D, Xia JJ, Teichgraeber JF. A Geometric Classification of Jaw Deformities. Journal of Oral & Maxillofacial Surgery Official Journal of the American Association of Oral & Maxillofacial Surgeons. 2015;73(12): S26-S31.

16.Kwon, Tae-Geon. Three-dimensional surgical simulation for facial asymmetry: soft tissue-, skeleton-, and occlusion-based planning. Maxillofacial Plastic & Reconstructive Surgery. 2017; 39(1):36.

17.Thiesen G, Guilherme BF, Freitas MPM, Oliver DR, Kim KB. Mandibular asymmetries and associated factors in orthodontic and orthognathic surgery patients. Angle Orthodontist. 2018;88:545-551.

18.Thiesen G, Gribel BF, Freitas MPM, Oliver DR, Kim KB. Craniofacial features affecting mandibular asymmetries in skeletal Class II patients. Journal of Orofacial Orthopedics-fortschritte Der Kieferorthopadie. 2017;78(5):437-445.

19. Xie, Qianyang, Shen, Yuqing, Yang, Chi, et al. Will unilateral temporomandibular joint anterior disc displacement in teenagers lead to asymmetry of condyle and mandible? A longitudinal study. J Craniomaxillofac Surg. 2016;44(5):590-6.

20. Msd SMKD, Msd HBD, Msd HDJD, et al. Diagnosis and Surgical Outcomes of Facial Asymmetry According to the Occlusal Cant and Menton Deviation. Journal of Oral and Maxillofacial Surgery. 2019;77(6):1261-1275.

21. Dalla CCC, Da SBL, Mariana M. Influence of occlusal plane inclination and mandibular deviation on esthetics. Dental Press Journal of Orthodontics. 2015;20(5):50-57.

22. Ikeda M, Miyamoto JJ, Takada JI, Moriyama K. Association between 3-dimensional mandibular morphology and condylar movement in subjects with mandibular asymmetry. Am J Orthod Dentofacial Orthop. 2017;151(2):324-334.

23. Widmalm SE, Dong Y, Li B, Lin M, Deng S. Unbalanced lateral mandibular deviation associated with TMJ sound as a sign in TMJ disc dysfunction diagnosis. Journal of Oral Rehabilitation. 2016;43(12):911-920.

24. Liu S, Zhen ZJ, Zhao R, Zheng XS, Wang LP. Meta-analysis of the condylar position with mandibular deviation. Shanghai journal of stomatology, 2018,27(2):210-215.

25. Zhou S, Yan J, Hu D, Yang Y, Na W, Wang W, et al. A Correlational Study of Scoliosis and Trunk Balance in Adult Patients with Mandibular Deviation. PLoS One. 2013;8(3):e59929.

26.Festa TF. Cervical spine curvature and craniofacial morphology in an adult Caucasian group: a multiple regression analysis. European Journal of Orthodontics. 2007;29(2):204-9.

27. Ozbek MM, Aysegül Köklü. Natural cervical inclination and craniofacial structure. Am J Orthod Dentofacial Orthop. 1994;104(6):584-591.

28.Pallegama RW, Ranasinghe AW, Weerasinghe VS, Sitheeque MAM. Influence of masticatory

muscle pain on electromyographic activities of cervical muscles in patients with myogenous temporomandibular disorders. Journal of Oral Rehabilitation. 2004; 31(5):423-429.
29. Wakano S, Takeda T, Nakajima K, Kurokawa K, Ishigami K. Effect of experimental horizontal mandibular deviation on dynamic balance. Journal of Prosthodontic Research. 2011;55(4):228-33.

30.Naito S, Ishida T, Kokai S, Fujita K, Shibata M, Yabushita T, et al. Functional adaptability of temporomandibular joint mechanoreceptors after an increase in the occlusal vertical dimension in rats. Angle Orthodontist. 2011;81(3):453-9.

31. Dieb W, Hafidi A. Mechanism of GABA involvement in post-traumatic trigeminal neuropathic pain: Activation of neuronal circuitry composed of PKCγ interneurons and pERK1/2 expressing neurons. European Journal of Pain. 2014;19(1):85-96.

32.Decocq P, Bocquet E. Influence of mandibular somesthesia on cephalic deviation and spatial representations. Orthodontie Franaise. 2020;91(1-2):83-91.

33.Melnik, Andrew K. A cephalometric study of mandibular asymmetry in a longitudinally followed sample of growing children. Am J Orthod Dentofacial Orthop. 1992; 101(4):355-66.

Figures

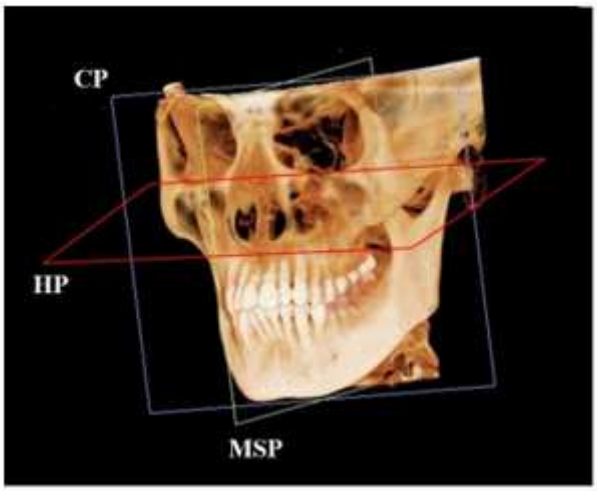

Figure 1

Three-dimensional reference plane

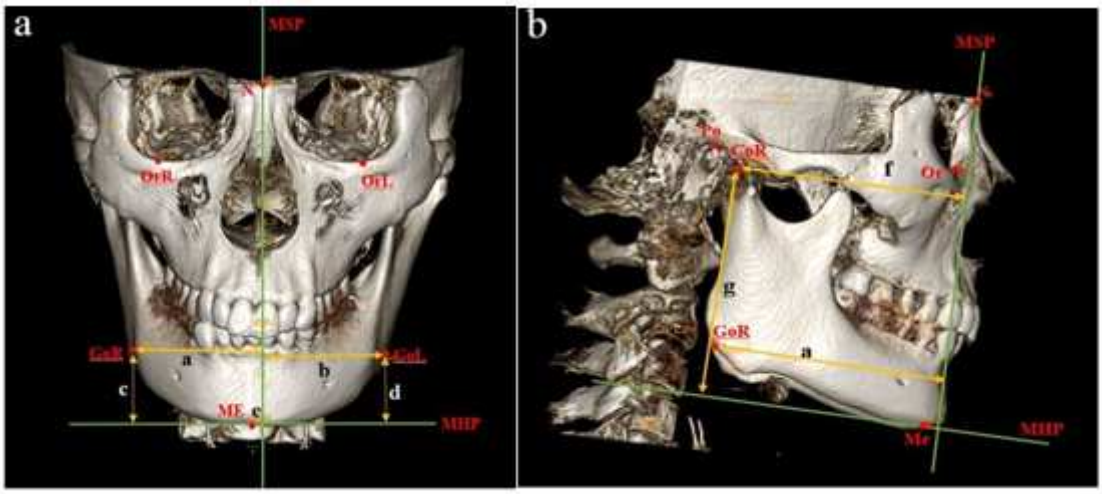

Figure 2

Mandibular measure items (a) in coronal plane (b) in median sagittal plane

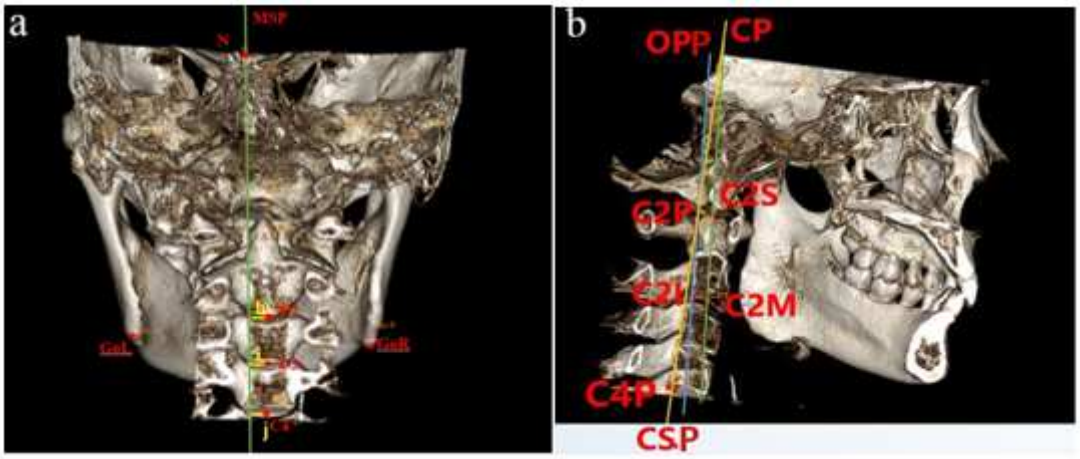

Figure 3

Cervical vertebra measure items (a) in coronal plane (b) in median sagittal plane

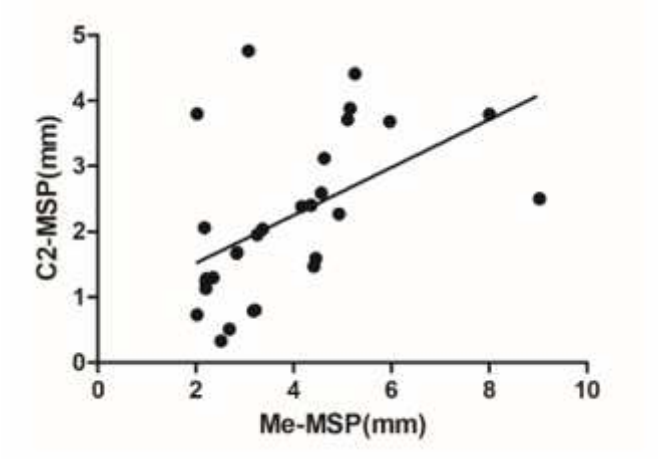

Figure 4

Correlation between chin deviation and cervical vertebra 2 deflection

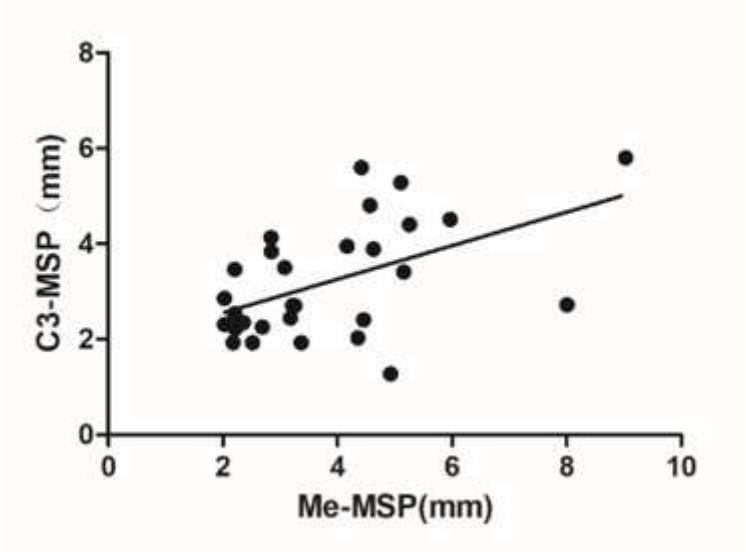

Figure 5

Correlation between chin deviation and cervical vertebra 3 deflection

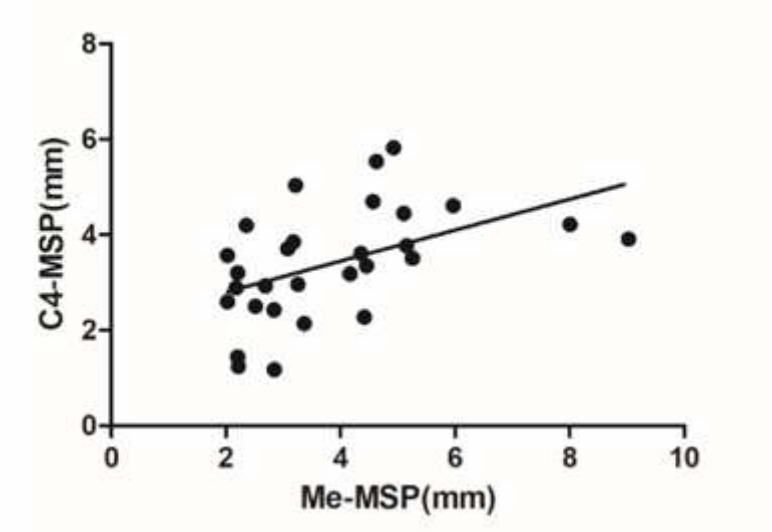

Figure 6

Correlation between chin deviation and cervical vertebra 4 deflection