Synchronous or sequential cementless bilateral total hip arthroplasty for osseous ankylosed hips with ankylosing spondylitis: a retrospective cohort study

Ping Mou
Sichuan University West China Hospital
Nan Wei Zeng
Sichuan University West China Hospital
Yu Chen
Sichuan University West China Hospital
Zongke Zhou (zhouzongke@scu.edu.cn)
Sichuan University West China Hospital https://orcid.org/0000-0002-9037-4756

Research article

Keywords: bilateral total hip arthroplasty, ankylosing spondylitis, ankylosed hips

Posted Date: August 3rd, 2020

DOI: https://doi.org/10.21203/rs.3.rs-46810/v1

Version of Record: A version of this preprint was published on March 24th, 2021. See the published version at https://doi.org/10.1186/s12891-021-04142-7.

Abstract

Purpose

cementless total hip arthroplasty (THA) for bilateral osseous ankylosed hips with ankylosing spondylitis (AS) is a challenging procedure. No literature compares the clinical outcomes of synchronous and sequential bilateral THA of these special patients.

Methods

23 patients (46 hips) were retrospectively analyzed and classified into receiving bilateral THA synchronously (group A) and receiving bilateral THA sequentially (group B). The clinical measurement, radiological assessments and complications were compared. Independent sample T test were used for data analysis.

Results

Harris Hip Scores (HHS) improved greatly for both groups (P = 0.58) as well as the range of motion (P = 0.64). But group B can realize shorter time (3.6 ± 1.2 days) to walk for the first time postoperatively (P = 0.02). The group A need more blood transfusions (P = 0.028). For group A, no statistic difference was found in bilateral inclination of cup (IC) (P = 0.48) and femoral offset (FO) (P = 0.07). For group B, no statistic difference was observed in bilateral IC (P = 0.37) but in bilateral FO (P = 0.04). The group A showed fewer difference of bilateral IC (P = 0.02), while comparative measurements for two groups in the difference of bilateral FO (P = 0.78) and leg length discrepancy (P = 0.83). For group A, one patient encountered femoral fracture intraoperatively and one patient encountered hip dislocation and delay union of wound as well as three hips encountering heterotopic ossification (HO). For group B, only three hips encountered HO.

Conclusion

Cementless bilateral THA was a safe and effective technique to improve hip function for patients diagnosed with osseous ankylosed hip due to AS. Synchronous bilateral THA can realize good clinical outcomes and more superior radiographic evaluation compared to sequential bilateral THA.

Introduction

Ankylosing spondylitis (AS) is an inflammation spondyloarthritis affecting the axial spine and peripheral joints and characterised by low back pain and limited range of motion (ROM) of lumbar spine [1, 2]. And AS is diagnosed using the modified New York criteria requiring image change of sacroiliitis and painful reduction of lumbar spine ROM as well as stiffness of more than 3 months [3]. Hips are the most

common peripheral joints involved in approximately 25%~50% patients diagnosed with AS [4, 5] and 90% presents bilateral hip ankylosis [6]. The end-stage hip ankylosis usually shows osseous ankylosis with total loss of hip ROM [7]. Although bilateral hip fusion leads to stable and painless hip, yet loss of hip function and premature degeneration of neighboring joints have an negative effect on quality of life, especially for suboptimal hip fusion for a long period [8–10]. Bilateral total hip arthroplasty (THA) can relieve pain and recover the ROM of hips to improve the joint function and self-care ability [11]. Also, many literatures have reported the good radiographic outcome and improvements in function [7, 12–14]. However, for bilateral osseous ankylosed hips with AS, there is no consensus on synchronous or sequential THA for these special group of patients.

There are many difficulties for hip fusion takedown to THA. Firstly, the exposure of femoral head and neck is not easy for ankylosed hip, especially for the case with external rotation deformity, which increases the damage chance of posterior acetabulum and the great trochanter [7]. Secondly, the ambiguous indication for the original joint plane [7] and disuse osteoporosis of the acetabulum [15] are usually encountered during anatomical identification and acetabular reaming. At last, the degenerative development of abductor muscles [16] and incorrect insertion of acetabular cup due to pelvic obliquity [12] can lead to hip dislocation and accelerate liner wear. For bilateral bony ankylosed hips with AS, while synchronous THA may prolong operation time and cause more blood loss, bilateral hip lesions can be solved simultaneously. Moreover, two flectional hips can be favourable for functional rehabilitation postoperatively. Sequential THA for these patients can lead to shorter operation time and less surgical damage, yet the temporary unhandled ankylosed hip can be an obstacle to the early exercise of the operated hip and the total two hospitalization expenses may increase unavoidably. Currently, the literatures just reported synchronous or sequential THA for osseous ankylosed hips with AS [7, 12, 14] with the limitation of different types of cementless cup and cemented or cementless stem [12], short time of follow-up [14] and small study population [7]. There was no report comparing the clinical and radiographic outcomes of synchronous with sequential cementless bilateral THA for osseous ankylosed hips with AS.

The purpose of this study was to primarily compare the clinical and radiographic outcomes of synchronous and sequential cementless bilateral THA to correct bony ankylosis of hips with AS. It was hypothesized that for osseous ankylosed hips with AS, synchronous cementless bilateral THA can realize the similar outcomes of sequential THA.

Materials And Methods

Data were collected by retrospective review of a prospective database from January 2010 to December 2017. Study approval was obtained from the Clinical Trials and Biomedical Ethics Committee of West China Hospital (ID: 2012 – 268), and all participants signed informed consents for the use of their data. The data included patient demographics, time of walking for the first time postoperatively, range of flection-extension motion, Harris Hip Scores (HHS), transfusion, radiological assessments and complications.

Patients

The inclusion criteria: Patients diagnosed with AS and underwent primary cementless THA; Patients with bilateral osseous ankylosed hips and trabecula bridging the joint plane on radiograph; Total loss of hip ROM; Patients receiving bilateral THA simultaneously or sequentially. The exclusion criteria: Bilateral osseous ankylosed hips caused by other reasons; Unilateral osseous ankylosed hip with AS; Fibrous ankylosis of the hip and no trabecula bridging the joint plane on radiograph; Patients just receiving unilateral THA; The patients lost to follow-up.

Ultimately, we analyzed the data of the patients receiving bilateral THA synchronously (group A) and bilateral THA sequentially (group B). All hips were identified as bony ankylosed hip with total loss of ROM. We called up the patients to accomplish follow-up. And we obtained the latest clinical and radiological outcomes. 11 patients (22 hips) in group A and 12 patients (24 hips) in group B were followed up. The demographic data of the patients was summarized in Table 1. The mean duration of the follow-up was 81.9 ± 36.3 months for group A and 79.9 ± 29.1 months for group B (P = 0.84).

Surgical procedures

All operations were performed by a group of surgeons specializing in THA. Considering the different degree of hip deformity, the worse hip was done firstly. After general anesthesia, all patients were positioned in lateral position and exposed the hips through posterolateral approach. Femoral neck was identified according to the lesser trochanter and osteotomy was done without hip dislocation. For the hip with external deformity, osteotomy behind the femoral neck is difficult. So, we usually perform osteotomy in the front of femoral neck to avoid damage of greater trochanter and posterior acetabulum. No trochanteric osteotomy was performed. Reamers with gradual increase in diameter were uesd to prepare the acetabulum in the medial direction and the counterrotation technique was used to avoid overreaming of the osteoporotic acetabulum. On the basis of foveal soft tissue and incomplete gray ossifying cartilage, we located the original joint plane. The optimal cup size and cup inclination of the acetabulum implant were identified by intraoperative fluoroscopy. And the anteversion of cup was confirmed with the indication of transverse acetabular ligament or long axis of body. If initial press-fit was not satisfactory, additional screws would be used to fix the cup before inserting the liner.

For the preparation of femoral canal, sequentially larger reamers were used to enlarge the canal until the diaphyseal cortex was involved. The lesser trochanter and ipsilateral transcondylar line indicated the anteversion of the stem. Then femoral trial prosthesis was inserted to correct the leg length discrepancy (LLD), check the stability in all direction and optimize the femoral offset. At last, the cementless femoral prosthesis and femoral head were inserted. We check again the stability and ROM of the hip to ensure an optimal angles and postoperative mobility. If the hip can’t be abducted more than 15°passively, we will cut off the adductor tendon. At the end of the procedure, the external rotator muscles were restored and the drainage was selected according to the the time of operation and blood loss before incision suturing. Only one single brand (DePuy, Warsaw, IN) of cementless cup and stem implants were used for all

patients. The friction interfaces used including ceramic-on-ceramic (CoC) or ceramic-on-polyethylene (CoP) were decided according the age, level of activity and patients' financial situation.

Perioperative Regimen

Isometric exercises and positive motion exercises were conducted in bed after recovering from anesthesia. Prophylactic intravenous antibiotics were used within the first 24 hours postoperatively. Additionally, low-molecular-weight heparin (LMWH) were systematically managed to prevent deep venous thrombosis (DVT) and Non-Steroidal Anti-inflammatory Drugs (NSAIDs) were used to relieve pain and reduce the chance of heterotopic ossification (HO), respectively. For unbearable postoperative pain, additional painkillers by intravenous or intramuscular injection were added. The drainage tube was removed within 24 hours.

From the first postoperative day on, the patients were allowed to partial weight-bearing exercises with the help of walker aid, then exercise with the help of cane after 2 weeks and full weight-bearing exercises after 4 weeks without help. Moreover, for the patient with hip flection deformity preoperatively, the hip gradually extended under the circumstances of bearable pain.

Clinical Measurements

At the latest follow-up, clinical details were recorded including flection-extension ROM of the hip and Harris Hip Scores (HHS) of the two group [17]. Special ruler was used to measure the range of hip flexion and extension when the patients were in supine position. ROM and Harris scores were examined by 2 authors to reduce the bias. Additionally, from our database, we collected the time of walking for the first time postoperatively, the average blood transfusions and the blood transfusion rate. The standard of blood transfusions refered to the guidelines of the National Ministry of Health, recommending blood transfusion for hemoglobin level less than 7 g/dL until the level reached or exceeded 8 g/dL. Additionally, when hemoglobin level fluctuated between 7 and 10 g/dL, transfusion would be considered in patients with symptomatic anemia (severe mental status changes, palpitations, and/or pallor).

Radiological Assessments

Standard anteroposterior radiographs were obtained preoperatively, immediately after surgery and at the latest follow-up. And the radiological data were collected and analyzed by the same two authors. The assessments include the inclination of the cup (IC), the difference of bilateral IC, the femoral offset (FO), the difference of bilateral FO and LLD at the latest follow-up. IC were measured directly on AP radiograph. The angle crossed by the horizontal line connecting the both teardrops and line through the longest diameter of the elliptical opening of the acetabular cup rim was recorded and regarded as IC [12]. If the teardrops were unrecognizable or the pelvis was asymmetric, we firstly bisected the sacrum with a vertical line A and secondly drawn a perpendicular line B to line A [12]. So, the line B can be used as horizontal line. FO was defined as the vertical distance from the center of femoral head to the ipsilateral anatomical femoral axis [18]. LLD was assessed by standardized-trochanteric method to avoid the influence of pelvic obliquity and femoral inclination on the radiographs [19].

Complications

The complications are recorded including early-onset and late-onset complications during the perioperative period and at the latest follow-up. The early-onset complications consist of dislocation, wound complications, infection, intraoperative fracture, DVT, pulmonary embolism and nerve palsy. The data were collected from the database. Meanwhile, the late-onset complications consist of postoperative dislocation, HO, osteolysis and aseptic loosening at the latest follow-up, which were assessed by two authors. On the basis of Brooker classification [20], we analyzed and classified the degree of HO. Osteolysis was defined as cystic or scalloped lesions with a diameter of more than 2 mm on radiograph [21, 22]. According to the criteria if DeLee [23], the acetabular component was considered loose if a complete radiolucent line thicker than 1 mm at bone-implant interface or migration of the component showed. Besides, the femoral implant stability was evaluated according to Engh [24], the stem was considered loose if subsidence more than 2 mm or angular shift of the stem more than 2°showed.

Statistical Analysis

Statistical analysis was performed using SPSS software for Windows Version 22.0 (SPSS, Chicago, IL). The level of statistical significance was set at p 0.05. The results were expressed as the mean ± standard deviation. Independent sample T test was used for data analysis.

Results

Clinical outcomes

The average preoperative HHS increased from preoperative 30.5 ± 5.9 to 84.0 ± 2.8 at the latest follow-up for group A and from preoperative 31.4 ± 4.6 to 83.4 ± 2.0 at the latest follow-up for group B. Moreover, all of the hips lost total ROM of hip preoperatively, but at the latest follow-up, the average flection-extension ROM was 85.7 ± 4.5° for group A and 85.1 ± 4.1° for group B. The average flexion and extension were 86.5 ± 4.4° and 0.73 ± 2.4° for group A and 85.7 ± 3.5° and 0.54 ± 1.9° for group B, respectively. No statistical difference was found in both groups, but large improvement was realized postoperatively (Table. 2). Additionally, all of the patients were satisfied with the clinical outcome and gait had improved markedly compared with preoperative status.

However ,the difference was found statistically that the patients receiving simultaneously bilateral THAs needed more time to walk for the first time postoperatively with 5.1 ± 2.6 days, while the patients receiving sequentially bilateral THAs walk for the first time postoperatively with 3.6 ± 1.2 days (P = 0.02) (Table. 2). The average interval time between two operations was 40.8 ± 23.0 days for group B. Furthermore, blood transfusions perioperativly were also different between the two groups. Average blood transfusions was 3 ± 3.97 U for group A and 0.71 ± 1.99 U for group B (P = 0.028), while the blood transfusion rate were 8/11 (72.7%) for group A and 5/24 (20.8%) for group B (Table. 2).

Radiographic evaluation

For group A, at the latest follow-up, it was no difference that the average IC between the right and left hips (P = 0.48) (Figure. 1). Similarly, the same finding was presented in group B (P = 0.37) (Figure. 2). For the FO, the patients in group A showed no difference between the right and left hips (P = 0.07), while statistical difference was found In group B (P = 0.04) (Table. 3). Also, we compared the difference of bilateral IC and the difference of bilateral FO of the both groups (Table. 4). The differences of bilateral IC were 3.0 ± 2.1°for group A and 5.5 ± 2.4°for group B, which showed a significant statistical difference (P = 0.02). Meanwhile, the differences of bilateral FO were 0.35 ± 0.27 cm for group A and 0.32 ± 0.21 cm for group B. And LLD were 0.48 ± 0.39 cm for group A and 0.45 ± 0.31 cm for group B. No differences were found between groups for the differences of bilateral FO (P = 0.78) and LLD (P = 0.83).

Complications

Only two hips in group A encountered early-onset complications. One femoral fracture intraoperatively and was fixed with several double-loop cerclage wires immediately. The patients postponed walking on the ground, which was substituted with functional exercise in bed. And the fracture healed without problem. Hip dislocation on the third day postoperatively and delay union of wound hit the same patient. Closed manipulative reduction was performed and dressings were changed more frequently. Also, we prolong the time of antibiotic use for three days to prevent the deep infection. Ultimately, no dislocation happened and the wound was recovered. For late-onset complications, three hips (13.6%) in group A and three hips (12.5%) in group B encountered asymptomatic HO, all of which belong to Brooker I. Other complications such as dislocation, osteolysis and loosening were not observed.

Discussion

The most important finding of this study was that cementless bilateral THA for osseous ankylosed hips with AS showed good clinical outcomes and all of the patients were satisfactory with the functional improvements and gait had improved markedly compared with preoperative status. Besides, compared to sequential bilateral THA, simultaneous bilateral THA can realized the comparative clinical outcomes with an average follow-up more than 79 months. Although simultaneous bilateral THA may need more blood transfusions, simultaneous procedure can realize nearer FO and lesser difference of bilateral IC.

Due to the deformity followed by bony ankylosed hip with AS and ambiguous landmarks, the adequate exposure of the surgical fields can simplify the subsequent procedure. There are three approaches to expose the coxa including: posterolateral approach [7, 13, 14], posterior approach [25–27] and direct lateral approach with a trochanteric osteotomy [6, 12]. For the bony ankylosed hips, the weakness of abductor muscles is obvious on account of disuse-artophy [16]. So, the early functional rehabilitation is significant to prevent dislocation and instability. However, to visualize the acetabulun and proximal femur, the direct lateral approach was usually performed with a trochanteric osteotomy. The secondary delay of walking [28] and possible nonunion of the greater trochanter [13] may pay for inferior rehabilitation and satisfaction. Besides, nerve injury especially the superior gluteal nerve is another complication resulting in abductor insufficiency after THA from direct lateral approach, which was reported an incidence of 2.2%-42.5% [29, 30]. So, in recent years, many literatures recommended posterolateral approach [7, 13, 14]

or posterior approach [25–27]. These two approaches can realize sufficient exposure to the acetabulum and poximal femur. But more attention should be attached to preventing the risk of sciatic nerve injury due to scarred and contracted soft tissues around the hip caused by AS [31, 32]. These two approaches both can achieve a safe and high-quality THA and we recommend that doctors choose the skilled and experienced approach to perform.

It's difficult to identify the interface of femoral head and acetabulum intraoperatively due to osseous bridge formation and total loss of ROM for the hip with AS. So, how to conduct acetabular reaming appropriately and insert the cup with suitable size play a vital role in successful THA. After performing femoral neck osteotomy, the osseous bridge between the acetabulum and femoral head make it difficult to ream in right direction and with right size. Although there is bony ankylosis of the hip, yet incomplete gray ossifying cartilage is still remaining at the original joint plane [7, 13, 14]. We can enlarge the acetabulum with sequentially larger reamer in the medial direction and adjust the direction of reaming according to the appearance of incomplete gray ossifying cartilage. Also, the foveal soft tissue can act as an indication for the depth of reaming [7, 13, 14]. Additionally, long-term loss of ROM leads to acetabular disuse osteoporosis [15], which can easily generate over-reaming of acetabulum. the counterrotation technique can avoid over-reaming and compress the bone in the acetabular base benefiting for primary press-fit of cup. Of course, intraoperative radiography facilitate judging the suitable size and depth of cup.

Asymmetric pelvis is usually encountered for bony ankylosed hips with AS resulting in great challenge of cup insertion in appropriate direction, especially for simultaneous bilateral THA [12]. Because ankylosis of the contralateral hip can hamper the position of pelvis in lateral position [12]. Also, pelvis tilt can be an obstacle to insert the cup in an appropriate direction [7, 12, 14]. The malposition of cup can lead to dislocation or impingement and accelerate the liner wear [12, 33]. On the basis of different type of deformity with AS, the studies reported different ways to insert the cup in the safe range (40°±10° for inclination and 15°±10°for anteversion) [34]. If the hip presents simple flexion deformity, just insert the acetabular cup routinely and if the hip combines with adduction deformity, the inclination angle of cup should be reduced [7]. Moreover, anterversion of the cup should be reduced than desired, if the hip has fixed adduction and flexion deformity[12]. Comparatively, anterversion of the cup should be increased than desired, if the the hip has fixed abduction and flexion deformity [12]. Although these methods can work in dealing with different type of deformities, yet intraoperative radiographs and tests of hip stability in all directions are more significant to avoid dislocation, impingement and premature wear.

The purpose of THA for bony ankylosed hip is to correct the hip deformity and restore the fundamental flexion-extension ROM from fusion hip, which is reported that the increase of ROM and improvement in self-care ability are two important factors associating with patient satisfaction [11]. Although conversion of bony ankylosed hip to THA leads to inferior ROM and HHS compared to primary THA (PTHA), THA for those patients can relieve pain, restore hip mobility, improve function and correct LLD [13, 16]. Also, THA for fusion hip is more technically difficult, needs more operation time and causes more traumatic response compared to PTHA [7, 12, 14, 33], which may result in more blood loss and longer time of

rehabilitation and more obvious for bilateral THA performed simultaneously, this kind of situation can be more obvious. The research has reported that postoperative transfusion rate for one-stage bilateral PTHA is 29.2% and unilateral PTHA is 15.9% as well as more rehabilitation time is needed for bilateral PTHA [35]. And our study also showed more transfusions were needed for simultaneous procedure and sequential procedure. Furthermore, simultaneous procedure demanded more transfusions and more time of rehabilitation than sequential procedure. However, with the extensive use of tranexamic acid in total joint arthroplasty [36, 37], the blood loss can be reduced obviously. Fortunately, these two operation options can realize comparable HHS and flexion-extension ROM. Moreover, no difference were found in LLD, IC and the difference of bilateral FO. Although simultaneous procedure can lead to less difference of bilateral IC, yet the average IC of both two procedure fluctuates between 30°and 50°. For the patients with good nutritional status, one-stage bilateral THA may be an alternative means to cure bony ankylosed hip simultaneously.

The study reported that AS increased perioperative and postoperative complications after THA and high incidences of complications including wound cmplications, polyethylene wear, revision and dislocation were observed [38]. Survival analysis of THA for AS was 81.4% at 15 years [6], which was lower than that of THA for other etiologies [39]. Also, the rate of polyethylene wear of THA for bony ankylsed hip was high than that of PTHA concluded according to Kim et al [40]. Two reasons may explain the higher rates of implant failure for bony ankylosed hip. Firstly, component malposition and abnormal spinopelvic mechanics contribute to abnormal stress to the implants resulting in accelerating the polyethylene wear and increasing revision rate [41, 42]. secondly, the patients receiving THA for these special group are younger and more active than average THA, who present higher functional demand and physical activity [38]. Hip dislocation is another frequent complication. Component malposition and increased demand for the motion of hip extension and flexion due to rigidity of spine add risk of hip dislocation when running daily activity [43]. Also, the weakness of abductor muscles is another risk of dislocation. Moreover, intraoperative periprosthetic fractures is another noticeable complication. Osteoporosis of acetabulum and proximal femur is usually encountered for fusion hip due to long-term disuse [15]. When insert the prosthesis, excessive impact may cause cup protrusion into pelvis or proximal femoral fracture leading to poor primary fixation of stem. So, appropriate impact and careful examination of possible fracture should be involved intraoperatively. If necessary, additional screws or the stem with distal fixation can be used also.

Several limitations are noticed in our study. First, the study is a retrospective evaluation of prospectively followed patients at a single center. Second, the number of patients enrolled is relatively small and short follow-up. But this study is the currently biggest sample-size research about THA for bilateral bony ankylosed hips. Third, the surgery-specific information including intraoperatve blood loss, total blood loss and Inflammatory biomarkers can’t be obtained. However, with the fast development of enchanced recovery after surgery in our joint center, the blood loss and traumatic response can be lesser and lesser accompanied with faster recovery from surgery for patients.

Conclusion

Cementless bilateral THA was a safe and effective technique to improve hip function for patients diagnosed with osseous ankylosed hip due to AS. Synchronous bilateral THA can realize good clinical outcomes and more superior radiographic evaluation compared to sequential bilateral THA

Abbreviations

THA
total hip arthroplasty; AS:ankylosing spondylitis; HHS:Harris Hip Score; IC:inclination of cup; FO:femoral offset; ROM:range of motion; LLD:leg length discrepancy; CoC:ceramic-on-ceramic; CoP:ceramic-on-polyethylene; LMWH:low-molecular-weight heparin; DVT:deep venous thrombosis; NSAIDs:Non-steroidal Anti-inflammatory Drugs; HO:heterotopic ossification;

Declarations

Ethics approval and consent to participate

This study has been approved by the Clinical Trials and Biomedical Ethics Committee of West China Hospital, Sichuan University (ID:2012-268). Informed consent (including patients' details, images or videos) was obtained from all participants. All experiments were performed in accordance with relevant guidelines and regulations. This study was conducted in accordance to the Declaration of Helsinki.

Consent for publication

All data collected in this study have consent for publication.

Availability of data and materials

The datasets used and/or analyzed during the current study are available from the corresponding author on reasonable request.

Competing interests

The authors announce that they do not have any competing interests.

Funding

This research was funded by the National Natural Science Foundation of China Program (81672135), Science and Technology Planning Project of Sichuan Province (2019YFS0266).

Authors' contributions

ZZ conceived and designed this study; PM and WZ collected the data; PM wrote the manuscript; YC performed the statistical analysis and prepared Tables. PM, WZ and ZKZ revised this manuscript. All authors reviewed the final manuscript. All authors agree to be accountable for all aspects of the work. PM and WZ contributed equally to this work and should be considered as equal first authors.

Acknowledgements

We thank all the patients for participation in our study, and we are grateful to the staff of our department for their support and contribution in this study.

References

1. *Braun, J., J. Sieper. Ankylosing spondylitis. Lancet, 2007. 369(9570)*: p. *1379–1390*.
2. *Raychaudhuri, S.P., A. Deodhar, The classification and diagnostic criteria of ankylosing spondylitis. J Autoimmun, 2014. 48–49*: p. *128 – 33*.
3. *van der Linden, S., H.A. Valkenburg, A. Cats. Evaluation of diagnostic criteria for ankylosing spondylitis. A proposal for modification of the New York criteria. Arthritis Rheum, 1984. 27(4)*: p. *361-8*.
4. *Tang, W., K. Chiu. Primary total hip arthroplasty in patients with ankylosing spondylitis. Journal of Arthroplasty, 2000. 15(1)*: p. *52–58*.
5. *Sochart, D.H., M.L. Porter. Long-term results of total hip replacement in young patients who had ankylosing spondylitis. Eighteen to thirty-year results with survivorship analysis. J Bone Joint Surg Am, 1997. 79(8)*: p. *1181-9*.
6. *Atul B Joshi, Ljubisa Markovic, Kevin Hardinge, John C M Murphy. Total hip arthroplasty in ankylosing spondylitis: an analysis of 181 hips. J Arthroplasty, 2002. 17(4)*: p. *427 – 33*.
7. *Bangjian, H., T. Peijian, L. Ju. Bilateral synchronous total hip arthroplasty for ankylosed hips. Int Orthop, 2012. 36(4)*: p. *697–701*.
8. *Callaghan, J.J., R.A. Brand, D.R. Pedersen. Hip arthrodesis. A long-term follow-up. J Bone Joint Surg Am, 1985. 67(9)*: p. *1328-35*.
9. *Roberts, C.S., J.F. Fetto. Functional outcome of hip fusion in the young patient. Follow-up study of 10 patients. J Arthroplasty, 1990. 5(1)*: p. *89–96*.

10. *Sponseller, P.D., A.A. McBeath, M. Perpich. Hip arthrodesis in young patients. A long-term follow-up study. J Bone Joint Surg Am, 1984. 66(6)*: p. *853-9*.
11. *Ding L, Gao YH, Li YR, Liu JG, Li SQ, Qi X. Determinants of satisfaction following total hip arthroplasty in patients with ankylosing spondylitis. Int Orthop, 2018. 42(3)*: p. *507–511*.
12. *Yong Lae Kim, Sang Ik Shin, Kwang Woo Nam, Jeong Joon Yoo, Young-Min Kim. Hee Joong Kim, Total hip arthroplasty for bilaterally ankylosed hips. J Arthroplasty, 2007. 22(7)*: p. *1037-41*.
13. *Young-Hoo Kim, S-H Oh, J-S Kim, S-H Lee. Total hip arthroplasty for the treatment of osseous ankylosed hips. Clin Orthop Relat Res, 2003(414)*: p. *136 – 48*.
14. *Dong-Xu Feng, Kun Zhang, Yu-Min Zhang, Yue-Wen Nian, Jun Zhang, Xiao-Min Kang, Shu-Fang Wu, Yang-Jun Zhu. Bilaterally Primary Cementless Total Hip Arthroplasty for Severe Hip Ankylosis with Ankylosing Spondylitis. Orthop Surg, 2016. 8(3)*: p. *352-9*.
15. *Vosse, D., K. de Vlam, Osteoporosis in rheumatoid arthritis and ankylosing spondylitis. Clin Exp Rheumatol, 2009. 27(4 Suppl 55)*: p. *S62-7*.
16. *D J Kilgus, H C Amstutz, M A Wolgin, F J Dorey. Joint replacement for ankylosed hips. J Bone Joint Surg Am, 1990. 72(1)*: p. *45–54*.
17. *Harris, W.H., Traumatic arthritis of the hip after dislocation and acetabular fractures: treatment by mold arthroplasty. An end-result study using a new method of result evaluation. J Bone Joint Surg Am, 1969. 51(4)*: p. *737 – 55*.
18. *Pregash Ellapparadja, Vivek Mahajan, Angela H Deakin, Kamal. Deep Reproduction of Hip Offset and Leg Length in Navigated Total Hip Arthroplasty: How Accurate Are We? J Arthroplasty, 2015. 30(6)*: p. *1002-7*.
19. *Matej Keršič, Drago Dolinar, Vane Antolič, Blaž* Mavčič. *The impact of leg length discrepancy on clinical outcome of total hip arthroplasty: comparison of four measurement methods. J Arthroplasty, 2014. 29(1)*: p. *137 – 41*.
20. *A F Brooker, J W Bowerman, R A Robinson, L H Riley Jr. Ectopic ossification following total hip replacement. Incidence and a method of classification. J Bone Joint Surg Am, 1973. 55(8)*: p. *1629-32*.
21. *R P Joshi, N S Eftekhar, D J McMahon, O A Nercessian. Osteolysis after Charnley primary low-friction arthroplasty. A comparison of two matched paired groups. J Bone Joint Surg Br, 1998. 80(4)*: p. *585 – 90*.
22. *W J Maloney, M Jasty, W H Harris, J O Galante, J J Callaghan. Endosteal erosion in association with stable uncemented femoral components. J Bone Joint Surg Am, 1990. 72(7)*: p. *1025-34*.
23. *DeLee, J.G., J. Charnley. Radiological demarcation of cemented sockets in total hip replacement. Clin Orthop Relat Res, 1976(121)*: p. *20–32*.
24. *Engh, C.A., P. Massin, K.E. Suthers. Roentgenographic assessment of the biologic fixation of porous-surfaced femoral components. Clin Orthop Relat Res, 1990(257)*: p. *107 – 28*.

25. *Chuan Ye*, *Riguang Liu*, *Changying Sun*, *Jianhao Lin*, *Hu Li*, *Houxiang Re*, *Bo Sun*, *Qi* Sun, Long Yang. *Cementless bilateral synchronous total hip arthroplasty in ankylosing spondylitis with hip ankylosis*. *Int Orthop*, *2014*. *38*(*12*): p. *2473-6*.
26. *Gautam*, *D R.*, *Malhotra*. *Total Hip Arthroplasty in Ankylosing Spondylitis With Extension Contracture of Hips*. *J Arthroplasty*, *2019*. *34*(*1*): p. *71–76*.
27. *Hong-Zhang Guo*, *Chen-Xu Yang*, *Zhao-Peng Tang*, *Cheng-Xiang Wang*. *The effects of total hip arthroplasty in treating hip bony fusion in young and middle-aged patients with ankylosing spondylitis*. *J Orthop Surg Res*, *2019*. *14*(*1*): p. *253*.
28. *Amstutz*, *H.C.*, *D.N. Sakai*, *Total joint replacement for ankylosed hips*. *Indications*, *technique*, *and preliminary results*. *J Bone Joint Surg Am*, *1975*. *57*(*5*): p. *619 – 25*.
29. *Khan*, *T.*, *D. Knowles*, *Damage to the superior gluteal nerve during the direct lateral approach to the hip*: *a cadaveric study*. *J Arthroplasty*, *2007*. *22*(*8*): p. *1198 – 200*.
30. *M Ramesh*, *J M O'Byrne*, *N McCarthy*, *A Jarvis*, *K Mahalingham*, *W F Cashman*. *Damage to the superior gluteal nerve after the Hardinge approach to the hip*. *J Bone Joint Surg Br*, *1996*. *78*(*6*): p. *903-6*.
31. *A Zink*, *J Braun*, *J Listing*, *J Wollenhaupt*. *Disability and handicap in rheumatoid arthritis and ankylosing spondylitis–results from the German rheumatological database*. *German Collaborative Arthritis Centers*. *J Rheumatol*, *2000*. *27*(*3*): p. *613 – 22*.
32. *Benjamin*, *M.*, *D. McGonagle*, *The anatomical basis for disease localisation in seronegative spondyloarthropathy at entheses and related sites*. *J Anat*, *2001*. *199*(*Pt 5*): p. *503 – 26*.
33. *Mujadid Idulhaq*, *Kyung Soon Park*, *Sanket R Diwanji*, Taek Rim Yoon, Jin Sang Wie. Total hip arthroplasty for treatment of fused hip with 90 degrees flexion deformity. J Arthroplasty, *2010*. 25(3): p. 498.e5-9.
34. *Pradhan*, *R. Planar anteversion of the acetabular cup as determined from plain anteroposterior radiographs*. *J Bone Joint Surg Br*, *1999*. *81*(*3*): p. *431-5*.
35. *Mina W Morcos*, *Adam Hart*, *John Antoniou*, *Olga L Huk*, *David J Zukor*, *Stephane G Bergeron*. *No Difference in Major Complication and Readmission Rates Following Simultaneous Bilateral vs Unilateral Total Hip Arthroplasty*. *J Arthroplasty*, *2018*. *33*(*8*): p. *2541–2545*.
36. *Duan Wang*, *Hao-Yang Wang*, *Ze-Yu Luo*, *Fu-Xing Pei*, *Zong-Ke Zhou*, *Wei-Nan Zeng*. *Finding the Optimal Regimen for Oral Tranexamic Acid Administration in Primary Total Hip Arthroplasty*: *A Randomized Controlled Trial*. *J Bone Joint Surg Am*, *2019*. *101*(*5*): p. *438–445*.
37. *Ze-Yu Luo*, *Hao-Yang Wang*, *Duan Wang*, *Kai Zhou*, *Fu-Xing Pei*, *Zong-Ke Zhou*. *Oral vs Intravenous vs Topical Tranexamic Acid in Primary Hip Arthroplasty*: *A Prospective*, *Randomized*, *Double-Blind*, *Controlled Study*. *J Arthroplasty*, *2018*. *33*(*3*): p. *786–793*.
38. *Daniel J Blizzard*, *Colin T Penrose*, *Charles Z Sheets*, *Thorsten M Seyler*, *Michael P Bolognesi*, *Christopher R Brown*. *Ankylosing Spondylitis Increases Perioperative and Postoperative Complications After Total Hip Arthroplasty*. *J Arthroplasty*, *2017*. *32*(*8*): p. *2474–2479*.
39. *Sodhi*, *N.*, *M.A. Mont*. *Survival of total hip replacements*. *Lancet*, *2019*. *393*(*10172*): p. *613*.

40. *Kim, Y.H., J.S. Kim, S.H. Cho. Primary total hip arthroplasty with a cementless porous-coated anatomic total hip prosthesis: 10- to 12-year results of prospective and consecutive series. J Arthroplasty, 1999. 14(5)*: p. *538 – 48*.
41. *Wanchun Wang, Guoliang Huang, Tianlong Huang, Ren Wu. Bilaterally primary cementless total hip arthroplasty in patients with ankylosing spondylitis. BMC Musculoskelet Disord, 2014. 15*: p. *344*.
42. *G Q Zheng, Y G Zhang, J Y Chen, Y Wang. Decision making regarding spinal osteotomy and total hip replacement for ankylosing spondylitis: experience with 28 patients. Bone Joint J, 2014. 96-b(3)*: p. *360-5*.
43. *Daniel J Blizzard, Charles Z Sheets, Thorsten M Seyler, Colin T Penrose, Mitchell R Klement, Michael A Gallizzi, Christopher R Brown. The Impact of Lumbar Spine Disease and Deformity on Total Hip Arthroplasty Outcomes. Orthop Clin North Am, 2016. 47(1)*: p. *19–28*.

Tables

Table.1 Baseline Characteristics of all included patients

Variable	Group A (22 hips)	Group B (24 hips)	T value	P value
M/F	1/10	2/10	-	-
Height (cm)	161.9±9.0	160.0±5.1	0.88	0.37
Weight (Kg)	59.9±10.7	58.1±6.6	0.69	0.50
BMI (Kg/m^2)	22.7±3.3	22.7±2.5	-0.02	0.98
Friction couples				
Ceramic-on ceramic	18	18	-	-
Ceramic-on-polyethylene	4	6	-	-
Average follow-up time (m)	81.9±36.3	79.9±29.1	0.21	0.84

Group A: synchronous cementless bilateral total hip arthroplasty

Group B: sequential cementless bilateral total hip arthroplasty

BMI: body mass index

Table. 2 Clinical outcomes of all included patients postoperatively

Variable	Group A (22 hips)	Group B (24 hips)	T value	P value
Preoperative HHS	30.5±5.9	31.4±4.6	-0.62	0.58
Postoperative HHS	84.0±2.8	83.4±2.0	0.89	0.38
extension	0.73±2.4	0.54±1.9	0.29	0.77
flexion	86.5±4.4	85.7±3.5	0.67	0.50
ROM	85.7±4.5	85.1±4.1	0.47	0.64
Time of walking for the first time postoperatively	5.1±2.6	3.6±1.2	2.43	0.02*
average blood transfusions (U)	3±3.97	0.71±1.99	2.29	0.028*
blood transfusion rate	8/11(72.7%)	5/24 (20.8%)	-	-

Group A: synchronous cementless bilateral total hip arthroplasty

Group B: sequential cementless bilateral total hip arthroplasty

HHS:Harris Hip score

ROM:range of motion

P values with statistical significance are marked with *

Table. 3 radiographic evaluation of the included patients between groups

Variable	Group A (22 hips)				Group B (24 hips)			
	Right hips	Left hips	T	P	Right hips	Left hips	T	P
Average IC(°)	39.6±3.8	38.8±5.1	0.73	0.48	41.5±4.4	39.9±5.2	0.94	0.37
Average FO(cm)	4.6±0.6	4.4±0.6	2.16	0.07*	4.1±0.3	3.9±0.3	2.34	0.04*

Group A: synchronous cementless bilateral total hip arthroplasty

Group B: sequential cementless bilateral total hip arthroplasty

IC: inclination of cup

FO: femoral offset

P values with statistical significance are marked with *

Table.4 radiographic evaluation of the included patients between groups postoperatively

Variable	Group A (22 hips)	Group B (24 hips)	T value	P value
The difference of bilateral IC (°)	3.0±2.1	5.5±2.4	-2.63	0.02
The difference of bilateral FO (cm)	0.35±0.27	0.32±0.21	0.28	0.78
LLD (cm)	0.48±0.39	0.45±0.31	0.22	0.83

Group A: synchronous cementless bilateral total hip arthroplasty

Group B: sequential cementless bilateral total hip arthroplasty

IC: inclination of cup

FO: femoral offset

LLD: leg length discrepancy

P values with statistical significance are marked with *

Figures

Figure 1

Case presentation of synchronous cementless bilateral total hip arthroplasty for osseous ankylosed hips with ankylosing spondylitis a: A man was diagnosed with ankylosing spondylitis and showed bilateral osseous ankylosed hips preoperatively. b: The radiograph of the pelvis after surgery immediately showed similar inclination of cup and femoral off-set as well as small leg-length discrepancy. c: The radiograph of the pelvis at 100-month follow-up showed no aseptic loosening and migration of the component.

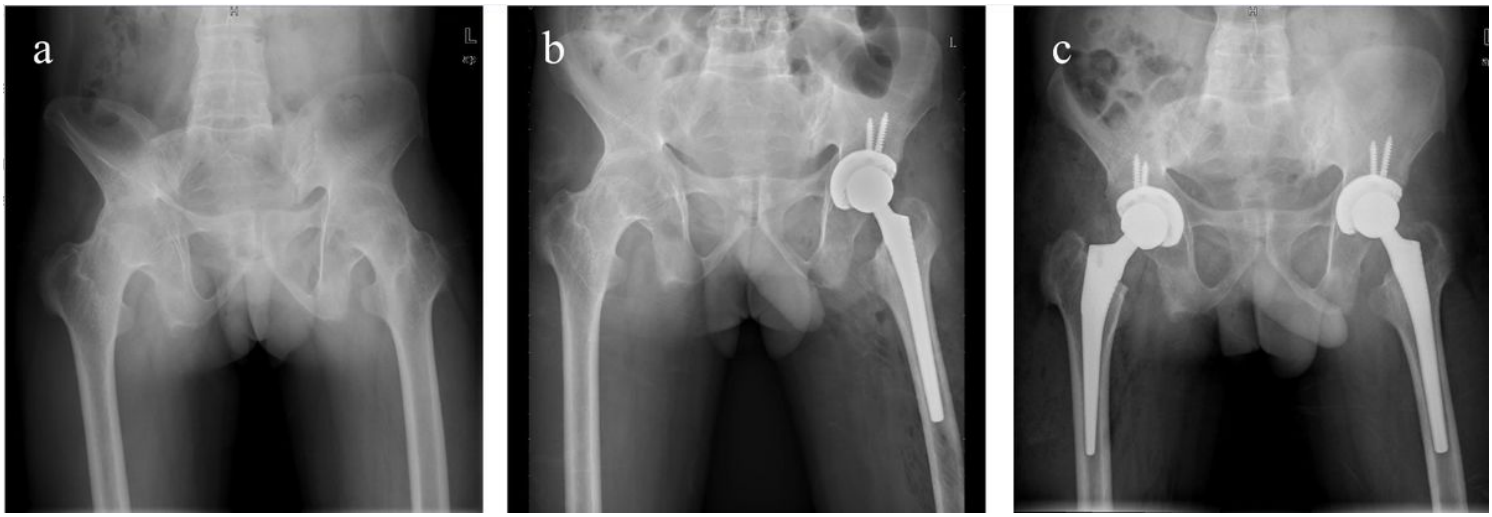

Figure 2

Case presentation of sequential cementless bilateral total hip arthroplasty for osseous ankylosed hips with ankylosing spondylitis a: A man was diagnosed with ankylosing spondylitis and showed bilateral osseous ankylosed hips preoperatively. b: The radiograph of the pelvis before contralateral THA showed excellent prosthesis position and size of firstly performed THA. c: The film of the pelvis at 97-month follow-up showed superior radiological parameter and good fixation of the prosthesis.