Treatment for Complex Elbow Fractures Involving Both a Hinged External Fixator and Internal Fixation

Xiao He
Xi'an Jiaotong University Department of Orthopaedic Surgery, Hong Hui Hospital

Quan Fen
Xi'an Jiaotong University

Jiarui Yang
Xi'an Jiaotong University

Yutian Lei
Xi'an Jiaotong University School of Medicine

Lisong Heng
Xi'an Jiaotong University

Yangjun Zhu
Xi'an Jiaotong University

Kun Zhang (zhangkunhhyy@163.com)
Xi'an Jiaotong University

Research Article

Keywords: Complex elbow fracture, Instability of elbow joint, External fixator, Internal fixation

Posted Date: May 17th, 2021

DOI: https://doi.org/10.21203/rs.3.rs-472685/v1

Abstract

Purpose

To explore the clinical outcomes of a hinged external fixator combined with internal fixation in treating complex elbow fractures.

Methods

This was a retrospective analysis of 42 cases of complex elbow fractures treated in our hospital from January 2015 to December 2019. Twenty-four cases were treated with a hinged external fixator combined with internal fixation (external fixation group), including 14 cases of the terrible triad of the elbow, 5 cases of posterior Monteggia fracture, and 5 cases of transolecranon fracture-dislocation. Eighteen cases were treated with adjustable brace fixation combined with internal fixation (brace group), including 11 cases of the terrible triad of the elbow, 3 cases of posterior Monteggia fracture and 4 cases of transolecranon fracture-dislocation. All patients were treated with open reduction and internal fixation, and the patients with postoperative elbow instability underwent fixation with a hinged external fixator or adjustable brace. Preoperative and surgical data were collected. At the last follow-up, elbow motion (extension-flexion, rotation) was recorded in the two groups of patients, and the Mayo Elbow Function Score (MEPS) was used to assess elbow joint function.

Results

All patients were followed up for 12 to 55 months (mean 28.2 months). The bones healed in all patients with fractures; the healing time was 12.9±1.9 weeks for the external fixation group and 12.2±1.8 weeks for the brace group, and the difference was not statistically significant (P 0.05). The average flexion-extension range of the elbow joint in the external fixation group was 128.8°±15.7°, the average rotation range of the forearm was 142.7° ± 21.5°, and the average MEPS score was 89.8±11.3 points (range 60-100 points); 14 cases were excellent, 7 cases were good, 2 cases were fair, and 1 case was poor. The excellent and good rate was 87.5%. In the brace group, the average flexion-extension range of the elbow joint was 110.3°±37.0°, the average rotation range of the forearm was 125.6°±30.5°, and the average MEPS score was 81.1±15.5 points (50-100 points); 8 cases were excellent, 5 cases were good, 2 cases were fair, and 3 cases were poor. The excellent and good rate was 72.2%. The difference between the two groups was statistically significant (P <0.05).

Conclusions

The combination of an external fixator and internal fixation in the treatment of unstable complex elbow fractures can better restore the stability and function of elbow joints than can adjustable brace fixation.

Background

Most complex elbow fractures are high-energy injuries, have complex injury mechanisms, are difficult to treat, have poor prognoses, and are associated with sequelae. Complex elbow joint fractures involve not only complex fracture types but also multiple fractures, including proximal ulna, radial head, coronal process and distal humerus fractures, and radial head and coronal process fractures are the most common. Moreover, the soft tissue around the joint is accompanied by severe contusion, and the ligament structure is severely damaged, which leads to the loss of bone and soft tissue stability in the elbow joint dislocation [1-5]. Nonoperative treatments for complex elbow fractures rarely yield satisfactory clinical results, and the incidence of related complications, including elbow instability, heterotopic ossification, joint stiffness and traumatic arthritis, is high, leading to a large burden on the life of patients. At present, most scholars believe that [6-8] complex elbow fractures need to be treated surgically to restore bone and soft tissue stability in the elbow joint and that functional elbow exercises should be performed as soon as possible after surgery. However, the goal of maintaining the stability of the elbow joint contradicts early functional exercise. Some studies [9] have shown that after an elbow stiffness release operation, the use of a hinged external fixator can allow early functional exercise by maintaining the stability of the elbow joint and can yield good medium- and long-term results. However, in most cases, complex elbow joint fixation is performed with a single fixation method, either simple internal fixation or simple external fixation. Some studies [10-12] have used hinged external fixators to treat patients with acute or chronic elbow instability and achieved good results. In clinical practice, patients with complex elbow fractures are still unstable after open reduction and internal fixation and are treated with a hinged external fixator or adjustable brace. Through a retrospective analysis of these cases, we explored the clinical efficacy of hinged external fixation combined with internal fixation in the treatment of complex elbow fractures.

Materials And Methods

Patients

Cases treated from January 2015 to December 2019 were reviewed. A total of 42 patients with complex elbow fractures still had elbow instability after open reduction and internal fixation and were treated with hinged external fixators or adjustable braces. The inclusion criteria were as follows: (1) patients initially diagnosed with a complex elbow fracture, (including the terrible triad of the elbow, a posterior Monteggia fracture and transolecranon fracture-dislocation); (2) patients who did not exhibit strong osseous or soft tissue stability after open reduction and internal fixation and need to undergo external fixation; (3) patients with a follow-up period of more than one year. The exclusion criteria were as follows: (1) open fractures; (2) multiple fractures of the same upper limb; (3) fractures in both upper limbs or those accompanied by nerve injury; and (4) severe medical diseases before surgery precluding surgical treatment. A total of 81 cases treated within the past 5 years were included, and 39 cases were excluded after screening. There were 14 cases of open fracture, 7 cases of multiple fractures in the same upper limb, 4 cases of fractures in both upper limbs, 4 cases of nerve injury, and 10 cases that were followed up for less than 12 months. Finally, 42 patients were included in this study (Fig 1). Twenty-four patients were treated with a hinged external fixator (external fixation group). These patients' ages ranged from 20-60

years (average 41.5±10.6 years), and there were 18 males and 6 females. There were 14 cases of the terrible triad of the elbow, 5 cases of posterior Monteggia fracture, and 5 cases of transolecranon fracture-dislocation; 15 cases involved the dominant side, including 8 cases of fall-related injuries, 14 cases of traffic-related injuries and 2 cases of sports-related injuries. The time from injury to the operation was 3-12 days (average 5.4±2.4 days). There were 18 patients treated with adjustable brace fixation (brace group). These patients' ages ranged from 20-60 years (average 41.2 ±9.8 years), and there were 13 males and 5 females. There were 11 cases of the terrible triad of the elbow, 3 cases of posterior Monteggia fracture, and 4 cases of transolecranon fracture-dislocation; 12 cases involved the dominant side, including 5 cases of fall-related injuries, 12 cases of traffic-related injuries and 1 case of a sports-related injury. The time from injury to the operation was 3-12 days (average 5.6±2.3 days) (Table 1). This study all methods were carried out in accordance with guidelines and regulations. This study was approved by the ethics committee of HongHui Hospital, Xi'an Jiaotong University, and all patients provided informed consent prior to participating. Typical case images have been allowed by participant to be displayed in the manuscript.

Surgical methods

All patients were treated with general anesthesia and placed in a supine position or lateral supine position, depending on the fracture type; an air bag tourniquet was placed at the root of the upper arm, The surgical site is routinely disinfected and covered with aseptic towels. The surgical methods presented by Pugh [13] and McKee [14] for the treatment of complex elbow fractures were used. The surgical approach used was the combined medial and lateral elbow approach or posterior median approach [15-17]. For the treatment of the fractures, the radial head fractures were fixed with countersunk nails or miniature plates. If severe comminution could not be repaired, artificial radial head replacement was performed. The olecranon fractures were fixed with a plate and screw or both a Kirschner wire and tension band. Coronal process fractures were fixed with lag screws, miniature plates or loop plates. Moreover, the articular capsule and medial and ligament were explored, in accordance with the injury mechanism and joint dislocation, and the structures of the articular capsule and ligament were sutured and repaired with thread anchors. After the completion of the above operation, omnidirectional passive movement of the elbow joint (flexion and extension, pronation, supination) was carried out to confirm the stability of the elbow joint, and the elbow joint was fixed with an external fixator or adjustable brace if there was still instability.

Installation of external fixture

The shoulder was abducted, and the forearm was placed on the operating table in a pronated position to determine the center of rotation. Standard positive and lateral films of the distal humerus were taken by a C-arm X-ray machine to determine the needle entry point. The lateral film focused on the center of the head of the humerus and the concentric circle of the pulley. A Kirschner needle with a diameter of 2.0 mm was slowly inserted from the outside to the inside from this point. The standard X-ray film of the front and side of the elbow joint was taken again to ensure it was located in the rotation center of the elbow

joint. The two movable arms of the external fixator were fixed on the lateral humerus and the ulnar crest with semithreaded nails. A small incision was made in the corresponding part of the skin, blunt separation was performed directly to the bone surface, and the nerves and other important tissues were protected. After drilling, two half-threaded needles were manually implanted at the distal and proximal ends. It was confirmed by X-ray that the tip of the needle passed through the medial cortex. The force line of the elbow joint was adjusted, the range of motion of the elbow joint was measured, the elbow was flexed to 90 °, the distance between the joints was maintained at 2 mm, and finally, the humerus end and the ulnar end of the external fixator were connected. Then, the bleeding was thoroughly stopped, the incision was rinsed with normal saline, a drainage tube was placed, the incision was sutured layer by layer, and the wound was wrapped with aseptic dressing.

Postoperative treatment

Antibiotics were routinely used to prevent infection within 24 hours after the operation. Metacarpophalangeal joint and interphalangeal joint movement was performed as soon as possible after the operation, as this movement can promote distal blood circulation and actively eliminate swelling. If the drainage volume was less than 30 ml within 24 hours after the operation, the drainage tube was removed. It was recommended that all patients take indomethacin enteric-coated tablets (25 mg, 3 times a day) for 4 weeks to prevent heterotopic ossification. Under the guidance of a professional rehabilitation physician, the brace group began functional exercises 3 days after the operation under the protection of the brace; the elbow joint was fixed at different flexion angles (30°, 90°, 130°) for 30 minutes each time, three times a day, and fixed in a straight position at night. The external fixator group began functional exercises 3 days after the operation. The elbow was fixed in a straight position at night, and the lock was released during the day so that passive flexion and extension exercises could be performed for a continuous 30 min period 3 times a day. When the edema of the elbow joint was alleviated, the frequency of exercise was increased appropriately, and the adjustable brace and external fixator were removed 6 ~ 8 weeks after the operation.

Evaluation project

Three days after the operation, the anterior and lateral X-ray films of the elbow joint and plain CT scan and three-dimensional reconstruction were reexamined to evaluate the repair of the fracture. The positive and lateral X-ray films of the affected limbs were reexamined at 1, 2, 3, 6 and 12 months after the operation to evaluate the extent of fracture healing. The operation time, the number of intraoperative fluoroscopies, the cost of hospitalization, the time needed for fracture healing, the incidence of postoperative complications and the range of motion of the elbow joint (range of extension and flexion, range of rotation) at the last follow-up were compared between the two groups. The function of the elbow joint was evaluated by the Mayo elbow performance score, (MEPS) [18] during the last follow-up. The scores for pain (45 points), range of motion (20 points), joint stability (10 points) and daily function (25 points) were categorized as follows: > 90 points was considered excellent, 75-89 points was considered good, 60-74 points was considered fair, < 60 points was considered poor.

Statistical analysis

Statistical analyses were performed using IBM SPSS, statistics version 22.0 (SPSS, Chicago, IL, USA). The count data are expressed as numbers (n), and the comparisons between the two groups were performed by the $\chi 2$-test; the measurement data are presented as M ±SD, and the comparisons between the two groups were performed by the t-test. P values < 0.05 were considered statistically significant.

Results

General results

The basic characteristics of the two groups of patients are shown in Table 1, and there were no significant differences in demographics between the two groups (P>0.05, Table 1). The surgical data of the two groups of patients are shown in Table 2. The average operation time and the average number of intraoperative fluoroscopies performed in the external fixation group were much higher than those in the brace group, and the difference between the two groups was statistically significant (P=0.003, P=0.000, Table 2). The average hospitalization cost in the brace group was much lower than that in the external fixator group, and the difference was statistically significant (P=0.000, Table 2).

Follow-up results

All patients were followed up for 12-55 months (mean 28.2 months). All patients exhibited bony healing, and no deep tissue infections or nerve injuries occurred. The fracture healing time in the external fixator group was slightly longer than that in the brace group. The difference between the two groups was not statistically significant (P>0.05, Table 2). At the last follow-up, the average flexion-extension range of the elbow and the average rotation range of the forearm in the external fixator group were much better than those in the brace group, and the difference was statistically significant (P=0.034, P=0.039, Table 3). In the external fixator group, the average MEPS score was 89.8±11.3, and in the brace group, the score was 81.1±15.5. The difference was statistically significant (P=0.042, Table 3). The curative effect in the external fixator group was excellent in 14 cases, good in 7 cases, fair in 2 cases and poor in 1 case. The excellent and good rate was 87.5%. In addition, the curative effect in brace group was excellent in 8 cases, good in 5 cases, fair in 2 cases and poor in 3 cases. The excellent and good rate was 72.2% (Fig 2). The typical case is shown in figure 4.

Complications

Redness and swelling of the skin around the pinhole and non-purulent exudate occurred in 3 cases (12.5%) in the external fixation group, and redness and swelling around the incision occurred in 1 case (5.6%) in the brace group. The cases in both groups were cured by oral antibiotics. Heterotopic ossification of the elbow joint occurred 3-6 months after the operation in 5 cases (20.8%) in the external fixation group and 3 cases (16.7%) in the brace group. All 8 cases were mild heterotopic ossification cases (Brooker1-2) [19] that did not require special treatment. According to Morrey et al. [20], an elbow

joint functional range of motion (flexion, extension or rotation) less than 100° indicates elbow joint stiffness, and there was 1 case (4.2%) in the external fixation group and 3 cases (16.7%) in the brace group (Fig 3). The elbow joint release operation was performed 6 months after the operation in all patients except 1 patient with severe stiffness in the brace group, who was treated conservatively.

Discussion

1. Elbow joint injury characteristics

The elbow joint is a compound joint that includes the humerus-ulnar joint, humeral-radial joint and upper ulnar-radial joint. It is the most flexible joint in the upper limb. The integrity of the bone and ligament is very important for the stability of the elbow joint. The repair of the coronal process, medial and lateral collateral ligament and olecranon notch of the ulna will directly affect the functional recovery of the elbow joint. Complex elbow joint fractures are high-energy injuries. When injured, the bony structure, peri-articular ligaments and joint capsules that maintain the stability of the elbow joint are damaged. When the elbow joint is severely injured, complications such as heterotopic ossification and stiffness of the elbow joint are prone to occur, which affects the functional recovery of the elbow joint after surgery and significantly reduces the patient's quality of life.

2. Treatment of complex elbow fractures

For the treatment of complex elbow fractures, because they are often accompanied by multiple structural injuries of the elbow joint, X-ray and CT scans and three-dimensional reconstruction must be performed before the operation to confirm the diagnosis, formulate the best treatment plan, and restore bone and soft tissue stability as much as possible during the operation. After the anatomical state of the elbow joint is restored and rigid internal fixation is applied during the operation, fracture redisplacement and elbow dislocation may still occur when there is instability. Some scholars have observed a better range of motion and curative effect in the elbow joint when a hinged external fixator was used. We used a hinged external fixator to maintain the stability of the elbow joint. In this study, 24 cases of complex elbow fractures were treated with internal fixation combined with a hinged external fixator. At the last follow-up, the excellent and good rate of elbow function evaluation was 87.5%, and the curative effect was considerable. The analysis shows that the hinged external fixator can not only help to maintain the concentric movement of the humeral ulnar joint but also maintain the stability of bone and soft tissue, allowing functional exercises to be performed early. In addition, early elbow rehabilitation training can prevent muscle atrophy, reduce joint adhesion and improve the curative effect. However, it should be done step by step and carefully to avoid internal fixation loosening and failure.

3. Application and characteristics of external fixator

External fixators have been used for more than 180 years, and they were first used to treat lower limb injuries. At present, they have been widely used to treat limb fractures [21-22], but they are rarely used in combination with internal fixation in the treatment of complex elbow joint fractures. For elbow joint

instability, Rao AJ et al [23] treated 20 patients with chronic elbow instability with a static external fixator. Although the stability of the elbow joint was restored, the secondary operation rate was 40%, and 25% of these operations were performed due to elbow stiffness. The reason for elbow stiffness may be that the elbow joint is fixed for a long time, which is contrary to the theory that early exercise should be performed after complex elbow joint operations, so a static external fixator is not suitable for the treatment of postoperative joint instability in complex elbow fractures. After performing a release procedure for severe traumatic elbow stiffness, Sun et al [24] used a hinged external fixator to not only provide stability for the elbow joint but also meet the requirements of early exercise, and the therapeutic effect was considerable. Most scholars believe that an important goal of the treatment of complex elbow fractures is to restore the absolute stability of the elbow joint as much as possible through surgery and start functional exercises as early as possible. However, complex elbow fractures involve a wide range of injuries and severe structural damage. Even if the tissue around the elbow joint is repaired, there is instability during functional exercise. In the past, plaster fixation was often used after operations, and with this method, the best time for functional exercise was missed. Biomechanical studies have shown that [25] a metal hinged external fixator can modify the joint space, effectively eliminate excessive friction on the joint surface, help protect the joint surface, and prevent reinjury of the bone and soft tissue after reduction. Volkov et al [26] found that the use of an external fixator after elbow joint operations can effectively preserve the height of the humerus-ulnar and humeral-radial joints, eliminate the axial pressure and shear force of the elbow joint, and effectively prevent displacement of the radial head and coronal process fractures. To date, a metal hinged external fixator has been used in the treatment of the terrible triad of the elbow, complex fractures and dislocation of the elbow joint, stiffness release procedures for the elbow joint and so on. It has shown its uniqueness. Iordens et al [27] treated 26 patients with complex elbow dislocation with a hinged external fixator, and satisfactory range of motion and functional results for the elbow joint were observed at the one-year follow-up. However, the requirements for the use of an external fixator are relatively strict, and there is a certain degree of technical difficulty. The goal of the method is to determine, restore and maintain the rotation center of the elbow joint, and these processes are considered difficult; the external fixator must be consistent with the rotation center of the elbow joint. Forthman et al [28] reported that if the external fixator is not applied properly, it will often have the opposite effect. A deviation of the rotation center of 5° will increase the motion resistance by 3.7 times, and a deviation of 10° can increase the motion resistance by as many as 7.1 times, thereby increasing the probability of the semithreaded needle loosening and breaking. In a study [29] of complications of hinged external fixators of the elbow joint, it was pointed out that the common complications were infection (including superficial and deep infection), loosening of the fixator, heterotopic ossification and so on. Some scholars have reported that [27,30] during functional exercise, fracture of the steel pin of the external fixator and malunion of the fracture can occur. In this study, there were 3 cases of infection in the external fixation stent group, all of which were superficial infections. There were 5 patients had mild heterotopic ossification, and there were no fixed steel needle fractures or fracture malunion cases. The excellent and good rate of elbow function at the last follow-up was 87.5%. We also found that the cost of the external fixator is high, which adds a certain economic burden on the patients. Second, to avoid the occurrence of infection, it is necessary to disinfect the fixed needle regularly, which increases the number of daily

nursing tasks. The elbow joint is an upper limb joint with a large range of motion and very complex kinematic mechanics, and functional recovery is very important for patients. Compared with the final good function of the elbow joint, we think that the above shortcomings are acceptable. The limitation of this study is that the study is a retrospective study, and the quality of the records was not necessarily the same because different medical staff members recorded the case data, which may affect the scientific reliability of the analysis results. Therefore, more prospective clinical trials are needed to verify these results. Second, the number of cases involved in the study was small, and the follow-up time was short, so it is necessary to assess more cases and include longer follow-up periods to ensure the accuracy of the results of the study.

In summary, for patients with joint instability after undergoing internal fixation of a complex elbow fracture, a metal-hinged external fixator can increase the elbow gap, restore the maximum controllable range of motion, effectively maintain the stability of the elbow, prevent the internal fixation failure, promote the recovery of elbow function and improve patient satisfaction with the clinical treatment.

Abbreviations

Mayo elbow performance score, (MEPS)

Declarations

Conflict of interest statement

No conflict of interest exits in the submission of this manuscript, and manuscript is approved by all authors for publication. I would like to declare on behalf of my co-authors that the work described was original research that has not been published previously, and not under consideration for published elsewhere, in whole or in part. All the authors listed have approved the manuscript that is enclosed.

Ethics approval and consent to participate

This study all methods were carried out in accordance with guidelines and regulations. This study was approved by the ethics committee of HongHui Hospital, Xi’an Jiaotong University, and all patients provided informed consent prior to participating.

Consent for publication

Not applicable

Availability of data and materials

All data generated or analyzed during this study are included in this published article.

Competing interests

No conflict of interest exits in the submission of this manuscript, and manuscript is approved by all authors for publication. I would like to declare on behalf of my co-authors that the work described was original research that has not been published previously, and not under consideration for published elsewhere, in whole or in part. All the authors listed have approved the manuscript that is enclosed.

Funding

1.Shaanxi Provincial Science and Technology Department 2017SF-197

2.Xi'an Science and Technology Plan Project 20YXYJ004(8)

Authors' contributions

HX Collected patient clinical cases, Statistics and analysis of patient clinical case information, Collected imaging data of typical cases, Completed case follow-up, and the major contributor in writing the manuscript.

FQ Collected patient clinical cases.

YJR Collected patient clinical cases.

LYT Statistics of patient clinical case information.

HLS Have a common contribution with HX.

ZYJ Completed case follow-up.

ZK Completed case follow-up and Financial assistance.

Acknowledgement

This work was supported by the Project of Shaanxi Provincial Science and Technology Department (2017SF-197) and Xi'an Science and Technology Plan Project (20YXYJ004(8)).

Authors' information (optional)

HX, MD, Resident, Research direction is orthopedics trauma, upper extremity and microsurgery.

FQ, MD, Resident, Research direction is orthopedics trauma, lower limbs.

YJR, MD, Resident, Research direction is orthopedics trauma, upper extremity.

LYT, MD, Resident, Research direction is bones and joints.

HLS, PhD, Deputy chief physician, Research direction is orthopedics trauma.

ZYJ, MD, chief physician, Research direction is orthopedics trauma.

ZK, PhD, chief physician, Research direction is orthopedics trauma.

References

1. Duckworth AD, Ring D, Kulijdian A, et al. Unstable elbow dislocations. J Shoulder Elbow Surg.2008; 17:281-6.
2. Jones ADR, Jordan RW. Complex Elbow Dislocations and the "Terrible Triad" Injury. Open Orthop J. 2017; 11:1394-1404.
3. Konrad GG, Kundel K, Kreuz PC, et al. Monteggia fractures in adults: long-term results and prognostic factors. J Bone Joint Surg Br. 2007; 89:354-360.
4. Kovacevic D, Vogel LA, Levine WN. Complex Elbow Instability: Radial Head and Coronoid. Hand Clin. 2015; 31:547-556.
5. Ramzi Z, Juanos Cabans J, Jennart H. Terrible triad of the elbow with an ipsilateral Essex-Lopresti injury: case report. J Surg Case Rep. 2020(6):rjaa103.
6. Xiao K, Zhang J, Li T, et al. Anatomy, definition, and treatment of the "terrible triad of the elbow" and contemplation of the rationality of this designation. Orthop Surg.2015; 7:13-18.
7. Doornberg J, Ring D, Jupiter JB. Effective treatment of fracture-dislocations of the olecranon requires a stable trochlear notch. Clin Orthop Relat Res.2004; 429:292-300.
8. Sanchez-Sotelo J, Morrey M. Complex elbow instability: surgical management of elbow fracture dislocations. EFORT Open Rev.2017; 1:183-190.
9. Zhou Y, Cai JY, Chen S, et al. Application of distal radius-positioned hinged external fixator in complete open release for severe elbow stiffness. J Shoulder Elbow Surg.2017; 26:e44-e51.
10. Zilkens C, Graf M, Anastasiadis A, et al. Treatment of acute and chronic elbow instability with a hinged external fixator after fracture dislocation. Acta Orthop Belg.2009; 75:167-74.
11. Yu JR, Throckmorton TW, Bauer RM, et al. Management of acute complex instability of the elbow with hinged external fixation. J Shoulder Elbow Surg.2007; 16:60-67.
12. Berendes S, Zilkens C, Anastasiadis A, et al. Additional external hinged fixator after open repositioning and internal fixation of acute elbow instability in non-compliant patients. Orthop Rev (Pavia). 2010; 2:e21.
13. Pugh DM, Wild LM, Schemitsch EH, et al. Standard surgical protocol to treat elbow dislocations with radial head and coronoid fractures. J Bone Joint Surg Am.2004; 86:1122-1130.
14. McKee MD, Pugh DM, Wild LM, et al. Standard surgical protocol to treat elbow dislocations with radial head and coronoid fractures. Surgical technique. J Bone Joint Surg Am.2005; 87:22-32.
15. Chan K, King GJ, Faber KJ. Treatment of complex elbow fracture-dislocations. Curr Rev Musculoskelet Med.2016; 9:185-189.
16. Zhou C, Xu J, Lin J, et al. Comparison of a single approach versus double approaches for the treatment of terrible traid of elbow-A retrospective study. Int J Surg.2018; 51:49-55.

17. Egol KA, Bianco I, Milone M, et al. Repair of Bado II Monteggia Fracture: Case Presentation and Surgical Technique. J Orthop Trauma.2019; 33:S13-S14.
18. Morrey BF, An KN.Functional evalution of the elbow[M]//Morrey BF. The elbow and its disorders[M]. Philadelphia:W.B.Saunders Co, 2000:74-83.
19. Brooker AF, Bowerman JW, Robinson RA, et al. Ectopic ossification following total hip replacement. Incidence and a method of classification. J Bone Joint Surg Am.1973; 55:1629-1632.
20. Morrey BF, Askew LJ, Chao EY. A biomechanical study of normal functional elbow motion. J Bone Joint Surg Am.1981; 63:872-877.
21. Tan V, Daluiski A, Capo J, et al. Hinged elbow external fixators: indications and uses. J Am Acad Orthop Surg.2005; 13:503-514.
22. Schep NW, De Haan J, Iordens GI, et al. A hinged external fixator for complex elbow dislocations: a multicenter prospective cohort study. BMC Musculoskelet Disord.2011; 12:130.
23. Rao AJ, Cohen MS. The use of static external fixation for chronic instability of the elbow. J Shoulder Elbow Surg.2019; 28:e255-e264.
24. Sun Z, Cui H, Ruan J, et al. What Range of Motion and Functional Results Can Be Expected After Open Arthrolysis with Hinged External Fixation For Severe Posttraumatic Elbow Stiffness? Clin Orthop Relat Res.2019; 477:2319-2328.
25. Sekiya H, Neale PG, O'Driscoll SW, et al. An in vitro biomechanical study of a hinged external fixator applied to an unstable elbow. J Shoulder Elbow Surg.2005; 14:429-432.
26. Volkov MV, Oganesian OV. Restoration of function in the knee and elbow with a hinge-distractor apparatus. J Bone Joint Surg Am.1975; 57:591-600.
27. Iordens GI, Den Hartog D, Van Lieshout EM, et al. Dutch Elbow Collaborative. Good functional recovery of complex elbow dislocations treated with hinged external fixation: a multicenter prospective study. Clin Orthop Relat Res.2015; 473:1451-1461.
28. Forthman C, Henket M, Ring DC. Elbow dislocation with intra-articular fracture: the results of operative treatment without repair of the medial collateral ligament. J Hand Surg Am.2007; 32:1200-1209.
29. Cheung EV, O'Driscoll SW, Morrey BF. Complications of hinged external fixators of the elbow. J Shoulder Elbow Surg.2008; 17:447-453.
30. Potini VC, Ogunro S, Henry PD, et al. Complications associated with hinged external fixation for chronic elbow dislocations. J Hand Surg Am.2015; 40:730-737.

Tables

Table 1. General data of two groups of patients before operation

Characteristics	HEF group (N=24)	Brace group(N=18)	p-value
Age, years (mean ± SD)	41.5±10.6	41.2±9.8	0.918
Gender (M/F)	18/6	13/5	1.000
BMI (kg/m²) (mean ± SD)	24.7±2.5	24.7±2.1	0.954
Injured side (Dominant/Non)	15/9	12/6	0.780
Injury mechanism			
Fall/ Traffic accident/ sports	8/14/2	5/12/1	0.848
Fracture type (TTE/PMF/TOD)	14/5/5	11/3/4	0.943
TFITS, (mean ± SD)	5.4±2.4	5.6±2.3	0.848

HEF Hinged external fixture, TTE terrible triad of the elbow, PMF Posterior Monteggia fracture, TOD Transolecranon fracture-dislocation, TFITS Time from injury to surgery.

Table 2.Operation and follow-up data of patients in two groups

Characteristics	HEF group (N=24)	Brace group(N=18)	p-value
Operation time, min, (mean ± SD)	136.7±20.3	118.3±15.4	0.003
Intraoperative fluoroscopy, times, (mean ± SD)	26.8±5.3	14.3±4.8	0.000
hospitalization cost, 10,000¥, (mean ± SD)	5.3±0.7	4.0±0.6	0.000
Fracture healing time, weeks, (mean ± SD)	12.9±1.9	12.2±1.8	0.263

HEF Hinged external fixture,

Table 3.The range of motion and function score of elbow joint in the two groups during the last follow-up

Characteristics	HEF group (N=24)	Brace group(N=18)	p-value
Extension (°) (mean ± SD)	4.6±5.1	8.6±7.2	0.040
Flexion (°) (mean ± SD)	133.3±13.2	118.9±31.5	0.049
ROM (flexion-extension) (°) (mean ± SD)	128.8±15.7	110.3±37.0	0.034
Pronation (°) (mean ± SD)	65.8±10.9	56.7±18.1	0.048
Supination (°) (mean ± SD	77.1±11.3	68.9±14.1	0.043
ROM (Rotation) (°) (mean ± SD)	142.7±21.5	125.6±30.5	0.039
MEPS points (mean ± SD)	89.8±11.3	81.1±15.5	0.042

HEF Hinged external fixture, ROM Range of motion; MEPS Mayo Elbow Performance Score.

Figures

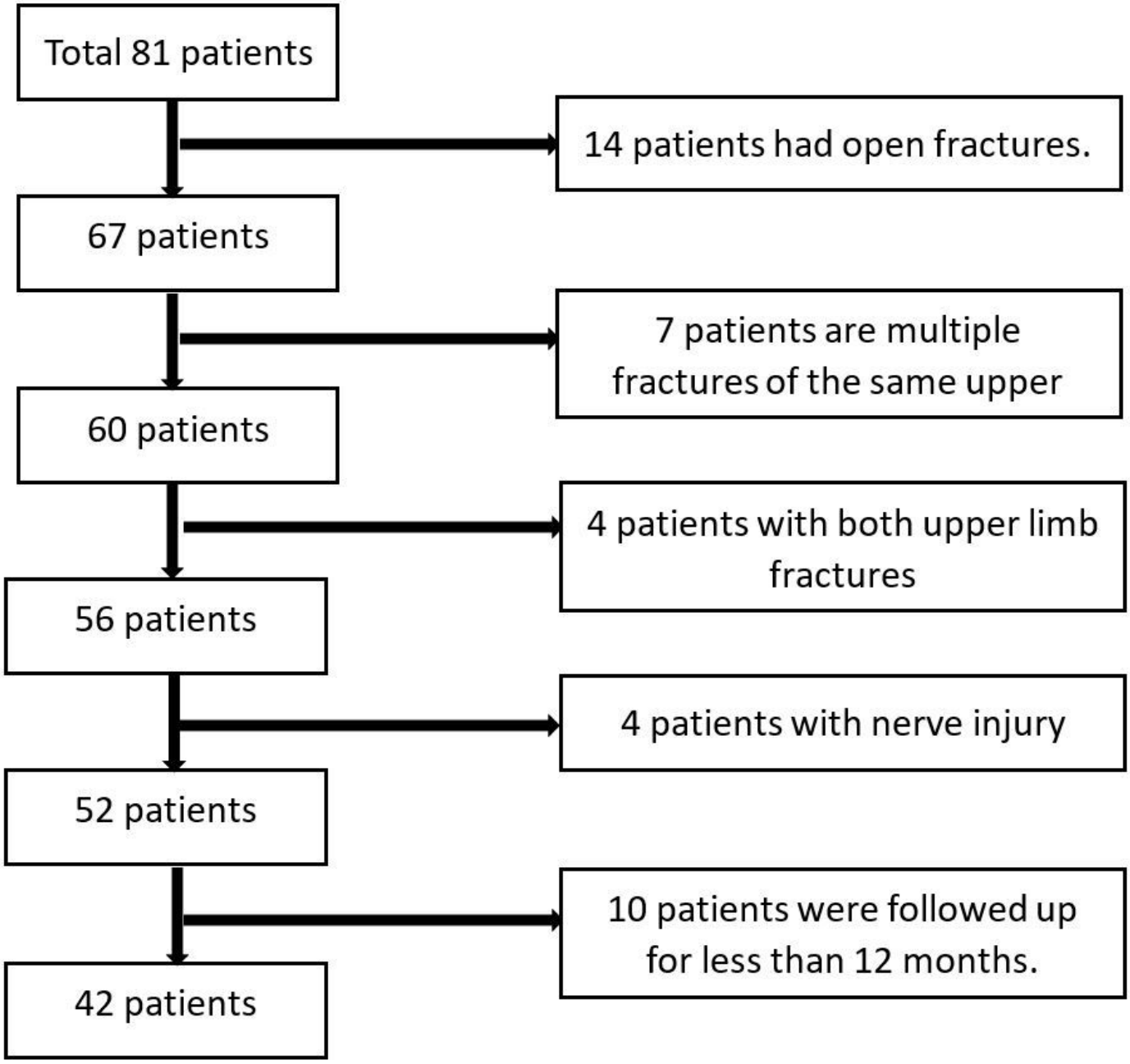

Figure 1

Screening of patients

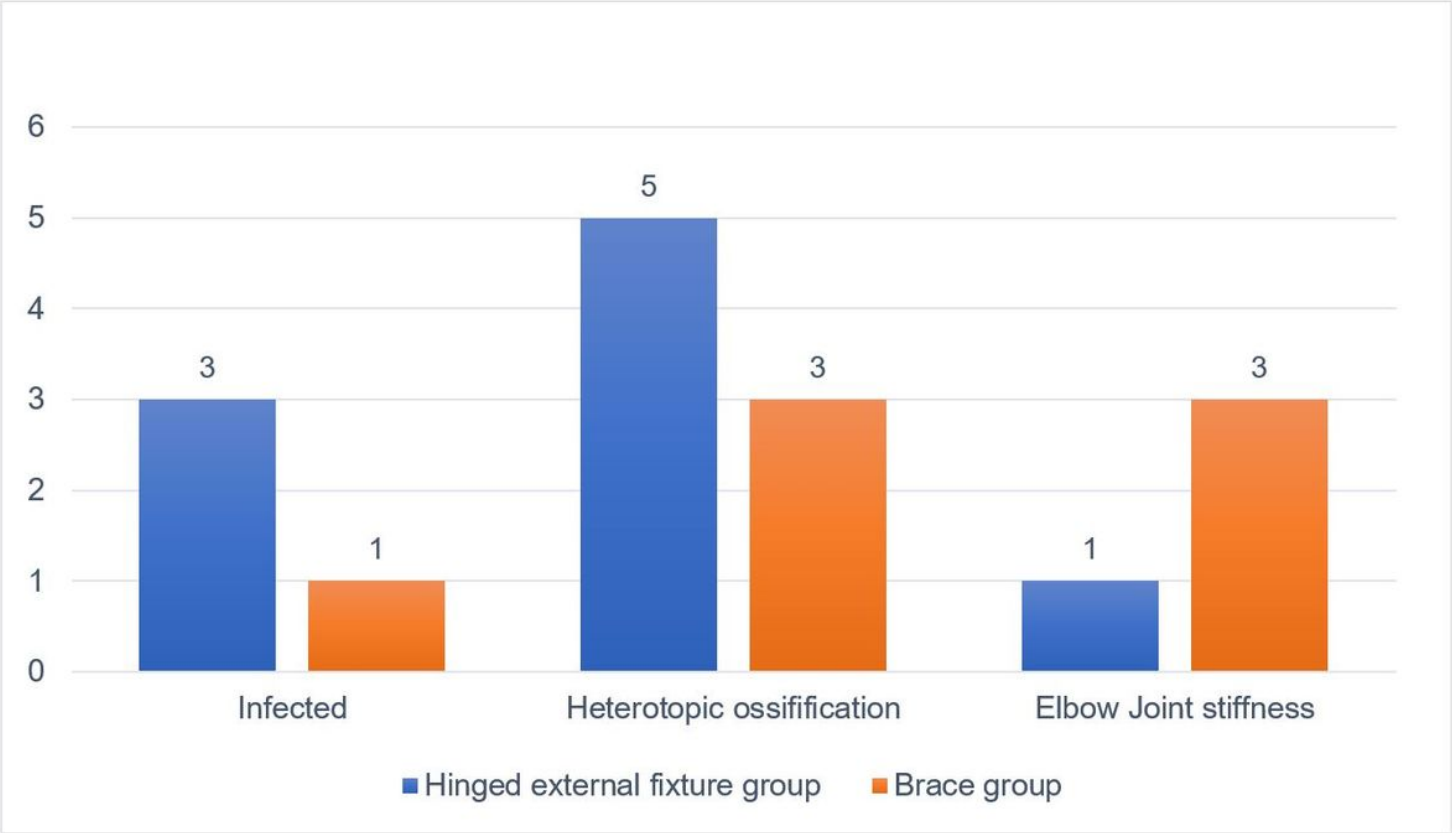

Figure 2

postoperative complications of two group

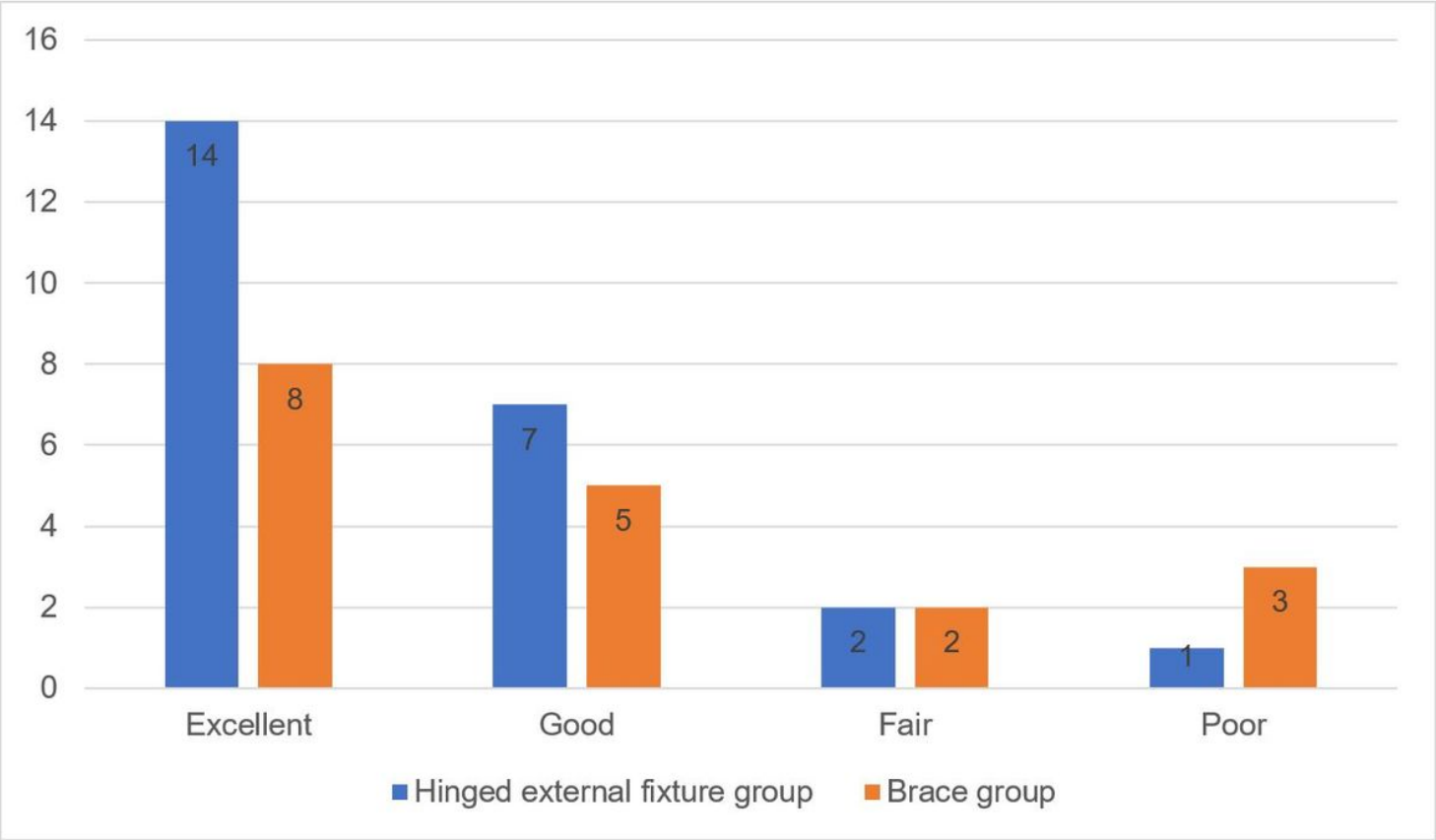

Figure 3

Functional evaluation of elbow joint

Figure 4

The typical case is a 42-year-old male who fell from a height and caused posterior Monteggia fracture of the right elbow joint (Jupiter Ⅱ A). a and b Preoperative anteroposterior and lateral view, c Preoperative 3D

reconstruction, d and e Post-operative anteroposterior and lateral view,f,g, h,i Functional appearance of the right elbow joint during the last follow-up.

Supplementary Files

This is a list of supplementary files associated with this preprint. Click to download.

- Fundproject.docx