Basic Reliable Intraperitoneal Extravesical Flexible (BRIEF) Technique in Robotic-Assisted Radical Nephroureterectomy With Excision of Bladder Cuff for Upper Tract Urothelial Carcinoma: Step by Step

sun fengze
Qindao University Medical College Affiliated Yantai Yuhuangding Hospital
Huibao Yao
Qindao University Medical College Affiliated Yantai Yuhuangding Hospital
Gang Wu
Qindao University Medical College Affiliated Yantai Yuhuangding Hospital
Dongxu Zhang
Qindao University Medical College Affiliated Yantai Yuhuangding Hospital
Di Wang
Qindao University Medical College Affiliated Yantai Yuhuangding Hospital
Hongwei Zhao
Qindao University Medical College Affiliated Yantai Yuhuangding Hospital
Youyi Lu
Qindao University Medical College Affiliated Yantai Yuhuangding Hospital
Jitao Wu (wjturology@163.com)
Qindao University Medical College Affiliated Yantai Yuhuangding Hospital

Research Article

Keywords: robotic surgery, laparoscopic surgery, upper tract urothelial carcinoma, nephroureterectomy

Posted Date: May 7th, 2021

DOI: https://doi.org/10.21203/rs.3.rs-472883/v1

Abstract

Objective

To describe a technique of robotic-assisted radical nephroureterectomy with excision of bladder cuff.

Method

In our institution, a total of 64 patients were enrolled in which 29 patients underwent robotic technique and 35 patients underwent laparoscopic technique. We compared perioperative data and tumor recurrence rates in two groups to confirm the advantages of robotic technique.

Result

All 64 patients finished their operation without converting operation. As the general conditions were no differences, the robotic group had less intraoperative blood loss (36.38±15.86ml verse 50.57±27.94ml, $P<0.05$), earlier ambulation (7.24±1.37h verse 9.14±2.03h, $P<0.05$), and shorter hospitalization time (3.55±0.69days verse 6.32±1.68days, $P<0.05$). And the visual analogue scale scores of the robotic group in 1h, 12h and 24h was lower than traditional laparoscopic group ($P<0.05$). And tumor recurrence and positive surgical margin were not difference between two groups ($P>0.05$).

Conclusion

Compared with laparoscopic method, the robotic technique has the advantages in postoperative recovery.

Introduction

Upper tract urothelial carcinoma (UTUC) accounting for 5%-7% of all urothelial cell carcinomas is more observed in renal pelvis compared with the ureter. [1] The standard treatment of UTUC is nephroureterectomy with bladder-cuff excision. Different approaches to access it has been described, including open, laparoscopic and robot-assisted technique. Some articles [2-4] have been published to reveal that laparoscopic radical nephroureterectomy with bladder-cuff excision (LRNU-BCE) is similar to the open technique in oncologic outcomes, since the first successful LRNU was reported by Clayman et al in 1991. [5] And the additional advantages of LRNU cover decreased postoperative narcotic use, shorter hospitalization time and more rapid convalescence [6-8]. However, the drawback to LRNU is obvious in the excision of the distal ureter and the reconstruction of the bladder. Because of these limitations, many other alternative and hybrid approaches are used to accomplish excision of the distal ureter and the reconstruction. [9-13]

Since the first robotic-assisted radical nephroureterectomy was reported in 2006, the extra degrees of freedom and articulation of the robotic wrists made it easy to isolate the distal ureter and reconstruct the bladder. Many centers devoted themselves to create some new techniques resecting the tumor totally and suturing the bladder and prove that robotic-assisted radical nephroureterectomy have similar outcomes to

laparoscopic technique. [14] Although the strategies of robotic systems in da Vinci Si system or da Vinci Xi system comes it true differently, it doesn't show different outcomes in two different systems. [15] Based on the summary of previous experiences and anatomical characteristics of the upper urinary tract in recent years, new method of nephroureterectomy named "basic reliable intraperitoneal extravesical flexible (BRIEF) technique" with bladder-cuff excision in da Vinci Si system has been applied in our hospital and achieved significant clinical effects. In this study, we introduce a new "BRIEF"technique which is more reliable and brief in some outcomes compared with LRNU-BCE.

Method And Patient

Clinical Data

The research is approved by Ethics Committee of Yantai Yuhuangding Hospital, and patients have signed the informed consent allowing us do this research. 64 patients with UTUC were selected from September 2019 to March 2021. 29 patients underwent robotic-assisted radical nephroureterectomy with excision of bladder cuff as robotic group, and 35 patients underwent laparoscopic radical nephroureterectomy with excision of bladder cuff as laparoscopic group, which were all operated by one same surgical team.

There were 15 males and 14 females aged between 56 and 84 years in robotic group. And 17 males and 18 females aged from 59 to 78 years were enrolled in laparoscopic group. 22 patients visited doctor because of painless gross hematuria symptoms in robotic group, and there were 23 patients in laparoscopic group. All patients were diagnosed by computed computed tumor-graphic urography (CTU) and magnetic resonance urography (MRU) to ensure the tumor location and tumor size before surgery. In robotic group, 12 patients were left lesions and 17 patients were right lesions, 19 had renal pelvis tumors while 10 patients had ureteral tumors higher than the crossing of the common iliac artery. In laparoscopic group, 14 patients were left lesions and 21 patients were right lesions, 23 had renal pelvis tumors while 12 patients had ureteral tumors higher than the crossing of the common iliac artery. And patients were also accepted cystoscopy to eliminated possibility of bladder tumor. Renal dynamic imaging and glomerular filtration rate (GFR) tests were adopted to evaluate contralateral renal function. And American Society of Anesthesiologists (ASA) score was 2.38±0.62 in robotic group, which was not statistical difference compared with laparoscopic group (2.49±0.56). There was not statistically significant difference in general conditions as gender, age, BMI, hematuria symptom, tumor size, tumor location, tumor stage and ASA between two groups ($P>0.05$).

Excluding criteria

Patients were excluded as following criteria: patients who suffered bilateral renal and ureter tumor, tumor with node metastasis, tumor located in the ureter lower than the crossing of the common iliac artery, bladder carcinoma, simultaneous pelvis or ureter tumor were not counted.

Surgical Technique

Robotic Group

A catheter was inserted into the urethra after general anesthesia. With the lesion side up, firstly, the patient kept lateral decubitus position in 70°. And the waist bridge was raised when the patient's navel located in the middle of operating bed. Then the assistant sterilized operation region and connected the equipment.

On the first step (taking UTUC at the right side as an example, Fig. 1A), the initial 12 mm camera port (port A) was placed just lateral to musculus rectus abdominis and parallel to the navel level. The first 8 mm working port (port B) was placed 2cm below the costal margin lateral to the musculus rectus abdominis to ensure enough working space. The second working port (port C) was placed about 2 cm above to the anterior superior iliac spine. A 12 mm assistant port (port D) was placed above the navel to avoide interference in the step two. The robot was docked over the back of the patient on the head side (Fig.1B). After entering the abdominal cavity, we incised the paracolic sulci and posterior peritoneum to find ureter (Fig. 2A). As the right side, to expose renal hilum, we usually followed the ureter to find it. On the left side, we followed the ureter and gonadal vein to find the renal hilum and expose renal vein and artery as the gonadal vein inserted renal vein. Once the renal hilum was identified, the renal vein was dissociated with other connective tissue and clipped with three Hem-o-lock clips. The distal vein between two hem-o-lock clips was cut with scissors to identify and release the renal artery, which was processed in a similar way (Fig. 2B). In order to prevent bleeding and lymphatic leakage, bipolar fulguration and clips were crucial. As soon as the renal hilum was controlled, the ureter was clipped below the primary tumor site with a hem-o-lock clip to prevent the tumor from spreading during renal mobilization and excision of the kidney. Then kidney and perirenal fat were completely free without adrenal gland. As we finished the isolation of the kidney and upper ureter, the second step exposing the lower ureter and vesico-ureteric junction was carried out. On the second step, one experienced circuit nurse changed the patient's position from 70° to 50°, as the adjustment of the patient's position could improve the comfort of the surgical operation. The third working port (port E) was placed about 5cm below to the navel after nephrectomy (Fig. 1C). Then the robot was changed on the foot side over the back of patient (Fig. 1D). And the assistant changed the robotic working arms from port B and port C to port C and port E, while the camera port was stable. Afterwards, lower ureter was continued to be dissected till the level of the vesico-ureteric junction. The goal of the second step was to dissect the distal ureter, vesico-ureteric junction, and bladder cuff clearly. Periureteric lymphatics and blood vessels to the ureter were fulgurated with bipolar energy to prevent bleeding and seepage. Then pulling the ureter (Fig. 2C) appears the bladder wall to cephalic side and cutting the bladder wall (Fig. 2D,2E). Then the distal ureter and bladder cuff were removed (Fig. 2F). And bladder opening was closed in a running fashion using the previously placed barbed suture in a double layer (Fig. 2G,2H). Bladder closure was checked with instillation of saline through the catheter, to observe the presence or absence of urine leakage. This was an extremely important step if postoperative intravesical chemotherapy was contemplated to prevent recurrence. Then the kidney and ureter were placed in specimen bag with a diameter of 130mm. The pneumoperitoneum pressure was change to 5mmHg to observe the active bleeding of wound. A 6 cm (5-7cm)-wide incision in the midline inferior to the navel was made to take out the surgical specimens. After pulling out the trocar B, a F20 porous

drainage tube was placed at the pelvic cavities. The incision on the abdominal wall was sutured, stapled, or adhered.

Laparoscopic Group

After general anesthesia, the patient was placed in lateral decubitus position with lesion side up. The assistant finished disinfection and placed the ports. Port a was placed lateral of the navel, port b was placed in the intersection point of navel level and anterior axillary line, port c was placed at lateral to musculus rectus abdominis above navel and port d was placed blow port a (Fig. 3). Firstly, the renal hilus should be found through dissociate connected tissue. After clipping and cutting the renal vein and artery, the kidney was completely freed. Then the ureter was clamped by hem-o-lock and dissociated as possible as we could. Then they change their position from head side to foot side, which was beneficial to remove the distal ureter dissection and connected bladder wall. And the bladder was sutured with 2-0 barbed suture. Bladder closure was checked by instilling saline. If urine leakage was not observed, the drainage tube was placed and the incision was closed step by step.

Follow Up

All patients followed until March 2021 received intravesical instillation therapy 2 weeks after surgery, once a week for 4~8 times and then once a month for a total of 1 year. According to EUA guidelines, all patients underwent cystoscopy once 3 months for 1 year, thereafter once a year. And CTU examination was performed at intervals of every 6 months for 2 years after surgery, and then once annually.

Statistical analysis

The corresponding indicators of the two groups were recorded and compared, and then the data were analyzed by using the SPSS 25.0 software. Continuous variables were analyzed by T test, while categorical variables were analyzed by chi-square test or Fisher’s exact test. As P-value less than 0.05, we considered the comparation of two group was statistically significant difference

Results

<p>All patients finished their operations completely without converting open operation. In two groups (Table. 1), no complications and second hospital admissions caused by postoperative complication were observed after leaving hospital. And the general conditions were not significant difference in age, gender, BMI, tumor location, tumor size and ASA (P>0.05). In perioperative period, although the operation time were not significant differences (P>0.05) in two groups, intraoperative blooding loss was less in robotic group (P<0.05), which means exquisite operation. And the visual analogue scale (VAS) scores of robotic groups in 1h, 12h and 24h was lower compared with traditional laparoscopic group (P<0.05), which was also beneficial from exquisite technique. And the recovery was better in robotic group, which showed in shorter hospitalization time, earlier ambulation (P<0.05). But there was not difference in postoperative recovery time of gastrointestinal function as the pathways of two groups were

intraperitoneal. As all patients received intravesical instillation therapy 2 weeks after surgery routinely. In our follow-up time (12.17months vs 13.23 months, P>0.05), which the median time to bladder tumor and other recurrence were 8.7 months according to previous study [16], there were no differences in tumor recurrence and positive surgical margin (P>0.05). The result showed that our robotic “BRIEF” technique was more reliable in exquisite operation and fast recovery compared with traditional LRNU-BCE.</p>

Discussion

The incidence of UTUC is lower than bladder tumor, accounting for 5%-7% in urothelial carcinoma [1]. Radical nephroureterectomy with excision of bladder cuff in open technique was the gold standard treatment of UTUC. As the first successful LRNU was reported [5], more and more surgeon devoted themselves to explore new technique to achieve better outcomes. With the popularization of laparoscopic technique and advances in minimally invasive intervention, the standard surgical method of UTUC shifted from open technique to laparoscopic technique. For advanced patients, some researches indicated that open surgery was better than LRNU. [17-20] But some researches have proved that LRNU is similar to the open technique in oncologic outcomes [2-4]. And compared with open technique, laparoscopic technique is charactered by minimally invasive and exquisite operation, which contributes to reduce intraoperative blood loss, decrease injury of adjacent tissue, shorten hospitalization time, achieve rapid recovery and reduce the occurrence rate of perioperative complications. Urologists are indicated to choose laparoscopic technique in UTUC. However, the insufficiencies of LRNU are significant in management of distal ureter tract and bladder cuff due to influence of the angle space.

With development of robotic technique, laparoscopic technique scales new heights. Compared with traditional laparoscopic technique, robotic laparoscope can magnify the surgical site clearly, which is basal to accomplish more exquisite operation. And the operative pathway is intraperitoneal exploring better view of operation and anatomical mark sufficiently, which is friendly to abecedarian compared with retroperitoneal pathway. At intraoperative period, the surgeon can adjust the camera optionally to achieve their thoughts which can reduce combination miss with assistant in traditional laparoscopic technique. After excision of bladder cuff, the urine in bladder remains in bottom to achieve the goal of preventing leakage of urine as the patient keeps lateral decubitus position. The suture of bladder, which is finished by flexible robotic arms, becomes more compact to achieve the goal of mucosa to mucosa. As the surgeon and assistant can finish the operation in sitting, their energy is spent less in position to make them more concentrated in operation. And in our research, it can be found that robotic group are shorter postoperative bedridden time and hospitalization time, which are beneficial for their recovery.

And many researches have reported their methods of UTUC in robotic-assisted radical nephroureterectomy with excision of bladder cuff, especially single robotic-docking technique, which could eliminate the redocking time to shorten operation time. According to the research of Pugh et al [21], although single robotic-docking technique can reduce the operative time finitely, robotic-redocking technique is more superior in excision of distal ureter and exploration of pelvic anatomy which is core of

this operation. And our experienced circuit nurses can reduce time of re-docking robot to ten minutes. Sometimes, economic element is crucial for patients to choose the operative method. Some researches [22-24] introduce their single robotic-docking method with three robotic arms, which increases economic press of patients. But our technique only needs two robotic arms which is prone to popularize. And Zargar et al [25] explored single robotic-docking method of two robotic arms, but it could be limited by short lateral edge of the rectus muscle decided by height of patients. At present, the single robotic-docking technique and two robotic-docking technique can be selected optionally due to the fact of patient.

It could be attention that lymph node dissection (LND) was not routinely performed in our center, although some researches stated that LND was better in oncology outcomes [26,27], the curative role of LND remains controversial for UTUC [28,29], which could be analyzed by more clinical data and research afterward. And intravesical instillation therapy timely and normatively after operation could reduce the incidence of bladder recurrence [30-32]. And our experience is limited by a small number of cases in one institution. However, our technique is repeatable for abecedarian to make larger cohort with longer follow-up to evaluate effectiveness of our technique.

Conclusion

In summary, our article describes a basic reliable intraperitoneal extravesical flexible technique in robotic-assisted radical nephroureterectomy with excision of bladder cuff which can decrease intraoperative blood loss, shorten postoperative bedridden time and hospitalization time compared with laparoscopic technique. As the postoperative outcomes and economy aspect, our technique deserves popularization to benefit more patients.

Declarations

Acknowledgments

All authors have no acknowledgements to disclose.

Funding Information

This work was supported by grants from the National Nature Science Foundation of China (Nos. 81870525; 81572835), Taishan Scholars Program of Shandong Province (No.tsqn201909199).

Availability of data and materials

The data used and analyzed in this research can be obtained from the corresponding author with a reasonable request.

Ethics approval and consent to participate

All patients in our research provided informed consent before the treatment.

Our study was approved by ethics committee of the Affiliated Yantai Yuhuangding Hospital of Qingdao University and with the 1964 Helsinki Declaration and its amendments.

Author Disclosure Statement

The authors declare that they have no competing interests.

Consent for publication

Not applicable.

Author Contributions

WJT is the corresponding author of the article. SFZ is the first author. YHB is the co-first author. WJT designed the research, interpreted the data, and revised the paper. SFZ, WG, YHB, ZDX, WD, ZHW and LYY performed the data extraction and drafted the paper. All authors read and approved the final manuscript.

References

1. Melamed M R,Reuter V E,Pathology and staging of urothelial tumors of the kidney and ureter.[J] .Urol Clin North Am, 1993, 20: 333-47.
2. Ni Shaobin,Tao Weiyang,Chen Qiyin et al. Laparoscopic versus open nephroureterectomy for the treatment of upper urinary tract urothelial carcinoma: a systematic review and cumulative analysis of comparative studies.[J] .Eur Urol, 2012, 61: 1142-53.
3. Favaretto Ricardo L,Shariat Shahrokh F,Chade Daher C et al. Comparison between laparoscopic and open radical nephroureterectomy in a contemporary group of patients: are recurrence and disease-specific survival associated with surgical technique?[J] .Eur Urol, 2010, 58: 645-51.
4. Waldert Matthias,Remzi Mesut,Klingler Hans Christoph et al. The oncological results of laparoscopic nephroureterectomy for upper urinary tract transitional cell cancer are equal to those of open nephroureterectomy.[J] .BJU Int, 2009, 103: 66-70.
5. Walton Thomas J,Novara Giacomo,Matsumoto Kazumasa et al. Oncological outcomes after laparoscopic and open radical nephroureterectomy: results from an international cohort.[J] .BJU Int, 2011, 108: 406-12.
6. Berger Andre,Haber Georges-Pascal,Kamoi Kazumi et al. Laparoscopic radical nephroureterectomy for upper tract transitional cell carcinoma: oncological outcomes at 7 years.[J] .J Urol, 2008, 180: 849-54; discussion 854.
7. Stewart Grant D,Humphries Katie J,Cutress Mark L et al. Long-term comparative outcomes of open versus laparoscopic nephroureterectomy for upper urinary tract urothelial-cell carcinoma after a median follow-up of 13 years*.[J] .J Endourol, 2011, 25: 1329-35.
8. Walton Thomas J,Novara Giacomo,Matsumoto Kazumasa et al. Oncological outcomes after laparoscopic and open radical nephroureterectomy: results from an international cohort.[J] .BJU Int,

2011, 108: 406-12

9. Eun Daniel,Bhandari Akshay,Boris Ronald et al. Concurrent upper and lower urinary tract robotic surgery: strategies for success.[J] .BJU Int, 2007, 100: 1121-5.
10. Fang Zhenqiang,Li Longkun,Wang Xiangwei et al. Total retroperitoneal laparoscopic nephroureterectomy with bladder-cuff resection for upper urinary tract transitional cell carcinoma.[J] .J Invest Surg, 2014, 27: 354-9.
11. Hemal Ashok K,Stansel Irina,Babbar Paurush et al. Robotic-assisted nephroureterectomy and bladder cuff excision without intraoperative repositioning.[J] .Urology, 2011, 78: 357-64
12. Nanigian Dana K,Smith William,Ellison Lars M,Robot-assisted laparoscopic nephroureterectomy.[J] .J Endourol, 2006, 20: 463-5; discussion 465-6.
13. Park Sung Yul,Jeong Wooju,Ham Won Sik et al. Initial experience of robotic nephroureterectomy: a hybrid-port technique.[J] .BJU Int, 2009, 104: 1718-21.
14. Rose K,Khan S,Godbole H et al. Robotic assisted retroperitoneoscopic nephroureterectomy – first experience and the hybrid port technique.[J] .Int J Clin Pract, 2006, 60: 12-4.
15. Hu Jim C,Silletti Joseph P,Williams Stephen B,Initial experience with robot-assisted minimally-invasive nephroureterectomy.[J] .J Endourol, 2008, 22: 699-704.
16. Patel Manish N,Hemal Ashok K,Does Advancing Technology Improve Outcomes? Comparison of the Da Vinci Standard/S/Si to the Xi Robotic Platforms During Robotic Nephroureterectomy.[J] .J Endourol, 2018, 32: 133-138.
17. Tan Wei Shen,Feber Andrew,Sarpong Rachael et al. Who Should Be Investigated for Haematuria? Results of a Contemporary Prospective Observational Study of 3556 Patients.[J] .Eur Urol, 2018, 74: 10-14.
18. Rouprêt Morgan,Babjuk Marko,Compérat Eva et al. European Association of Urology Guidelines on Upper Urinary Tract Urothelial Carcinoma: 2017 Update.[J] .Eur Urol, 2018, 73: 111-122.
19. Bariol Simon V,Stewart Grant D,McNeill S Alan et al. Oncological control following laparoscopic nephroureterectomy: 7-year outcome.[J] .J Urol, 2004, 172: 1805-8.
20. Liu Wentao,Wang Yinhuai,Zhong Zhaohui et al. Transperitoneal versus retroperitoneal laparoscopic nephroureterectomy in the management of upper urinary tract urothelial carcinoma: a matched-pair comparison based on perioperative outcomes.[J] .Surg Endosc, 2016, 30: 5537-5541.
21. Pugh Joseph,Parekattil Sijo,Willis Daniel et al. Perioperative outcomes of robot-assisted nephroureterectomy for upper urinary tract urothelial carcinoma: a multi-institutional series.[J] .BJU Int, 2013, 112: E295-300.
22. Taylor Benjamin L,Scherr Douglas S,Robotic Nephroureterectomy.[J] .Urol Clin North Am, 2018, 45: 189-197.
23. Lee Ziho,Cadillo-Chavez Ronald,Lee David I et al. The technique of single stage pure robotic nephroureterectomy.[J] .J Endourol, 2013, 27: 189-95.

24. Hemal Ashok K,Stansel Irina,Babbar Paurush et al. Robotic-assisted nephroureterectomy and bladder cuff excision without intraoperative repositioning.[J] .Urology, 2011, 78: 357-64.
25. Zargar Homayoun,Krishnan Jayram,Autorino Riccardo et al. Robotic nephroureterectomy: a simplified approach requiring no patient repositioning or robot redocking.[J] .Eur Urol, 2014, 66: 769-77.
26. Abe Takashige,Kondo Tsunenori,Harabayashi Toru et al. Comparative study of lymph node dissection, and oncological outcomes of laparoscopic and open radical nephroureterectomy for patients with urothelial carcinoma of the upper urinary tract undergoing regional lymph node dissection.[J] .Jpn J Clin Oncol, 2018, 48: 1001-1011.
27. Choo Min Soo,Yoo Sangjun,Yuk Hyeong Dong et al. Survival Benefits Based on the Number of Lymph Nodes Removed during Radical Nephroureterectomy for Upper Tract Urothelial Carcinoma: Systematic Review and Meta-Analysis.[J] .J Clin Med, 2020, 9: undefined.
28. Nazzani Sebastiano,Mazzone Elio,Preisser Felix et al. Rates of lymph node invasion and their impact on cancer specific mortality in upper urinary tract urothelial carcinoma.[J] .Eur J Surg Oncol, 2019, 45: 1238-1245.
29. Roscigno Marco,Brausi Maurizio,Heidenreich Axel et al. Lymphadenectomy at the time of nephroureterectomy for upper tract urothelial cancer.[J] .Eur Urol, 2011, 60: 776-83.
30. O'Brien Tim,Ray Eleanor,Singh Rajinder et al. Prevention of bladder tumours after nephroureterectomy for primary upper urinary tract urothelial carcinoma: a prospective, multicentre, randomised clinical trial of a single postoperative intravesical dose of mitomycin C (the ODMIT-C Trial).[J] .Eur Urol, 2011, 60: 703-10.
31. Wu Wen-Jeng,Ke Hung-Lung,Yang Yi-Hsin et al. Should patients with primary upper urinary tract cancer receive prophylactic intravesical chemotherapy after nephroureterectomy?[J] .J Urol, 2010, 183: 56-61.
32. Ito Akihiro,Shintaku Ichiro,Satoh Makoto et al. Prospective randomized phase II trial of a single early intravesical instillation of pirarubicin (THP) in the prevention of bladder recurrence after nephroureterectomy for upper urinary tract urothelial carcinoma: the THP Monotherapy Study Group Trial.[J] .J Clin Oncol, 2013, 31: 1422-7.

Tables

Table. 1 Relevant preoperative, perioperative, and postoperative data in two groups.

	Robotic Group(n=35)	Laparoscopic Group(n=43)	P value
Age (year) (x±s)	68.79±6.549	69.17±5.084	0.796
Gender (n)			
Male	15	17	
Female	14	18	0.802
BMI (x±s)	24.83±2.08	24.55±1.95	0.585
Hematuresis□n□			
YES	22	23	
NO	7	12	0.376
Tumor (lift/right) (n)			
Lift	12	14	
Right	17	21	0.911
Tumor location (n)			
Renal pelvis	19	23	
Ureter	10	12	0.987
Tumor stage (T1/T2/T3) (n)			
T1	18	23	
T2	9	9	
T3	2	3	0.883
ASA(±s)	2.38±0.62	2.49±0.56	0.48
Maximal tumor size (cm) (x±s)	2.34±0.53	2.174±0.52	0.221
Operation time (min) (x±s)	121.69±10.41	116.43±13.32	0.088
Intraoperative blood loss (ml) (x±s)	36.38±15.86	50.57±27.94	0.014*
Postoperative ambulation (h) (x±s)	7.24±1.37	9.14±2.03	<0.001*
Postoperative pain score(x±s)			
1h after surgery	4.52±0.74	5.71±0.86	<0.001*
12h after surgery	2.97±0.68	3.51±0.78	0.004*
24h after surgery	1.72±0.59	2.31±0.63	<0.001*

48h after surgery	1.28±0.46	1.37±0.49	0.426
Recovery of bowel function (h) (x±s)	7.09±1.20	7.17±1.47	0.802
Hospital stay(days) (x±s)	3.55±0.686	6.32±1.68	<0.001*
Follow-up(month) (x±s)	12.17±3.67	13.23±3.99	0.279
Positive surgical margin (n) (x±s)	0/29	1/35	0.359
Recurrence(n)			
Bladder recurrence	1/29	3/35	0.399
Local/retroperitoneal	1/29	2/35	0.669

* Statistically significant

Figures

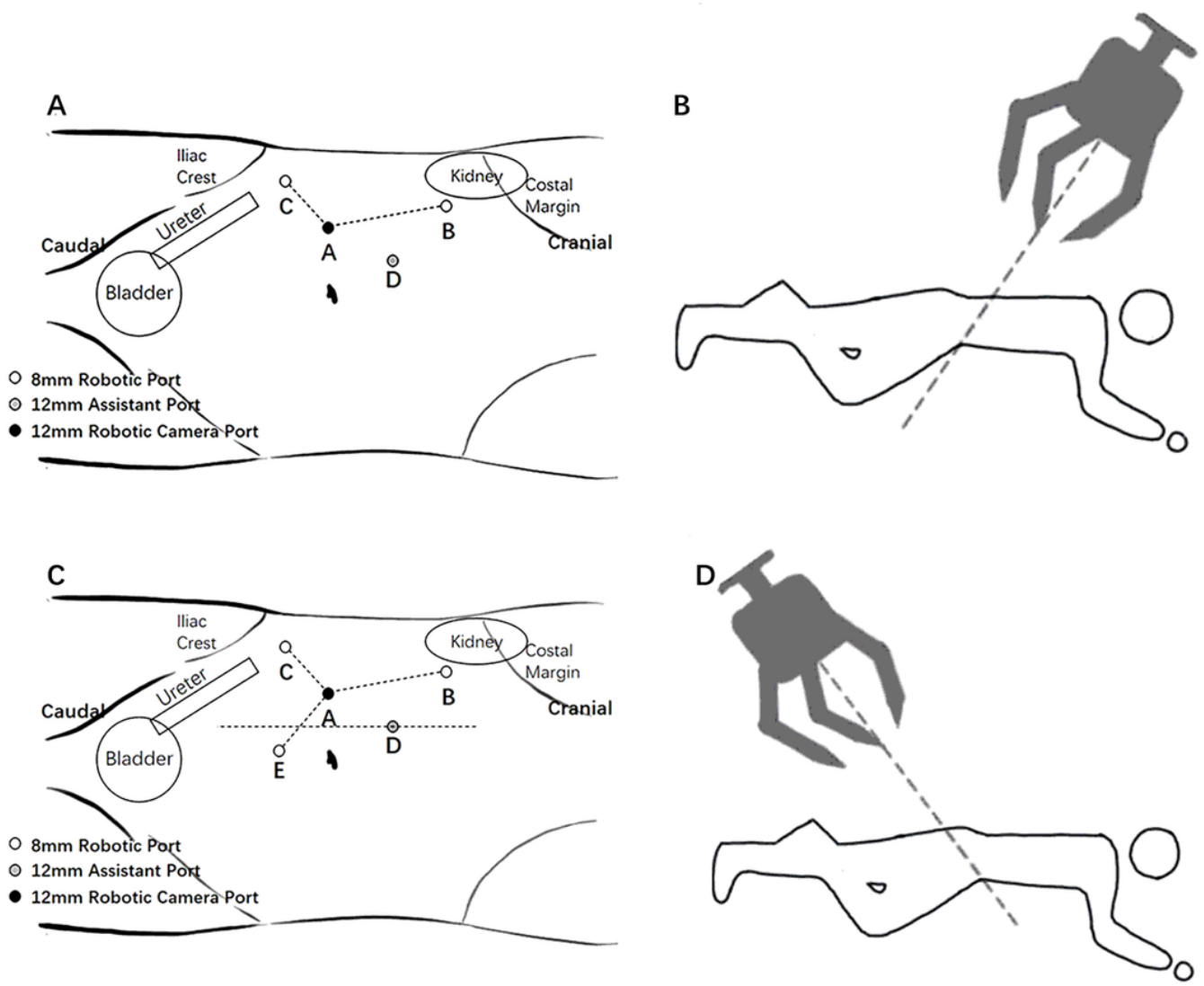

Figure 1

Surgical technique of patient. (A), port placement of RRUN in first step; (B), surgical robot position in first step; (C), port E placement in second step; (D), surgical robot position in second step.

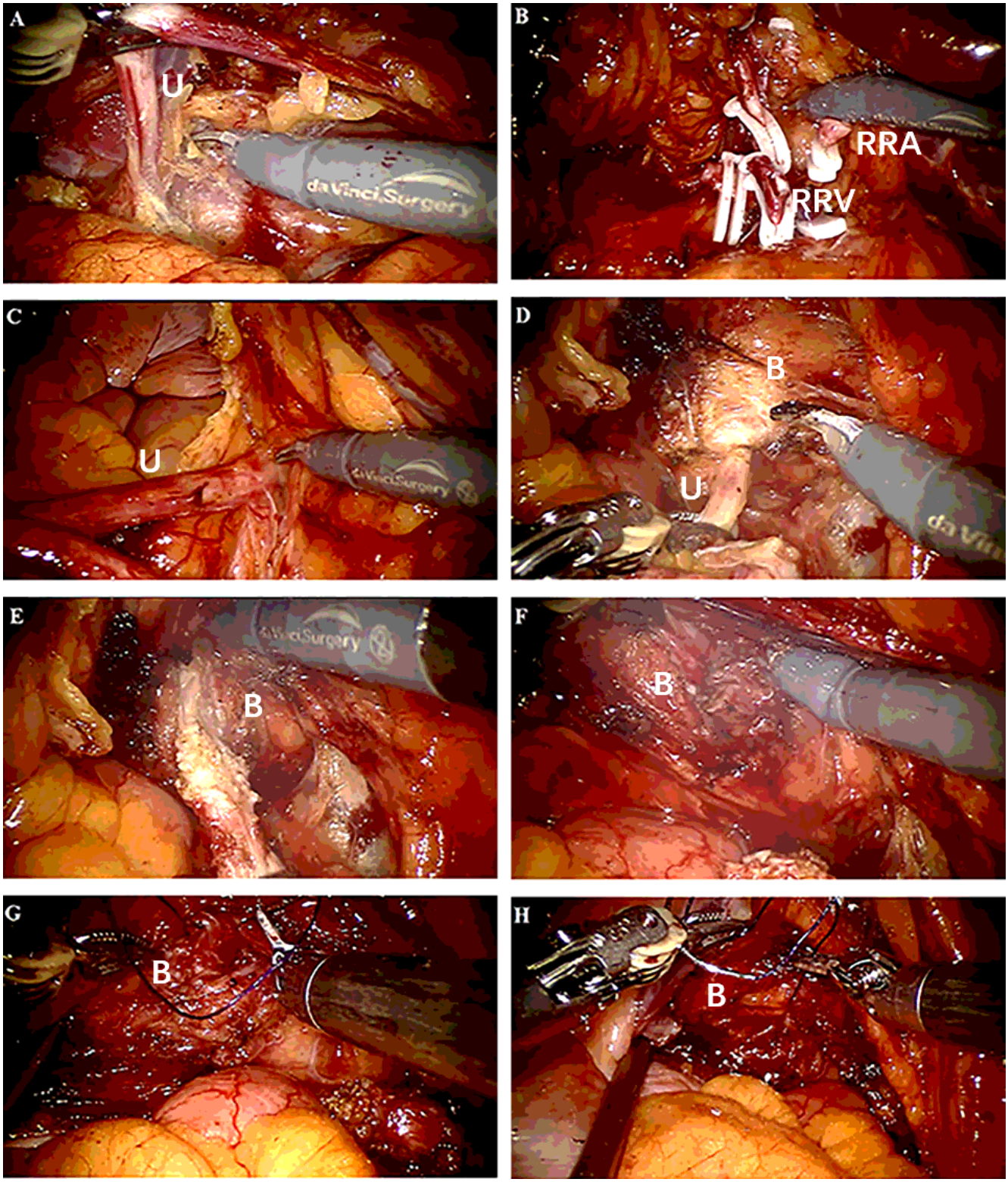

Figure 2

Image of surgical procedure. (A), detection of right ureter; (B), isolation and ligation of renal artery and vein; (C), detection of ureter in second step; (D, E), dissection of ureter and bladder cuff; (F), the bladder after removement of bladder cuff; (G, H), suturing the bladder. RRA, right renal artery; RRV, right renal vein; U, ureter; B, bladder

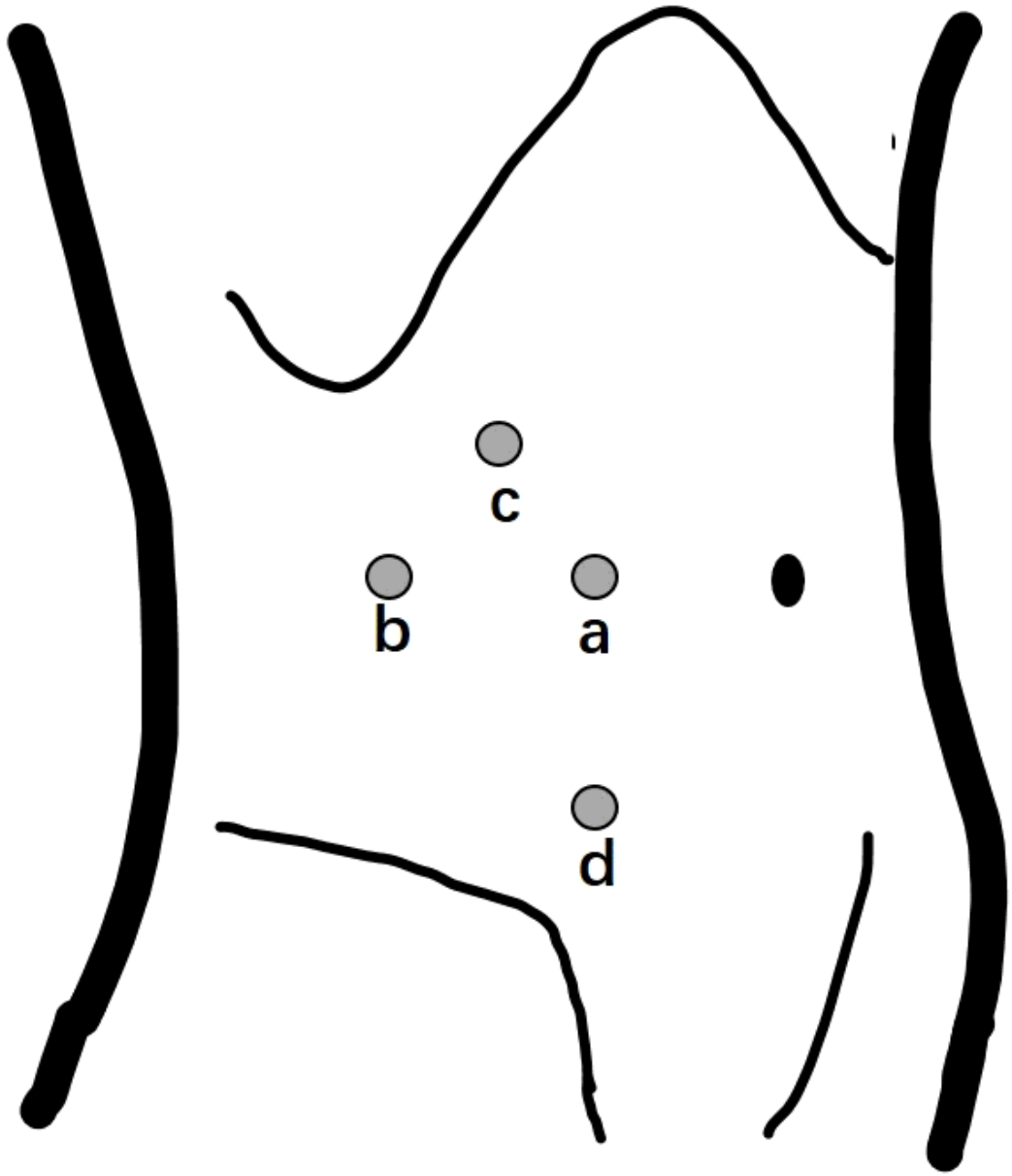

Figure 3

The port placement of laparoscopic group.