Early Recurrent Dislocation and Dissociation of Bipolar Cup: Two Intricate Cases and Review of Literature.

Xiao-lei Fan
Xiangya Hospital Central South University
Jian Wang
Karamay Central Hospital of Xinjiang
De-hua Zhang
Karamay Central Hospital of Xinjiang
Feng Mao
Karamay Central Hospital of Xinjiang
Yi Liao (ly6233005@126.com)
Karamay Central Hospital of Xinjiang

Research article

Keywords: bipolar cups, close reduction, dislocation, dissociation, hemiarthroplasty (HA)

Posted Date: July 23rd, 2020

DOI: https://doi.org/10.21203/rs.3.rs-47413/v1

Abstract

Background: Bipolar hemiarthroplasty (BHA) is one of the best options to treat femoral neck fracture in elderly patients. However, the early dislocation problem also happens in the bipolar cup. Furthermore, BHA has a specific implant-related complication, namely bipolar cup dissociation, in which the femoral head dissociates from the polyethylene (PE) liner. Early dislocation and dissociation are relatively uncommon but devastating complications and almost always lead to reoperation with revision of the prosthesis. Dislocation and dissociation of the bipolar cup can be challenging to manage and easily turn to recurrent episodes in case of improper handling. We hope to find out the best strategy for treatment early recurrent dislocation and dissociation of the bipolar cup.

Methods: We retrospectively reviewed 2 patients who had a history of early recurrent posterior dislocations following primary BHA from 2016 to 2019. What's more, they had early recurrent bipolar cup dissociation during the attempt of closed reduction maneuvers within 3 months of the original surgery.

Results: All the patients were treated with open reduction and revision of Bipolar hemiarthroplasty (BHA). One patient has a good outcome, and no recurrence of dislocation was recorded.

Conclusion: Recognition of the risk of dislocation and dissociation of bipolar cup is essential to its prevention and treatment. Complete revision of bipolar parts and the femoral head may be the minimum solution necessary to avoid the early recurrence of bipolar cup dissociation. Further investigations are recommended to strengthen these results.

Background

Every year hundreds of thousands of hip arthroplasties are performed worldwide due to unstable femoral neck fractures. Total hip arthroplasty (THA) and bipolar hemiarthroplasty (BHA) are two basic types of hip endoprostheses. The dual mobility concept was proposed to restore hip biomechanics function and to prevent postoperative dislocation events of hip replacement[1]. The bipolar cup system consists of polyethylene (PE) acetabular components encased in ultra-smooth polished outer metal shells, for articulation in the bony acetabulum. The PE liner has an articulation for the femoral head. There is an anti-luxation system against dissociation between the bipolar cup and the femoral head. The bipolar cup commonly has a self-centering system that involves an eccentric offset of bearing centers. Smrke D et al. found that flexion, abduction, and adduction were significantly higher in the bipolar cup[2]. BHA has some advantages over unipolar components; increased range of motion, variable choice of head size, neck length, decreased wear of acetabulum and reduced the risk of dislocation[3]. Therefore, BHA was widely used for elderly patients who experienced femoral neck fractures[4, 5]. However, dislocation and dissociation can happen from the modularity of this implant. A previous study reported the incidence of dislocation in 6 months was 2.7% with a bipolar cup[6]. The actual rate of dislocation may be higher clinically, though it has not been given for BHA. Dislocation after primary BHA can usually be reduced by routine closed methods but is associated with a high rate of recurrent dislocation. Li L et al. reported 54%

of patients who had early dislocation sustained recurrent dislocations[5]. Similarly, Barnes CL et al. report that 13 patients(52%) of these closed reduced hips subsequently experienced one or more re-dislocations, of which 7 required operative treatments for the recurrent dislocation[7].

Dislocation after hip hemiarthroplasty is a common complication, but dissociation of a bipolar prosthesis is rare. The bipolar cup dissociation in which the femoral head dissociates from the PE liner may occur late or early postoperatively[8–10]. Late dissociations are commonly caused by long-term wear of the PE liner and sometimes fracture of the locking ring. The meantime to dissociate was 7.5 years, and the incidence of this failure was 11%[10]. In recent years, with the application of ultrahigh molecular weight polyethylene (UHMWPE), the abrasion resistance of PE liner also delays the occurrence of late dissociations. Some scholars reported the frequency of early dissociation of the bipolar cup was 13% in patients with dislocations[11]. Dissociation of the bipolar components can happen during the hip dislocation, the reduction maneuvers, or spontaneously without any dislocation[9]. The dissociation between the bipolar components has very devastating results and almost always requires surgical management. Early recurrent dissociation of the bipolar cup has been rarely reported. Here we retrospect two early bipolar cup dissociation cases in which experienced recurrent dislocation after revision surgery. This article aims to find out the reason for the patient's early recurrent dislocation and dissociation of bipolar cup, and to review the theories regarding the etiology and the treatment options for this rare complication. These cases are rare and will be beneficial for surgeons who perform BHA in elderly patients. To the best of our knowledge, this is the first report early recurrent dislocation and dissociation of bipolar cup.

Methods

This study was performed in accordance with the ethical standards of the 1964 Declaration of Helsinki. We performed a retrospective review of the medical records of patients diagnosed with early recurrent dislocation and dissociation of bipolar cup from 2016 to 2019. A total of 2 patients were identified, all of whom were treated by the senior doctor. The variables collected included date of injury, imaging, treatment, pain resolution, and return to daily activities. Imaging features of dislocation and dissociation of bipolar cup were analyzed on radiographs and correlated with clinical and surgical history.

Results

Case 1

An 80-year-old male patient was transported to the emergency room (ER) with a right femoral neck fracture (Fig. 1A) after a simple fall from standing height. He was a household ambulator and had a high risk for hip dislocation following THA. Therefore, he was treated with a BHA (Vario-cup, LINK, German) via a posterolateral approach the next day. The outer diameter of the bipolar cup was 52 mm, and that of the metal femoral head was 28 mm. One week after the original operation, he sustained a posterior hip dislocation during sleeping. Closed reduction was attempted under conscious sedation in the inpatient

department and ‘succeed’. But the x-rays revealed a dissociation between the ultrahigh molecular weight polyethylene (UHMWPE) liner and the femoral head (Fig. 1B). He was sent to the operating room (OR), where subsequent open reduction was performed through the original approach. He underwent a revision BHA under spinal anesthesia. It was found the UHMWPE locking ring showed no signs of scratch or defects, but the locking ring was still revised with the same size. The hip was reduced, and the stability of full range motion was tested. Hip abduction orthosis was used during the postop period.

One month following revision, the patient experienced second hip dislocation, which was spontaneously dislocated while arising from a seated position. The prereduction radiograph revealed a posterior dislocation (Fig. 1C). He was then taken to OR, where another attempt at closed reduction was performed under general anesthesia. During the reduction maneuvers, the second dissociation of the femoral head from the bipolar cup was confirmed by an image intensifier (Fig. 1D). Open reduction was performed and a posterolateral approach was again used. Intraoperatively, the UHMWPE locking ring was still securely fixed into the slot of the PE liner. The femoral stem component was found to be well fixed. The bipolar cup and femoral head were replaced with another new Vario-cup implant of the same size. The posterior capsule was repaired, and the hip joint was stable during the final testing. The postoperative radiograph (Fig. 1E) was satisfactory. The patient was transferred to the intensive care unit postoperatively. One week later, he experienced the third hip dislocation (Fig. 1F) by unconscious activities. The patient’s family was informed of the need for reduction or revision of the prosthesis. Based on severe health problems of the patient, his family wished no further actions to be taken at that time and the patient was dead in a month.

Case 2

A 79-year-old female was treated with a BHA (Vario-cup, LINK, German) after a subcapital fracture of left femoral neck. The operation was performed using a posterolateral approach. Yet, she slipped and fell onto a cement floor and experienced a periprosthetic femoral fracture (Fig. 2A) two weeks later. She was referred to our department to undergo revision HA through the same posterolateral approach. There was an obvious loosening of the femoral stem component. Therefore, all original components were changed and another bipolar cup (Vario-cup, LINK, German) was chosen to improve motion and stability. The outer diameter of the bipolar cup was 44 mm, and that of the metal femoral head was 28 mm. And the periprosthetic femoral fracture were fixed by wire cerclage. She also had 3 posterior hip dislocations within 3 months of her revision surgery.

A week later, the posterior dislocation of the prosthesis (Fig. 2B) was identified after she tried to get up from sickbed. This time the patient was taken to the OR for a closed reduction under general anesthesia. It worked out, and a postoperative CT scan was used to check for prosthesis loosening or polyethylene liner dislocation (Fig. 2C). Following the successful closed reduction, she experienced another posterior dislocation after one month. Therefore, it was decided to proceed with another revision to avoid recurrent episodes of dislocation. Intraoperatively, the anteversion of the femoral stem was increased to prevent postoperative recurrent dislocation. Hip abduction orthosis was also used during the postop period.

One month following revision she sustained a posterior hip dislocation again. Prereduction radiographs revealed a posterior dislocation with an intact bipolar cup (Fig. 2D). Closed reduction was performed under general anesthesia. During routine maneuvers of reduction, dissociation of the femoral head from the PE liner was confirmed by the image intensifier (Fig. 2E). A posterolateral approach was used again for opening reduction. Intraoperatively, there was no noticeable damage to the polyethylene liner and locking ring. New bipolar cup and femoral head components were replaced with another Vario-cup implant of the same size. The posterior capsule was repaired, and the stability of full range motion was tested. Strict anterior and posterior precautions were enforced for the first 6 weeks postoperatively. The patient's postoperative course was uneventful with no further episodes of dislocation or dissociation. One year postoperatively, X-rays show the excellent position of the prosthetic device and no evidence of complications (Fig. 2F). The patient remains pain-free and able to ambulate long distances with a frame at the time of the last follow-up.

Discussion

Postoperative dislocation of a BHA is a relatively low-probability complication. The patients above had the first dislocation within a month postoperatively. Besides, they experienced recurrent dislocation and revision treatment. This study, on the one hand, confirms that patients with early dislocation are at high risk of recurrence. The factors contributing to dislocation in patients who had BHA are not well known. Enocson A et al. reported that the posterolateral surgical approach increases the risk of dislocation[12]. Therefore, Therefore, the repair of short external rotator and preservation of posterior structures is an important thing. In our case, the posterior joint capsule and the abductor were repaired intraoperatively. Pala E and colleagues reported a significantly lower dislocation rate of 1.8% in the early postoperative period using a direct anterior approach (DAA)[13]. Yet, Sierra RJ et al. reported there was no significant association of dislocation with the surgical approach[4]. A previous study reported that cognitive dysfunction was an independent risk factor associated with prosthetic dislocation[5]. Several studies suggested that decreasing femoral offset and limb-length shortening may reduce muscle tension and induce impingement between prosthesis and acetabulum, leading to dislocation[14, 15]. It was reported that patients with low center-edge (CE) angle and femoral offset prosthesis had a higher risk for early recurrent dislocation[14, 15]. During the BHA, choose the suitable length and angle of the femoral stem neck to restore femoral offset and leg length. If the patient has a shallow acetabulum, a THA or the DAA could be considered[15]. The mechanism leading to early dislocation in our patient may be cognitive dysfunction or the posterolateral surgical approach selection.

Routine closed reduction of a dislocated bipolar component is more difficult than that of a conventional THA because of the larger diameter of the outer cup. Closed reduction techniques should be performed with satisfactory analgesia and muscle relaxation[7, 16]. Although closed reduction was attempted in all patients, only 30 percent of patients were managed to avoid additional surgery [4, 17]. Patients with recurrent or irreducible dislocations should be treated with open reduction and component revision according to the contributing factors. Barnes CL and colleagues reported more than 50% of the patients who had redislocation eventually required operative intervention for recurrent dislocation problems[7].

Revision surgery included such as another BHA, convert to a THA, isolated component exchange (choosing a suitable length and angle of femoral stem neck or change a bigger bipolar cup only), and so on[4, 7, 18]. Reports on the prognosis of these treatments are lacking. Some scholars reported that convert to a THA with dual mobility cups in the treatment of a hemiarthroplasty recurrent dislocation had a very good outcome[19]. Early recurrent dislocation of BHA is a frequent indication for revision surgery. Revision method, it seems that the etiology of dislocation is affecting the eventual treatment of these recurrent dislocations.

Dislocation and dissociation of bipolar cup are closely related. Most dissociation usually occurs when the dislocation reduction fails, and dislocation may occur because of dissociated components. Varley and Parker reported that dissociations accounted for 12% of all dislocations in bipolar prostheses[20]. Li L et al. found that 15% of all dislocations also were dissociations[5]. The most common cause of early dissociation in the reports was manipulation for closed reduction after bipolar cup dislocation. Dissociation during attempted closed reduction is a specific implant-related complication that can occur even under general anesthesia sometimes[9, 21]. The bottle-opener mechanism is the most commonly accepted reason for early bipolar cup dissociation[21], and it may account for 79% of the early dissociation published cases[16]. Another possible cause was the failure of the polyethylene locking ring. Lee YK et al. found that a single locking mechanism may be associated with an increased risk of bipolar cup-femoral head dissociation[11]. Dual locking mechanisms may be a better recommendation in BHA. In our case, the Vario-cup had a single UHMWPE locking ring, and this may be why bipolar cup dissociation easily, even when we attempt closed reduction under general anesthesia. Three types of failure of the locking ring have been discussed[10]. We classified the failure in our patient as a type III failure because it involved dislocation of the inner head without the detached locking ring. There are also many other reasons associated with early bipolar dissociation such us femoral head diameter, cup position, and implant design. Some scholars suggest the use of large diameter non-skirted femoral head, eccentric design of the PE liner, and small diameter polished surface femoral neck[22]. The cause of early bipolar cup dissociation remains questionable, and further research is needed. Early recurrent dissociation of the bipolar cup is rarely reporting. The design of prosthesis may be considered one reason for recurrent dissociation. It may also be due to inappropriate treatment, to some extent, attributed to iatrogenic factors. Therefore, the management of bipolar cup dissociation is significantly important. Improper treatment may lead to recurrent dissociation or dislocation.

Rapidly increasing use of BHA may lead to a corresponding increase in the incidence of bipolar cup dissociation. Clinicians need to be aware of the risk for bipolar cup dissociation [16]. Open reduction and revision should be prepared before a closed reduction attempt for dislocation. Once the early dislocation occurred, it always requires surgical management and bipolar component revision[8, 16, 21]. No previous studies, except for case reports, have described the strategy to manage early bipolar cup dissociation. Surgery included open reduction of the dissociation, modular components exchange (locking ring or PE liner or bipolar cup), and conversion to a THA, and another BHA (stem and bipolar components)[8, 9, 18]. We can also refer to the treatment of late bipolar cup dissociation. However, there is no standard treatment procedure, and no surgery method has shown superior results. Leonard T et.al found that

mixing manufacturers when placing dual mobility articulations on well-fixed femoral stems should not increase the risk of bipolar cup instability[23]. The isolated mobile component exchange could be used to manage early bipolar cup dissociation with well-fixed, and nondamaged implants occurring after external maneuvers[10, 16]. However, there are certain risks associated with the isolated mobile component exchange. The failure rate was 18% within 5 years, and one mode of failure was the early recurrence of intra-prosthetic dislocation[24]. If there is a prosthesis design problem, another bipolar hemiarthroplasty with a more appropriate prosthesis mentioned above is recommended. Consequently, the management of bipolar cup dissociation must be determined according to the available historical data and cause. In the absence of components damage, a complete revision of bipolar cup, PE liner, and femoral head components is a better solution for early recurrent bipolar cup dissociation. After such difficult cases, we would recommend at least complete bipolar components and femoral head revision for early bipolar cup dissociation with well-fixed steam, even there may be a risk of failure.

There were several limitations to this study. First, the strength of our results is limited, as the study was a retrospective with a small number of subjects. Second, the follow-up periods were limited. We are aware that longer follow-up is needed to identify clinical outcomes about the treatment.

Conclusions

In conclusion, early dislocation of BHA is an uncommon complication but it can be challenging to manage when they occur. When to prevent this condition, proper techniques such as choosing proper prosthetic and approach, short external rotator repair, should be done as a priority procedure to decrease the chance of recurrent dislocation. The direct anterior approach (DAA) may be a better choice for BHA. Once early dislocation occurred, the closed reduction should be realized very carefully under general anesthesia and fluoroscopic control to prevent early bipolar dissociation. The surgeon must be aware of the possibility of open reduction. Early dissociation of the bipolar cup is a complex complication that can happen between PE liner and femoral head articulation. This condition requires open operative treatment. Complete revision of bipolar cup, PE liner, and femoral head is the minimum solution necessary to avoid the recurrence of bipolar cup dissociation. Therefore, early recognize the cause of bipolar dislocation and dissociation is essential to its management. Patients with this prosthesis should be carefully followed up.

Abbreviations

BHA: Bipolar hemiarthroplasty; PE: polyethylene; HA: hemiarthroplasty; THA: Total hip arthroplasty; UHMWPE: ultrahigh molecular weight polyethylene; ER: emergency room; OR: operating room; DAA: direct anterior approach

Declarations

Acknowledgements

We thank all of the patients involved in the study. We want to thank Wen-Tao Wang for technological support.

Authors' contributions

Yi Liao contributed to the study design and is the corresponding author. Xiao-lei Fan contributed to the study design, data analysis and interpretation, and manuscript draft. De-Hua Zhang contributed to the data collection and analysis. Feng Mao contributed to the data collection and analysis. Jian Wang contributed to the literature search and manuscript revision. All authors have read and approved the final manuscript.

Funding

The authors did not receive grants or outside funding in support of their research or preparation of the manuscript.

Availability of data and materials

The datasets generated and analyzed during the current study are available from the corresponding author on reasonable request.

Ethics approval and consent to participate

The present study was approved by the ethics committee of Karamay central hospital and was performed in accordance with the ethical standards of the 1964 Declaration of Helsinki. Informed written consent was obtained from all patients.

Consent for publication

Not applicable

Competing interests

The authors declare that they have no competing interests.

References

1. Noyer D, Caton JH. Once upon a time.... Dual mobility: history. Int Orthop, 2017, 41(3):611-8.
2. Smrke D, Beden R, Stankovski V. Bipolar versus total hip endoprosthesis: functional results. Arch Orthop Trauma Surg, 2000, 120(5-6):259-61.
3. Inngul C, Hedbeck CJ, Blomfeldt R, Lapidus G, Ponzer S, Enocson A. Unipolar hemiarthroplasty versus bipolar hemiarthroplasty in patients with displaced femoral neck fractures: a four-year follow-up of a randomised controlled trial. Int Orthop, 2013, 37(12):2457-64.

4. Sierra RJ, Schleck CD, Cabanela ME. Dislocation of bipolar hemiarthroplasty: rate, contributing factors, and outcome. Clinical orthopaedics and related research, 2006, 442:230-8.
5. Li L, Ren J, Liu J, et al. What Are the Risk Factors for Dislocation of Hip Bipolar Hemiarthroplasty Through the Anterolateral Approach? A Nested Case-control Study. Clinical orthopaedics and related research, 2016, 474(12):2622-9.
6. Gonzalez AI, Bartolone P, Lubbeke A, et al. Comparison of dual-mobility cup and unipolar cup for prevention of dislocation after revision total hip arthroplasty. Acta Orthop, 2017, 88(1):18-23.
7. Barnes CL, Berry DJ, Sledge CB. Dislocation after bipolar hemiarthroplasty of the hip. J Arthroplasty, 1995, 10(5):667-9.
8. Georgiou G, Siapkara A, Dimitrakopoulou A, Provelengios S, Dounis E. Dissociation of bipolar hemiarthroplasty of the hip after dislocation. A report of five different cases and review of literature. Injury, 2006, 37(2):162-8.
9. Uruç V, Özden R, Duman İG, Kalacı A. Five cases of early dissociation between the bipolar hip endoprosthesis cup components; either spontaneously or during reduction maneuvers. Acta Orthopaedica et Traumatologica Turcica, 2017, 51(2):172-6.
10. Hasegawa M, Sudo A, Uchida A. Disassembly of bipolar cup with self-centering system: a report of seven cases. Clinical orthopaedics and related research, 2004, (425):163-7.
11. Lee YK, Park CH, Ha YC, Koo KH. What Is the Frequency of Early Dissociation of Bipolar Cups and What Factors Are Associated With Dissociation? Clinical orthopaedics and related research, 2018, 476(8):1585-90.
12. Enocson A, Tidermark J, Tornkvist H, Lapidus LJ. Dislocation of hemiarthroplasty after femoral neck fracture: better outcome after the anterolateral approach in a prospective cohort study on 739 consecutive hips. Acta Orthop, 2008, 79(2):211-7.
13. Pala E, Trono M, Bitonti A, Lucidi G. Hip hemiarthroplasty for femur neck fractures: minimally invasive direct anterior approach versus postero-lateral approach. European journal of orthopaedic surgery & traumatology : orthopedie traumatologie, 2016, 26(4):423-7.
14. Madanat R, Mäkinen TJ, Ovaska MT, Soiva M, Vahlberg T, Haapala J. Dislocation of hip hemiarthroplasty following posterolateral surgical approach: a nested case-control study. Int Orthop, 2012, 36(5):935-40.
15. Mukka S, Lindqvist J, Peyda S, et al. Dislocation of bipolar hip hemiarthroplasty through a postero-lateral approach for femoral neck fractures: A cohort study. Int Orthop, 2015, 39(7):1277-82.
16. De Martino I, D'Apolito R, Waddell BS, McLawhorn AS, Sculco PK, Sculco TP. Early intraprosthetic dislocation in dual-mobility implants: a systematic review. Arthroplasty Today, 2017, 3(3):197-202.
17. Addona JL, Gu A, De Martino I, Malahias M-A, Sculco TP, Sculco PK. High Rate of Early Intraprosthetic Dislocations of Dual Mobility Implants: A Single Surgeon Series of Primary and Revision Total Hip Replacements. The Journal of Arthroplasty, 2019, 34(11):2793-8.
18. Hernigou P, Dubory A, Potage D, Roubineau F, Flouzat Lachaniette CH. Dual-mobility arthroplasty failure: a rationale review of causes and technical considerations for revision. Int Orthop, 2017,

41(3):481-90.

19. Carulli C, Macera A, Matassi F, Civinini R, Innocenti M. The use of a dual mobility cup in the management of recurrent dislocations of hip hemiarthroplasty. Journal of orthopaedics and traumatology : official journal of the Italian Society of Orthopaedics and Traumatology, 2016, 17(2):131-6.
20. Varley J, Parker MJ. Stability of hip hemiarthroplasties. Int Orthop, 2004, 28(5):274-7.
21. Salvi AE. "Bottle-opener" effect in bipolar hip prostheses dislocations. J Arthroplasty, 2014, 29(10):2053-4.
22. Fabry C, Langlois J, Hamadouche M, Bader R. Intra-prosthetic dislocation of dual-mobility cups after total hip arthroplasty: potential causes from a clinical and biomechanical perspective. International Orthopaedics, 2015, 40(5):901-6.
23. Buller LT, Torres L, Baral EC, Wright TM, Ast MP. No Difference in Force Required for Intraprosthetic Dislocation of Mixed Manufacturer vs Same Manufacturer Dual Mobility Articulations. J Arthroplasty, 2020, 35(2):597-602.
24. Wegrzyn J, Malatray M, Pibarot V, Anania G, Béjui-Hugues J. Is Isolated Mobile Component Exchange an Option in the Management of Intraprosthetic Dislocation of a Dual Mobility Cup? Clinical orthopaedics and related research, 2020, 478(2):279-87.

Figures

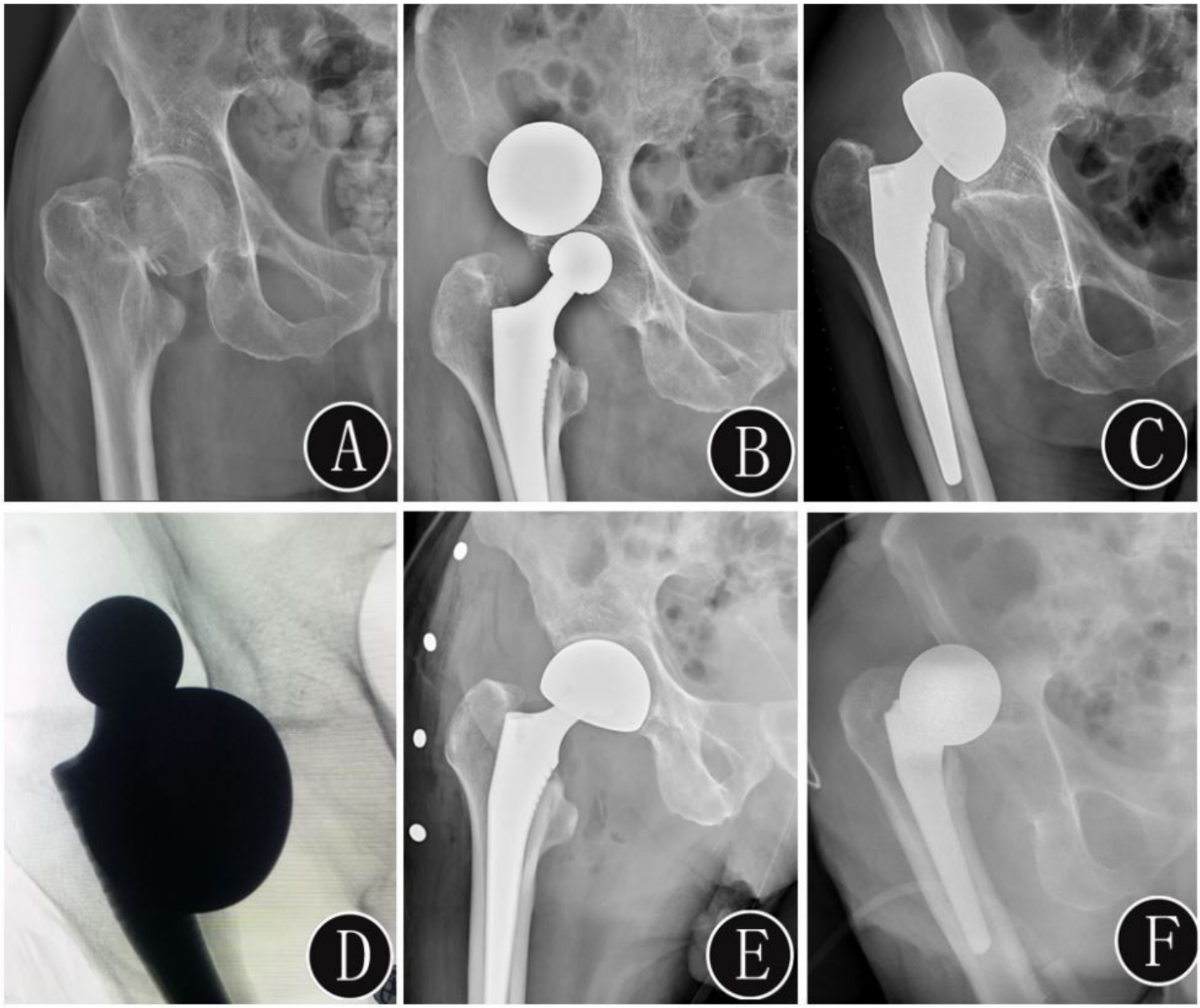

Figure 1

Anteroposterior radiographs of right hip joint: (A) The 80-years-old man experienced a right femoral neck of fracture. (B) The first dislocation and dissociation of bipolar cup with a location of the inner metal head into the acetabulum. (C) Prereduction radiograph revealed the second dislocation of the BHA. (D) The femoral head completely dissociated from the bipolar cup again. (E) Postoperative radiograph confirming the revision hip hemiarthroplasty. (F) Radiograph of the hip prosthesis after the third dislocation, 7 weeks postoperatively.

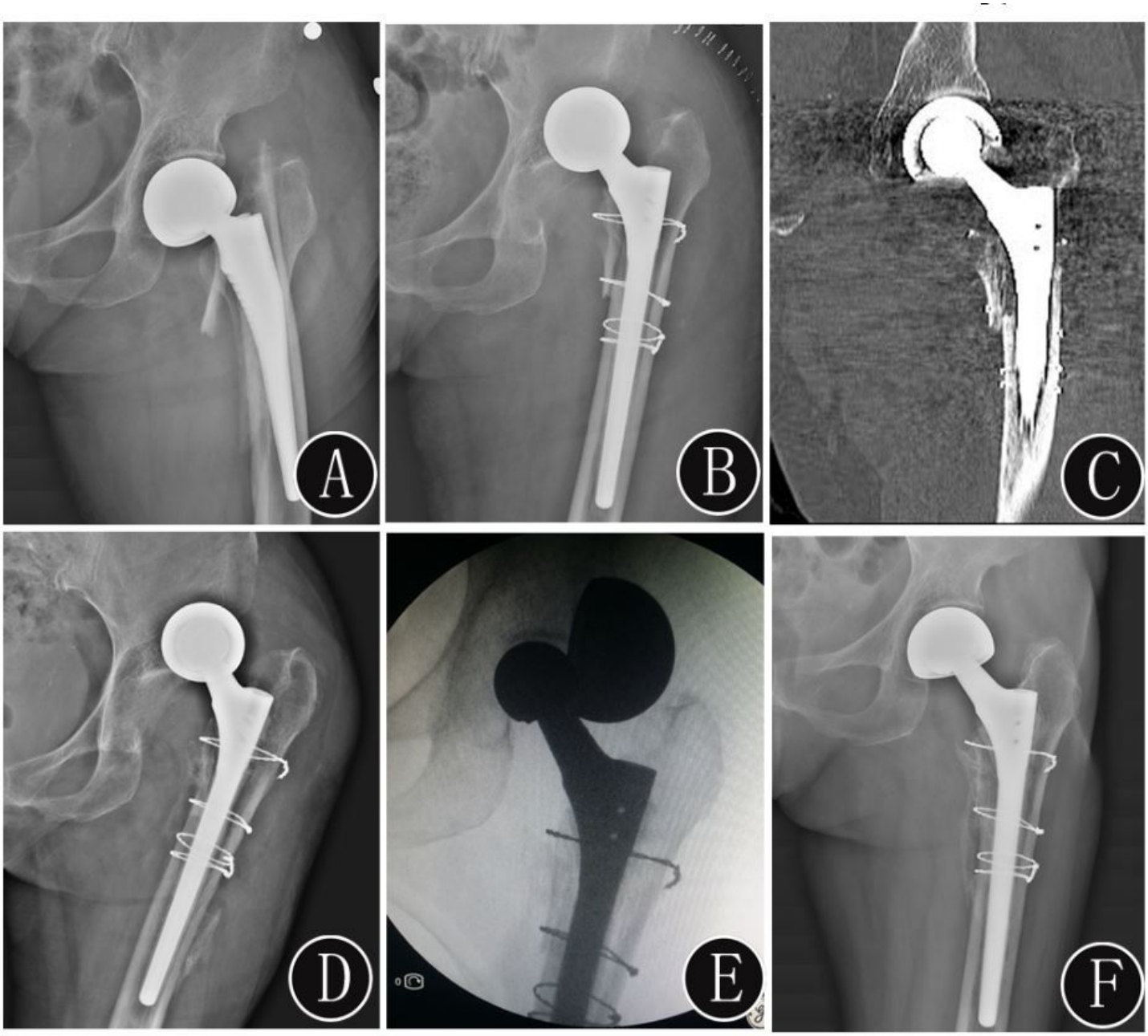

Figure 2

Serial radiographs of another recurrent dislocation and dissociation: (A) A 79-year-old woman suffered a left femoral periprosthetic fracture subsequent to a BHA two weeks later. (B) The first dislocation after the revision of HA one week later. (C) A CT scan was performed in case of instability after closed reduction. (D) Prereduction radiograph revealed another dislocation after one month. (E) During manual reduction, the femoral head dissociated from the bipolar cup. (F) Complete bipolar components and femoral head revision were performed, radiograph shows an excellent position of the prosthetic device one year postoperatively.