Operative Management of Fragility Fractures of the Pelvis – A Systematic Review

Daniel Wilson (d.wilson@doctors.org.uk)
Royal Adelaide Hospital https://orcid.org/0000-0002-3731-5052
Joshua Kelly
Royal Adelaide Hospital Orthopaedic and Trauma Service
Mark Rickman
University of Adelaide: The Centre for Orthopaedic and Trauma Research

Research article

Keywords: Osteoporosis, Pelvic Fracture, Pelvic Ring, Fragility Fracture of the Pelvis, Percutaneous.

Posted Date: May 4th, 2021

DOI: https://doi.org/10.21203/rs.3.rs-482087/v1

Version of Record: A version of this preprint was published at BMC Musculoskeletal Disorders on August 21st, 2021. See the published version at https://doi.org/10.1186/s12891-021-04579-w.

Abstract

Background

The incidence of osteoporotic pelvic fractures in elderly patient is rising. This brings an increasing burden on health and social care systems as these injuries often lead to prolonged hospital admissions, loss of independence, morbidity and mortality. Some centres now advocate stabilisation of these injuries to reduce pain, facilitate early mobilisation, decrease hospital stay and restore independence. A systematic review of the literature was planned to establish the evidence for this intervention.

Methods

A systematic review was performed according to PRISMA guidelines. A clinical librarian performed a search of the following databases: NHS Evidence, TRIP, the Cochrane Database of Systematic Reviews, MEDLINE and EMBASE. 17 eligible studies were identified with 766 patients.

Results

The quality of evidence was poor with no good quality randomised trials. The majority of injuries were minimally displaced. Posterior ring injuries were most often stabilised with percutaneous screws which were sometimes augmented with void filler. A variety of techniques were described for stabilisation of the anterior ring although fixation of the anterior ring was frequently not performed.

There was consistent evidence from the included studies that operative intervention significantly improved pain. Complications were minimal but there were increased failure rates when a single unaugmented sacroiliac joint screw was used. The limited availability of non-operative comparators made it difficult to draw firm conclusions about the efficacy of surgical over non-surgical management in these patients.

Conclusions

Operative management of fragility fractures of the pelvis should be considered for patients failing a brief period of non-operative management, however prospective randomised trials need to be performed to provide improved evidence for this intervention. Surgeons should consider which fixation techniques for fragility fractures of the pelvis are robust enough to allow immediate weightbearing, whilst minimising operative morbidity and post-operative complications.

PROSPERO Systematic Review ID: CRD42020171237

Background

The rising incidence of osteoporosis has brought significant challenges regarding the management of associated low energy injuries. In the past, high energy pelvic fractures associated with major trauma have predominated, however the incidence of low energy fragility fractures of the pelvis (FFP) is increasing and predicted to continue rising in the future[1–3].

High energy injuries often involve both the bony pelvis and associated ligaments and soft tissues. In contrast, low energy FFP are more commonly characterised by injuries affecting only the weaker osteoporotic bone. This observation is the basis for Rommen's classification which divides FFP into four groups of increasing instability ranging from isolated pubic rami injuries to complex bilateral displaced sacral injuries[4].

Historically the management of FFP in the elderly has involved a brief period of bed rest and analgesia followed by return to mobilisation as pain allowed[5, 6]. Despite this, significant pain caused by the injury [7, 8] often leads to prolonged immobility[9]. The consequences of this in a vulnerable population are significant. The mortality rate is similar to hip fractures, there is significant associated morbidity, prolonged inpatient stay and patients often require temporary or permanent admission to nursing homes [3, 10–15]. As with other debilitating osteoporotic fractures, this injury carries with it a significant financial burden[16] and results in a significant reduction in patient reported quality of life[17].

Some centres now advocate surgical management of these injuries to improve outcomes[18, 19]. The aim of this systematic review is to evaluate evidence for surgical management of FFP. This includes fracture patterns encountered as well as fixation methods and timing of interventions. We also aimed to identify whether these interventions improve pain and other outcomes such as mobility, length of stay, quality of life and mortality compared to conservatively managed patients.

Methods

This systematic review was registered with the International prospective register of systematic reviews (PROSPERO) Centre for Reviews and Dissemination, University of York and conducted in accordance with PRISMA guidelines[20]. A clinical librarian searched the followed databases; NHS Evidence, TRIP, the Cochrane Database of Systematic Reviews, MEDLINE and EMBASE. Bibliographic database searches were conducted using the NHS Evidence Healthcare Databases Advanced Search platform. The final search was conducted on 4th May 2020. Relevant natural language and controlled vocabulary terms were selected and combined, and final results reviewed. There were no language restrictions in the initial search, however studies not written in English were excluded.

All studies with fragility fractures of the pelvic ring including sacral insufficiency fractures were included in patients 60 years or older. Studies were excluded if they contained patients with high-energy injuries (defined as a fall greater than from standing height), or a pathological fracture from a cause other than

osteoporosis. We also excluded patients managed with sacroplasty alone although included patients with augmentation of sacroiliac joint (SIJ) screws with bone cement or other void filler. Acetabular fractures and isolated iliac crest fractures were excluded as were studies with fewer than ten patients.

Abstracts were analysed by two authors (DW and JK). Relevant abstracts were selected for full text review and inclusion where relevant. Any disagreement on studies to include was decided by discussion and with the senior author (MR). A flowchart of the study selection can be seen in Fig. 1. Randomised and non-randomized studies were assessed for bias using The Cochrane Collaboration's tool for assessing risk of bias[21, 22] and case series assessed by the Joanna Briggs Institute checklist for case series[23]. Studies were assessed by two authors (DW and JK) and any disagreements resolved by discussion with a third (MR). A narrative synthesis was then performed using these tools. Main outcomes were pain scores, quality of life, mobility, length of stay and mortality. Secondary outcomes were complications including re-operations, failure of fixation, neurological deficits, and infection. No meta-analysis was planned.

Results

17 studies were identified with 766 patients of which 463 were managed operatively. One randomised study and three studies with non-operative comparison groups were identified. The remaining studies were case series. A summary of the results is presented in Table 1.

Table 1

Author, year and Study type	Patients	Classification and numbers	Indication for surgery	Fixation Method		Screw Augment	X-ray/CT	Post op weight bearing	Outcome measures	Results
				Posterior	Anterior					
Osterhoff et al 2019 Retrospective case control	230	"Low energy fractures of the pelvis"	Inability to mobilise 3-5 days post injury	2 SIJ screws - Unilateral = 33 bilateral = 24 Spinopelvic = 2 plate = 2.	Plate = 8 Ramus screw = 5 Infix = 4	-	X-ray	WBAT	1 and 2 year mortality. Majeed score	Overall mortali 21%. 2 early operati 17% no operati p=0.29. Majeed 66.1 operati 65.7 no (p=0.91 61 mor average LoS 12 operati 8 days op p=<(
Balling et al 2019 Randomised trial	52	Rommens Type 2 = 52	Failed conservative management for 14 days	Minimum 2 transacral screws. 26 with sacroplasty, 26 without.	none	Additional sacroplasty in 26	CT	WBAT	VAS, ODI, Length of stay	Mean p VAS SI vs 9.0 SIJ+SP Discha VAS 3.5 3.6 respect P=<0.0 differer betwee groups. 9.3 day vs 9.6 c SIJ+SP op mea SIJ 86. 86.2 SI Decrea 32.7 an respect at disch
Oikonomidis et al 2019 Retrospective case series	32	Rommens Type 1 = 1 Type 2 = 22 Type 3 = 9	Inability to mobilise after 1 week	Single SIJ screw = 31	Photodynamic bone stabilisation system = 32	-	X-ray	WBAT	VAS, length of stay, mortality	3% Mor at 7.5 months Mean dischar VAS 4.4 follow u VAS 3.0 Averag 16.5 da
Walker et al 2018 Retrospective Cohort	41	Young & Burgess LC1 = 26 "Sacral U" = 16	Inability to ambulate or severe pain on ambulation	Single transacral screw = 15, Double transacral screw = 1	none	-	X-ray	WBAT	VAS, LoS	VAS on admiss operati group 7 improv 3.5 on dischar non-op 5.1. p= <0.001 3.6 ope vs 4.2 r operati P=0.51
Pulley et al 2018 Retrospective case series	16	"Sacral U" = 16	Failure of conservative management or inability to weight bear	2 transacral screws = 13, 2 SIJ screws bilaterally = 1, 1 transacral screw + 1 SIJ screw bilaterally = 1, 1 SIJ screw	none	-	X-ray	WBAT	VAS	Averag improv in pre to op VAS p=<0.0

				bilaterally = 1						
Hoch et al 2017 (1) Retrospective Case series	128	OTA B2.1 = 115 B3.3 = 13 Operative, non-operative and failed non-operative groups	Unable to mobilise after 3 days with adequate analgesia	Single SIJ screw = 28, 2 SIJ screws = 6, Bilateral SIJ screws = 14, Triangular fixation = 2.	Plate = 3	Additional sacroplasty in 13	CT in 7 cases	WBAT	VAS, SF12, LoS, Mortality, EQ5D	2 Year mortali non-op 20% operati <0.05. LoS 18 operati 9.2 non P=<0.0 Mean E at 2 yea non-op failed n 76.3, operati 74.6 - n signific differer SF12 n differer betwee groups
Eckardt et al 2017 Retrospective case series	50	Rommens Type 2 = 15, Type 3 = 10, Type 4 = 25	persistent mobility limiting pain	Single screw = 37, 2 screws = 11, Plate = 2. transacral screws = 23, SIJ screws= 27	Plate = 14 (combined with single screw = 11, double screw = 1)	-	CT	WBAT	VAS, TUG, Mortality	1 year mortali 10%. T test at 2 years: 0 5pts (1 10-20s (44%), 2 7pts (2 >30s 6p (19%). rest 0/1 20pts (VAS 1-3 (21%), >3 6pts (18%). TUG VA 0/10 17 (52%), 3 6pts (VAS >3 (30%)
Hoch et al 2017 (2) Prospective case series	34	Rommens Type 2 = 25 Type 4 = 8	Persistent immobilisation	Single SIJ = 25, Double SIJ = 1, Single SIJ bilaterally = 8	Plate = 16, Ramus screw = 16 Plate and screw = 1	All screws augmented with PMMA	X-ray	WBAT	VAS, SF12, LoS	VAS on admiss 6.7 admiss 2.7 day to disch (p=<0.0 SF12 a year no differer age ma control 14 days
Fox et al 2016 Retrospective case series	11	Bilateral sacral = 7 Jumpers variant = 1 unilateral sacral = 2, S1 stress = 1	Failure of non-operative measures or pain limiting mobilisation	1 transacral screw = 10, 2 transacral screws = 1	none	-	X-ray	WBAT	VAS, ODI, LoS, Mortality	1 year mortail 10%. M VAS 9.1 op vs 3 post-op 2.4 fina follow u <0.01. LoS 2.5 Mean O 71.6 pr 17.6 po and 14. follow u <0.01
Collinge et al 2016 Retrospective case series	24	OTA B2.2 = 15, B3.3 = 8, C3.2 = 1	Acute fractures thought to be unstable or with marked pain limiting mobility	Single SIJ screw = 15, Single transacral screw = 9	none	All screws augmented with CaPO4	X-ray	WBAT	VAS	Mean V 7.9 pre- 3.4 at dischar <0.001. 3.2 at 6 weeks,

										final fo up
Hopf et al 2015 Retrospective case series	30	Anterior and posterior = 18, Unilateral posterior = 1, Bilateral posterior = 11	Persistent pain or unacceptable mobility reduction after 6 days conservative management	Single SIJ = 6, Double SIJ = 12, Triple SIJ = 1, Bilateral SIJ = 2, Bilateral double SIJ = 6, Bilateral triple SIJ = 1, Bilateral SIJ - 2 screws one side, 1 screw other = 2,	none	-	X-ray	WBAT	VAS	Mean V 6.8 on admiss 6.0 afte rest vs post op 3.6 p=< 1.8 on dischar <0.001
Arduini et al 2015 Retrospective case series	14	Rommens Type 2 = 3, Type 3 = 9, Type 4 = 2	6 months failed conservative treatment	Single SIJ = 8, Plate and screw = 3, Spinopelvic fixation = 2	Screw = 2, plate = 3, 'screw or plate in Rommens Type 3' = 9	-	X-ray	Bed rest for 4-6 weeks	LoS	LoS 6 c post-op
Wahnert et al 2013 Retrospective case series	12	"insufficiency fractures" = 12	5-7 days conservative treatment without improvement	Single SIJ = 12	Infix = 3	All screws augmented with PMMA	CT	WBAT	VAS	Mean V 8.2 pre- 2.6 pos (no stat analysi perform
Gansslen et al 2013 Retrospective case series	25	OTA B2.1 = 24, B3.3 = 1	not described	none	Supra-acetabular external fixator = 25	-	X-ray	Partial on side of injury	VAS, LoS	Mean V pre-op Post-op 2.3 (p= <0.001) Frame remova (mean weeks) 0.6 p= <0.000 Averag dischar days po
Mehling et al 2012 Retrospective case series	11	"insufficiency fractures"	fatigue fracture of sacrum or sacroiliac instability	Transacral bar = 11	ORIF = 3	-	X-ray	WBAT	German Multicentre Pelvis Study Group Score	Germar Multice Pelvis S Group outcom score a months point s summa radiolo clinical social reintegr 2 Excel Good, 4
Lau et al 2010 Retrospective case series	37	Young & Burgess isolated pubic rami = 15, LC1 = 13, LC2 = 9	not described	Plate = 7	Screw = 1	-	X-ray	WBAT	Mortality	1 year mortali 27% Ra fracture 23% LC 13% LC (Operat interver in 7/9 L only)
Vanderschot et al 2009 Retrospective case series	19	Unilateral sacral = 1, Bilateral sacral = 18	not described	Transacral bar = 19	none	-	CT	WBAT	VAS	Mean V pre-op 2.3 at 9 months <0.001) 3.6 op non-op P=0.51

OTA - Orthopaedic Trauma Association, LC1 - Lateral Compression Type 1, LC2 - Lateral Compression Type 2, SIJ - Sacroiliac Joint, Infix - Internal fixator, PMMA - Polymethylmethacrylate, CT - Computed Tomography, VAS - Visual anologue scale, ODI - Oswestry Disability Index, TUG - Timed up and go test, LoS - Length of Stay, WBAT - Weight bear as tolerated, SP – Sacroplasty

Quality assessment

Overall the quality of evidence for surgical management of FFP was low. The only randomised trial investigated the outcomes of FFP stabilised with transacral screw fixation with and without additional sacroplasty[24]. This study suffered from high risk of selection bias and was not blinded meaning drawing conclusions between the two groups was difficult. Despite this, robust follow-up and comprehensive reporting gave useful information regarding the pre and post-operative outcomes of surgically managed FFP.

The three comparative studies all suffered from high levels of bias. Groups were often poorly matched, had a variety of interventions and suffered from incomplete follow up. All studies suffered selection bias as only patients in more significant pre-operative pain were selected for operative intervention. Whilst this may reflect the real life scenario facing surgeons it makes comparisons between the groups difficult.

The quality of case series was variable. A common issue with the quality was a lack of pre-operative assessment of outcomes – particularly pain scores. Only six of the 13 case series contained pre-and post-operative/discharge pain scores for comparison. Most had some assessment of mobility or independence but these were often crude and unvalidated scoring systems and assessments that lacked a pre-operative comparison. Exclusion criteria, patient demographics and comorbidities were often poorly described or absent.

Fracture Patterns

A variety of systems were used to classify injuries including the Orthopaedic Trauma Association (OTA)[25], Young and Burgess[26] and Rommen's[4] classifications. Some studies did not use a recognised classification system and described fracture locations or grouped injuries as 'sacral insufficiency' fractures. This heterogeneity of fracture classifications made comparisons and analysis difficult between studies. Over 80% of the fractures studied consisted of minimally displaced unilateral or bilateral injuries suitable for percutaneous posterior fixation (Lateral compression type 1, Rommens Type II, OTA type B2). A minority of fractures were more displaced posterior unilateral fractures (5%), Displaced bilateral fractures (5%) and "Sacral U" type fractures (4%). Except for the lack of stable isolated pubic rami fractures which would have been managed non operatively this distribution is similar to those previously described[4, 27].

Fixation Methods

Numerous fixation methods were described for both anterior and posterior ring injuries. The majority of studies used percutaneous screws to fix posterior ring injuries. 48% had a single posterior screw. These single screws were often transacral screws passing from one side of the pelvis through both sacroiliac joints to the contralateral ilium[8, 24, 28–31]. SIJ and transacral screws were sometimes augmented with polymethymethacralate (PMMA) or other void filler[8, 14, 32]. Only 23% of patients had a single, unaugmented SIJ screw. 36% of patients had 2 or more screws crossing the SIJ, again some utilised transacral screws where sacral morphology allowed.

Eckardt examined reoperation rates for different screw configurations. They found a significantly increased reoperation risk when a single SIJ screw (not transacral or augmented) was used for posterior stabilisation regardless of whether the anterior ring was stabilised or not[30].

Two papers with a total of 30 (6%) patients described the use of a percutaneous transacral bar[18, 33] to treat bilateral sacral fractures.

There was consistent evidence that pain scores were reduced post-operatively with any percutaneous posterior ring fixation.

Seven patients in one study had plate fixation for their iliac fractures without SIJ screws[34]. Five patients in two studies had their percutaneous screw fixation augmented with a posterior plate[30, 35] and seven patients in three studies had spinopelvic fixation[14, 35, 36]. This method of fixation was reserved for the most complex and displaced fractures, which were not suitable for other less invasive methods of fixation.

Five studies used sacroplasty or screw augmentation. Balling et al. performed a prospective randomized study comparing a minimum of two transacral screws with and without PMMA sacroplasty. There was a statistically significant reduction in post-operative VAS scores and Oswestry Disability Index (ODI) scores in both groups but there was no difference between the groups. There were 4 cases of PMMA extrusion, 2 into the spinal canal but with no symptoms[24].

Four other case series described screws augmentation. One utilised the technique in some patients but didn't comment on indications or analyse these patients separately[14]. The others all showed statistically significant improvements in post-operative pain scores. No screw loosening or failure was described in any study but one noted asymptomatic PMMA leakage in 3(8%) of cases[6, 8, 32].

Anterior fixation of the pelvic ring was variable. 322 (70%) operatively managed patients had no anterior fixation. Seven studies did not utilise any form of anterior fixation[8, 19, 24, 28, 29, 31, 33]. Some chose to stabilise all the anterior ring injuries with either percutaneous screws or an open reduction and plate fixation[35]. Other studies performed selective fixation for more displaced injuries[6, 14]. One case series used external fixation in isolation for 4 weeks with significant decrease in post-operative pain[7]. Two studies used an anterior internal fixator (Infix)on seven patients of [32, 36]. Another used a photodynamic bone stabilization system to stabilise rami fractures with concurrent posterior screw fixation[37]. Overall there was no consensus regarding method or indication for anterior fixation.

Pain

Ten studies chose the Visual Analogue Scale (VAS) to quantify pain pre and post-operatively. Post-operative scores were either performed 24–48 hours post-operatively or at discharge from hospital but in one case it was performed at an average of nine months follow up[33]. All these studies in isolation showed a statistically significant improvement in average VAS scores. The average decrease in VAS amongst these studies was 4.5 which exceeds the minimally

important clinical difference of 2.0 for patients with low back pain[38]. Only one study with a non-operative comparison group reported on pain pre-injury and on discharge. It showed a significant decrease in VAS from 7.4 pre-operatively to 3.5 in the operative group compared to the non-operative cohort who had an average VAS of 5.7 on admission and 5.1 on discharge. The operative patients had a significantly longer walking distance on discharge and 75% were discharged back home compared to 20% in the non-operative group[29].

Three papers reported VAS post operatively at various timepoints but with no pre-operative comparison. All of these showed low VAS scores, which were comparable to the scores of other studies[14, 30, 37].

Disability/Mobility Outcomes

A variety of disability and quality of life scoring systems were used by authors. Two studies used the Oswestry Disability Index (ODI) questionnaire pre and post-operatively. The randomised study compared transacral screws with and without sacroplasty augmentation and showed a significant average improvement from 86.2 to 30.6 between pre and post-operative assessment but with no significant difference between the two cohorts[24]. One of the better quality case series also showed a significant average improvement from 71.6 to 17.6 after management with a single transacral screw[28]. SF-12 and EQ-5D scores were reported in two studies and found no difference between uninjured comparisons at one year[6] or operatively and non-operatively managed patients at two years[14].

One retrospective case control study performed Majeed scores at an average of 61 months post operatively and found no significant difference (66.1 operative, vs 65.7 non-op p = 0.91)[36].

Mehling et al utilised a scoring system by the German Multicentre Pelvic Registry[39] which assesses radiographic, clinical and social reintegration domains. It reported 2 excellent, 5 good and 4 fair results at an average of 14 months follow up, but with no pre-operative comparison[18].

Most studies had an assessment of mobility or degree of post-operative independence. These are summarised in Table 2. Again there was a great variety in the method and timings of assessment, which made comparisons difficult. One of the cohort studies by Walker et al showed significantly longer walking distances with operatively managed patients who were also more likely to be discharged home (75% vs 20%) compared to non-operatively managed patients[29].

Table 2
Mobility/Independence Outcomes

		Author/Year	Mobility/Independence
Osterhoff et al 2019	36(24%) patients returned home in operative group compared to 19(23%) in non-operative group	Fox et al 2016	All patients returned to pre injury level of function at an average 625 days of follow up
Balling et al 2019	All patients discharged when able to mobilise upstairs	Collinge et al 2016	Not described
Oikonomidis et al 2019	Mobility at discharge: 10(31%) crutches, 21(66%) walker/rollator, 1 (3%) unable to mobilise. Follow up at 7 months: 11(34%) independent, 7(22%) crutches, 6(19%) walker, 1(3%) immobile	Hopf et al 2015	Complete mobility regained in 73% at discharge
Walker et al 2018	75% patients discharged home in operative group compared to 20% in non-operative group (p = < 0.001). Significantly longer walking distance in operative vs non-operative at discharge (95.4 vs 35.2 feet p = < 0.01)	Arduini et al 2015	Bed rest 4–6 weeks post op. At 6 months 11 patients (79%) had normal mobility, 1(7%) single crutch, 1 (7%) two crutches
Pulley et al 2018	Average day 1 mobilisation 102 feet	Wahnert et al 2013	All patients could be mobilised to their pre-operative levels
Hoch et al 2017 (1)	Not described	Gansslen et al 2013	24 patients full mobility pre injury and 1 patient mobile with walker. At discharge 14 (58%) regained full mobility. 7 (28%) partial weight bearing. 21 (88%) patients regained baseline mobility at frame removal (average 4 weeks)
Eckardt et al 2017	73% independent at home, 13% lost independence. 60% Performed TUG test < 30s	Mehling et al 2012	Not described
Hoch et al 2017 (2)	At 1 year 9(26%) patients mobile without aids, 6(18%) required 1 or 2 crutches, 12 (35%) with walker	Lau et al 2010	At 3 months 53% baseline mobility isolated rami fractures, 62% LC1 and 56% LC2 fractures
		Vanderschot et al 209	5 point ADL score used. Average 3.26 pre op improved to 1.68 at follow up (P = < 0.0001) at an average of 9 months

LC1 - Lateral Compression Type 1, LC2 – Lateral compression type 2, ADL – Activities of Daily Living

Length of stay

Walker et al noted no significant difference in the length of stay between operative and non-operative groups (3.6 vs 4.2 days respectively)[29]. Hoch noted a significantly greater length of stay in operatively treated patients (18 days vs 9 days) although this did include an average of 6 days for an attempt at conservative management pre operatively[14]. Length of stay varied from an average of 2.5 to 16 days in the remaining studies reporting this outcome.

Mortality

Hoch et al studied mortality rates at two years in three cohorts. They noted that 2-year mortality was significantly greater (41%) in the non-operative group compared to the operative and failed non-operative groups (18 and 21% respectively) although the operative group was noted to be younger on average[14]. Another study comparing operative and non-operative groups showed no significant difference in mortality at 1 year (23% vs 17% p = 0.29). It did however, show a survival benefit in the operative group develop after 2 years[36]. Reported 1 year mortality rates ranged from 10–27% in other studies.

Complications

Table 3 summarises the complications reported in the included studies. Operative complications were relatively uncommon. The main reasons for reoperation were for symptomatic screw loosening, incorrect screw placement with neurological symptoms and evacuation of post-operative haematoma. One study noted a significant rate of symptomatic screw loosening of 18% where a single percutaneous sacroiliac joint screw was used compared to two screws[30].

Table 3
Complications and reoperations

	Reoperations (%)	Indications	Other
Osterhoff et al 2019	No reoperations reported	-	In hospital complications more common in operative group (35%) vs non-operative group (14%) p = < 0.05
Balling et al 2019	1 (2%)	evacuation post op haematoma	1 guidewire perforation into spinal canal, 4 cases cement extrusion – 2 into canal, 2 into soft tissue. All asymptomatic
Oikonomidis et al 2019	1 (3%)	Implant failure requiring removal	2 pneumonia, 4 UTI
Walker et al 2018	No reoperations reported	-	1 GI bleed in operative group. 1 GI bleed and 2 COPD exacerbations in non-operative group.
Pulley et al 2018	No reoperations reported	-	no complications
Hoch et al 2017 (1)	4 (13%)	3 screw malposition, 1 revision for infection	2 patients (4%) required transfusion post op. Medical complications 8% non-operative group, 18% operative group
Eckardt et al 2017	13 (26%)	1 screw malposition, 1 infection, 9 for symptomatic implant loosening, 2 patients revised for implant loosening required further revision for non-union	-
Hoch et al 2017 (2)	2 (6%)	1 screw malposition, 1 evacuation haematoma	3 asymptomatic PMMA leaks, 1 Pulmonary embolism
Fox et al 2016	No reoperations reported	-	No complications
Collinge et al 2016	No reoperations reported	-	1 extravasation of calcium phosphate into sacroiliac joint - asymptomatic
Hopf et al 2015	3 (10%)	1 screw malposition, 2 evacuation haematoma	1 intraoperative bleed requiring 3 units blood. 2 cases HAP and 2 Cases UTI in 3 patients
Arduini et al 2015	No reoperations reported	-	1 intrapelvic iliac screw from spinopelvic fixation - asymptomatic and left in situ
Wahnert et al 2013	No reoperations reported	-	No complications
Gansslen et al 2013	No unplanned reoperations reported	All patients required planned removal of external fixator in outpatient setting	2 pin site infections managed with antibiotics. 1 pin loosening.
Mehling et al 2012	No reoperations reported	-	1 temporary L5 nerve palsy
Lau et al 2010	No reoperations reported	-	1 fibrous non-union. 1 permanent L5 nerve palsy
Vanderschot et al 2009	2 (11%)	2 evacuation post op haematoma	-

UTI – Urinary Tract Infection, GI – Gastrointestinal, COPD – Chronic Obstructive Pulmonary Disease, PMMA – polymethylmethacrylate, HAP – Hospital Acquired Pneumonia.

Discussion

Traditionally FFP have been managed non-operatively, often with a period of bed rest with analgesia and then mobilisation[5, 40]. Knowledge regarding the detrimental effect of bed rest and immobility in the elderly population has been present for decades[41]. Even short periods of immobilisation or decreased mobility leads to prolonged loss of muscle strength[42] and loss of ability to perform activities of daily living leading to loss of independence[43, 44]. Mortality from non-operatively managed pelvic fractures is also similar to matched patients treated for hip fracture[45].

Elderly patients are unable to comply with restricted weightbearing regimes[46] – any management strategy should facilitate immediate full weight bearing with sufficient control of pain. This review highlights that whilst the quality of evidence for surgical fixation of FFP is poor, there is consistent data to support the idea that the majority of fracture patterns can be stabilised through minimally invasive methods, with a consequent reduction in pain and improvement in mobility. Whether this assertion is correct and if it translates to reduced lengths of stay, improved mortality, better quality of life and mobility needs further investigation.

Many different fracture classifications were used by the studies, which made comparisons difficult. FFP often do not fit well into the OTA, Tile or Young and Burgess classifications as elderly patients tend to have bony injuries rather than ligamentous involvement[4, 8]. Recognising this, the Rommen's classification was developed specifically for these injuries and may be more useful in classifying these injuries in the future[47].

The decision to pursue operative intervention in most of the studies was made after failure of conservative measures rather than based on fracture morphology. Whilst some unstable fractures may mandate surgical intervention, the commonest minimally displaced posterior injuries and even some more extensive and displaced injuries may be managed successfully with conservative measures. Conservative management was normally instituted for a period of 3–7 days although it did range up to 6 months. Given that relatively short periods of immobility can lead to significant morbidity we would recommend considering intervention after 48 hours of failed conservative management and certainly within 1 week.

A variety of fixation methods were noted in this review. The majority of authors utilised percutaneous posterior fixation where possible. Biomechanical studies have shown that two SIJ screws, a single augmented SIJ screw and a single transacral screw offer similar levels of stability and are all superior to single SIJ screw fixation in osteoporotic models[48–52]. There is some clinical evidence from this review identifying increased rates of screw loosening when one unaugmented SIJ screw was used alone regardless of whether the anterior ring was also fixed[30]. Therefore would suggest that a single un-augmented SIJ screw may not provide sufficient stability in the osteoporotic patient to facilitate early full weightbearing and adequate pain relief. Either multiple screws, longer transacral screws, or screw augmentation should be considered. Surgeons should be mindful of the potential additional risks and benefits of each option.

Anterior fixation was sporadic if present and there was no correlation between lack of anterior fixation and overall fixation failure. Tile noted that the posterior ring contributes around 60% to pelvic stability[53] and Matta confirmed that even in unstable pelvic injuries rami fractures did not require stabilization by internal or external fixation when the posterior ring was stabilised[54]. The data presented here would support the assertion that posterior fixation in these injuries is more critical than anterior fixation. Stabilising the anterior ring contributes to overall pelvic stability and this may understandably be desirable to surgeons managing osteoporotic FFP. Percutaneous screw fixation is an attractive option in minimally displaced fractures, however there is some biomechanical evidence in osteoporotic bone that plate fixation is superior to percutaneous retrograde screw fixation, the trade-off being that this requires an open approach[55]. External fixation is a quick and relatively easy technique but its use in the osteoporotic patient raises concerns with regard to pin-site infection, loosening and patient acceptance[4]. The Infix is a newer development and current trials are ongoing to identify whether it is a suitable method for stabilising osteoporotic type 1 lateral compression fractures[56], however its use is also not without complications[57]. A large study of the German pelvic database comparing Tile B and C type pelvic fractures with the anterior component involving the obturator foramen showed a higher rate of complications from more extensive anterior and posterior surgery compared to posterior stabilization alone with no difference in fixation failure or mortality[58]. When electing to stabilise FFP surgeons should be mindful that whilst attractive, supplementary anterior fixation may not be necessary with a robust posterior fixation. If electing to stabilise the anterior ring surgeons should be mindful of potential complications associated with the chosen method. Anterior fixation alone may be appropriate depending on the strength of fixation and degree of posterior instability[7].

In general complications from surgical interventions were low. Most studies used either computed tomography (CT) guidance or fluoroscopy to insert screws. Incorrect screw placement was noted with both techniques but was infrequent and any iatrogenic neurological deficits resolved after removal and repositioning[6, 14, 19, 30].

We noted a previous systematic review of four studies on the effectiveness of surgical fixation of osteoporotic LC1 fractures. This found insufficient evidence to support guidance on the most effective treatment for patients sustaining this injury however where reported, mobility and function did improve after surgery[59]. This systematic review is a more comprehensive overview of 17 studies encompassing all types of FFP.

This systematic review does have some weaknesses. Firstly there was a lack of good quality randomised studies on which to base conclusions and most studies suffered from significant risk of bias. There was also significant heterogeneity in fracture classification and outcome measures which made pooling of data and direct comparisons difficult. We also excluded trials with less than 10 patients and excluded papers where an English translation could not be obtained. This will result in the loss of some data but as only a small number of cases were excluded this is unlikely to change the overall impression of the review.

Conclusion

This systematic review set out to identify the evidence for surgical management of FFP. Overall the quality of evidence was low. Of the 17 studies identified only one was randomised but with high risk of bias. Three studies were identified with a non-operative comparator group but all suffered from significant bias. Despite this, consistent improvement in pain and mobility was noted with stabilisation of the pelvis, which was most often performed percutaneously to the posterior ring. Anterior fixation of the pelvic ring was often absent and variable techniques were used when present. More than one SIJ screw posteriorly, longer transacral screws or screw augmentation offer more robust fixation than single SIJ screws for stabilising the pelvis, especially in the context of osteoporosis. Surgeons should consider operative stabilisation of FFP after a brief period of conservative management to avoid morbidity associated with immobility.

Abbreviations

FFP
fragility fracture of the pelvis
PROSPERO
International prospective register of systematic reviews
PRISMA
Preferred reporting instructions for systematic review and meta-analysis
NHS
National Health Service
SIJ
Sacroiliac Joint
OTA
Orthopaedic Trauma Association
PMMA
polymethylmethacrylate
VAS
Visual analogue scale
ODI
Oswestry Disability Index
CT
computed tomography

Declarations

Ethics approval and consent to participate: Ethical approval was not sought as this was a review of completed research studies with individual ethical approval.

Consent for publication: not applicable

Availability of data and material: The datasets analysed and/or created where not presented are available from the corresponding author on reasonable request.

Competing Interests: The authors declare they have no competing interests.

Funding: No funding was received by any author for preparation of this manuscript

Author contributions:

DW: methodology, search, study selection and analysis, writing and editing paper, read and approved manuscript.

JK: study selection and analysis, writing and editing paper, read and approved manuscript.

MR: concept, methodology, editing paper, study selection, read and approved manuscript

Acknowledgements: The authors would like to acknowledge Tom Roper, Clinical Librarian, Brighton and Sussex University Hospitals NHS Trust for his assistance in conducting the literature search.

References

1. Boufous S, Finch C, Lord S, Close J (2005) The increasing burden of pelvic fractures in older people, New South Wales, Australia. Injury 36:1323–1329. https://doi.org/10.1016/J.INJURY.2005.02.008
2. Rollmann MF, Herath SC, Kirchhoff F, Braun BJ, Holstein JH, et al (2017) Pelvic ring fractures in the elderly now and then – a pelvic registry study. Arch Gerontol Geriatr 71:83–88. https://doi.org/10.1016/J.ARCHGER.2017.03.007
3. Kannus P, Palvanen M, Niemi S, Parkkari J, Järvinen M (2000) Epidemiology of Osteoporotic Pelvic Fractures in Elderly People in Finland: Sharp Increase in 1970-1997 and Alarming Projections for the New Millennium. Osteoporos Int 11:443–448. https://doi.org/10.1007/s001980070112

4. Rommens PM, Hofmann A (2013) Comprehensive classification of fragility fractures of the pelvic ring: Recommendations for surgical treatment. Injury 44:1733–1744. https://doi.org/10.1016/j.injury.2013.06.023
5. Gotis-Graham I, McGuigan L, Diamond T, Portek I, Quinn R, et al (1994) Sacral insufficiency fractures in the elderly. J Bone Joint Surg Br 76-B:882–886. https://doi.org/10.1302/0301-620X.76B6.7983111
6. Höch A, Pieroh P, Henkelmann R, Josten C, Böhme J (2017) In-screw polymethylmethacrylate-augmented sacroiliac screw for the treatment of fragility fractures of the pelvis: a prospective, observational study with 1-year follow-up. BMC Surg 17:132. https://doi.org/10.1186/S12893-017-0330-Y
7. Gänsslen A, Hildebrand F, Kretek C (2013) Supraacetabular external fixation for pain control in geriatric type B pelvic injuries. Acta Chir Orthop Traumatol Cech 80:101–5
8. Collinge CA, Crist BD (2016) Combined Percutaneous Iliosacral Screw Fixation With Sacroplasty Using Resorbable Calcium Phosphate Cement for Osteoporotic Pelvic Fractures Requiring Surgery. J Orthop Trauma 30:e217–e222. https://doi.org/10.1097/BOT.0000000000000520
9. Kortebein P, Symons TB, Ferrando A, Paddon-Jones D, Ronsen O, et al (2008) Functional Impact of 10 Days of Bed Rest in Healthy Older Adults. Journals Gerontol Ser A Biol Sci Med Sci 63:1076–1081. https://doi.org/10.1093/gerona/63.10.1076
10. Alnaib M, Waters S, Shanshal Y, Caplan N, Jones S, et al (2012) Combined pubic rami and sacral osteoporotic fractures: A prospective study. J Orthop Traumatol 13:97–103. https://doi.org/10.1007/s10195-012-0182-2
11. van Dijk WA, Poeze M, van Helden SH, Brink PRG, Verbruggen JPAM (2010) Ten-year mortality among hospitalised patients with fractures of the pubic rami. Injury 41:411–414. https://doi.org/10.1016/J.INJURY.2009.12.014
12. Koval KJ, Aharonoff GB, Schwartz MC, Alpert S, Cohen G, et al (1997) Pubic rami fracture: a benign pelvic injury? J Orthop Trauma 11:7–9. https://doi.org/10.1097/00005131-199701000-00003
13. Breuil V, Roux CH, Testa J, Albert C, Chassang M, et al (2008) Outcome of osteoporotic pelvic fractures: An underestimated severity. Survey of 60 cases. Jt Bone Spine 75:585–588. https://doi.org/10.1016/J.JBSPIN.2008.01.024
14. Höch A, Özkurtul O, Pieroh P, Josten C, Böhme J (2017) Outcome and 2-Year Survival Rate in Elderly Patients With Lateral Compression Fractures of the Pelvis. Geriatr Orthop Surg Rehabil 8:3–9. https://doi.org/10.1177/2151458516681142
15. Fritz A, Gericke L, Höch A, Josten C, Osterhoff G (2020) Time-to-treatment is a risk factor for the development of pressure ulcers in elderly patients with fractures of the pelvis and acetabulum. Injury 51:352–356. https://doi.org/10.1016/j.injury.2019.12.007
16. Heinrich S, Rapp K, Rissmann U, Becker C, König H-H (2010) Cost of falls in old age: a systematic review. Osteoporos Int 21:891–902. https://doi.org/10.1007/s00198-009-1100-1
17. Schmitz P, Lüdeck S, Baumann F, Kretschmer R, Nerlich M, et al (2019) Patient-related quality of life after pelvic ring fractures in elderly. Int Orthop 43:261–267. https://doi.org/10.1007/s00264-018-4030-8
18. Mehling I, Hessmann MH, Rommens PM (2012) Stabilization of fatigue fractures of the dorsal pelvis with a trans-sacral bar. Operative technique and outcome. Injury 43:446–51. https://doi.org/10.1016/j.injury.2011.08.005
19. Hopf JC, Krieglstein CF, Müller LP, Koslowsky TC (2015) Percutaneous iliosacral screw fixation after osteoporotic posterior ring fractures of the pelvis reduces pain significantly in elderly patients. Injury 46:1631–1636. https://doi.org/10.1016/j.injury.2015.04.036
20. Liberati A, Altman DG, Tetzlaff J, Mulrow C, Gøtzsche PC, et al (2009) The PRISMA statement for reporting systematic reviews and meta-analyses of studies that evaluate healthcare interventions: explanation and elaboration. BMJ 339:b2700. https://doi.org/10.1136/bmj.b2700
21. Higgins JPT, Altman DG, Gøtzsche PC, Jüni P, Moher D, et al (2011) The Cochrane Collaboration's tool for assessing risk of bias in randomised trials. BMJ 343:. https://doi.org/10.1136/BMJ.D5928
22. Sterne JA, Hernán MA, Reeves BC, Savović J, Berkman ND, et al (2016) ROBINS-I: a tool for assessing risk of bias in non-randomised studies of interventions. BMJ 355:i4919. https://doi.org/10.1136/bmj.i4919
23. Moola S, Munn Z, Tufanaru C, Aromataris E, Sears K, et al (2017) Systematic reviews of etiology and risk. In: Aromatis E, Munn Z (ed) Joanna Briggs Institute Reviewer's Manual. The Joanna Briggs Institute
24. Balling H (2019) Additional Sacroplasty Does Not Improve Clinical Outcome in Minimally Invasive Navigation-Assisted Screw Fixation Procedures for Nondisplaced Insufficiency Fractures of the Sacrum. Spine (Phila Pa 1976) 44:534–542. https://doi.org/10.1097/BRS.0000000000002899
25. Meinberg E, Agel J, Roberts C, Karam M, Kellam J (2018) Fracture and Dislocation Classification Compendium—2018. J Orthop Trauma 32:S1–S10. https://doi.org/10.1097/BOT.0000000000001063
26. Manson T, O'Toole R V, Whitney A, Duggan B, Sciadini M, et al (2010) Young-Burgess Classification of Pelvic Ring Fractures: Does It Predict Mortality, Transfusion Requirements, and Non-orthopaedic Injuries? J Orthop Trauma 24:603–609. https://doi.org/10.1097/BOT.0b013e3181d3cb6b
27. Rommens PM, Arand C, Hopf JC, Mehling I, Dietz SO, et al (2019) Progress of instability in fragility fractures of the pelvis: An observational study. Injury 50:1966–1973. https://doi.org/10.1016/j.injury.2019.08.038
28. Sanders D, Fox J, Starr A, Sathy A, Chao J (2016) Transsacral-Transiliac Screw Stabilization: Effective for Recalcitrant Pain Due to Sacral Insufficiency Fracture. J Orthop Trauma 30:469–473. https://doi.org/10.1097/BOT.0000000000000596
29. Walker JB, Mitchell SM, Karr SD, Lowe JA, Jones CB (2018) Percutaneous Transiliac–Transsacral Screw Fixation of Sacral Fragility Fractures Improves Pain, Ambulation, and Rate of Disposition to Home. J Orthop Trauma 32:452–456. https://doi.org/10.1097/BOT.0000000000001243
30. Eckardt H, Egger A, Hasler RM, Zech CJ, Vach W, et al (2017) Good functional outcome in patients suffering fragility fractures of the pelvis treated with percutaneous screw stabilisation: Assessment of complications and factors influencing failure. Injury 48:2717–2723. https://doi.org/10.1016/j.injury.2017.11.002

31. Pulley BR, Cotman SB, Fowler TT (2018) Surgical Fixation of Geriatric Sacral U-Type Insufficiency Fractures. J Orthop Trauma 32:617–622. https://doi.org/10.1097/BOT.0000000000001308
32. Wähnert D, Raschke MJ, Fuchs T (2013) Cement augmentation of the navigated iliosacral screw in the treatment of insufficiency fractures of the sacrum. A new method using modified implants. Int Orthop 37:1147–1150. https://doi.org/10.1007/s00264-013-1875-8
33. Vanderschot P, Kuppers M, Sermon A, Lateur L (2009) Trans-iliac-sacral-iliac-bar procedure to treat insufficiency fractures of the sacrum. Indian J Orthop 43:245–252. https://doi.org/10.4103/0019-5413.53454
34. Lau T-W, Leung F (2010) Occult Posterior Pelvic Ring Fractures in Elderly Patients with Osteoporotic Pubic Rami Fractures. J Orthop Surg 18:153–157. https://doi.org/10.1177/230949901001800205
35. Arduini M, Saturnino L, Piperno A, Iundusi R, Tarantino U (2015) Fragility fractures of the pelvis: treatment and preliminary results. Aging Clin Exp Res 27:61–67. https://doi.org/10.1007/s40520-015-0430-4
36. Osterhoff G, Noser J, Held U, Werner CML, Pape H-C, et al (2019) Early Operative Versus Nonoperative Treatment of Fragility Fractures of the Pelvis. J Orthop Trauma 33:e410–e415. https://doi.org/10.1097/BOT.0000000000001584
37. Oikonomidis S, Alabsi A, Ashqar G, Graf M, Sobottke R (2019) Intramedullary Stabilization of Pubic Ramus Fractures in Elderly Patients With a Photodynamic Bone Stabilization System (IlluminOss). Geriatr Orthop Surg Rehabil 10:1–8. https://doi.org/10.1177/2151459318824904
38. Hägg O, Fritzell P, Nordwall A, Swedish Lumbar Spine Study Group (2003) The clinical importance of changes in outcome scores after treatment for chronic low back pain. Eur Spine J 12:12–20. https://doi.org/10.1007/s00586-002-0464-0
39. Pohlemann T, Tosounidis G, Bircher M, Giannoudis P, Culemann U (2007) The German Multicentre Pelvis Registry: A template for an European Expert Network? Injury 38:416–423. https://doi.org/10.1016/j.injury.2007.01.007
40. Babayev M, Lachmann E, Nagler W (2000) The Controversy Surrounding Sacral Insufficiency Fractures. Am J Phys Med Rehabil 79:404–409. https://doi.org/10.1097/00002060-200007000-00014
41. Creditor MC (1993) Hazards of Hospitalization of the Elderly. Ann Intern Med 118:219. https://doi.org/10.7326/0003-4819-118-3-199302010-00011
42. Hvid LG, Suetta C, Nielsen JH, Jensen MM, Frandsen U, et al (2014) Aging impairs the recovery in mechanical muscle function following 4days of disuse. Exp Gerontol 52:1–8. https://doi.org/10.1016/j.exger.2014.01.012
43. Bell KE, von Allmen MT, Devries MC, Phillips SM (2016) Muscle Disuse as a Pivotal Problem in Sarcopenia-related Muscle Loss and Dysfunction. J frailty aging 5:33–41. https://doi.org/10.14283/jfa.2016.78
44. Sonn U (1996) Longitudinal studies of dependence in daily life activities among elderly persons. Scand J Rehabil Med Suppl 34:1–35
45. Reito A, Kuoppala M, Pajulammi H, Hokkinen L, Kyrölä K, et al (2019) Mortality and comorbidity after non-operatively managed, low-energy pelvic fracture in patients over age 70: a comparison with an age-matched femoral neck fracture cohort and general population. BMC Geriatr 19:315. https://doi.org/10.1186/s12877-019-1320-y
46. Kammerlander C, Pfeufer D, Lisitano LA, Mehaffey S, Böcker W, et al (2018) Inability of Older Adult Patients with Hip Fracture to Maintain Postoperative Weight-Bearing Restrictions. J Bone Jt Surg 100:936–941. https://doi.org/10.2106/JBJS.17.01222
47. Pieroh P, Höch A, Hohmann T, Gras F, Märdian S, et al (2019) Fragility Fractures of the Pelvis Classification. J Bone Jt Surg 101:987–994. https://doi.org/10.2106/JBJS.18.00930
48. Oberkircher L, Masaeli A, Bliemel C, Debus F, Ruchholtz S, et al (2016) Primary stability of three different iliosacral screw fixation techniques in osteoporotic cadaver specimens—a biomechanical investigation. Spine J 16:226–232. https://doi.org/10.1016/j.spinee.2015.08.016
49. König A, Oberkircher L, Beeres FJP, Babst R, Ruchholtz S, et al (2019) Cement augmentation of sacroiliac screws in fragility fractures of the pelvic ring—A synopsis and systematic review of the current literature. Injury 50:1411–1417. https://doi.org/10.1016/j.injury.2019.06.025
50. van Zwienen CMA, van den Bosch EW, Snijders CJ, Kleinrensink GJ, van Vugt AB (2004) Biomechanical Comparison of Sacroiliac Screw Techniques for Unstable Pelvic Ring Fractures. J Orthop Trauma 18:589–595. https://doi.org/10.1097/00005131-200410000-00002
51. Suero EM, Greiner A, Becker CA, Cavalcanti Kußmaul A, Weidert S, et al (2020) Biomechanical stability of sacroiliac screw osteosynthesis with and without cement augmentation. Injury. https://doi.org/10.1016/j.injury.2020.01.043
52. Osterhoff G, Dodd AE, Unno F, Wong A, Amiri S, et al (2016) Cement Augmentation in Sacroiliac Screw Fixation Offers Modest Biomechanical Advantages in a Cadaver Model. Clin Orthop Relat Res 474:2522–2530. https://doi.org/10.1007/s11999-016-4934-9
53. Vrahas M, Hern TC, Diangelo D, Kellam J, Tile M (1995) Ligamentous contributions to pelvic stability. Orthopedics 18:271–4
54. Matta; J (1996) Indications for Anterior Fixation of Pelvic Fractures. Clin Orthop Relat Res 329:88–96. https://doi.org/10.1097/00003086-199608000-00011
55. Acklin YP, Zderic I, Buschbaum J, Varga P, Inzana JA, et al (2016) Biomechanical comparison of plate and screw fixation in anterior pelvic ring fractures with low bone mineral density. Injury 47:1456–1460. https://doi.org/10.1016/j.injury.2016.04.013
56. ISRCTN - ISRCTN16478561: Surgical vs conservative treatment of LC1 pelvic fractures in the elderly. http://www.isrctn.com/ISRCTN16478561. Accessed 28 May 2020
57. Vaidya R, Woodbury D, Nasr K (2018) Anterior Subcutaneous Internal Pelvic Fixation/INFIX. J Orthop Trauma 32:S24–S30. https://doi.org/10.1097/BOT.0000000000001248
58. Schmal H, Froberg L, S. Larsen M, Südkamp NP, Pohlemann T, et al (2018) Evaluation of strategies for the treatment of type B and C pelvic fractures. Bone Joint J 100-B:973–983. https://doi.org/10.1302/0301-620X.100B7.BJJ-2017-1377.R1

59. Booth A, Ingoe HMA, Northgraves M, Coleman E, Harden M, et al (2019) Effectiveness of surgical fixation for lateral compression type one (LC-1) fragility fractures of the pelvis: a systematic review. BMJ Open 9:e024737. https://doi.org/10.1136/bmjopen-2018-024737

Figures

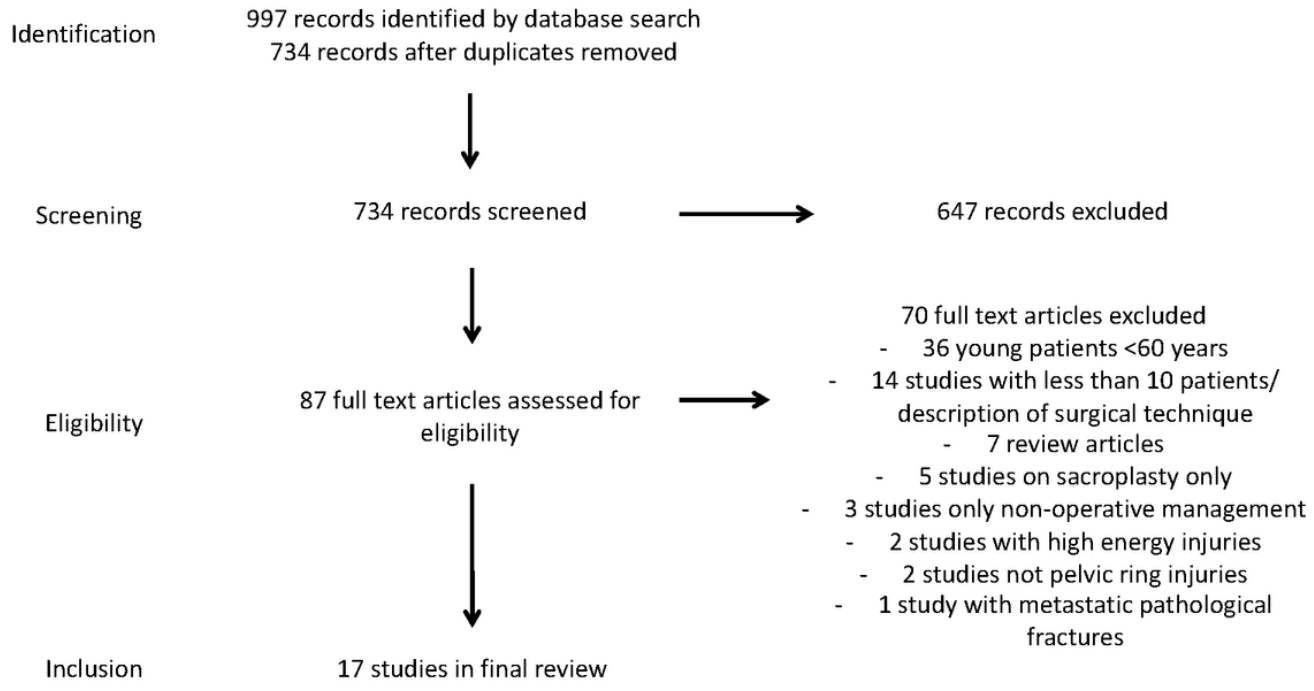

Figure 1

PRISMA flowchart of study selection.

Supplementary Files

This is a list of supplementary files associated with this preprint. Click to download.

- EMBASEsearchstrategy.docx
- PRISMAChecklist.doc