Aneurysmal Subarachnoid Haemorrhage After COVID-19 Infection

Sajjad Muhammad (Sajjad.Muhammad@med.uni-duesseldorf.de)

1. Department of Neurosurgery, Medical Faculty, Heinrich-Heine-University, Moorenstrasse 5, 40225, Düsseldorf, Germany

Soheil Naderi
Mostafa Ahmadi
Askar Ghorbani
Daniel Hänggi

Case report

Keywords: COVID-19, Neurosurgery, Neurovascular complications, aSAH

Posted Date: July 30th, 2020

DOI: https://doi.org/10.21203/rs.3.rs-48374/v1

Abstract

Background

SARS-CoV-2 virus infection leads to a severe and dysbalanced inflammatory response with hypercytokinemia and immunodepression. Systemic inflammation due to viral infections can potentially cause vascular damage including disruption of blood-brain barrier (BBB) and alterations in coagulation system that may also lead to cardiovascular and neurovascular events. Here, we report the first case of COVID-19 infection leading to aneurysmal subarachnoid haemorrhage (aSAH).

Case Description

A 61-year-old woman presented with dyspnea, cough and fever. She was over weight with Body mass-index of 34 and history of hypertension. No history of subarachnoid hemorrhage in the family. She was admitted in ICU due to low oxygen saturation (89%). A chest CT showed typical picture of COVID-19 pneumonia. Oropharyngeal swab with a PCR-based testing was COVID-19 positive. She was prescribed with favipiravir and hydroxychloroquine in Addition to oxygen support. On second day she experienced sudden headache and losst conciousness. A computer tomography (CT) with CT-angiography revealed subarachnoid haemorrhage in basal cisterns from a ruptured anterior communicating artery aneurysm. The aneurysm was clipped microsurgically through a standard pterional approach and the patient was admitted again to intensive care unit for further intensive medical treatment. Post-operative the patient showed slight motor dysphasia. No other neurological deficits.

Conclusion

Aneurysmal subarachnoid haemorrhage secondary to COVID-19 infection might be triggered by systemic inflammation. COVID-19 infection could be one of the risk factors leading to instability and rupture of intracranial aneurysm.

Introduction

The number of SARS-CoV-2 virus infected patients is increasing dramatically and have now reached over two million confirmed infected individuals with over 200,000 deaths worldwide. World health organisation has now declared the COVID-19 disease as a pandemic. The disease started in December 2019 in Wuhan, China and spread rapidly in January 2020 to Japan and over February/March 2020 in Europe. From mid of March 2020, COVID-19 spread briskly to North America and North America now shows the fastest growing number of newly diagnosed COVID-19 patients. Intensive epidemiological and biological research led to identification of novel corona virus 2019 (COVID-19) that can infect both animals and human (1, 2). COVID-19 infection is respiratory in nature and can range from common cold with mild symptoms to severe acute respiratory syndrome (SARS) with respiratory failure (3-5). COVID-19 infection typically presents with fever, fatigue, dry cough and shortness of breath (2, 4, 5) but can also involve other organs and systems including cardiovascular system and gastrointestinal tract (6). Involvement of other

organs especially the cardiovascular system has been shown to pose significant additional mortality in COVID-19 infected patients (7). Involvement of central nervous system during COVID-19 infection is not well known. Recently, a case of encephalopathy in a COVID-19 positive patient was reported showing the possible accessibility of the virus to the brain and involvement of central nervous system (8). Until date there is no report showing an aneurysmal subarachnoid haemorrhage secondary to COVID-19 infection.

Case Description

A 61-year-old woman presented with dyspnea, cough and fever.,She was over weight with Body mass-index of 34 and history of hypertension. No history of subarachnoid hemorrhage in the family. She was admitted in ICU due to low oxygen saturation (89%). A chest CT showed typical picture of COVID-19 pneumonia. Oropharyngeal swab with a PCR-based testing was COVID-19 positive. She was prescribed with favipiravir and hydroxychloroquine in addtion to oxygen support. On second day she experienced sudden headache and loss of conciousness. A computer tomography (CT) with CT-angiography revealed subarachnoid haemorrhage in basal cisterns from a ruptured anterior communicating artery aneurysm.

Treatment and outcome

The aneurysm was clipped microsurgically through a standard pterional approach. . All precautions including FFP-3 mask, glasses for eye protection and double gloves were used to protect surgical staff. The patient was admitted again to intensive care unit for further intensive medical treatment. Post-operative the patient showed slight motor dysphasia. No other neurological deficits.

Discussion

With increasing number of COVID-19 patients worldwide, multiple reports have shown that COVID-19 infection apart from lungs can also involve other organs including the brain (6-8). We present the first case of COVID19 infection that led to aneurysmal subarachnoid haemorrhage from a ruptured anterior communicating artery aneurysm. Microsurgical clipping was performed (due to lacking endovascular facility) to exclude bleeding aneurysm from the circulation and pneumonia was treated with favipiravir and hydroxychloroquine in addtion to oxygen support in intensive medical ward. Post COVID-19 aneurysmal subarachnoid haemorrhage might be due to severe cough leading to increased pressure on aneurysm wall or due to secondary systemic inflammation with free radical load due to virus infection that may weaken the aneurysm wall. There are however, multiple mechanisms, how an intracranial aneurysm can possibly lead to vascular wall instability due to systemic inflammation during viral infection. Viral infections including COVID-19 are known to induce cytokine storm (hypercytokinemia) leading to elevated systemic inflammation(9-11). Systemic inflammation is known to cause vascular injury including breakdown of collagen and permeability of blood-brain barrier (12, 13). Influenza A virus infection for example disturbs BBB through involvement of systemic elevated MMP-9 (12) that breaks collagen present in the basal membrane of every arterial wall and a high collagen turnover in the systemic circulation is a sign of instability of existing intracranial aneurysm (14) in patients with

unruptured intracranial aneurysms. Moreover, COVID-19 infection has been reported to increase systemic inflammation through dysbalance of T helper cells with exaggerated Th1 response (15). Similar kind of alterations in T helper cells populations have been found in patients with intracranial aneurysms (16). Moreover, a disturbed balance of macrophages and other inflammatory markers has been found in the wall of ruptured intracranial aneurysms (17, 18) showing that inflammation is an important component of instable aneurysms. In our patient, we found elevated systemic leukoctyes as a sign of systemic inflammation that is probably due to both infection and SAH. We however could not analyse subpopulations of different leukocytes in systemic circulation that might be altered. Another possibility could be a direct invasion of virus in the brain as previously reported (8). An aneurysm wall biopsy and COVID-19 PCR can exactly show the direct effect of virus on the aneurysm wall. For the general practice the neurosurgeons should work closely with other disciplines to rapidly diagnose and treat such patients.

Taken together, aneurysm instability partially due to systemic inflammation after virus infection might be one possible reason leading to SAH. This is however a single case report with post COVID-19 subarachnoid hemorrhage. Therefore, further epidemiological/clinical studies are needed to confirm the relationship and animal experiments in controlled conditions are required to find out exact mechanism.

Conclusion

Aneurysmal subarachnoid haemorrhage secondary to COVID-19 infection might be triggered by systemic inflammation. COVID-19 infection could be one of the risk factors leading to instability and rupture of intracranial aneurysm.

Abbreviations

COVID-19: SARS-CoV-2 virus

aSAH: Aneurysmal subarachnoid Hemorrhage

BBB: Blood-Brain Barrier

Declarations

Patient Consent

The patient has consented to the submission of the case report

Availability of Data and Materials:

Data sharing not applicable to this article as no datasets were generated or analysed during the current study.

Competing Interests

The authors declare that they have no competing interests.

Funding

We acknowledge the funding support from EANS to SM

Author's contribution

SM wrote manuscript

SN collected patient data

MA and AG treated the patients and reviewed manuscript

DH reviewed the manuscript critically.

Acknowledgements

Not applicable

References

1. Zhang T, Wu Q, Zhang Z. Probable Pangolin Origin of SARS-CoV-2 Associated with the COVID-19 Outbreak. Current Biology. 2020.

2. Zhou F, Yu T, Du R, Fan G, Liu Y, Liu Z, et al. Clinical course and risk factors for mortality of adult inpatients with COVID-19 in Wuhan, China: a retrospective cohort study. The Lancet. 2020.

3. Guan W-j, Ni Z-y, Hu Y, Liang W-h, Ou C-q, He J-x, et al. Clinical characteristics of coronavirus disease 2019 in China. New England Journal of Medicine. 2020.

4. Wang D, Hu B, Hu C, Zhu F, Liu X, Zhang J, et al. Clinical characteristics of 138 hospitalized patients with 2019 novel coronavirus–infected pneumonia in Wuhan, China. Jama. 2020.

5. Xu Z, Shi L, Wang Y, Zhang J, Huang L, Zhang C, et al. Pathological findings of COVID-19 associated with acute respiratory distress syndrome. The Lancet respiratory medicine. 2020.

6. Gu J, Han B, Wang J. COVID-19: Gastrointestinal Manifestations and Potential Fecal–Oral Transmission. Gastroenterology. 2020.

7. Guo T, Fan Y, Chen M, Wu X, Zhang L, He T, et al. Cardiovascular implications of fatal outcomes of patients with coronavirus disease 2019 (COVID-19). JAMA cardiology. 2020.

8. Filatov A, Sharma P, Hindi F, Espinosa PS. Neurological complications of coronavirus disease (covid-19): encephalopathy. Cureus. 2020;12(3):e7352.

9. Muhammad S, Haasbach E, Kotchourko M, Strigli A, Krenz A, Ridder DA, et al. Influenza virus infection aggravates stroke outcome. Stroke. 2011;42(3):783-91.

10. Qin C, Zhou L, Hu Z, Zhang S, Yang S, Tao Y, et al. Dysregulation of immune response in patients with COVID-19 in Wuhan, China. China (February 17, 2020). 2020.

11. Zhang W, Zhao Y, Zhang F, Wang Q, Li T, Liu Z, et al. The use of anti-inflammatory drugs in the treatment of people with severe coronavirus disease 2019 (COVID-19): The experience of clinical immunologists from China. Clinical Immunology. 2020:108393.

12. Muhammad S, Planz O, Schwaninger M. Increased plasma matrix metalloproteinase-9 levels contribute to intracerebral hemorrhage during thrombolysis after concomitant stroke and influenza infection. Cerebrovascular diseases extra. 2016;6(2):50-9.

13. Westover JB, Hickerson BT, Van Wettere AJ, Hurst BL, Kurz JP, Dagley A, et al. Vascular Leak and Hypercytokinemia Associated with Severe Fever with Thrombocytopenia Syndrome Virus Infection in Mice. Pathogens. 2019;8(4):158.

14. Hackenberg KA, Rajabzadeh-Oghaz H, Dreier R, Buchholz BA, Navid A, Rocke DM, et al. Collagen Turnover in Relation to Risk Factors and Hemodynamics in Human Intracranial Aneurysms. Stroke. 2020:STROKEAHA. 120.029335.

15. Huang C, Wang Y, Li X, Ren L, Zhao J, Hu Y, et al. Clinical features of patients infected with 2019 novel coronavirus in Wuhan, China. The Lancet. 2020;395(10223):497-506.

16. Zhang H-F, Zhao M-G, Liang G-B, Yu C-Y, He W, Li Z-Q, et al. Dysregulation of CD4+ T cell subsets in intracranial aneurysm. DNA and cell biology. 2016;35(2):96-103.

17. Hasan D, Chalouhi N, Jabbour P, Hashimoto T. Macrophage imbalance (M1 vs. M2) and upregulation of mast cells in wall of ruptured human cerebral aneurysms: preliminary results. Journal of neuroinflammation. 2012;9(1):222.

18. Hasan D, Hashimoto T, Kung D, Macdonald RL, Winn HR, Heistad D. Upregulation of cyclooxygenase-2 (COX-2) and microsomal prostaglandin E2 synthase-1 (mPGES-1) in wall of ruptured human cerebral aneurysms: preliminary results. Stroke. 2012;43(7):1964-7.

Figures

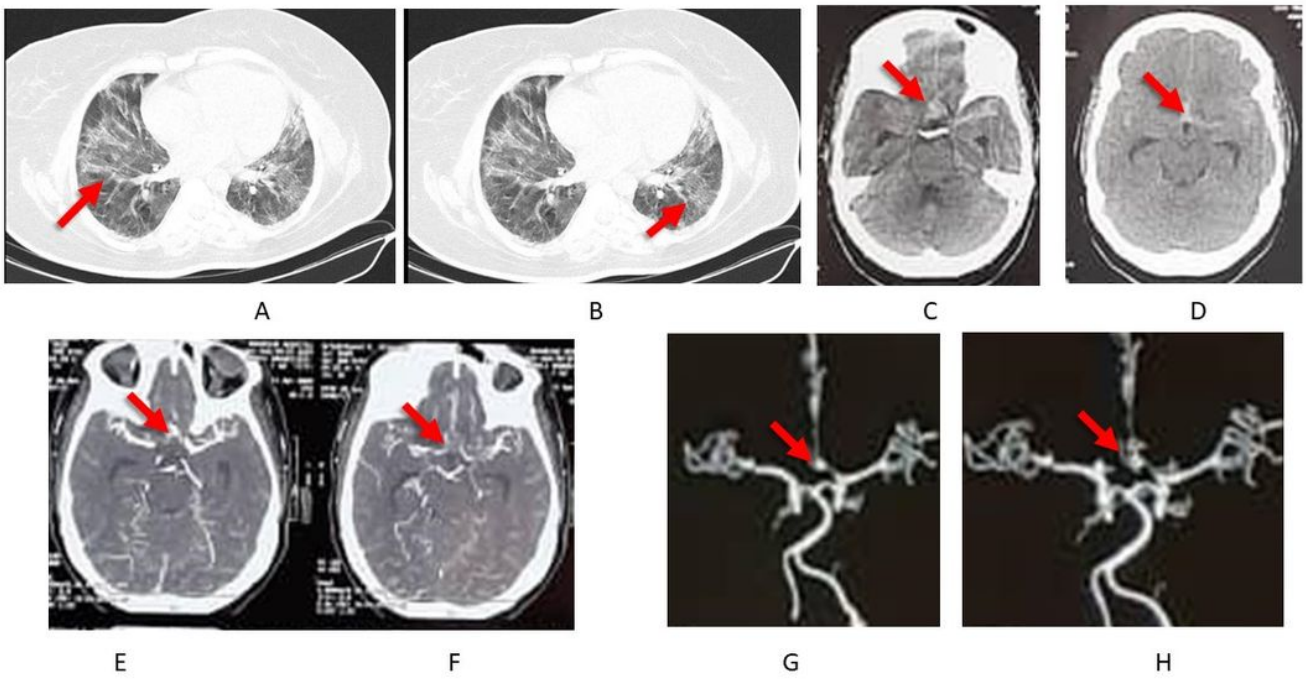

Figure 1

COVID-19 infection with pneumonia (A, B) and subarachnoid haemorrhage (C, D) from an anterior communicating artery aneurysm (E, F, G, H).