WITHDRAWN: Transconjunctival Cryo-Assisted Extraction of Intraconal Cavernous Hemangioma

ayman el sayed abd el sayed ghafar

aiman_eg_123@yahoo.com

Mansoura University Faculty of Medicine https://orcid.org/0000-0002-5127-7558

Sameh M Saleh

Mansoura University Faculty of Medicine

Ahmed S Elwehidy

Mansoura University Faculty of Medicine

amr mahmoud awara

Tanta University Faculty of Medicine

Research article

Keywords: transconjunctival orbitotomy, cryo-assisted extraction of hemangioma, intraconal cavernous hemangioma.

Posted Date: January 31st, 2020

DOI: https://doi.org/10.21203/rs.2.14177/v2

EDITORIAL NOTE:

The full text of this preprint has been withdrawn by the authors while they make corrections to the work. Therefore, the authors do not wish this work to be cited as a reference. Questions should be directed to the corresponding author.

Abstract

Background: The aim of this study is to evaluate safety and efficacy of transconjunctival cryo-assisted orbitotomy for extraction of intraconal cavernous hemangioma.Methods: The study was performed at the Mansoura ophthalmic center, Mansoura University, Egypt from May 2017 to August 2018, It included 18 patients with orbital intraconal cavernous hemangioma. In all cases, preoperative orbital MRI(magnetic resonance imaging) with contrast was performed, transconjunctival approach was used and cryo-assisted extraction of the lesions was performed. Cases were followed for six months after surgery.Results: This study included 18 patients with intraconal cavernous hemangioma, ten females (55.6%) and eight males (44.4%) with a mean age 35.6 years. Eight cases (44.5%) were lateral to the optic nerve, four cases (22.2%) were above the optic nerve, and six cases (33.3%) were below the optic nerve. Postoperative complications included three cases (16.7%) with postoperative diplopia due to lateral rectus paresis that improved in all cases within six months, one case (5.6%) with postoperative retrobulbar hemorrhage and proptosis that resolved within two weeks without sequelae, and four cases (22.2%) showed subconjunctival hemorrhage which resolved within two weeks. Of the two cases with drop of visual acuity preoperative, one case (5.6%) showed improvement of and one case (5.6%) did not improve. Conclusions: Transconjunctival orbitotomy assisted by the use of the cryoprobe for excision of intraconal cavernous hemangioma represents a good approach with minor resolvable complicationsTrial registration: Mansoura institutional review board (IRB)registration number: R/17.05.26 registration date: 10/5/2017 Keywords: transconjunctival orbitotomy, cryo-assisted extraction of hemangioma, intraconal cavernous hemangioma.

Background

Cavernous hemangioma is the second most common cause of proptosis after thyroid eye disease. [1-3] The intraconal space is the most common location for this tumor, so it mostly presents with painless slowly progressive, axial proptosis, diplopia and compressive optic neuropathy may occur in large lesions. [4-5]

Standard lateral orbitotomy with bone flap is the most common approach for lesions lateral, superior and inferior to the optic nerve. However, it is a long procedure and it is difficult to excise medial intraconal lesions using this procedure. [4-5]

Transconjunctival orbitotomy is gaining popularity in recent years, being a less traumatizing and more cosmetic approach compared to lateral orbitotomy. Use of the standard retinal cryoprobe helps the application of a good grip to the lesion and a safer extraction. [6]

In this study we try to evaluate the safety and efficacy of transconjunctival cryo-assisted extraction of intraconal cavernous hemangioma of the orbit assisted by cryoprobe.

Methods

This is a prospective interventional case series that was performed in Mansoura ophthalmic center, Mansoura University from May 2017 to August 2018. It included 18 patients with intraorbital, intraconal cavernous hemangioma. Cases were selected from the outpatient clinic of the Mansoura ophthalmic center presenting with axial proptosis.

Inclusion criteria:

Intraconal cavernous hemangioma was diagnosed on bases of clinical features of slowly progressive axial proptosis with or without compression of the optic nerve and supported by orbital magnetic resonance imaging(MRI) with contrast and confirmed postoperative by histopathology of the excised lesions.

Exclusion criteria:

Intraconal non-compressible solid lesions simulating cavernous hemangioma e.g. schwannoma, solitary neurofibroma, and fibrous histiocytoma were excluded because these lesions being solid need wider exposure through lateral orbitotomy.

We differentiated cavernous hemangioma from other solid lesions by:

1. Clinically cavernous hemangioma produces less marked proptosis compared to other variants even if it is large in size being compressible.
2. MRI with contrast shows moderate enhancement with filling of the angioma from the center to the periphery, others show filling from the periphery to the center (Fig.1).
3. Intraoperative ; the angioma is compressible bluish lesion but others appear grayish and solid.

In all cases, full ophthalmological examination was performed including; visual acuity testing, ocular motility testing, pupil examination for detection of afferent pupillary conduction defect, slit-lamp examination of the anterior segment, posterior segment examination by indirect ophthalmoscopy for detection of optic disc swelling and choroidal folds and measurement of ocular tension by applanation tonometer was performed.

The degree of axial proptosis was measured using Hertel's exophthalmometer and horizontal and vertical displacement was measured using two rulers.

MRI with contrast was performed for all cases and showed an intraconal well-defined rounded or oval mass iso-intense to the muscle in T_1 and hyper-intense to the muscle in T_2 and presumed to be cavernous hemangioma. Eight lesions were lateral to the optic nerve, four above and six below the optic nerve.

After getting an ethical approval from the Mansoura Institutional Review board (IRB), A written consent was taken from all patients and all surgeries were performed under general anaesthesia.

180° periotomy was fashioned in the conjunctiva and the site was chosen according to the location of the lesion in the orbit e.g. for lesions located in the intraconal space superior or lateral to the optic nerve, a conjunctival incision between the superior and inferior recti was performed and for lesions inferior to the optic nerve a conjunctival incision between the lateral and medial recti was performed.

The two exposed recti muscles were retracted and widely separated using muscle hooks. A cotton-tipped applicator is used for blunt dissection of the orbital fat until exposure of the anterior border of the lesion (Fig.2). Then, the surrounding fluid and blood were dried and the standard retinal cryoprobe(with a tip diameter of 2.5mm) was applied and turned on until an ice ball was formed, the probe was twisted to the right and left until the hemangioma become separated from the surrounding tissues and removed (Fig.3).

Hemostasis was done by using the diathermy to cauterize vessels on the surface of the mass before application of the cryoprobe and the pedicle of vessels on the posterior surface of the mass after extraction, the conjunctiva was closed with polyglactin sutures 6/0.

All excised masses were sent for histopathology and confirmed to be cavernous hemangioma.

Postoperative systemic antibiotics and topical combined antibiotic/steroid eye drops were used for one week. Patients were followed up at one day, one week, one month, three months and six months after surgery.

Results

This study included 18 patients with intraconal cavernous hemangioma, ten females (55.6%) and eight males (44.4%) with a mean age of 35.6 years (ranging from 21 to 52 years). All cases presented with axial proptosis: two cases (11.1%) presented with vertical diplopia and two cases (11.1%) presented with a drop of visual acuity (best corrected visual acuity was 0.3 and 0.5) with optic disc swelling in addition to proptosis.

All lesions were located in the intraconal space: eight lesions (44.5%) were lateral to the optic nerve, four (22.2%) were located above the optic nerve, and six (33.3%) were located below the optic nerve.

Postoperative complications included; three cases (16.7%) showed postoperative diplopia due to lateral rectus muscle paresis that improved within six months, one case (5.6%) showed postoperative retrobulbar hemorrhage and proptosis that was resolved within two weeks without squelae, four cases (22.2%) showed subconjunctival hemorrhage that resolved within two weeks.

Visual acuity was not affected except in the two cases that presented preoperatively with a drop in visual acuity. One case (5.6%) showed improvement (from 0.3 to 0.5) and the other case (5.6%) did not improve due to long-standing optic nerve compression.

Discussion

Lateral orbitotomy is traditionally used for approaching of intraconal cavernous hemangioma, as this gives a wide surgical exposure. However, it is a time consuming major procedure requiring a visible skin incision, a bone flap creation and reconstruction and a risk of trauma to the lateral rectus muscle with subsequent myopathy. Additionally, it is difficult to approach lesions medial to the optic nerve using this technique. [6]

Transcranial approach is still used by neurosurgeons for the approach of intraconal space in spite of high rate of morbidity including visual loss, ptosis, orbital hemorrhage, postoperative subdural hematoma and meningitis. This technique should be reserved for lesions at the orbital apex or those with an intracranial extension. [7]

Since its introduction in 1980, transconjunctival anterior orbitotomy was used for approach of the intraconal space. It is not time consuming, gives better cosmesis compared to lateral orbitotomy with a low risk of optic nerve affection and it can be tailored according to the location of the lesion. However, transconjunctival orbitotomy technique was under-utilized because of the narrow space it presents, inadequate exposure of deep intraconal lesions and subsequent postoperative complications. [8]

For achievement of better results with transconjunctival approach, the anterior border of the lesions should be close to the posterior pole of the globe, because deeper lesions close to the orbital apex will be masked by the orbital fat and therefore more difficult to handle. [9]

In this study we used the transconjunctival approach for intraconal cavernous hemangioma where the mass was present lateral, above and below the optic nerve. All tumors were successfully extracted with the aid of the cryoprobe that provided a good grip to the mass, facilitating removal without affection of the surrounding structures. In this study three cases showed postoperative lateral rectus myopathy that improved spontaneously within six months, one case showed postoperative retrobulbar hemorrhage that did not compress the optic nerve and improved spontaneously, and four cases showed subconjunctival hemorrhage. Two cases presented preoperatively with drop of vision; one of them showed improvement and one case did not improve.

Jin et al. (2008) discussed several studies that had investigated transconjunctival access to the intraconal space; Lazar et al. (1985) used the transconjunctival approach in 11 patients with intraconal cavernous hemangioma and reported complete, uncomplicated removal of all tumors. Loewenstein et al. (1993) in a study including 33 patients with cavernous hemangioma reported the same results as Lazar. [9]

Hayyam et al. (2005) reported complete removal of intraconal cavernous hemangiomas through a transconjunctival approach in 24 cases, but in this study one of the patients lost vision due to optic nerve trauma. [10]

Xiang et al. (2008) performed transconjunctival cryo-extraction of 36 intraconal lesions; 35 of them were cavernous hemangioma and one of them was diagnosed pathologically as neurilemoma. They reported

that this approach is a safe. less traumatizing and less time consuming. [11]

Renbeing et al. (2013) reported that transconjunctival approach is nearly equal to lateral orbitotomy as regard improvement of proptosis and rate of complications with less operative time. [12]

Cryo-extraction is best used in tumors and cysts containing fluid (blood or other fluid) rather than in solid tumors, because freezing occurs on the surface of the tumor as well as in the stroma and fluid or blood inside. Consequently, the outer and inner ice balls allow a strong grip to be applied by the probe, so cavernous hemangiomas are ideal for this approach. [13]

Gdal-On et al. used cryo-assisted extraction of intraconal hemangiomas and reported easy extraction in lesions touching the globe, but they did not recommend this approach in deeper lesions reaching the orbital apex, as it may endanger the apical structures. [14]

Tsirbas et al. (2005) reported that use of the cryoprobe for removal of intraconal tumors through transconjunctival approach decreased the complications of surgery. [15]

Castelnuovo et al. (2019) used the cryoprobe to extract two orbital cavernous hemangiomas transnasally and reported that the cryoprobes represent an adjunctive tool in extraction of fluid-filled intraorbital lesions.[16]

One of the limitations of this approach is the narrow working space, so the lesion's anterior margin should be adjacent to the globe for easy, safe, handling and removal of the tumors. However, more posterior lesions will be more difficult to manipulate and will be masked by orbital fat. Use of the standard retinal cryoprobe provide a good grip to the mass even in deep lesions, without affecting the surrounding structures.

In this study we found that use of the cryoprobe for extraction of the tumors helps removal of deeper lesions that are not touching the back of the globe after exposure of a sufficient portion of the mass to provide a good grip and after retraction of the surrounding fat. Retrobulbar hemorrhage and rupture of the angioma are possible complications and should be avoided be good intraoperative hemostasis and gentle dissection of the mass respectively.

Conclusion

We concluded that, transconjunctival orbitotomy assisted by use of the cryoprobe for excision of intraconal cavernous hemangioma represents a good approach with minor resolvable complications. However it is worth noting that we did not meet any cases with hemangiomas medial to the optic nerve in this study. Further comparative studies on a larger group of patients are needed for more evaluation of safety and efficacy of the technique.

Declarations

Ethics approval and consent to participate

The study was approved by Mansoura institutional review board (IRB)

R/17.05.26 on 10/5/2017 and a written consent from all participants was taken

Consent to publish

Not applicable

Availability of data and materials

I do not wish to share the raw data

Competing interest

There are no conflicts of interest.

No external or third-party financial support was involved.

Funding

No fund

Authors contributions

AA performed the surgery for all cases, wrote and submitted the manuscript , SS and AE reviewed the manuscript and performed analysis of the results. AA made the changes on the revised version of the manuscript. All authors have read and approved the manuscript.

Acknowledgement

Not applicable

Abbreviations

Not applicable

References

1. Casper DS, Chi TL, Trokel SL. Orbital disease: Imaging and analysis. New York: Thieme Medical Publisher 1993: 81-97.
2. Scheuerle AF, Steiner HH, Kolling G, Kunze S, Aschoff A. Treatment and long-term outcome of patients with orbital cavernomas. Am J Ophthalmol 2004;138:237-44.

3. Rootman J. Diseases of the orbit: A multidisciplinary approach. 2nd ed. Philadelphia: Lippincott Williams & Wilkins 2003:420-60.
4. Wirtschafter JD, Chu AE. Lateral orbitotomy without removal of the lateral orbital rim. Arch ophthalmol 1988;106:1463- 68.
5. Aria H, Sato K, Katsuda T, Rhoton AL. Lateral approach to intraorbital lesions: Anatomic and surgical considerations. Neurosurgery 1996; 39: 1157-62.
6. Kyong J C, Ji-Sun P, Suk-Woo Y. Surgical outcomes of transconjunctival anterior orbitotomy for intraconal orbital cavernous hemangioma. Korean J Ophthalmol 2010; 24(5):274-78.
7. Missori P, Tarantino R, Delfini R, Lunardi P, Cantore G. Surgical management of orbital cavernous angiomas: prognosis of visual functions after removal. Neurosurgery 1994; 35: 34-38.
8. Yan J, Wu Z. Cavernous hemangioma of the orbit: Analysis of 214 cases. Orbit 2004; 23:33-40.
9. Jin WC, Rui LW, Ji PC, You L. Transconjunctival orbitotomy for orbital cavernous hemangiomas. Can j ophthalmol 2008; 43:234-38.
10. Hayyam K, Burcin B, Sevgul B. Transconjunctival approach for retrobulbar intraconal orbital cavernous hemangiomas. Orbital surgeon perspective. World neurosurgery 2005;64:71-74.
11. Xiang Q, Xu XL, Jiang HB. Transconjunctival surgical cryoextraction of introconal orbital cavernous hemangiomas. J Cent South Un 2008 Jun;33(6):537-40.
12. Renbing J, Xianqun F. Transconjunctival versus lateral orbitotomy approach for retrobulbar intraconal orbital cavernous hemangioma- A comparative study of long term outcomes. IOVS 2013; 54:740-47.
13. Manquez M E, Shields C L , Karatza E C , Shields J A. Fingertip cryoprobe assisted orbital tumour extraction. BJO 2004;49:777-78.
14. Gdal-On M, Gelfand YA. Surgical outcome of transconjunctival cryosurgical extraction of orbital cavernous hemangioma. Ophthalmic Surg Lasers 1998; 29:969-73.
15. Tsirbas A, Kazim M, Close L. Endoscopic approach to orbital apex lesions. Ophthal Plast Reconstr Surg 2005; 21: 271-75.
16. Castelnuovo P, Arosio AD, Volpi L, De Maria F, Ravasio A, Donati S, Azzolini C, Dallan I, Bignami M, Locatelli D. Endoscopic Transnasal Cryo-Assisted Removal of Orbital Cavernous Hemangiomas: Case Report and Technical Hints. World Neurosurg. 2019 Jun;126:66-71.

Figures

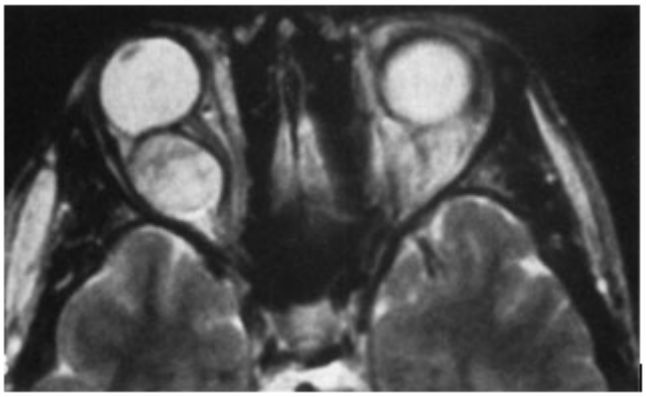

Figure 1

Axial MRI(T2-weighted image) demonstrates a well-defined, homogeneous intraconal mass hyperintense to the muscle

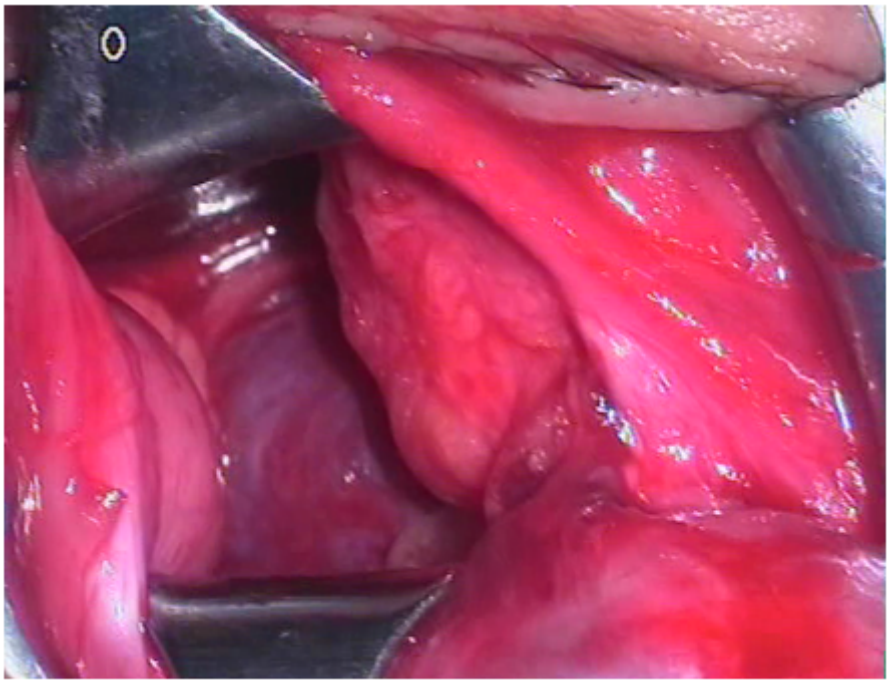

Figure 2

intraoperative transconjunctival exposure of intraconal cavernous hemangioma

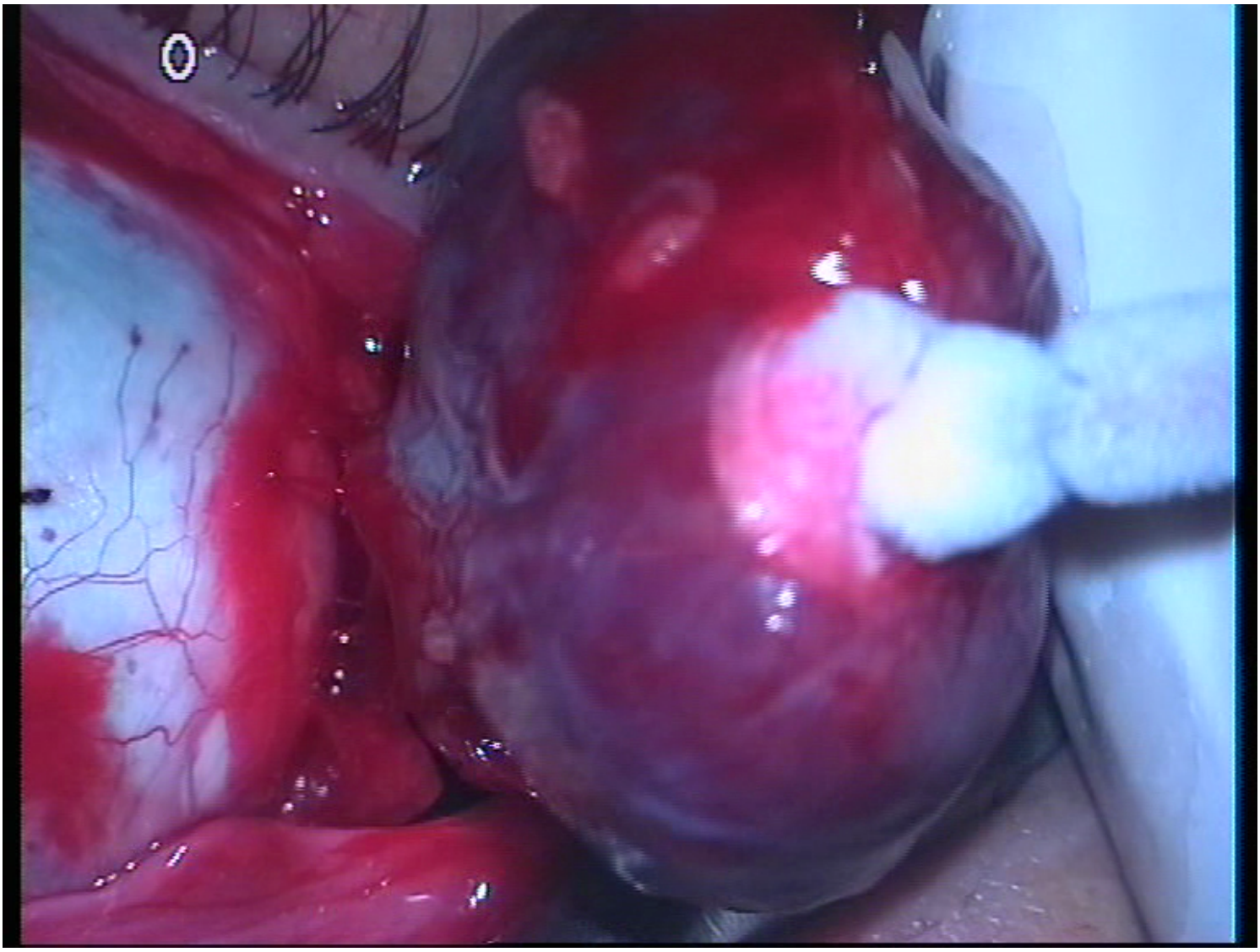

Figure 3

intraoperative transconjunctival Cryo-assisted extraction of intraconal cavernous hemangioma

Supplementary Files

This is a list of supplementary files associated with this preprint. Click to download.

- video.avi