WITHDRAWN: Transconjunctival Cryo-Assisted Extraction of Intraconal Cavernous Hemangioma

ayman el sayed abd el sayed ghafar

aiman_eg_123@yahoo.com

Mansoura University Faculty of Medicine https://orcid.org/0000-0002-5127-7558

Sameh M Saleh

Mansoura University Faculty of Medicine

Ahmed S Elwehidy

Mansoura University Faculty of Medicine

amr mahmoud awara

Tanta University Faculty of Medicine

Research article

Keywords: transconjunctival orbitotomy, cryo-assisted extraction of hemangioma, intraconal cavernous hemangioma

Posted Date: May 13th, 2020

DOI: https://doi.org/10.21203/rs.2.14177/v5

EDITORIAL NOTE:

The full text of this preprint has been withdrawn by the authors while they make corrections to the work. Therefore, the authors do not wish this work to be cited as a reference. Questions should be directed to the corresponding author.

Abstract

Background: The aim of this study is to evaluate the safety and efficacy of cryo-assisted transconjunctival orbitotomy for the extraction of intraconal cavernous hemangiomas.

Methods: The study was performed at the Mansoura Ophthalmic Center, Mansoura University, Egypt from May 2017 to August 2018 and included 18 patients with orbital intraconal cavernous hemangiomas. In all the cases, preoperative orbital magnetic resonance imaging (MRI) with contrast was performed, the transconjunctival approach was used and cryo-assisted lesion extraction was performed. Cases were followed for six months after the surgery.

Results: This study included 18 patients with intraconal cavernous hemangiomas, ten females (55.6%) and eight males (44.4%) with a mean age of 35.6 years. .The hemangiomas were lateral to the optic nerve in eight(44.5%), above the optic nerve in four cases(22.2%), and below the optic nerve in six cases(33.3%). Eight cases had postoperative complications: three cases (16.7%) had postoperative diplopia due to lateral rectus paresis that improved in all three cases within six months, one case (5.6%) had postoperative retrobulbar hemorrhage and proptosis that resolved within two weeks without sequelae, and four cases (22.2%) showed subconjunctival hemorrhages which resolved within two weeks. Of the two cases with preoperative decreases in visual acuity preoperative, one case (5.6%) showed improvement and one case (5.6%) did not improve.

Conclusions: Cryoprobe-assisted transconjunctival orbitotomy for the excision of intraconal cavernous hemangiomas is a good approach with minor resolvable complications.

Ethics approval : Mansoura institutional review board (IRB)

Registration number: R/17.05.26

Registration date: 10/5/2017

Trial Registration:

Name of registry: ISRCTN Register

Trial registration number: ISRCTN45970569

Retrospectively registered on 24/4/2020

Background

Cavernous hemangioma is the second most common cause of proptosis after thyroid eye disease. [1-3] The intraconal space is the most common location for this tumor, and so it mostly presents with painless, slowly progressive, axial proptosis and diplopia, compressive optic neuropathy may occur in large lesions. [4-5]

Standard lateral orbitotomy with bone flap is the most common approach for treating lesions that are lateral, superior or inferior to the optic nerve; however, it is a long procedure and it is difficult to excise medial intraconal lesions through this procedure. [4-5]

Transconjunctival orbitotomy has gained popularity in recent years because it is, a less traumatizing and more cosmetically-friendly approach than lateral orbitotomy. The use of the standard retinal cryoprobe helps the surgeon to achieve a good grip on the lesion and thus a safer extraction . [6]

In this study we evaluated the safety and efficacy of cryoprobe-assisted transconjunctival extraction of intraconal cavernous hemangiomas of the orbit.

Methods

This is a prospective interventional case series that was performed in the Mansoura Ophthalmic Center, Mansoura University from May 2017 to August 2018. It included 18 patients from the outpatient clinic of the Mansoura Ophthalmic Center with intraorbital, intraconal cavernous hemangiomas who presented with axial proptosis.

Inclusion criteria:

Intraconal cavernous hemangioma was diagnosed on the basis of the clinical features of slowly progressive axial proptosis with or without compression of the optic nerve supported by orbital magnetic resonance imaging(MRI) with contrast and confirmed postoperatively by histopathology of the excised lesions.

Exclusion criteria:

Intraconal, non-compressible, solid lesions that simulate cavernous hemangioma e.g. schwannoma, solitary neurofibroma, and fibrous histiocytoma were excluded because these solid lesions require wider exposure to remove, e.g. through lateral orbitotomy.

We differentiated cavernous hemangioma from other solid lesions as follows:

1. Clinically cavernous hemangioma produces less marked proptosis compared to other variants, even if the hemangioma is large in size, because it is compressible.
2. Under MRI with contrast, angiomas shows moderate enhancement with filling of from the center to the periphery, whereas the other lesions show filling from the periphery to the center(Fig.1).
3. Intraoperatively, the angioma is a compressible, bluish lesion, but the other lesions appear grayish and solid.

In all the cases, full ophthalmological examinations were performed, including; visual acuity testing, ocular motility testing, pupil examination for the detection of afferent pupillary conduction defects, slit-lamp examination of the anterior segment, posterior segment examination by indirect ophthalmoscopy

for detection of optic disc swelling and choroidal folds and measurement of the ocular tension by an applanation tonometer.

The degree of axial proptosis was measured by using a Hertel's exophthalmometer and the levels of horizontal and vertical displacement were measured by using two rulers.

MRI with contrast was performed for all the cases and showed a well-defined rounded or oval mass that was iso-intense to the muscle in T_1 and hyper-intense to the muscle in T_2 and presumed to be cavernous hemangioma. Eight lesions were lateral to the optic nerve, four were above the nerve and six were below the nerve.

After receiving an ethical approval from the Mansoura Institutional Review Board (IRB), written consent was obtained from all the patients and all the surgeries were performed under general anesthesia.

A 180° periotomy was fashioned in the conjunctiva and the site was chosen according to the location of the lesion in the orbit, e.g, for lesions located in the intraconal space superior or lateral to the optic nerve, a conjunctival incision between the superior and inferior recti was performed whereas for lesions inferior to the optic nerve, a conjunctival incision between the lateral and medial recti was performed.

The two exposed recti muscles were retracted and widely separated using muscle hooks. A cotton-tipped applicator was used for the blunt dissection of the orbital fat until the anterior border of the lesion was exposed (Fig.2). Then, the surrounding fluid and blood were dried and a standard retinal cryoprobe(with a tip diameter of 2.5mm) was applied and turned on until an ice ball formed; afterward, the probe was twisted to the right and left until the hemangioma was separated from the surrounding tissues and removed (Fig.3).

Hemostasis was done by using diathermy to cauterize vessels on the surface of the mass before application of the cryoprobe and on the pedicle of vessels on the posterior surface of the mass after extraction; The conjunctiva was closed with polyglactin sutures 6/0.

All the excised masses were sent for histopathology testing, which confirmed that the excised masses were cavernous hemangiomas.

Systemic antibiotics and topical combined antibiotic/steroid eye drops were used for one week after the surgery . Patient follow-ups were conducted one day, one week, one month, three months, and six months after the surgery.

The primary outcome of this study was the incidence of post-operative complications after the cryo-assisted transconjunctival extraction of the intraconal cavernous hemangioma. A total of 18 patients were enrolled in the study. Post-operative complications were recorded in 10 patients (55%). The null hypothesis was that 90% of patients or more would have post-operative complications. A sample size of 18 achieves 89.23% power to detect a difference (P1-P0) of 35% using a two-sided exact test with a target significance level of 0.05. The actual significance level achieved by this test was 0.006 . These results

assume that the population proportion under the null hypothesis (P0) is 0.90. These calculations were conducted by the Power Analysis and Sample Size software program (PASS) version 15.0.5 for Windows (2017) using a two-sided Fisher's test assuming a binomial distribution.

Results

This study included 18 patients with intraconal cavernous hemangiomas, ten females (55.6%) and eight males (44.4%), with a mean age of 35.6 years (range; 21 to 52 years). All the cases presented with axial proptosis; but two cases (11.1%) also presented with vertical diplopia and two cases (11.1%) presented with drops in their visual acuity (best-corrected visual acuity was 0.3 and 0.5) with optic disc swelling in addition to proptosis.

All the lesions were located in the intraconal space: eight lesions (44.5%) were lateral to the optic nerve, four (22.2%) were located above the optic nerve, and six (33.3%) were located below the optic nerve.

The postoperative complications included; three cases (16.7%) with postoperative diplopia due to lateral rectus muscle paresis, which improved within six months; one case (5.6%) with postoperative retrobulbar hemorrhage and proptosis that resolved within two weeks without sequelae; and four cases (22.2%) with subconjunctival hemorrhage that resolved within two weeks.

Visual acuity was not affected except in the two cases that presented preoperatively with drops in visual acuity. One case (5.6%) showed improvement (from 0.3 to 0.5) and the other case (5.6%) did not improve due to long-standing optic nerve compression.

Discussion

Lateral orbitotomy is the traditional approach for treating intraconal cavernous hemangioma; as this gives wide surgical exposure. However, it is a time-consuming major procedure that requires a visible skin incision, creation and reconstruction of a bone flap and a risk of trauma to the lateral rectus muscle with subsequent myopathy. Additionally, it is difficult to approach lesions that are medial to the optic nerve when using this technique. [6]

The transcranial approach is still used by neurosurgeons to approach the intraconal space despite the high rate of morbidity including visual loss, ptosis, orbital hemorrhage, postoperative subdural hematoma and meningitis. This technique should be reserved for lesions at the orbital apex or those with an intracranial extension. [7]

Since its introduction in 1980, transconjunctival anterior orbitotomy has been used to approach the intraconal space. It is not time-consuming, gives better cosmesis than lateral orbitotomy with a low risk of affecting the optic nerve, and it can be tailored according to the location of the lesion.

However, the transconjunctival orbitotomy technique is under-utilized because of the narrow space it presents, its inadequate exposure of deep intraconal lesions and subsequent postoperative complications. [8]

To achieve better results with the transconjunctival approach, the anterior border of the lesions should be close to the posterior pole of the globe; because deeper lesions close to the orbital apex will be masked by the orbital fat and therefore are more difficult to handle. [9]

In this study, we used the transconjunctival approach for excising intraconal cavernous hemangiomas where the masses were present lateral to, above, or below the optic nerve. All the tumors were successfully extracted with the aid of the cryoprobe that provided a good grip on the mass, facilitating removal without affecting the surrounding structures. In this study, three cases showed postoperative lateral rectus myopathy that improved spontaneously within six months, one case showed postoperative retrobulbar hemorrhage that did not compress the optic nerve and improved spontaneously, and four cases showed subconjunctival hemorrhage. Two cases presented preoperatively with drops in visual acuity; one of them showed improvement and one case did not improve after the surgery.

Jin et al. (2008) discussed several studies that had investigated transconjunctival access to the intraconal space; and Lazar et al. (1985) used the transconjunctival approach in 11 patients with intraconal cavernous hemangioma and reported complete, uncomplicated removal of all the tumors. Loewenstein et al. (1993) in a study that included 33 patients with cavernous hemangioma reported the same results as Lazar. [9]

Hayyam et al. (2005) reported complete removal of intraconal cavernous hemangiomas through a transconjunctival approach in 24 cases, but in this study one of the patients lost their vision due to optic nerve trauma. [10]

Xiang et al. (2008) performed transconjunctival cryo-extraction of 36 intraconal lesions; 35 of these lesions were cavernous hemangioma and one of them was diagnosed pathologically as neurilemoma. They reported that this approach is safe; less traumatizing and less time-consuming than other techniques. [11]

Renbeing et al. (2013) reported that the transconjunctival approach is nearly equal to lateral orbitotomy in terms of the improvement of proptosis and rate of complications with decreased operative time. [12]

Cryo-extraction is best used in tumors and cysts that contain fluid (blood or other fluids), rather than in solid tumors, because freezing occurs on the surface of the tumor as well as in the stroma and fluid or blood inside. Consequently, the outer and inner ice balls allow a strong grip to be applied by the probe, which makes cavernous hemangiomas ideal for this approach. [13]

Gdal-On et al. used cryo-assisted extraction of intraconal hemangiomas and reported easy extraction in lesions that touched the globe, but they did not recommend this approach in deeper lesions that reached

the orbital apex; as this technique may endanger the apical structures. [14]

Tsirbas et al. (2005) reported that the use of the cryoprobe for the removal of intraconal tumors through the transconjunctival approach decreased the rate of complications associated with the surgery [15].

Castelnuovo et al. (2019) used the cryoprobe to extract two orbital cavernous hemangiomas transnasally and reported that the cryoprobes represent an adjunctive tool in the extraction of fluid-filled intraorbital lesions. [16]

One of the limitations of this approach is the narrow working space, and therefore the lesion's anterior margin should be adjacent to the globe for easy, safe, handling and removal of the tumors. However, more posterior lesions will be more difficult to manipulate and will be masked by orbital fat. Use of the standard retinal cryoprobe provides a good grip on the mass. even in deep lesions, without affecting the surrounding structures .[16]

In this study, we found that the use of a cryoprobe for tumor extraction helps with the removal of deeper lesions that are not touching the back of the globe after exposure of a sufficient portion of the mass to provide a good grip and after retraction of the surrounding fat. Retrobulbar hemorrhage and rupture of the angioma are possible complications and should be avoided through good intraoperative hemostasis and gentle dissection of the mass, respectively.

Conclusion

We concluded that cryoprobe-assisted transconjunctival orbitotomy for the excision of intraconal cavernous hemangiomas represents a good approach with minor resolvable complications. However, it is worth noting that we did not have any cases with hemangiomas that were medial to the optic nerve in this study. Further comparative studies on a larger group of patients are needed to further evaluate the safety and efficacy of the technique.

Declarations

Ethics approval and consent to participate

The study was approved by the Mansoura IRB

R/17.05.26 on 10/5/2017 and all participants gave their written consent.

Consent to publish

Not applicable

Availability of data and materials

The datasets generated and analysed during the current study are not publicly available due to privacy of the patients but are available from the corresponding author on reasonable request.

Competing interest

There are no conflicts of interest.

No external or third-party financial support was involved.

Funding

No external or third-party financial support was involved.

Author contributions

AA performed the surgery for all cases and wrote and submitted the manuscript.SS and AE reviewed the manuscript and analyzed the results. AA revised the manuscript. All the authors have read and approved the manuscript.

Acknowledgement

Not applicable

References

1. Casper DS, Chi TL, Trokel SL. Orbital disease: Imaging and analysis. New York: Thieme Medical Publisher 1993: 81-97
2. Scheuerle AF, Steiner HH, Kolling G, Kunze S, Aschoff A. Treatment and long-term outcome of patients with orbital cavernomas. Am J Ophthalmol 2004;138:237-44.
3. Rootman J. Diseases of the orbit: A multidisciplinary approach. 2nd ed. Philadelphia: Lippincott Williams & Wilkins 2003:420-60
4. Wirtschafter JD, Chu AE. Lateral orbitotomy without removal of the lateral orbital rim. Arch Ophthalmol 1988;106:1463- 68.
5. Aria H, Sato K, Katsuda T, Rhoton AL. Lateral approach to intraorbital lesions: Anatomic and surgical considerations. Neurosurgery 1996; 39: 1157-62.
6. Kyong J C, Ji-Sun P, Suk-Woo Y. Surgical outcomes of transconjunctival anterior orbitotomy for intraconal orbital cavernous hemangioma. Korean J Ophthalmol 2010; 24(5):274-78.
7. Missori P, Tarantino R, Delfini R, Lunardi P, Cantore G. Surgical management of orbital cavernous angiomas: prognosis of visual functions after removal. Neurosurgery 1994; 35:34-38.
8. Yan J, Wu Z. Cavernous hemangioma of the orbit: Analysis of 214 cases. Orbit 2004; 23:33-40.
9. Jin WC, Rui LW, Ji PC, You L. Transconjunctival orbitotomy for orbital cavernous hemangiomas. Can J Ophthalmol 2008; 43:234-38.

10. Hayyam K, Burcin B, Sevgul B. Transconjunctival approach for retrobulbar intraconal orbital cavernous hemangiomas. Orbital surgeon perspective. World Neurosurgery 2005; 64:71-74.
11. Xiang Q, Xu XL, Jiang HB. Transconjunctival surgical cryoextraction of introconal orbital cavernous hemangiomas. J Cent South Un 2008; 33(6):537-40.
12. Renbing J, Xianqun F. Transconjunctival versus lateral orbitotomy approach for retrobulbar intraconal orbital cavernous hemangioma- A comparative study of long term outcomes. IOVS 2013; 54:740-47.
13. Manquez ME, Shields CL,Karatza EC, Shields JA. Fingertip cryoprobe assisted orbital tumour extraction. BJO 2004; 49 :777-8.
14. Gdal-On M, Gelfand YA. Surgical outcome of transconjunctival cryosurgical extraction of orbital cavernous hemangioma. Ophthalmic Surg Lasers 1998;29 :969-73.
15. Tsirbas A, Kazim M, Close L. Endoscopic approach to orbital apex lesions. Ophthal Plast Reconstr Surg 2005; 21: 271-75.
16. Castelnuovo P, Arosio AD, Volpi L, De Maria F, Ravasio A, Donati S, et al. Endoscopic Transnasal Cryo-Assisted Removal of Orbital Cavernous Hemangiomas: Case Report and Technical Hints. World Neurosurg. 2019; 126:66-71.

Figures

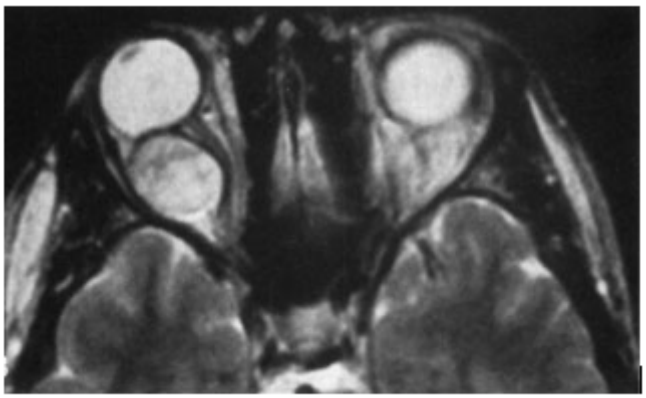

Figure 1

Axial MRI(T2-weighted image) demonstrates a well-defined, homogeneous intraconal mass hyperintense to the muscle

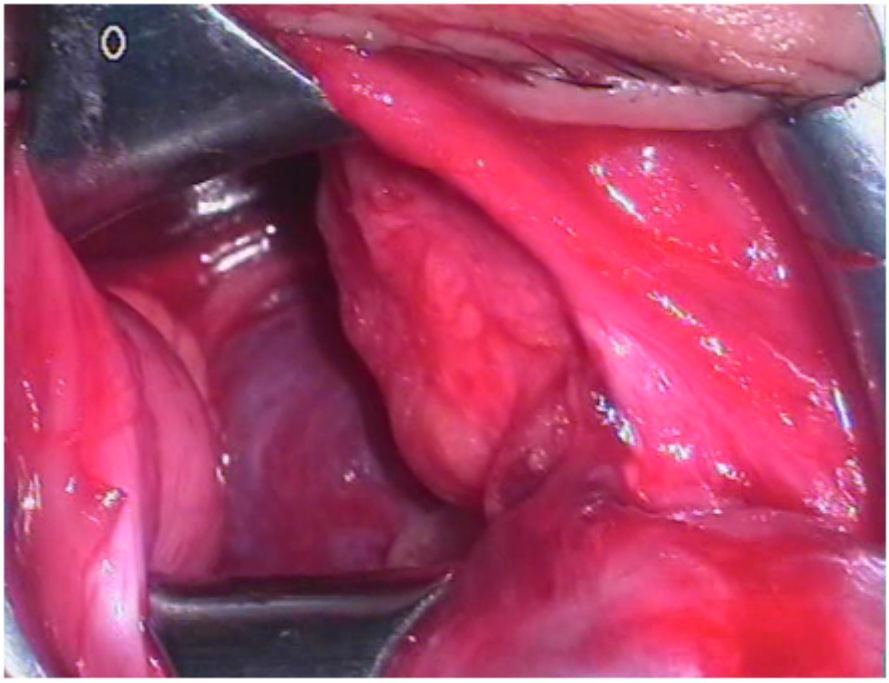

Figure 2

intraoperative transconjunctival exposure of intraconal cavernous hemangioma

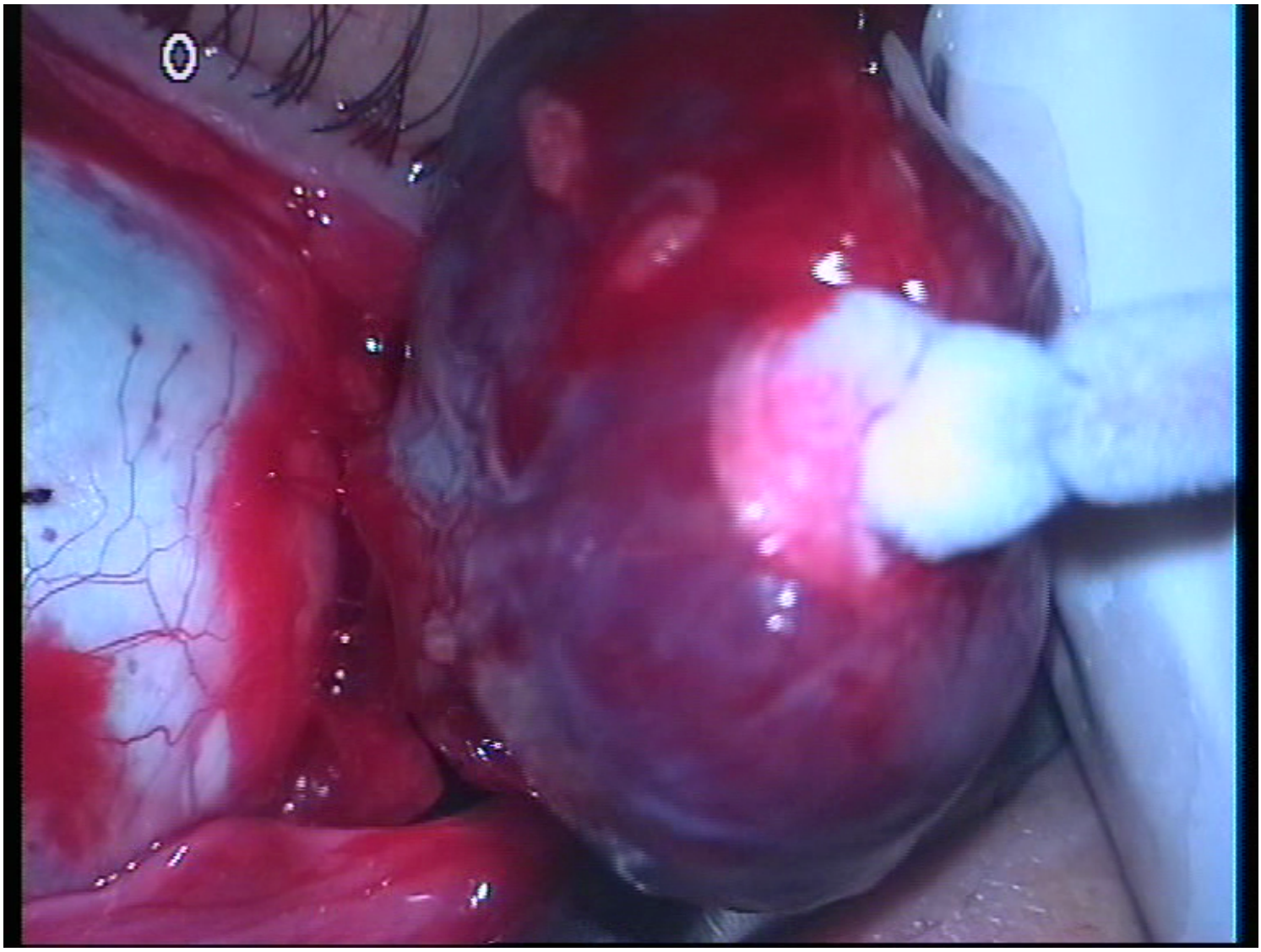

Figure 3

intraoperative transconjunctival Cryo-assisted extraction of intraconal cavernous hemangioma

Supplementary Files

This is a list of supplementary files associated with this preprint. Click to download.

- video.avi