Analysis of curative effect: percutaneous transforaminal endoscopic discectomy for lumbar disc herniation with buttock pain as the main symptom

Jun-Yan An
The Second Hospital of Jilin University
Jun Zhang
The Second Hospital of Jilin University
Jiu-Ping Wu
The Second Hospital of Jilin University
Tong Yu
The Second Hospital of Jilin University
Wu Xue
The Second Hospital of Jilin University
Le Qi
The Second Hospital of Jilin University
Qin-Yi Liu (qinyi@jlu.edu.cn)
The Second Hospital of Jilin University

Research Article

Keywords: Lumbar disc herniation, gluteal, buttock pain, minimally invasive surgery, percutaneous transforaminal endoscopic discectomy

Posted Date: May 14th, 2021

DOI: https://doi.org/10.21203/rs.3.rs-492938/v1

Abstract

Background

. Lumbar disc herniation (LDH) is a common disease in spinal surgery which often causes acute radicular pain. However, LDH with buttock pain (BP) as the main clinical symptom is rare. Herein, we retrospectively evaluated the efficacy and safety of percutaneous transforaminal endoscopic discectomy (PTED) in the treatment of LDH with the buttock as the primary clinical symptom.

Methods

. Totally 12 patients have LDH (L4-5) with BP who underwent PTED from January 2019 to June 2020 were enrolled. All patients performed magnetic resonance imaging (MRI) and computed tomography (CT) preoperatively, 1 week postoperatively, and at follow-up. The pain relieve were evaluated by the Visual analog scale (VAS), the functional recovery was assessed by Oswestry disability index (ODI) and Roland-Morris questionnaire (RMQ). Parameters were evaluated preoperatively, immediately after surgery, 1 month, 3 months and 6 months after surgery, respectively. Moreover, the lumbar function was determined by modified MacNab criteria.

Results

. Pain relieve was found in 11 patients postoperatively. The VAS, ODI and RMQ scores were improved significantly at the latest follow up visit compared to preoperative ($P < 0.05$). One patient suffered from LDH recurrence one month after operation and received revision surgery, then achieved satisfied effect. Two patients experienced residual BP after operation and obtained good clinical outcomes by conservative treatment. No other surgical complications were found during follow up period. The average length of follow-up was 6.68 ± 0.67 months.

Conclusion.

PTED is a safe and efficacious method in treating LDH with BP.

Background

LDH is a degenerative disease (1) caused by intervertebral disc degeneration, leading to acute lumbosacral radiculopathy and sciatica. Recently, we have found some patients with LDH whose symptoms are mainly BP. Fang et al (2) found that about three-quarters of the patients with LDH showed BP, among which L4/5 disc herniation was the main cause of BP.

At present, patients who suffer LDH with BP always adopt conservative treatment. Although non-surgical treatment has withstood the test of time, surgical treatment also seems to be an excellent choice (1). The long-term result of Spine prognosis study showed (3–5) that compared with the non-operative group, the operation group had a significant improvement in pain, function and satisfaction. Traditional surgical treatments, such as open lumbar discectomy, can partly solve the symptoms of patients. However, it still has various disadvantages, including large surgical trauma, more intraoperative bleeding, and slow postoperative recovery (6). With the development of endoscopy technology and instruments, surgeons have more and more experience and patients who need surgery are more inclined to choose minimally invasive treatment, which leads to the rapid development of minimally invasive spinal surgery (7). PTED has become the most commonly used minimally invasive technique in recent decades (8, 9) because of its smaller incision, faster recovery, lower wound infection rate, almost no damage to muscles and soft tissue structures and small extent postoperative epidural fibrosis (10–13). Moreover, the overall postoperative complications of PTED are lower and studies have shown that (14, 15) there is no significant difference in long-term results between PTED and open lumbar discectomy.

Up to now, there is almost no relevant literature describing the use of PTED in the treatment of LDH with BP as the main manifestation. Therefore, we retrospectively analyzed 12 patients who had LDH with BP as the main symptom treated with PTED to evaluate the safety and effectiveness of this minimally invasive method.

Methods

Patient Characteristics

All experiments were performed in accordance with relevant guidelines and regulations. We retrospectively studied 193 patients with lumbar disc herniation who were admitted to our hospital from January 2019 to June 2020. All patients have received the same surgical strategies which performed by our corresponding author. The two trained surgeons independently performed the data extraction from the medical records. If the results are consistent, the data is considered valid. However, if the results are inconsistent, the trained surgeons need to re-envaulted the data until a consensus was reached. Subsequently, 12 patients who presented for BP were enrolled.

Inclusion Criteria

The indications for PTED treatment were as follows: (1) MRI and CT were diagnosed as L4/5 disc herniation. (2) The patient complained mainly of BP with or without slightly low back pain or occasional lower limb pain or numbness. (3) All participants were administered to accept PTED for the alleviation of symptoms.

Exclusion criteria

The contraindications for PTED treatment were as follows: (1) Patients who have received non-operative treatment. (2) The patients who underwent open lumbar discectomy or other surgical methods. (3) The

participants with severe mental illness, peripheral nerve injury and severe psychological disorders.

Surgical technique

The patient was placed in the lateral position with the affected side facing upward, with a thin pillow at waist. knee flexion and hip flexion. The herniated disc was verified and the direction and site of puncture was marked using C-arm fluoroscopy. Disinfection and draping were performed conventionally. The procedure was performed with a posterolateral approach. Local anesthesia was administrated into the skin, subcutaneous tissue, up to the tip of the superior articular process (SAP). At 12–14 cm from the midline, make an incision 2 cm above the level of intervertebral space and then 0.7 cm towards the midline. An 18-gauge puncture needle was inserted from the incision to the SAP of the lower involved vertebrae under fluoroscopy, and then dilate the soft tissue with a layer-by-layer dilation catheter. Step by step resection of the ventral and tip of the SAP with a trephine to enlarge the intervertebral foramen. C-arm confirmed that the trajectory of the working channel is within the range of the Kambin's triangle, as described in previous study (16). After confirming that the working sleeve enters into the intervertebral space under fluoroscopy, connect the endoscope, light source, imaging system and other equipment. Then, the intervertebral foramen area was continuously irrigated with normal saline intraoperative. The surface of the SAP was first identified.

With regard to the most critical procedure of nerve root decompression, we have adopted the following methods (1) Removal of herniated nucleus pulposus. (2) Denervation of annulus fibrosus by bipolar electrocoagulation. (3) Lateral recess formation. (4) Partial resection of posterior longitudinal ligament (PLL) and fibrous annulus in the posterolateral region of the superior edge of the inferior vertebral body. Bipolar electrocoagulation was used to fully stop bleeding and eliminate the peripheral hyperplasia of small nerves. The intervertebral space was explored in order to remove the loose nucleus pulposus. After nerve root decompression was completed (Fig. 1), fluid gelatin was injected before retracting the working cannula, and the skin was sutured.

Statistical Analysis

All data management and statistical analysis were performed with Graphpad version 8.0.1. The measurement data was expressed as mean ± standard deviation. $P < 0.05$ was considered to be statistically significant. We recorded the preoperative basic information of 12 patients, including gender, age, duration of symptoms and affected side (Table.1). The clinical outcomes were assessed by VAS for BP, and the postoperative functional recovery was evaluated by ODI and RMQ. The excellent and good rate was determined by modified MacNab criteria. The average follow-up time was 6.68 ± 0.67 months.

Results

Patients and surgical characteristics

This study included 6 males and 6 females with an average age of 54.42 ± 10.98 (range from 26 to 70 years). All participants completed the questionnaire, including the VAS score, ODI, RMQ score and modified MacNab criteria. The average surgical time was 39.46 minutes and The average length of hospital stay was 4 days.

Complications

1 patient had a recurrence of LDH 1 month after operation for which reoperation was required. After the second operation, there were still some residual symptoms. There were two patients developed residual BP after operation and were relieved after 2 weeks conservative treatment. All patients successfully completed PTED operation under local anesthesia without spinal cord injury, nerve root injury and other complications.

Clinical Outcomes and Follow-up

The results showed that the BP was relieved in the patients treated with PTED. The mean VAS score decreased from 7.33 ± 0.65 before treatment to 2.17 ± 0.558, 2.75 ± 1.36, 2.00 ± 0.85, 1.67 ± 0.98 immediately, at one month, 3 months, and 6 months after treatment. After six months of follow-up, the ODI and RMQ scores were significantly decreased in 11 patients who had undergo PTED (Fig. 2). The excellent or good rate of patients after operation was evaluated according to the modified MacNab criteria (Fig. 3). 75.00% (9 participants), 50.00% (6 participants) and 83.33% (10 participants) were considered excellent or good immediately, 1 month and 3 months after the operation, respectively. At the time of the last follow-up, the excellent or good rate of lumbar function had reached 91.67% (11 Participants). Statistical analysis shows that there is a significant difference before and after treatment, which is statistically significant($P < 0.05$).

Case Presentation

A 50-year-old male patient (Case.1) complained of BP as the main symptom for 12 months and had no history of trauma. He was treated in a local hospital and was diagnosed as “Piriformis Syndrome” (PS). After two weeks of treatment, the symptoms were not significantly relieved and transferred to our institution for treatment. The physical examination found that the patient merely showed simple BP, no low back pain and lower limb symptoms. There were clear tenderness points in the buttock region. After a detailed review of MRI, it was suspected to be LDH. In order to make a definite diagnosis, the patient was given a selected nerve root block and BP disappeared. Lumbar MRI before the operation showed (Fig. 4) that the lumbar disc was herniated in L4/5, the compression of the lateral recess resulting in lateral recess stenosis. the VAS score was 8, and the ODI and RMQ scores were 70 and 23, respectively. After the PTED (Fig. 5), the pain of the patient was significantly relieved and he was able to walk after returning to the ward. the VAS score of the patient decreased from 8 points to 2 points after operation, the ODI score was 26 points, and the RMQ score developed to 8 immediately postoperative. One month after operation, the patient was able to do their daily work and expressed his satisfaction with the operation.

Discussion

So far, surgeons have not paid much attention to the mainly BP caused by LDH. On the one hand, according to our clinical findings, the incidence of LDH leading to BP as the main symptom is not high, and few surgeons associate BP with LDH. On the other hand, clinical misdiagnosis and mistreatment often occur. Under such conditions, the symptoms of patients often cannot be effectively resolved, affecting the quality of life of patients.

In addition to LDH, there are other factors that can cause BP, such as referred pain caused by facet joint or sacroiliac joint, proximal sciatica, deep gluteal syndrome (17–19), PS and peripheral nerve injury, among which PS is most easily confused with the cases described in this study. PS describes non-discogenic pain in the buttock caused by extrapelvic compression of the sciatic nerve (20). Factors leading to sciatic nerve compression include piriformis spasm (21, 22), anatomical changes of piriformis (23–25), piriformis hypertrophy (26) and buttock trauma (27). Walking/bending/lifting will aggravate the symptoms (28). Signs include piriformis tenderness, piriformis muscle stretch pain, positive signs of straight leg raising test, gluteal atrophy and weakness (29). Among the participants included in this study, several patients had been misdiagnosed as PS and were ineffective after treatment. Therefore, the accurate diagnosis of the disease before operation is very important. Surgeons should carefully review the MRI of patients, conduct a careful physical examination before surgery, and further rule out other diseases through selected nerve root blocks. During the operation, actively communicate with the patients and ask whether the pain has been alleviated. Long-term follow-up of patients after operation is also essential.

Studies have shown (30) that there is a significant correlation between nerve root symptoms caused by LDH and BP. But the specific mechanism is not clear. Based on previous studies (17), we have identified the following possible causes of BP, and further found that BP may be related to intervertebral discs. (1) Referred pain in buttock caused by sinus vertebral nerves (SVN): Li (31) has studied the SVN and found that 100% of the SVN can be seen in the intervertebral foramen. Most of the trunk of the SVN originated from the spinal ganglion of the posterior root of the spinal nerve (77, 58%). Nucleus pulposus itself is not an inert substance, but has biological activity, which can generate a series of inflammatory mediators (32), resulting in changes in vascular endothelial cells, which will increase vascular permeability, dilate blood vessels, and make immune cells adhere to this site. Lead to the transmission of inflammatory cytokines (33). Therefore, when the lumbar intervertebral disc is herniated, the nerve terminal receptors of SVN were in a highly sensitive state (34), which reduced the pain threshold. Because the SVN and the L5 nerve root are located in the same spinal cord. There may be referred pain in the buttock. (2) All the anterior branch of L5 nerve root forms the superior and inferior gluteal nerves: The sacral plexus is composed of the lumbosacral trunk from the lumbar plexus and the anterior branches of the sacral and coccygeal nerves. The lumbosacral trunk is synthesized below the lumbar plexus by some of the fibers of the anterior branch of the L4 and all the fibers of the L5. The sacral plexus emits many branches, including the superior gluteal nerve formed by the confluence of L4-S1, and the inferior gluteal nerve synthesized by L5-S2. They control the sensation and movement of gluteal muscles (35, 36). BP may

occur when the protruding nucleus pulposus oppresses the anterior branch of the L5 nerve root. (3) Compression of the posterior branch of the spinal nerve: In anatomy, the anterior root is connected to the anterolateral sulcus of the spinal cord, which is composed of motor nerve filaments, and the posterior root is connected to the posterolateral sulcus of the spinal cord, which is composed of sensory nerve root filaments. From this, a mixed nerve root is formed in intervertebral foramen. Many studies have shown (37, 38) that the posterior branches of L4 and L5 spinal nerves are also involved in forming superior cluneal nerves. Through anatomical studies, Iwanaga et al (39) have confirmed that about 10% of the superior cluneal nerves come from the L5 nerve, which is a group of pure sensory nerve fibers that control the gluteal region (40, 41). Therefore, we speculate that when L4-5 disc is herniated, the nucleus pulposus oppresses the posterior branch of the L5 nerve root, resulting in BP.

At present, there is no research on the treatment of this kind of LDH. Therefore, we have drawn a plan for endoscopic treatment of gluteal pain, and proved that our treatment method has a certain clinical significance in operation. (1) Removal of herniated nucleus pulposus: relieving mechanical compression and inflammatory stimulation of nerve roots. (2) Denervation of annulus fibrosus by bipolar electrocoagulation: Li et al (31) have shown that the SVN originates from the posterolateral edge of the intervertebral disc to the spinal canal, and the accessory branches of the SVN enter directly into the posterolateral margin of the intervertebral disc. Among them, 55.8% of the main trunk of the SVN originates from the spinal ganglion of the posterior root of the spinal nerve. When disc herniation, the SVN is in a highly sensitive state (34), resulting in discogenic gluteal pain. The use of bipolar electrocoagulation to eliminate the SVN around the intervertebral disc to reduce nerve hypersensitivity. (3) Lateral recess formation: During the operation, we performed the method of “decompression around the lateral recess” to remove hyperplastic osteophytes from the posterior edge of the vertebral body. Besides, we also used high-speed grinding drill and endoscopic osteotome to remove the facet joints with hyperosteogenesis, and removed part of the ligamentum flavum near the lateral recess so as to achieve complete decompression. (4) Partial resection of PLL and fibrous annulus at the upper edge of the inferior vertebral body: LDH is one of the most common chronic degenerative diseases of the lumbar spine (1, 42). Patients may have a long history of disease, characterized by hypertrophy of annulus fibrosus and PLL. Through cadaver experimental study, Raoul et al. (43) found that some of the ascending branch of the SVN originates from the PLL, the ventral side of the dura mater and intervertebral disc, and the descending branch originates from the deep layer of the PLL and the intervertebral disc. Through microscopic observation of the sensory fibers of the PLL (44), it was found that it received a large number of traffic fibers from the SVN and formed a fiber network with the SVN from the opposite side. There are many branches of the SVN on the PLL and fibrous annulus in the posterolateral part of the superior edge of the inferior vertebral body. Therefore, in addition to the above treatment, resection of part of the PLL and fibrous annulus are helpful for the relief of BP. 12 patients with BP were treated by the method described in this study. All patients had L4/5 disc herniation with BP that lasted for at least 6 months. The BP of 11 patients was relieved after the PTED operation, and the pain was significantly relieved or even disappeared after 6 months of follow-up. One patient had recurrence of LDH at 1 month postoperative and the other two patients developed slightly residual BP after the

operation. There were no adverse events such as nerve root injury, massive bleeding and cerebrospinal fluid leakage during the operation. and no postoperative infection, lower extremity thrombosis, pressure sores and other postoperative complications. We attribute all these good results to accurate preoperative diagnosis and the removal of the disc by PTED technique.

There are also some limitations: (1) A relatively small sample size may lead to differences in the results. (2) All the patients included in this study had L4/5 disc herniation, This study did not explore whether other disc herniation would cause BP.

Conclusion

LDH with BP as the main symptom affects the quality of life of patients, which is enough to attract the attention of surgeons. However, there is no standardized treatment for this symptom. Most patients choose conservative treatment, but the curative effect is often unsatisfactory. Minimally invasive surgery, a more and more popular technique, has achieved good results in the treatment of BP, so we believe that PTED is a safe and efficacious method in treating LDH with BP.

Abbrevitions

LDH: Lumber disc herniation

PTED: Percutaneous transforaminal endoscopic discectomy

BP: Buttock pain

MRI: Magnetic resonance imaging

CT: Computed tomography

VAS: Visual analog scale

ODI: Oswestry disability index

RMQ: Roland morris questionnaire

SAP: Superior articular process

PLL: Posterior longitudinal ligament

PS: Piriformis syndrome

SVN: Sinus vertebral nerves

Declarations

Ethical approval and consent to participate

This report was approved by the ethics committee of the Second Hospital of Jilin University, Changchun, China (In 2021, research review No.001). All patients included in the study signed written informed consent.

Consent for publication

Not applicable.

Availability of data and materials

The datasets used during the current study are available from the corresponding author on reasonable request.

Competing interests

The authors declare that they have no competing interests.

Funding

Supported by Graduate Innovation Fund of Jilin University.

Authors' contributions

JYA, JPW, and QYL participated in the study design and surgery; JZ , WX and LQ participated in surgery and radiographic outcome assessment. JYA and JPW collected all data. Data analysis was performed by TY under supervision of QYL. All authors contributed in reviewal and interpretation of data. The manuscript was drafted by JYA, reviewed by all authors and revised

with contributions from all authors under supervision and final revision of QYL. QYL was responsible for the integrity of the work from inception to finished article. All authors read and approved the final manuscript.

Acknowledgments

None

References

1. Benzakour T, Igoumenou V, Mavrogenis AF, Benzakour A: Current concepts for lumbar disc herniation. Int Orthop 2019, 43(4):841-51.
2. Fang G, Zhou J, Liu Y, Sang H, Xu X, Ding Z: Which level is responsible for gluteal pain in lumbar disc hernia? BMC Musculoskelet Disord 2016, 17(1):356.

3. Weinstein JN, Lurie JD, Tosteson TD, Skinner JS, Hanscom B, Tosteson AN, Herkowitz H, Fischgrund J, Cammisa FP, Albert T *et al*: Surgical vs nonoperative treatment for lumbar disk herniation: the Spine Patient Outcomes Research Trial (SPORT) observational cohort. JAMA 2006, 296(20):2451-9.
4. Weinstein JN, Lurie JD, Tosteson TD, Tosteson AN, Blood EA, Abdu WA, Herkowitz H, Hilibrand A, Albert T, Fischgrund J: Surgical versus nonoperative treatment for lumbar disc herniation: four-year results for the Spine Patient Outcomes Research Trial (SPORT). Spine (Phila Pa 1976) 2008, 33(25):2789-800.
5. Lurie JD, Tosteson TD, Tosteson AN, Zhao W, Morgan TS, Abdu WA, Herkowitz H, Weinstein JN: Surgical versus nonoperative treatment for lumbar disc herniation: eight-year results for the spine patient outcomes research trial. Spine (Phila Pa 1976) 2014, 39(1):3-16.
6. Shi R, Wang F, Hong X, Wang YT, Bao JP, Liu L, Wang XH, Xie ZY, Wu XT: Comparison of percutaneous endoscopic lumbar discectomy versus microendoscopic discectomy for the treatment of lumbar disc herniation: a meta-analysis. Int Orthop 2019, 43(4):923-37.
7. Telfeian AE, Veeravagu A, Oyelese AA, Gokaslan ZL: A brief history of endoscopic spine surgery. Neurosurg Focus 2016, 40(2):E2.
8. Kanno H, Aizawa T, Hahimoto K, Itoi E: Minimally invasive discectomy for lumbar disc herniation: current concepts, surgical techniques, and outcomes. Int Orthop 2019, 43(4):917-22.
9. Vaishnav AS, Othman YA, Virk SS, Gang CH, Qureshi SA: Current state of minimally invasive spine surgery. J Spine Surg 2019, 5(Suppl 1):S2-S10.
10. Mlaka J, Rapcan R, Burianek M, Rapcanova S, Gajdos M, Kocanova M, Griger M, Kovalicova L, Vaskova J, Kocan L: Endoscopic discectomy as an effective treatment of a herniated intervertebral disc. Bratisl Lek Listy 2020, 121(3):199-205.
11. Sairyo K, Chikawa T, Nagamachi A: State-of-the-art transforaminal percutaneous endoscopic lumbar surgery under local anesthesia: Discectomy, foraminoplasty, and ventral facetectomy. J Orthop Sci 2018, 23(2):229-36.
12. Chen J, Jing X, Li C, Jiang Y, Cheng S, Ma J: Percutaneous Endoscopic Lumbar Discectomy for L5S1 Lumbar Disc Herniation Using a Transforaminal Approach Versus an Interlaminar Approach: A Systematic Review and Meta-Analysis. World Neurosurg 2018, 116:412-20 e2.
13. Ahn Y, Lee HY, Lee SH, Lee JH: Dural tears in percutaneous endoscopic lumbar discectomy. Eur Spine J 2011, 20(1):58-64.
14. Cong L, Zhu Y, Tu G: A meta-analysis of endoscopic discectomy versus open discectomy for symptomatic lumbar disk herniation. Eur Spine J 2016, 25(1):134-43.
15. Khandge AV, Sharma SB, Kim JS: The Evolution of Transforaminal Endoscopic Spine Surgery. World Neurosurg 2021, 145:643-56.
16. Pan Z, Ha Y, Yi S, Cao K: Efficacy of Transforaminal Endoscopic Spine System (TESSYS) Technique in Treating Lumbar Disc Herniation. Med Sci Monit 2016, 22:530-9.
17. Wang Y, Yang J, Yan Y, Zhang L, Guo C, Peng Z, Kong Q: Possible pathogenic mechanism of gluteal pain in lumbar disc hernia. BMC Musculoskelet Disord 2018, 19(1):214.

18. Kurosawa D, Murakami E, Aizawa T: Referred pain location depends on the affected section of the sacroiliac joint. Eur Spine J 2015, 24(3):521-7.
19. Bartynski WS: Clinical, anatomic, and imaging correlation in spine-related pain: the essential elements. Tech Vasc Interv Radiol 2009, 12(1):2-10.
20. Martin HD, Reddy M, Gomez-Hoyos J: Deep gluteal syndrome. J Hip Preserv Surg 2015, 2(2):99-107.
21. Filler AG, Haynes J, Jordan SE, Prager J, Villablanca JP, Farahani K, McBride DQ, Tsuruda JS, Morisoli B, Batzdorf U *et al*: Sciatica of nondisc origin and piriformis syndrome: diagnosis by magnetic resonance neurography and interventional magnetic resonance imaging with outcome study of resulting treatment. Journal of neurosurgery Spine 2005, 2(2):99-115.
22. Fishman LM, Anderson C, Rosner B: BOTOX and physical therapy in the treatment of piriformis syndrome. American journal of physical medicine & rehabilitation 2002, 81(12):936-42.
23. Koh E, Webster D, Boyle J: Case report and review of the potential role of the Type A piriformis muscle in dynamic sciatic nerve entrapment variant of piriformis syndrome. Surg Radiol Anat 2020, 42(10):1237-42.
24. Wun-Schen C: Bipartite piriformis muscle: an unusual cause of sciatic nerve entrapment. Pain 1994, 58(2):269-72.
25. Natsis K, Totlis T, Konstantinidis GA, Paraskevas G, Piagkou M, Koebke J: Anatomical variations between the sciatic nerve and the piriformis muscle: a contribution to surgical anatomy in piriformis syndrome. Surg Radiol Anat 2014, 36(3):273-80.
26. Broadhurst NA, Simmons DN, Bond MJ: Piriformis syndrome: Correlation of muscle morphology with symptoms and signs. Arch Phys Med Rehabil 2004, 85(12):2036-9.
27. Beauchesne RP, Schutzer SF: Myositis ossificans of the piriformis muscle: an unusual cause of piriformis syndrome. A case report. The Journal of bone and joint surgery American volume 1997, 79(6):906-10.
28. Kirschner JS, Foye PM, Cole JL: Piriformis syndrome, diagnosis and treatment. Muscle Nerve 2009, 40(1):10-8.
29. Vas L, Pai R, Pawar KS, Pattnaik M: "Piriformis Syndrome": Is It Only Piriformis? Pain Med 2016, 17(9):1775-9.
30. Adelmanesh F, Jalali A, Jazayeri Shooshtari SM, Raissi GR, Ketabchi SM, Shir Y: Is There an Association Between Lumbosacral Radiculopathy and Painful Gluteal Trigger Points?: A Cross-sectional Study. American journal of physical medicine & rehabilitation 2015, 94(10):784-91.
31. Zhao Q, Cheng L, Yan H, Deng S, Zhao J, Liu Z, Tan X, Zhong E, Zhuo W, Jin D *et al*: The Anatomical Study and Clinical Significance of the Sinuvertebral Nerves at the Lumbar Levels. Spine (Phila Pa 1976) 2020, 45(2):E61-E6.
32. Cosamalón-Gan I, Cosamalón-Gan T, Mattos-Piaggio G, Villar-Suárez V, García-Cosamalón J, Vega-Álvarez JA: Inflammation in the intervertebral disc herniation. Neurocirugía (English Edition) 2021, 32(1):21-35.

33. Amin RM, Andrade NS, Neuman BJ: Lumbar Disc Herniation. Curr Rev Musculoskelet Med 2017, 10(4):507-16.
34. McNally DS, Naish C, Halliwell M: Intervertebral disc structure: observation by a novel use of ultrasound imaging. Ultrasound in medicine & biology 2000, 26(5):751-8.
35. Ling ZX, Kumar VP: The course of the inferior gluteal nerve in the posterior approach to the hip. J Bone Joint Surg Br 2006, 88(12):1580-3.
36. Akita K, Sakamoto H, Sato T: Origin, course and distribution of the superior gluteal nerve. Acta anatomica 1994, 149(3):225-30.
37. Konno T, Aota Y, Kuniya H, Saito T, Qu N, Hayashi S, Kawata S, Itoh M: Anatomical etiology of "pseudo-sciatica" from superior cluneal nerve entrapment: a laboratory investigation. J Pain Res 2017, 10:2539-45.
38. Akbas M, Yegin A, Karsli B: Superior cluneal nerve entrapment eight years after decubitus surgery. Pain practice : the official journal of World Institute of Pain 2005, 5(4):364-6.
39. Iwanaga J, Simonds E, Schumacher M, Oskouian RJ, Tubbs RS: Anatomic Study of Superior Cluneal Nerves: Revisiting the Contribution of Lumbar Spinal Nerves. World Neurosurg 2019, 128:e12-e5.
40. Kikuta S, Iwanaga J, Watanabe K, Tubbs RS: Revisiting the Middle Cluneal Nerves: An Anatomic Study with Application to Pain Syndromes and Invasive Procedures Around the Sacrum. World Neurosurg 2019, 127:e1228-e31.
41. Tubbs RS, Levin MR, Loukas M, Potts EA, Cohen-Gadol AA: Anatomy and landmarks for the superior and middle cluneal nerves: application to posterior iliac crest harvest and entrapment syndromes. Journal of neurosurgery Spine 2010, 13(3):356-9.
42. Stevens S, Agten A, Timmermans A, Vandenabeele F: Unilateral changes of the multifidus in persons with lumbar disc herniation: a systematic review and meta-analysis. Spine J 2020, 20(10):1573-85.
43. Raoul S, Faure A, Robert R, Rogez JM, Hamel O, Cuillere P, Le Borgne J: Role of the sinu-vertebral nerve in low back pain and anatomical basis of therapeutic implications. Surg Radiol Anat 2003, 24(6):366-71.
44. Imai S, Konttinen YT, Tokunaga Y, Maeda T, Hukuda S, Santavirta S: Tyrosine hydroxylase-immunoreactive nerve fibres in rat posterior longitudinal ligament. Journal of the autonomic nervous system 1997, 63(1-2):51-60.

Table

Table 1. Clinical data

Case	Gender	Age	Symptom Duration(mos.)	Side of operation	Follow-up (mos.)
1	M	50	12	L	6.5
2	F	61	7	L	6.1
3	M	57	14	L	6.7
4	M	70	9	R	7.3
5	M	55	10	L	6.7
6	F	65	13	R	6.3
7	F	51	15	R	6.0
8	F	47	7	R	7.2
9	M	57	6	L	8.3
10	F	55	9	L	6.3
11	M	26	10	R	6.0
12	F	59	11	L	6.8
Mean value	-	54.42±10.98	10.25±2.86	-	6.68±0.67

Note: M: male. F: female. Mos.: months.

Figures

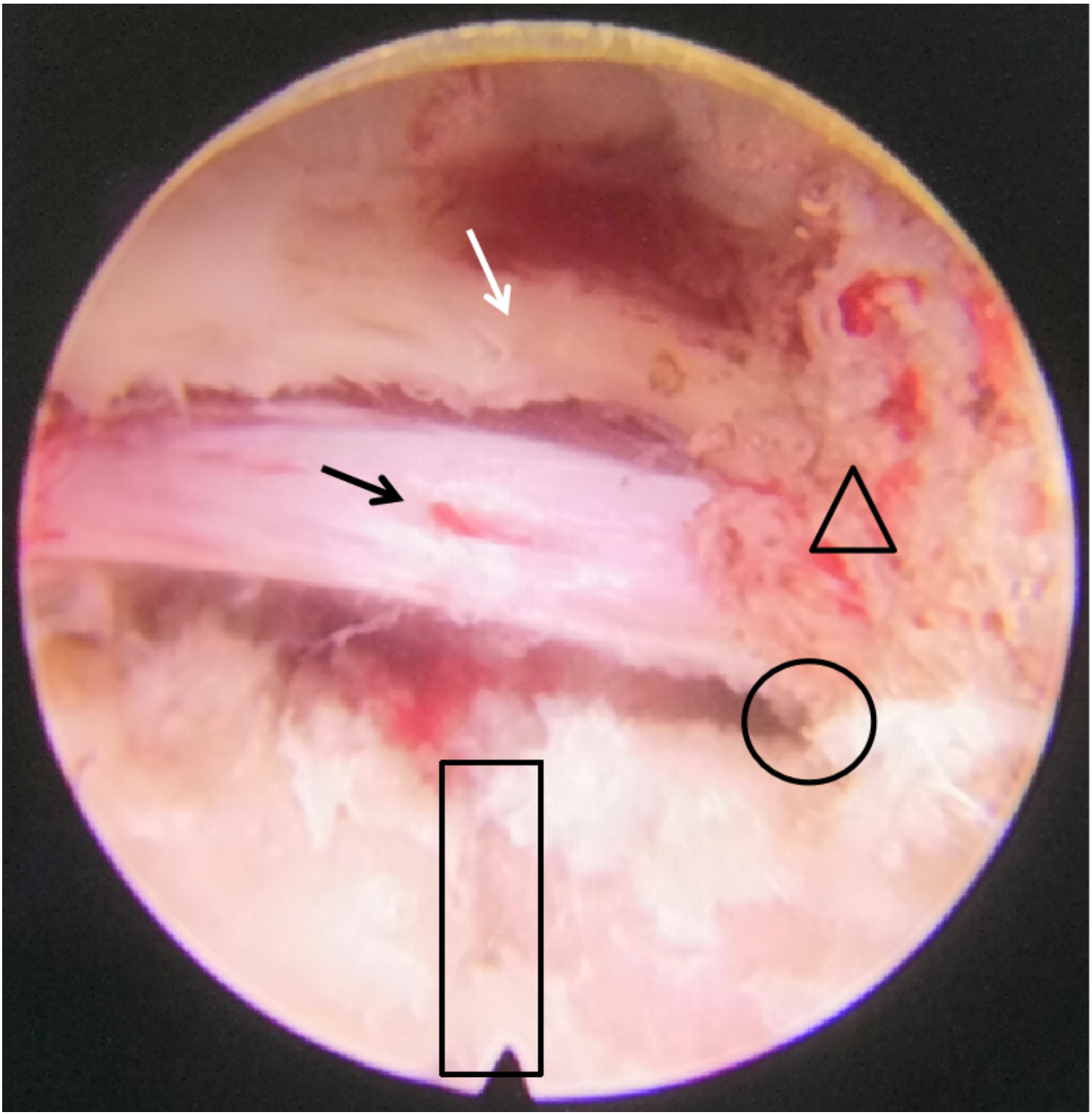

Figure 1

Endoscopic visual field showed completely decompressed nerve roots (black arrow), partially removed ligamentum flavum (white arrow), upper articular process after trephine treatment (Black triangle), lateral recess formation (black circle) and partial resection of fibrous annulus in the posterolateral region of the superior edge of the inferior vertebral body (black box).

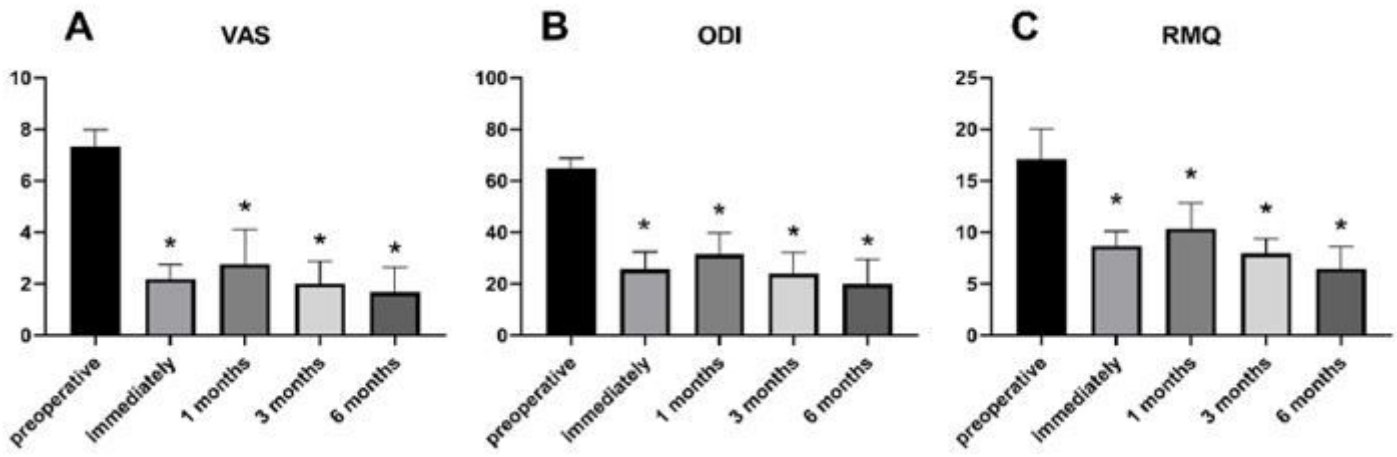

Figure 2

The mean VAS(A), ODI(B) and RMQ score(C) of BP before treatment, immediately after operation and during follow-up period. * indicates that there is a significant effect before and after treatment, which is statistically significant (P<0.05).

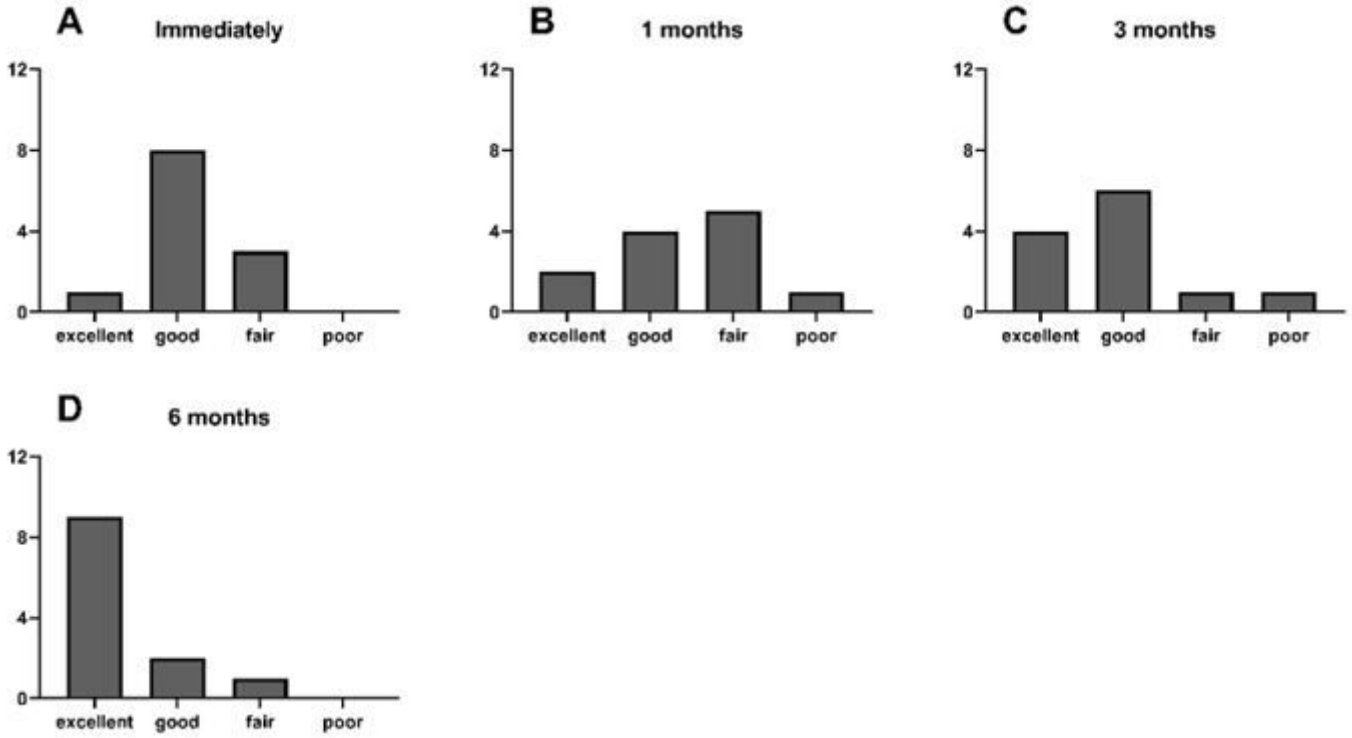

Figure 3

The results were evaluated immediately(A), 1 month(B), 3 months(C) and 6 months(D) after operation according to the MacNab criteria.

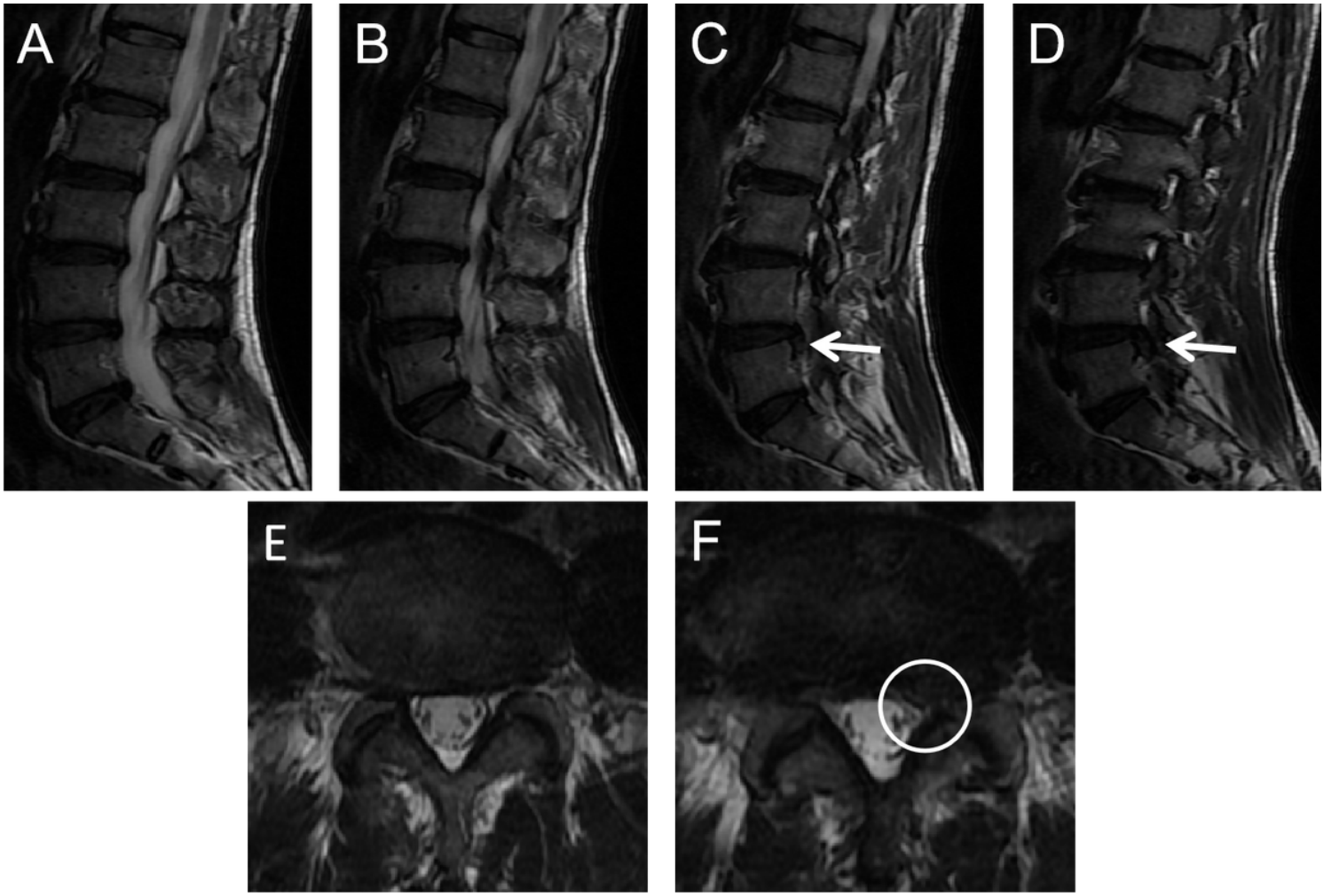

Figure 4

Sagittal T2 weighted (A-D) and transverse (E, F) MR images showed lateral prolapse of L4/5 intervertebral disc, with a downward trend of dissociation (white arrow), compressing the nerve root and dural sac. In addition, MRI showed lateral recess stenosis (white arrow).

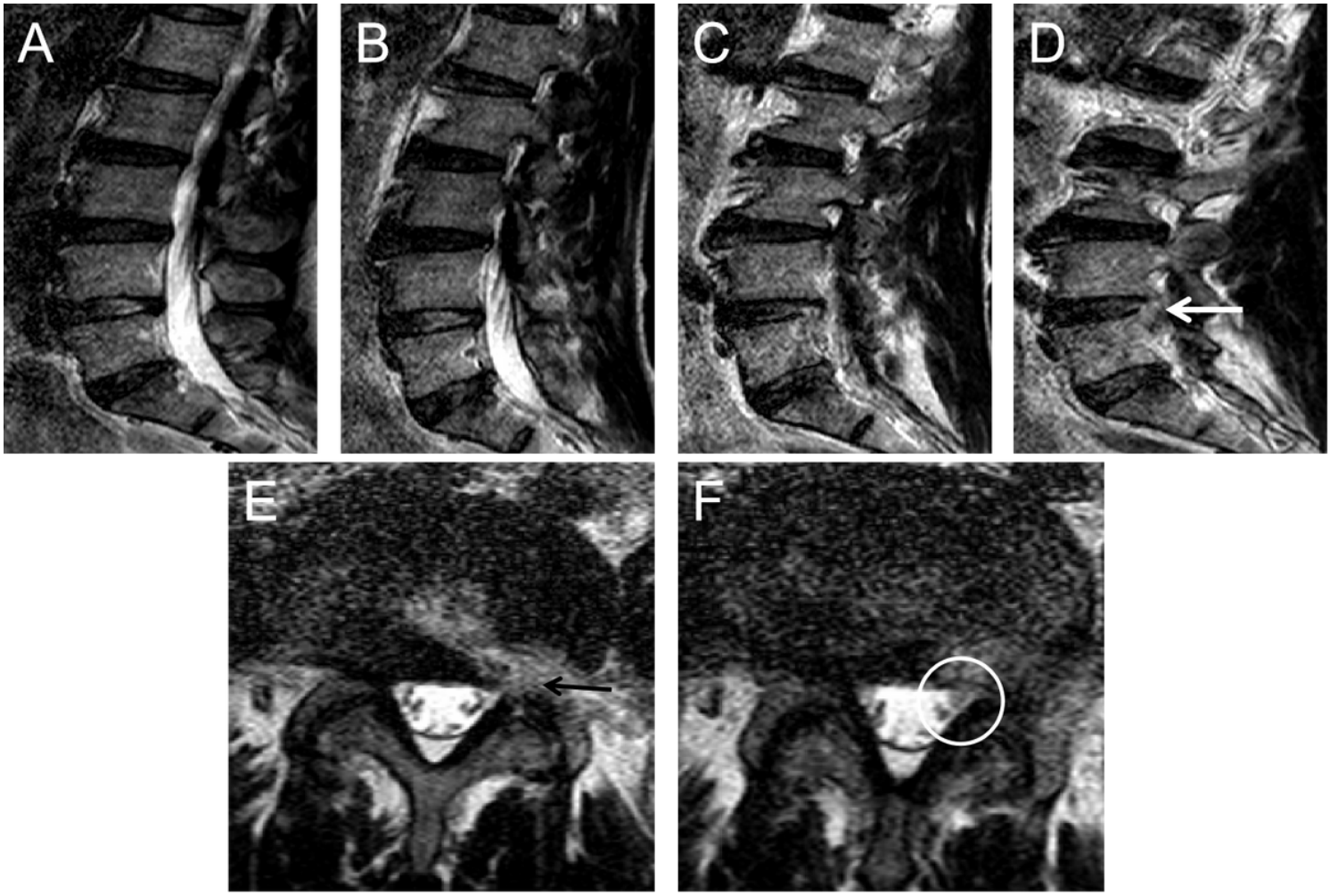

Figure 5

Postoperatively, T2 weighted sagittal (A-D) and transverse (E, F) MR images of the lumbar spine showed that the nucleus pulposus was removed (white arrow), part of the hyperplastic osteophytes of the superior articular process were removed (black arrow). The lateral recess of the affected side was decompressed (white circle).