Improved Abdomen Hypodermic Embedding for Salvage of the Amputated Fingertip from Tip to Lunula (Tamai Zone Ⅱ)

Yiming Lu
Northern Jiangsu People's Hospital

Bin Wang
Northern Jiangsu People's Hospital

Hongjun Liu
Northern Jiangsu People's Hospital

Naichen Zhang
Northern Jiangsu People's Hospital

Jiaxiang Gu (gjx69@163.com)
Northern Jiangsu People's Hospital https://orcid.org/0000-0003-4000-3524

Technical advance

Keywords: fingertip amputation; abdomen hypodermic embedding; replantation

Posted Date: August 19th, 2020

DOI: https://doi.org/10.21203/rs.3.rs-50559/v1

Abstract

Background To explore the clinical efficacy of a new surgical approach called improved abdomen hypodermic embedding for salvage of the amputated fingertip from tip to lunula (Tamai zone Ⅷ).

Methods From September 2015 to June 2017, we treated 18 fingertips from 15 patients with abdomen hypodermic embedding while all the fingertips were completely amputated and failed to vascular anastomose. After 3 weeks, all the fingertips were taken out from abdomen. After 6 months, outcomes were evaluated with DASH score and static two-point finger discrimination.

Results 16 fingertips survived completely, 2 fingertips developed partial loss and scar healed by dressing change. All patients were satisfied with the appearance of the fingertips while one woman was not satisfied for ischemic atrophy. The DASH score ranged from 35-46 (average 38), static two-point discrimination was 6–14mm (average 8mm).

Conclusions When vascular anastomosis is not feasible in fingertip replantation, improved abdomen hypodermic embedding is a simple and feasible operation for the amputated fingertip from tip to lunula.

1. Background

The hand is the most commonly used organ in daily life and the most vulnerable part for injury. The fingertip is the most important sensory part of the hand. It has a structure such as a nail, which has an important influence on the pinching and appearance. Amputated fingertip from tip to lunula is common in the emergency department. It usually occurs due to cutting, squeezing, and crushing.

There are many treatments for amputated fingertip: wound care, revision amputation, in situ suture, replantation, flap repair and reconstruction. The amputated fingertip with minor soft tissue defect and without bone exposure can be treated with wound care [1]. It is simple but it cannot treat the severe cases. Revision amputation deserts the amputated section and repairs the residual. It is simple and practical but the finger shortens which means poor function. In situ suture keeps the finger from shortening. However, the survival rate is low and the appearance is atrophic because there is not enough blood supply for the amputated section. Flap repair can ensure that the finger will not shorten, but there are also many kinds of drawbacks such as poor appearance, large damage, and poor recovery of the flap. Reconstruction is rarely used because of the large trauma and the uncertain survival rate. The replantation technique of reconstructing the blood supply is the best choice. However, the anatomical factors, the technical ability of the doctor, the soft tissue conditions and patient selection affect the fingertip survival.

Some scholars such as Wang Bin [2] proposed a novel treatment. They conducted abdominal hypodermic embedding after de-epithelialization, sutured in situ without Kirschner wire fixation. Satisfactory appearance and function were obtained. Therefore, in the study, we aim to improve it to explore a relatively simpler and more general approach with higher survival rate, better appearance, less shortening, less cost and higher patient satisfaction.

2. Methods

From September 2015 to June 2017, 15 people were admitted to Northern Jiangsu People's Hospital with 18 fingertip amputation from tip to lunula with or without bone exposure. All the wounds were debrided. There were various reasons for the inability to perform vascular anastomosis. All patients signed informed consent before surgery.

Our surgery was divided into two parts: emergency surgery and second-stage surgery.

Emergency surgery

Local anesthetic 2% lidocaine was given. After thorough disinfection, the finger root was tied with rubber strips to stop bleeding. After repeated washing with physiological saline and hydrogen peroxide, the fingertip was immersed in 0.02% chlorohexidine for 5 minutes and debrided under the microscope. Probe and mark the vascular and nerve. If the vascular anastomosis could not be performed due to the vascular defect or the distal part avulsion, the epidermis of the amputated fingertip was removed. A scalpel was used to remove the epidermis to the dark purple dermis. The fracture end was properly trimmed and the 9 − 0 or 10 − 0 Plylin was used to suture finger nerve. The broken finger was loosely sutured in situ with the 4 − 0 Plylin and the Kirschner wire fixation was not used. Local anesthesia was injected on the ipsilateral abdomen and the incision made was slightly wider than the transverse diameter of the broken finger to reach the subcutaneous fat layer. The subcutaneous fat was bluntly separated to accommodate the distal end of the broken finger. Then, the proximal end of the finger was sutured to the abdomen with the 4 − 0 Plylin.

Second-stage surgery

3 weeks after emergency operation, sutures were removed and the finger was removed from the subcutaneous fat space of the abdomen under local anesthesia. The surface was covered with a large amount of granulation tissue, and the excess granulation tissue was appropriately trimmed with reference to the surrounding residual epidermis.

Burn cream was applied to keep the finger wet. The fingertip was exposed without gauze and disinfected every 2 days. The granulation tissue was trimmed again if necessary. Postoperative routine anti-infection, circulation invigorating, shoulder, elbow and wrist joint function exercise were conducted.

3. Results

There were 9 males of 10 fingers and 6 females of 8 fingers with aged between 25–56 years old with an average age of 41 years. Among them, 8 cases of 9 fingers were of cut, 3 cases of 4 fingers were of crush injury, and 5 cases of 5 fingers were of punching injury, which gave a total of 2 Thumb finger, 9 index finger, 6 middle finger, 1 ring finger. The time from injury was between 1–6 hours, with an average of 2.3 hours.

In this sample, the fingertip healed about 2 weeks after second-stage surgery. 15 cases of 18 fingers all survived, and 2 cases had partial soft tissue necrosis at the time of removal. About 4 weeks after the removal of the broken fingers, all of them epithelialized. One female patient was dissatisfied with the appearance due to atrophy of the fingertip, and the remaining patients were satisfied. After six months, DASH [3] scores ranged from 35–46, with an average of 38 points. According to the Chinese Medical Association upper limb function evaluation trial standard, excellent performance was recorded in 9 cases, good in 5 cases, and general in 1 case [3]. The patient's static two-point finger discrimination was 6–14 mm, with an average of 8 mm.

Typical case: Patient, Chen XX, male, 39 years old, was admitted to the hospital in emergency due to cable twist trauma 2 hours after the accident. Physical examination: The left index finger was completely amputated from radialis middle part of the nail to the ulnaris distal part. The bone was exposed and the soft tissue was severely crushed. The radialis digital artery could not be found after debridement under the microscope. After the patient's consent was obtained, the epidermis was removed and the fingertip was embedded in the abdomen. The finger was removed from the abdomen 3 weeks after the operation, and the broken finger survived well. After 3 months, the appearance was similar to the uninjured and the function was good. (Figs. 1–8)

4. Discussion

There are many treatments for amputated fingertip: wound care, revision amputation, in situ suture, replantation, flap repair and reconstruction [4, 5]. The amputated fingertip with minor soft tissue defect and without bone exposure can be treated with wound care [1]. Revision amputation is a simple and practical method. It can achieve almost normal sensibility and satisfactory motion [6]. However, it also has many disadvantages, such as frequent cold intolerance [7], painful neuroma formation [8], shortening of the fingers and poor appearance. It cannot be accepted by many Asians especially female patients. Some scholars believe that if condition of the disconnected fingertip is good and the wound is flat, the success rate of in situ suture can reach more than 60% [9]. However, in actual clinical situations, it is often unsatisfactory. The success rate is extremely low because of seriously grinded soft tissue. Moreover, the disconnected fingertip atrophies for lack of blood supply. The above three methods all result in shortened fingers and atrophy which cannot be accepted by Asians for cultural factors [10]. Their satisfaction with the operation largely depends on appearance such as length and the nail maintaining [11, 12]. It means that their obsession with appearance outweighs their need for function. Sometimes this obsession manifests itself simply as a desire for physical integrity, even if both the appearance and function are poor.

The flap repair can ensure that the finger will not shorten, but there are also many kinds of drawbacks such as poor appearance, large damage, poor sensitivity [7] and poor mechanical properties of the flap. Reconstruction of blood supply by microsurgery is still the best treatment at present, but the technical difficulty is high, especially the identification of vessel ends, anastomosis of the submillimeter vessels

and fingertip's highly specialized anatomy [13]. Moreover, the appropriate conditions for the amputated finger are also required [14, 15].

For fingertips which vascular anastomosis cannot be performed, scholars have adopted various techniques. We once successfully replanted amputated fingertip (Tamai zone Ⅲ) without venous anastomosis, all of which were treated with artery-only anastomosis and postoperative venous outflow [16]. Emin Sir introduced a novel method called reposition flap repair, which could preserve the length and sensory functions of the fingertip [17]. Akito Nakanishi discovered that reconstruction using a digital artery flap and microsurgical replantation were comparable regarding postoperative activities of daily living and hand performance, but reconstruction gave better objective functional outcomes such as strength, digital sensitivity and finger mobility [18]. Although the above method is effective, the large trauma to the finger and the bloated appearance are also unsatisfactory. Wang Bin et al [2] took the lead to report in China that the subcutaneous embedding method was used to treat the distal segmental disconnection. Many scholars have improved it and achieved satisfactory results in this technology. Like abdomen hypodermic embedding, some scholars used other finger [19] or palm [20] to foster the smaller amputated fingertip. All of them have their respective advantages and disadvantages.

The bilateral digital arteries beyond the distal deep flexor tendon insertion form the distal transverse arterial arch, then give off branches [21]. The distal digital dorsal veins in the proximal nail root confluence into the terminal veins. Palmar digital veins only exist in the finger pulp or the slant ulnar side and the outer diameter is wee. According to this feature, the Tamai partition method divides the fingertip into two zones, the Zone I: the lunula (methyl) to the finger end; the Zone II: the distal interphalangeal joint to the lunula (methyl) [22]. All of our cases were belonged to Zone I. Combining the above various methods and improving them, we have adopted the method of de-epithelial embedding to provide an effective surgical method for the distal injury beyond the lunula.

The early survival of the amputated finger can be achieved through the exchange of plasma and dialysate in the abdomen, as well as the penetration of the bone marrow cavity blood. Similar to the abdominal subcutaneous fostering, the survival of the amputated finger was ensured, and the formation of capillary network gradually establishes blood supply. In the previous abdomen hypodermic embedding methods, it was usually fixed with a fracture reduction and Kirschner wire, and then embedded in the palm, forearm or abdomen. We improved it in the following aspects. Firstly, we did not recommend the use of Kirschner wire for fixation, which is one of our strengths. For the amputated fingertip from tip to lunula, the demand of Kirschner wire fixation is not very high. When it does not cross the distal interphalangeal joint, it is easy to loosen and slip off after 3 weeks. When the joint is fixed, the joint stiffness is easy to occur. Long-term Kirschner wire internal fixation increases the likelihood of infection. Though there was no Kirschner wire fixation accompanied by a risk of fracture nonunion, there was no painful discomfort during follow-up. Secondly, we sutured the abdominal skin with amputated finger at 2 mm proximity from the wound instead of at the distal or proximal interphalangeal joint surface. Excessive soft tissue containment is unnecessary and it increases the likelihood of infection and joint stiffness. Considering that ipsilateral abdominal embedding can better help perform functional

rehabilitation of shoulder and elbow after surgery, ipsilateral abdominal embedding was adopted to replace contralateral abdominal embedding. Among the 15 patients we treated, 2 patients had necrosis of some soft tissues during the second operation. The possible reason of oversized finger or excessive soft tissue squeezing was not ruled out. However, both of them scarring healed after the dressing change.

The purpose of surgery is to restore appearance and function, so postoperative rehabilitation is as important as surgery. Many patients fail to perform rehabilitation in time, resulting in tendon adhesions and joint stiffness. It is recommended to start the functional exercise of the shoulder and elbow joint on the first day after emergency surgery. After the second operation, rehabilitation can be gradually transited from the passive activity to the active activity. All of our patients didn't remain movement disorder.

To sum up, we believe that subcutaneous embedding method can integrate the advantages and disadvantages of all aspects. When the replantation of amputated finger cannot be performed due to poor soft tissue conditions, it can feed the amputated finger to the greatest extent, so as to save the amputated finger. And for fingertip defects, we do not recommend the use of flap repair. The flap is bloated and poor in appearance, which hinders the postoperative functional recovery especially the fine motor. At the same time, the sensory function of donor skin is not as good as fingertip skin, and nerve regeneration is difficult. All of them lead to the dissatisfactory recovery of fingertip sensory function after surgery. Moreover, the flap has a great damage to the donor area, poor resistance to compression and abrasion, intolerance to physicochemical stimulation and difficulty to bear the function of finger. Whereas, removing the epidermis and embedding on the abdomen can perfectly solve these problems. Since the dermis is not damaged, the new epidermis is almost the same as the original fingertip skin, which can replace the original fingertip skin in appearance, mechanical characteristics and motor functions. In addition, after half a year of follow-up, we found that there was little effect on the static two-point discrimination for the neurorrhaphy, and some scholars also had similar views through research [23, 24].

Our surgical method is convenient, reliable and it is suitable for primary hospitals. However, there are also some shortcomings. There were 2 cases of soft tissue necrosis which scarring healed after the dressing change. It was probably because both of their amputated fingertips were larger, which wound reached the vicinity of lunula. We embedded the fingertip for 3 weeks according to abdominal pedicled flap, but our embedding didn't need vascularization. Therefore, we cannot be sure if the embedding time could be shortened without avascular necrosis. The level of amputation which can survive through the abdomen embedding has not been reported in china or abroad. Our follow-up time was also a little short, the recovery, appearance and sensory reconstruction also required further follow-up observation.

5. Conclusion

When vascular anastomosis is not feasible in fingertip replantation, improved abdomen hypodermic embedding is a simple and feasible operation for the amputated fingertip from tip to lunula.

Abbreviations

DASH: disabilities of the arm, shoulder and hand

Declarations

Ethics approval and consent to participate: All procedures performed in this study involving human participants were in accordance with the ethical standards of our institution Northern Jiangsu People's Hospital and with the 1964 Helsinki declaration and its later amendments or comparable ethical standards. Written informed consents were obtained from all participants if necessary.

Consent for publication: Not applicable.

Availability of data and materials: All data generated or analysed during this study are included in this published article.

Competing interests: The authors declare that they have no competing interests.

Funding sources: This research did not receive any specific grant from funding agencies in the public, commercial, or not-for-profit sectors.

Authors' contributions:

YL: acquisition of data, analysis and interpretation of data, performing the operation, final approval of the version to be submitted

BW: acquisition of data, analysis and interpretation of data, drafting the article, final approval of the version to be submitted

HL: acquisition of data, final approval of the version to be submitted

NZ: revising it critically for important intellectual content, final approval of the version to be submitted

JG: the conception and design of the study, final approval of the version to be submitted

Acknowledgements: The authors would like to thank all participants in the study. In addition, the authors would like to thank Dr Zheng Feei Ma for improving the English in our manuscript.

References

[1] Emily M. Krauss and Donald H. Lalonde. Secondary healing of fingertip amputations: a review. Hand (N Y). 2014;9(3):282-8.

[2] Bin WANG, Shaoping ZHAO, Huiren LIU, et al. Treat severed distal segment finger with subcutaneous embedding. China J Hand Surg. 2003;19(3):150.

[3] Dade PAN, Yudong GU, De SI, et al. Chinese society of hand surgery upper limb function evaluation trial standard. China J Hand Surg. 2000;16(3):130-5.

[4] Won Young Yoon and Byung Il Lee. Fingertip Reconstruction Using Free Toe Tissue Transfer Without Venous Anastomosis. Arch Plast Surg. 2012;39(5):546–50.

[5] Muwei Li, Ming Huang, Yanjun Yang, et al. Preliminary Study on Functional and Aesthetic Reconstruction by Using a Small Artery-only Free Medial Flap of the Second Toe for Fingertip Injuries. Clinics (Sao Paulo). 2019;74: e1226.

[6] Keming Wang, Erika Davis Sears, Melissa J. Shauver, et al. A systematic review of outcomes of revision amputation treatment for fingertip amputations. Hand (N Y). 2013;8(2):139-45.

[7] Frank Yuan, Evan P. McGlinn, Aviram M. Giladi, et al. A systematic review of outcomes after revision amputation for treatment of traumatic finger amputation. Plast Reconstr Surg. 2015;136(1):99-113.

[8] Nicholas S. Golinvaux, Jed I. Maslow, James P. Hovis, et al. Fingertip Injury and Management. JBJS Essent Surg Tech. 2019;9(3): e30.

[9] Dachuan XU. Surgical Anatomy for Functional Reconstruction of the Hand. People's Medical Publishing House, Beijing.1996:323-6.

[10] Melissa J. Shauver, Takanobu Nishizuka, Hitoshi Hirata, et al. Traumatic finger amputation treatment preference among hand surgeons in the US and Japan. Plast Reconstr Surg. 2016;137(4):1193-202.

[11] Matsuzaki H, Yoshizu T, Maki Y, et al. Functional and cosmetic results of fingertip replantation: anastomosing only the digital artery. Ann Plast Surg. 2004;53(4):353-9.

[12] Hattori Y, Doi K, Ikeda K, et al. A retrospective study of functional outcomes after successful replantation versus amputation closure for single fingertip amputations. J Hand Surg Am. 2006;31(5):811-8.

[13] Jin-Soo Kim, Jae-Won Yang, Dong-Chul Lee, et al. Challenges in Fingertip Replantation. Semin Plast Surg. 2013; 27:165–73.

[14] Shimpei Ono and Kevin C Chung. Efficiency in Digital and Hand Replantation. Clin Plast Surg. 2019;46(3):359-70.

[15] Marjolein A. M. Mulders, Valentin Neuhaus, Stéphanie J. E. Becker, et al. Replantation and revascularization vs. amputation in injured digits. Hand (N Y). 2013;8(3):267-73.

[16] An-shi Huan, Subhash Regmi, Jia-xiang Gu, et al. Fingertip replantation (zone I) without venous anastomosis: clinical experience and outcome analysis. SpringerPlus. 2016;5:1835.

[17] Sir E, Aksoy A, Kasapoğlu Aksoy M. Comparisons between long-term outcomes of the use of reposition flaps and replantations in fingertip amputations. Ulus Travma Acil Cerrahi Derg. 2018;24:462-7.

[18] Akito Nakanishi, Shohei Omokawa, Kenji Kawamura, et al. Tamai Zone 1 Fingertip Amputation: Reconstruction Using a Digital Artery Flap Compared With Microsurgical Replantation. J Hand Surg Am. 2019;44(8):655-61.

[19] Yi-Syuan Li, Chun-Yu Chen, Shan-Wei Yang, et al. Cross-finger subdermal pocketplasty as a salvage procedure for thumb tip replantation without vascular anastomosis: a case report. J Int Med Res. 2018;46(9):3717-23.

[20] Mi Sun Jung, Young Kook Lim, Yong Taek Hong, et al. Treatment of Fingertip Amputation in Adults by Palmar Pocketing of the Amputated Part. Arch Plast Surg. 2012;39(4):404-10.

[21] Yong Seok Nam, Young Joon Jun, In-Beom Kim, et al. Anatomical Study of the Fingertip Artery in Tamai Zone I: Clinical Significance in Fingertip Replantation. J Reconstr Microsurg. 2017;33(1):45-8.

[22] Jung MS, Lim YK, Hong YT, et al. Treatment of fingertip amputation in adults by palmar pocketing of the amputated part. Arch Plast Surg. 2012;39(4):404-10.

[23] Zhaowei ZHU, Xiaoyan ZOU, Yongjun HUANG, et al. Evaluation of sensory function and recovery after replantation of fingertips at Zone I in children. Neural Regen Res. 2017;12(11):1911-7.

[24] H. Venkatramani and S. Raja Sabapathy. Fingertip replantation: Technical considerations and outcome analysis of 24 consecutive fingertip replantations. Indian J Plast Surg. 2011;44(2):237-45.

Figures

Figure 1

pre-operation

Figure 2

remove epidermis to dermis

Figure 3

abdominal embedding

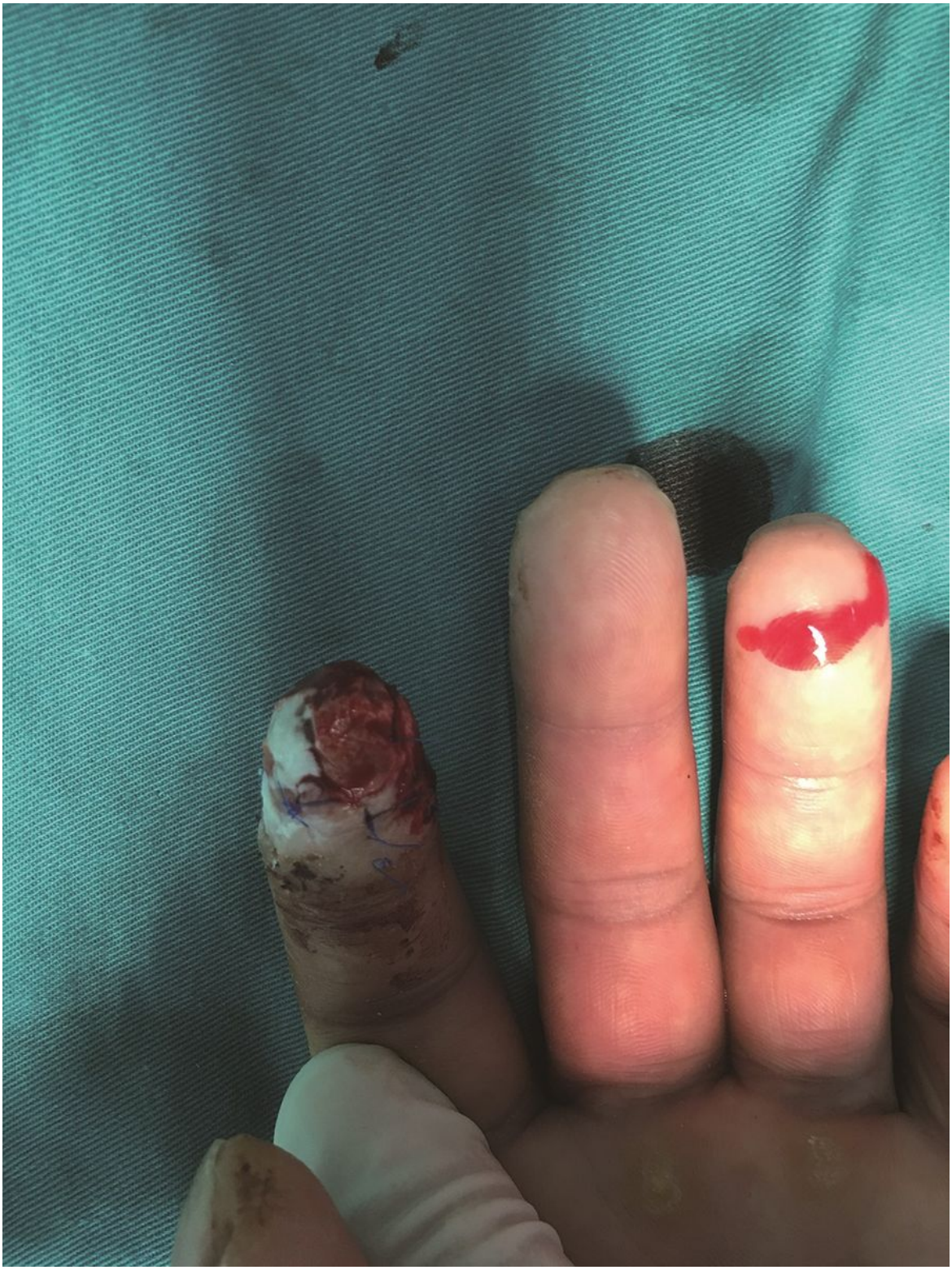

Figure 4

after second-stage operation

Figure 5

appearance after three months

Figure 6

appearance after three months

Figure 7

flexion function after three months

Figure 8

extending function after three months