Cardiac Metastasis from Gastric Adenocarcinoma Mimicking COVID-19 Symptoms

Fatemeh Jahanshahi
Iran University of Medical Sciences

Sam Zeraatian Nejad Davani
Iran University of Medical Sciences

Amirhossein Parsaei (ah-parsaei@alumnus.tums.ac.ir)
Tehran University of Medical Sciences https://orcid.org/0000-0002-9980-3238

Research Article

Keywords: gastric cancer, adenocarcinoma, right-side cardiac metastasis, cardiac metastasis

Posted Date: May 12th, 2021

DOI: https://doi.org/10.21203/rs.3.rs-509859/v1

Abstract

Background

Cardiac metastasis with origin of gastric adenocarcinoma is extremely rare. This type of metastasis tends to involve the pericardium through lymphatic seeding. Currently, no reports of solitary tumor emboli to the heart cavity with possible transvenous pathway of seeding has been made. Due to initial dyspnea and accompanying symptoms, cardiac tumor embli may be mistaken with covid-19 infection.

Case presentation:

A sixty-year-old female with known inoperable diffuse gastric adenocarcinoma receiving chemotherapy from eight months ago, presented to hospital with progressive dyspnea. Other sign and symptoms included chest pain, hypotension, tachycardia and muffled heart sounds. The patients had no fever or other common covid-19 infection symptoms. The RT-PCR for Covid-19 RNA was negative. Initial chest CT-scan showed no sign of infection. A transesophageal echocardiography was performed and revealed a > 6cm vermiform mass free-floating in the right atrium protruding to the tricuspid valve and right ventricle compatible with emboli. By urgent cardiac surgery the mass was removed. The postoperative course was uneventful. The pathology results confirmed a tumor emboli originated from gastric carcinoma. Whole body PET-scan shoed no evidence of other metastasis.

Conclusions

However cardiac metastasis are extremely rare, in gastric cancer cases with cardiopulmonary manifestation should be considered as a probable differential diagnoses. Regarding to ongoing covid-19 pandemic the present case misdiagnosed with coronavirus infection.

Introduction

Cardiac metastasis is extremely rare phenomena and often is asymptomatic and recognized postmortem. In previous studies on autopsies the incidence of cardiac metastasis reported almost 1.2%. Cardiac metastasis is more prevalent in melanoma, lymphoma, leukemia and carcinoma of the lung, breast and esophagus. However metastasis from malignancy of organs below the diaphragm reported rarely. Moreover, it is expected cardiac metastasis observed in wide spread metastatic cancer cases and occurrence of solitary isolated cardiac metastasis is not predictable. [1–4]

In this study a seventy-year old female patient known case of inoperable diffuse sclerotic gastric adenocarcinoma reported which presented to the hospital with a complaint of progressive dyspnea and chest pain, para-clinical investigations demonstrated a solitary cardiac metastasis from gastric adenocarcinoma.

Case Presentation

The patient was a sixty-year-old female patient with a history of known inoperable diffuse sclerotic gastric adenocarcinoma receiving chemotherapy treatment. Eight months ago, following epigastric pain, which was not responded to proton-pump inhibitor drugs for two months, she underwent upper GI endoscopic evaluation, and gastric cancer was diagnosed. Regarding to unresectable gastric cancer, the patient underwent a chemotherapy regimen.

The patient presented to the hospital with a complaint of progressive dyspnea and chest pain. She had no cough symptoms, tiredness, myalgia, headache, diarrhea, loss of taste and smell. No fever (T = 36.8℃), decreased O2 saturation (O2 Sat = 98%), and no abnormal respiratory sound was detected in the examination. Moreover, blood pressure was 90/50; HR was 120. In heart auscultation, a muffled sound was detected. She had experienced NYHA class III-IV dyspnea. The patient had been tested for COVID-19 infection, and the nasopharyngeal PT-PCR was negative. On the Spiral chest computed tomography without contrast no evidence of coronavirus infection was found. Therefore, transthoracic and transesophageal echocardiography was conducted, which demonstrated severe right ventricle enlargement and systolic dysfunction, D shape septum due to right ventricle overload and large size hypermobile vermiform mass with length > 6 cm and thickness of 1 cm in right atrium seems to be free-floating and protruding to the tricuspid valve and right ventricle during diastole compatible with emboli (Fig. 1, Supplementary video 1). The patient underwent urgent cardiac surgery, and the mass was removed by using total inflow occlusion on the beating heart technique (Fig. 2, Supplementary video 2). Due to severe right ventricle dysfunction, the patient needed a right ventricular assist device postoperatively. Whole-body positron emission tomography noted no evidence of metastasis. Pathology investigation was confirmed tumor emboli with the origin of gastric adenocarcinoma.The postoperative course was uneventful in intensive unit care.

Discussion

Cardiac metastasis is considered extremely rare with an incidence of 1.2% and often remains silent until autopsy [1, 2]. The most common origins of cardiac metastatic tumors are adjacent organs, including the lung, breast, and esophagus[3]. Cardiac metastasis as the first site of metastasis is reported only in isolated cases. These tumors usually accompany other multi-organ seedings of the primary tumor and are often discovered by autopsy[4].

The most common sites of metastasis from gastric adenocarcinoma are the liver, peritoneum, lung, and bone[5]. Cardiac metastasis with the origin of gastric adecarcinoma has a very slight chance of occurrence. The chances of this event to be solitary are very minute. In a report of 476 consecutive tumor deaths with cardiac involvement, young JM demonstrated that only 2 cases had metastatic cardiac lesions while none were solitary cardiac metastasis; they suggested a hematogenous path of spread for the metastasis[1]. In contrast, Bussani et al. showed that only 8% of autopsies with cardiac metastases had a gastric origin. They described gastric metastases to tend to infiltrate the pericardium more often.

Again there was no report of solitary cardiac metastasis[6]. KY Lam et al., in a report on 12,485 autopsies, found that cardiac metastases with gastric origin have an incidence of 4%.

To our knowledge, there are no reports regarding gastric adenocarcinoma with solitary cardiac metastasis on the right side of the heart; only Peter B et al. reported a 60 mm left-sided cardiac metastasis that probably originated from gastric adenocarcinoma in the patient[7]. The unique feature of the current case is the thrombotic of the tumor, which is extremely rare, leading to the floating and hypermobility of the lesion. Adenocarcinoma metastases to the heart tend to infiltrate the pericardium via the lymphatic pathway.

Several mechanisms are suggested to contribute to the rareness of cardiac metastasis in malignancies; These include the rigorous motion of the myocardium, metabolic features of myocardial cells, rapid flow of blood through the heart, and adequate deep and superficial lymphatic drainage from the heart[8]. Despite the mentioned mechanisms, cardiac metastasis may occur due to direct, hematogenous, lymphatic spread, transvenous or a combination of these pathways; Regarding the malignancies in adjacent organs such as the lung, the lymphatic spread is offered as the most probable route[9]. The lymphatic route of spread most probably leads to pericardial involvement, but in our case, considering the site and features of the metastatic mass in the right side of the heart (right atrium) with no infiltration[10], we assume it as a transvenous metastasis. The mechanism can be explained through seeding of the tumor cells from stomach into portal veins, liver, inferior vena cava and eventually atrium.

Cardiac metastatic lesions are only 10% symptomatic. In previous literature, the first sign of cardiac cavity metastatic tumor reported as progressive dyspnea, as in our case, the patient had NYHA class III-IV dyspnea with sufficient O2 Saturation and increased respiratory rate. Due to covid-19 pandemic, first diagnosis was the viral acute respiratory syndrome. But in the next stage the reverse transcriptase chain reaction test for covid-19 RNA showed negative results. Absence of other covid-19 infection symptoms,and the suspicion to cardiac causes due to hemodynamic changes, convinced us to perform transesophageal echocardiography that revealed the tumor in the right atrium. Other initial symptoms are hypotension, muffled heart sound in auscultation, tachycardia, arrhythmia, cardiomegaly, heart failure, and in one report, jugular vein distension and pulsus paradox[1, 11, 12]. The symptoms result from tumor obstructive mass effect in the atrial inlet, atrial cavity, inside the tricuspid valve and right ventricle, or other related infiltrative complications such as pericardial effusion or even cardiac tamponade[11].

Solitary metastasis to the heart is extremely rare, and cardiac metastasis is observed more frequently in autopsy studies of patients with extensive multi-organ metastases[13]. The cardiac myxoma (benign primary cardiac tumor) is considered as the top differential diagnosis of solitary cardiac metastasis in the atrial cavity. Others include vegetation and thrombosis[12]. In the presented case, the preoperative diagnosis was established via trans-esophageal echocardiography as a floating mass compatible with thrombi that later was observed in the IHC study to be a gastric adenocarcinoma metastasis. It is suggested that late gadolinium-enhanced cardiac MRI studies can help to improve the diagnosis and depth of tumor infiltration because it provides a definite distinction of heart layers from the tumor and

limits the differential diagnosis. Besides MRI, in one study, Computed Tomography could detect the extent of a left-sided cardiac metastatic tumor of unknown origin with adjacent nodular densities [10].

Choi et al. discussed that with recent advances in diagnosis techniques, the incidence of cardiac metastasis would increase, urging the need for standard guidelines for diagnosis and treatment options of cardiac metastasis[12]. Cardiac metastatic tumors yield an abysmal prognosis in the affected patients. The obstructive mass, low cardiac input and consequently low output, hypotension, possible arrhythmia, and in some cases pericardial effusion and tamponade —as mentioned above— and finally hemodynamic instability urges the immediate action for removing the metastatic mass to save the patient's life. Due to complicated surgical procedures and compromised patient factors, this procedure is associated with an extreme risk of bleeding, ventricular dysfunction, tumor cells seeding, or death in some cases[12]. However, several authors have suggested surgery to be helpful, particularly in solitary metastatic tumors, to relieve the symptoms or palliation [10, 11, 14]. In cases of inoperable cardiac tumors, it is worth considering palliative chemotherapy to shrink the size, maintain the cardiac output and increase survivability[10, 11].

Conclusion

The metastatic tumors of the heart are limited to case reports. In this case the patient with primary gastric adenocarcinoma represented symptoms such as dyspnea and hemodynamic changes. Regarding the pandemic and symptoms that mimicked covid-19, the patient was misdiagnosed as covid-19 infection. A tumor emboli in the heart cavity is a possible diagnosis that should be investigated through echocardiographic evaluation. The option of treatment is made based on patient situation to relieve symptoms.

References

1. Young J, GOLDMAN IR. Tumor metastasis to the heart. Circulation. 1954;9(2):220–9.
2. Sarjeant JM, Butany J, Cusimano RJ. Cancer of the heart. American Journal of Cardiovascular Drugs. 2003;3(6):407–21.
3. Reynen K, Köckeritz U, Strasser R. Metastases to the heart. Ann Oncol. 2004;15(3):375–81.
4. Pinho T, et al. *Cardiac metastasis of melanoma as first manifestation of disease.* Revista portuguesa de cardiologia: orgao oficial da Sociedade Portuguesa de Cardiologia = Portuguese. journal of cardiology: an official journal of the Portuguese Society of Cardiology. 2009;28(5):633–9.
5. Riihimäki M, et al. Metastatic spread in patients with gastric cancer. Oncotarget. 2016;7(32):52307.
6. Bussani R, et al. Cardiac metastases. J Clin Pathol. 2007;60(1):27–34.
7. Bernhardt P, et al. Cardiac metastasis of a gastric adenocarcinoma. European heart journal. 2009;30(13):1655–5.
8. Prichard R. Tumors of the heart: review of the subject and report of one hundred and fifty cases. Arch pathol. 1951;51:98–128.

9. Klatt EC, Heitz DR. Cardiac metastases. Cancer. 1990;65(6):1456–9.
10. Cheruvu B, Cheruvu P, Boyars M. An unusual case of metastasis to the left side of the heart: a case report. Journal of medical case reports. 2011;5(1):1–4.
11. Hajsadeghi S, et al., *A rare case of cardiac metastasis from uterine cervical adenocarcinoma*. Journal of Cardiology Cases, 2020.
12. Choi PW, et al. Cardiac metastasis from colorectal cancer: a case report. World journal of gastroenterology: WJG. 2009;15(21):2675.
13. Abraham K, Reddy V, Gattuso P. Neoplasms metastatic to the heart: review of 3314 consecutive autopsies. Am J Cardiovasc Pathol. 1990;3(3):195–8.
14. Ayyala SS, et al. A rare case of atrial metastasis from a rectal adenocarcinoma. J Clin Med Res. 2017;9(10):886.

Declarations

Ethic approval and consent to participant:

The present study is in compliance with ethical standards and standards of research involving humans. This article does not contain any studies involving animals performed by any of the authors.

Consent for publication:

Written informed consent was obtained from the patient for publication of this case report and any accompanying images. A copy of the written consent is available for review by the Editor-in-Chief of this journal.

Availability of data and materials:

Data in the current study are available from the corresponding author on reasonable request.

Competing interests:

There is no conflict of interest to declare.

Funding:

This study has no financial source and support.

Author's contributions:

Study concept and design: FJ, SZ

Acquisition of data: FJ, SZ

Drafting of the manuscript: FJ, AP

Critical revision of the manuscript for important intellectual content: SZ

Study supervision: AP, SZ

All authors read and approved the final manuscript

Acknowledgements:
None.

Figures

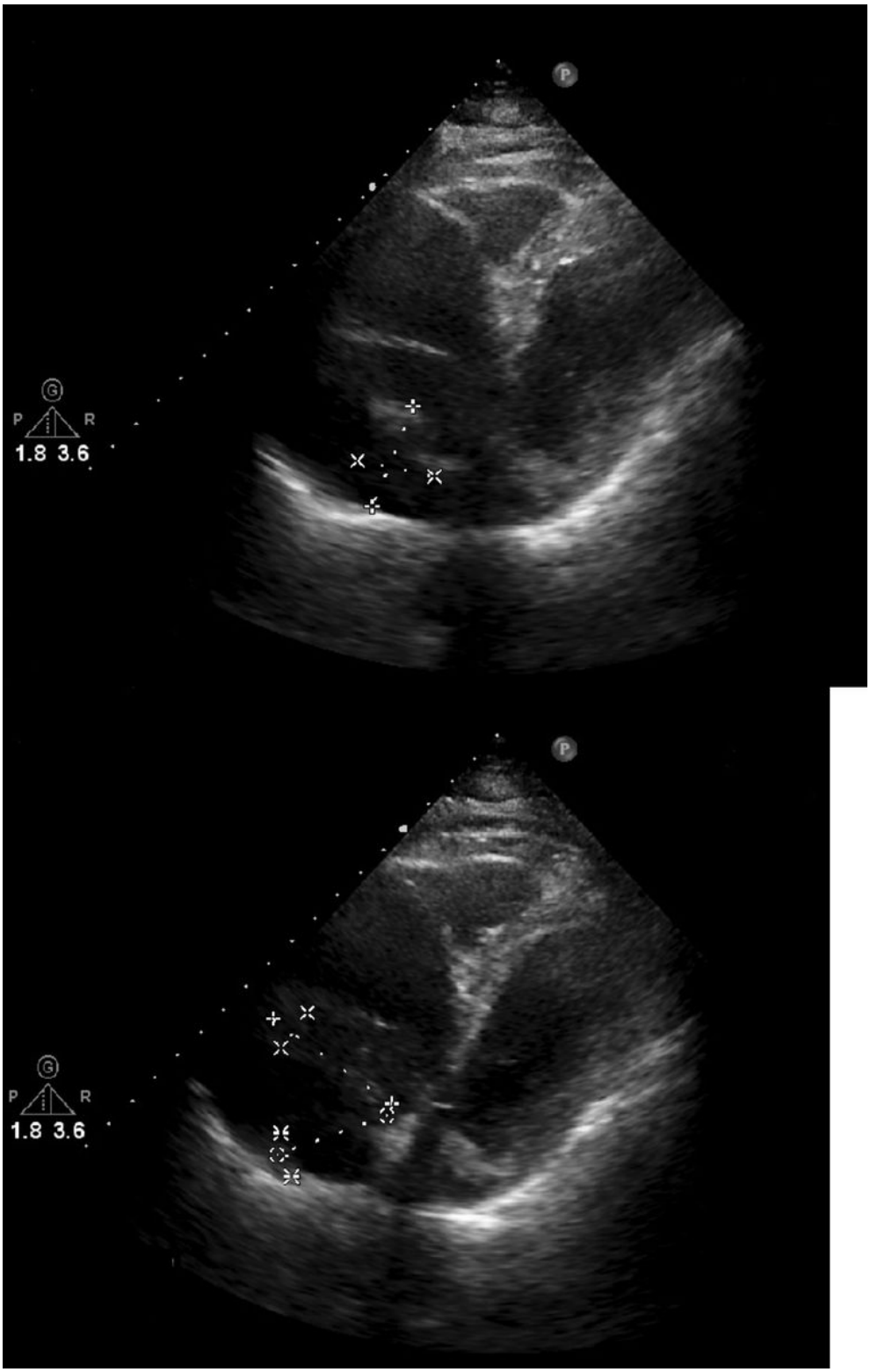

Figure 1

The echocardiography with trans thoracic view of tumor thrombosis with extension into right ventricle cavity

Figure 2

Gross specimen of removed lesion from right atrium

Supplementary Files

This is a list of supplementary files associated with this preprint. Click to download.

- Supplementaryvideo1.mp4
- Supplementaryvideo2.mp4