Large Left Ventricular Pseudoaneurysm Presenting After Mitral Valve Replacement

filippo prestipino (filippo.prestipino@libero.it)

Regional Hospital San Carlo: Azienda Ospedaliera Regionale San Carlo https://orcid.org/0000-0002-4668-0633

Riccardo D'Ascoli

Regional Hospital San Carlo: Azienda Ospedaliera Regionale San Carlo

Giampaolo Luzi

Regional Hospital San Carlo: Azienda Ospedaliera Regionale San Carlo

Research Article

Keywords: cardiac wall, pericardium, coronary occlusion, Diagnosis, ventricular pseudo-aneurysm

Posted Date: July 12th, 2021

DOI: https://doi.org/10.21203/rs.3.rs-511744/v1

Abstract

Left ventricular pseudo-aneurysm is a rupture of the cardiac wall tamponated by the pericardium. It can be caused by coronary occlusion, cardiac trauma, endocarditis or it may follow a mitral valve replacement. Mortality, if not treated, is greater than 10% and diagnosis must be supported by imaging investigations. Surgery is often the only choice, at high risk, and it should be planned basing on specific anatomy. Diagnosis of left ventricular pseudo-aneurysm after the replacement of the mitral valve usually occur accidentally; in the case, we presented it was discovered 2 years after the intervention. The patient was treated successfully with planned surgical operation.

Introduction

Left ventricular pseudo-aneurysm (LVP) is a rare and insidious condition, difficult to diagnose and to treat. It is generated by the rupture of the ventricular posterior wall contained by the pericardium, which blocks the bleeding and the consequent cardiac tamponade. Several causes have been described, the most common of which is myocardial infarction of the inferior left ventricle wall. The second most common cause of LVP is surgery, in particular mitral valve replacement, in literature, it is reported in a percentage from 0.02–2% (1). Lesser causes are heart trauma and infections.

Case Presentation

A 61-year-old patient was referred to the Department of Cardiology of our Hospital for the presence of severe exertional dyspnea, NYHA functional class III. Two years before he underwent mitral valve replacement with mechanical prosthesis for the presence of endocarditis leading to severe mitral insufficiency; subsequently about 2 months later the patient had removed the mechanical prosthesis for dysfunction of this (thrombosis), with implantation of a bio-prosthesis Carpentier Edwards 27. The post-operative course was uneventful and the patient was discharged on seventh postoperative day after an echocardiogram that highlighted the correct position and function of the mitral prosthesis. Subsequently, the patient remained asymptomatic for two years, then he began to complain dyspnea, progressively worsened; surface echocardiogram and then a trans-esophageal, demonstrated the correct functioning of mitral bio-prosthesis in presence of a left ventricle pseudo-aneurysm (LVP) of about 6 cm maximum diameter determining a total tele-diastolic volume of 267 ml. Cardiac synchronized multi-detector computed tomography (MDCT) was then useful to better characterize the lesion, and it confirmed the presence of the pseudo-aneurysm, with the neck just adjacent to the edge of mitral prosthesis; the overall size of LVP was 7.6x7.4x6 cm. Along the external profile LVP was demarcated by a scar tissue of about 0.5 cm thick. The neck measured 2.5x2.2 cm and was not visible any thrombus inside the LVP, that was close to the right ventricle and right atrium; collaterally, MDCT did not highlight critical coronary disease (Fig. 1). Surgery was then planned, and through a longitudinal median sternotomy, extracorporeal circulation has begun by cannulation of ascending aorta and right atrium by femoral percutaneous vein; the posterior and inferior surface of the heart was cleaved by the surrounding structures after initiating extracorporeal circulation to hold the ventricles. LVP was then opened allowing access to its cavity and

visualization from the inside of the neck, which in the cranial portion lay behind the mitral prosthesis. The consistency of the left ventricular wall at the LVP neck has allowed us to perform the implantation of a dacron patch to close it. The patch was sutured with 2 – 0 prolene U-stitches with pledgets in the area adjacent to the mitral prosthesis, while the remaining perimeter was sutured with a 3 – 0 prolene running suture. Successively, LVP external wall was closed covering the patch to complete the hemostasis. The mitral prosthesis appeared in excellent condition confirming that seen in the ultrasound. The patient was easily disconnected from the extracorporeal circulation and the post-operative course was uneventful. A trans-esophageal echocardiogram was performed in five post-operative day and confirmed the suitable surgical result with the absence of residual pseudo-aneurysm and preserved good shape and global kinesis of the left ventricle. Chest tomography at three months from operation showed a good surgical result (Fig. 2).

Discussion

LVP after replacement of the mitral valve complicates the post-operative course of this intervention at a percentage between 0.02% and 2.0% (1, 2). Several causes may determine a rupture in the posterior wall of left ventricle post-mitral surgery, such as the presence of endocarditis with or without abscess, the need for extensive decalcification of the annulus, and the placement of a valve oversized. From the few works in the literature on the subject, it emerges that the formation of LVP is facilitated by the presence of coronary heart disease with myocardial infarction (3). LPA after mitral valve replacement usually occurs from a few days to a few weeks after the surgery. In our case, two years have passed between the surgery and the diagnosis of LPA. The onset in our case may have been delayed due to the repeated stress of the mitral valve over a back ventricular wall already weakened. But the rupture may have occurred even shortly after the intervention and then with time the LPA has increased considerably. Due to a poor trans-thoracic echocardiographic window and the absence of symptoms, the diagnosis may have been delayed. The main symptoms in presence of LVP are dyspnea and chest pain, although in 10% of cases it can be asymptomatic and diagnosis occurs at a post-operative echo (4). There are also changes in electrocardiogram and widening of the cardiac shadow to the chest x-ray, but the instrumental investigations that best allow diagnosis are echocardiography, including trans-esophageal, cardiac tomography or magnetic resonance (MRI) and angiography. The last one represents a method that can be used after the echocardiographic suspect of LVP and allows for a good view of the size of the sac around the left ventricle, the size of the neck, and assess the presence of coronary occlusion. Cardiac tomography and MRI allow you to delimit the contours of LVP and relationships with other cardiac structures, as well as measuring the distance of the neck from the mitral prosthesis (MP). The only therapeutic solution for LVP is represented by surgery, since leaving this untreated would mean a volumetric increase and a 30 to 45% of rupture risk (5). Elective surgery is at high risk, with a mortality ranging from 10–23%, and requires optimal planning based on the characteristics of the pseudo-aneurysm. Sternotomy access allows better control of LVP, especially when by large size, and troubles derived from the presence of adhesions. Closure of LVP has been described without opening the cardiac cavities, but suturing the wall from the outside with teflon reinforced prolene points (6). Alternatively,

access may be performed by left mini-thoracotomy at the fifth intercostal space, avoiding exposure of the lesion by retracting the heart (7). The planning of this operation was crucial, through the interpretation of cardiac tomography with three-dimensional reconstruction and angiography.

Conclusions

Right diagnosis and structural characterization are of crucial importance in the management of LVP and they must be supported by instrumental investigations such as MDCT and trans-esophageal echocardiography. The correct surgical strategy should be selected based on clinical presentation and anatomy, taking into account the causes that led to the genesis of pseudaneurysm. Surgery is burdened by high mortality but when diagnosis is done it must be performed to avoid the risk of breakage.

Declarations

Funding

None declared

Informed consent

written informed consent was obtained from the patient for publication of this manuscript and any accompanying images.

Acknowledgments

The authors declare that information present in this article were not presented before. All authors respect the criteria of authorship.

Contributions

FP conceived and designed the research. FP and RD wrote manuscript. GL revised and integrated the work. All authors approved the manuscript.

Conflict of interest: The authors have no conflict of interest to disclose.

Support: San Carlo Hospital, Potenza, Italy

References

1. Frances C, Romero A, Grady D. Left ventricular pseudoaneurysm. J Am Coll Cardiol. 1998 Sep;32(3):557-61.
2. Honda K, Okamura Y, Nishimura Y, Hayashi H. Patch repair of a giant left ventricular pseudoaneurysm after mitral valve replacement. Ann Thorac Surg. 2011 May;91(5):1596-7.

3. Becker RC[1], Gore JM, Lambrew C, Weaver WD, Rubison RM, French WJ, Tiefenbrunn AJ, Bowlby LJ, Rogers WJ. A composite view of cardiac rupture in the United States National Registry of Myocardial Infarction. J Am Coll Cardiol. 1996 May;27(6):1321-6.
4. Neupane, S., Kommuri, N. V. A., Kazanji, N. and Chowdhury, P. (2016), Left ventricular pseudoaneurysm after mitral valve replacement. Echocardiography, 00: 1–2. doi: 10.1111/echo.13294
5. Miura T, Yamazaki K, Kihara S, Saito S, Miyagishima M, Aomi S, Kurosawa H. Transatrial repair of submitral left ventricular pseudoaneurysm. Ann Thorac Surg. 2008 Feb;85(2):643-5.
6. Min SK, Sir JJ, Nah JC, Kim YI. Successful resection of giant left ventricular pseudoaneurysm developed later after mitral valve replacement. J Korean Med Sci. 2010 Jul;25(7):1080-2.
7. Hirasawa Y, Miyauchi T, Sawamura T, Takiya H. Giant left ventricular pseudoaneurysm after mitral valve replacement and myocardial infarction. Ann Thorac Surg. 2004 Nov;78(5):1823-5.

Figures

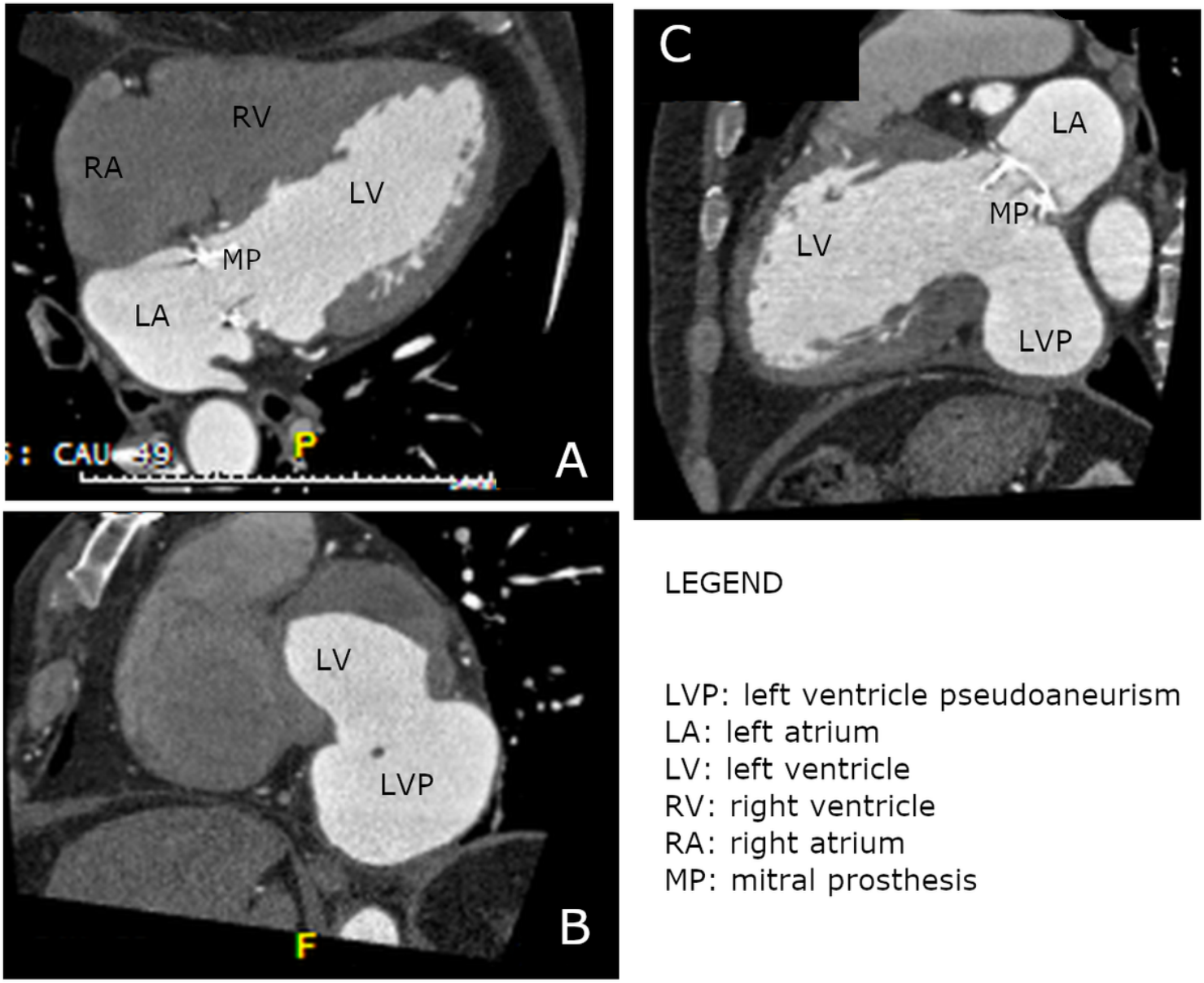

Figure 1

three-dimension cardiac synchronized tomography showing left ventricle pseudo-aneurysm. A: four chambers view; B: short-axis view showing the neck of the pseudo-aneurysm; C: two-chambers view showing the proximity of left ventricle pseudo-aneurysm with mitral prosthesis.

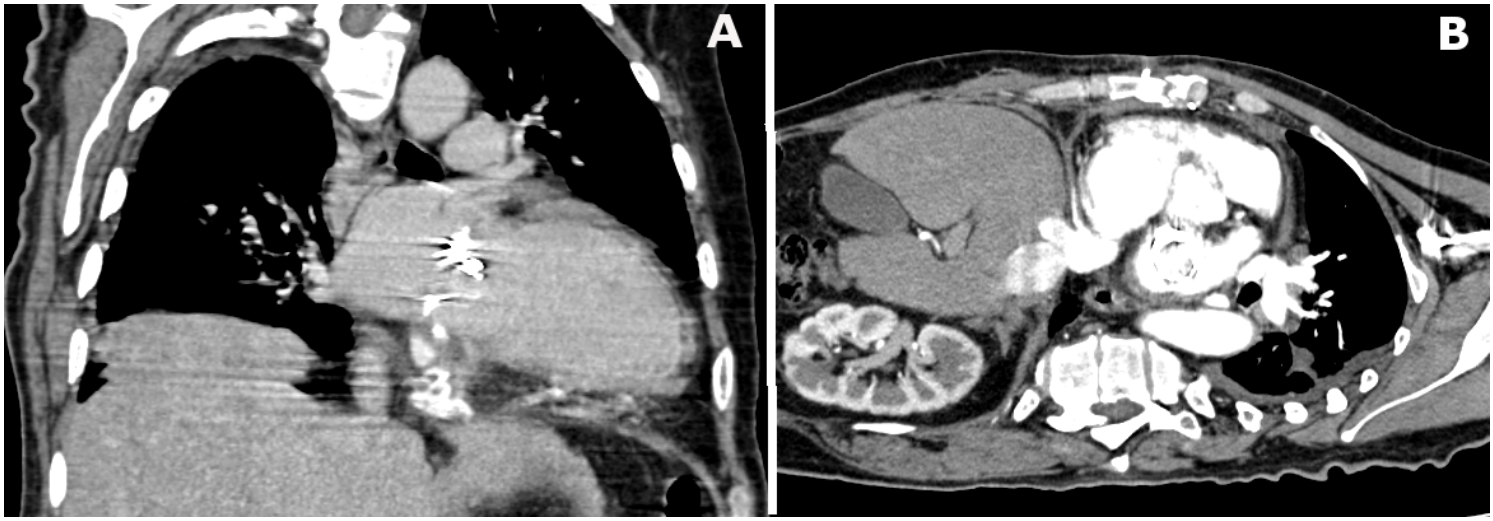

Figure 2

three-dimension cardiac synchronized tomography three months after surgical repair of left ventricle pseudo-aneurysm. A: Coronal view. B: Axial view. C: sagittal view.