Traumatic Internal Mammary Injury— A Literature Review and Guide for Management

Yu-Tung Wu
Chang Gung Memorial Hospital
Chien-Hung Liao
Chang Gung Memorial Hospital
Chien-An Liao
Chang Gung Memorial Hospital
Chih-Yuan Fu
Chang Gung Memorial Hospital
Chi-Hsun Hsieh (hsieh0818@cgmh.org.tw)
Chang Gung Memorial Hospital

Original research

Keywords: internal mammary artery injury, internal thoracic artery injury, thoracic injuries, mammary arteries, chest trauma, transarterial embolization

Posted Date: August 4th, 2020

DOI: https://doi.org/10.21203/rs.3.rs-51285/v1

Abstract

Background

Traumatic internal mammary artery (IMA) injury is a rare but clinically significant injury since it is linked to various troublesome conditions. In this review, we aim to provide a complete description and a practical strategy for managing this injury.

Methods

PubMed, Embase, and the Web of Science were searched from 1960 to 2019. We also reviewed IMA injuries in our hospital. Only traumatic IMA injuries were included. The demographics, diagnostic procedures, treatments and outcomes were recorded and analyzed.

Results

There were a total of 72 IMA injury cases, including 4 in our hospital. The injuries were predominantly in males (79.2%), were on the left side (66.7%), were considered blunt injuries (63.9%), and featured mediastinal hematoma (62.5%). Computed tomography (CT) has been used to diagnose IMA injuries in recent years. Most patients could be managed by nonsurgical treatments (61.2%). The outcome for IMA injury is very good, with low morbidity and mortality rates.

Conclusions

Identifying traumatic IMA injuries requires alertness from the physicians. An appropriate management chosen according to the patient's individualized condition could lead to a satisfying result.

Trial registration: not applicable

Background

Internal mammary artery (IMA) injury is uncommon among chest traumas. However, this injury is known as a red flag to trauma physicians because of its potential for tremendous life-threatening bleeding (1). In addition, sometimes these injuries could be insidious at first and therefore masked by other more severe injuries (2).

The first case report can be traced back to 1963 (3); however, these injuries have not been well discussed in the literature since then. The aim of this study is to provide a comprehensive review of IMA injuries, review our experiences, and establish a clinical guide.

Methods

PubMed, Embase, and the Web of Science were searched from 1960 to 2019 for available articles using the following keywords: "internal mammary artery injury," "internal thoracic artery injury", "thoracic

injuries", "mammary arteries" and "chest trauma". We focused on trauma cases in this review, so iatrogenic IMA injuries were excluded. Articles were also excluded if general data, the clinical course and the diagnostic tools could not be retrieved from the full text or the abstract.

Two trauma surgeons independently reviewed all studies. Discrepancies between the two reviewers were resolved by a third author.

We also reviewed the trauma registry database of our hospital, which is a level I trauma center, and collected all IMA injuries from 2009 to 2018. For all the included studies and patients, the following variables were recorded: patient age, sex, injury mechanism, lesion side, clinical presentation, diagnostic methods, treatment, and outcome.

Results

During the 50-year period, 38 articles were found, including 4 case series and 34 case reports (1-38). The largest case series had 18 patients. Among the included articles and our database, there were a total of 72 IMA injuries, four of which were from our hospital. The mean patient age was 40.9 years (range 16-86 years), and there was a male predominance (79.2%).

The general data are listed in Table 1. Forty-six patients (63.9%) had blunt injuries, of which traffic accidents were the most common etiology. Twenty-six patients (36.1%) had penetrating injuries, of which stab injury was the most common cause. The left side (66.7%) was involved much more often than the right (16.7%) and bilateral (16.7%) sides. At least 58% of patients had associated injuries. Adjacent structures, such as the heart, lung, nearby vessels, sternum, and rib, were more likely to be involved, while some patients had multisystem injuries.

As shown in Table 2, the most common recorded presentation was mediastinal hematoma (45 patients, 62.5%), followed by hemothorax (33 patients, 45.8%). Among the patients with mediastinal hematoma, nearly one quarter (11/45, 24.4%) had extracardiac tamponade. Fifty-three percent of the cases were reported taking plain chest films. Mediastinal widening was a common finding on plain chest film (63.2%) but was not always present. Based on the retrieved studies that clearly mentioned diagnostic modalities, most of the patients received computed tomography (75.5%), angiography (73.6%), or both (26/53, 49.1%) to identify the lesion sources. The types of IMA injuries according to angiography or surgical findings were described in 57 patients. Transection (38.6%) was the most common injury pattern, followed by contrast extravasation (35.1%) and aneurysm/pseudoaneurysm (17.5%). Arteriovenous fistulas (AVFs) with various adjacent veins were not common but were reported in 5 cases (8.8%) (3, 6, 19, 20, 30).

The management strategies and outcomes are shown in Table 3. Nonsurgical treatment was applied in 61.2% of the patients, including 55.6% who underwent transarterial embolization (TAE) and 5.6% who received conservative treatment. The rest of the patients required surgical intervention. Sternotomy was the most frequent approach, while few patients were managed by antero-lateral thoracotomy incision.

More than three-quarters of the patients recovered uneventfully. Eight patients (11.1%) were mentioned to have complications, including retained/delayed hemothorax, persistent pneumothorax, or pleural effusion. Two patients needed tracheostomy for long-term respiratory failure. The mortality rate was 9.7% (7 patients); however, only one patient died of uncontrolled exsanguination due to IMA (1.4%) (1), and the other deaths were attributed to severe brain injury (1, 21), cardiac injury (13, 36), acute renal injury (36), or multiple organ failure (13).

To clarify the decision-making process when confronting IMA injury, fifty-three patients with a detailed clinical course were selected and are summarized in Figure 1 (1-17, 19-35, 37, 38). Five patients were sent to the operating room directly, while 14 patients underwent surgery after the CT results were reviewed. Among the 34 patients receiving angiography, only 27 patients were managed with embolization, and the other seven patients still underwent surgery.

Discussion

IMA originates from the subclavian artery and comprises the anterior intercostal, perforating,

musculophrenic, superior epigastric, and pericardiophrenic branches. Injury to the IMA and/or its branches is rare in chest trauma, but the anatomical proximity to the heart could result in significant and life-threatening bleeding. In addition, bleeding confined to the mediastinum may result in extracardiac tamponade or the accumulation of blood in the thoracic cavity, resulting in tension hemothorax; both of these conditions could further compromise hemodynamic stability. Early detection is challenging but is very important in clinical practice.

Most chest trauma patients receive a plain chest film first. However, for IMA injury, an unacceptably high proportion of patients would be missed since there are no significant findings. Before multidetector CT was prevalent, angiography was arranged for patients with a high suspicion of mediastinal vessel injury. In our review, eight patients underwent angiography without CT, all of whom were from studies before 2000 (3, 6, 15, 17, 19, 30, 34, 37). After 2000, although diagnosis and treatment could be performed simultaneously by angiography, most physicians chose contrast-enhanced chest CT as the diagnostic tool because of its easy accessibility and ability to provide more comprehensive information. For blunt chest trauma, the National Emergency X-Radiography Utilization Study chest algorithm (NEXUS-chest) has already provided well-validated and practical recommendations for the implementation of chest imaging (39). For penetrating chest trauma, if an IMA injury is suspected according to the depth and route of injury, a contrast-enhanced chest CT scan is the reasonable first choice as long as the patient’s condition is suitable for the exam.

The treatments for IMA injury include observation, TAE, and surgery. Four patients in our review recovered after observation, and all were from the same series (36). In the series from Whigham et al., angiography was performed in all of their 18 patients, but four of them did not receive embolization since no active bleeding was identified. According to our review, TAE for IMA bleeding was first described in 1982 (15). Since the technique and image quality have made large progress in recent decades, TAE has become the

mainstay choice in the literature for managing IMA bleeding due to its less invasive nature and equivalent success rate for hemostasis compared to surgery.

Shock remained the most important reason for surgery. Five patients in our review were operated on directly without CT or angiography (2, 4, 14, 17). Four patients were in shock status before the operation, and the other patient was sent back to the operating room due to massive hemothorax after receiving laparotomy for intra-abdominal bleeding. Fourteen patients underwent surgery after the initial CT scan, including 4 patients for shock(1, 12, 28), three for extracardiac tamponade(10, 16, 23), two for massive hemothorax(1), two for both extracardiac tamponade and hemothorax(1, 24), one for a large aneurysm(25), one for a foreign body (5), and one for persistent bleeding after pericardiotomy (11). Seven patients underwent surgery after angiography. Three were for AVF (3, 6, 19), two for shock (17, 22), one for combined subclavian and vertebral artery injury (27), and one for diagnosis only (37).

The outcome of IMA injury is good. Although the overall mortality rate seems high in our review, only one death was caused by uncontrolled exsanguination due to IMA, while the others were caused by severe associated injuries or organ failure. Most patients had an uneventful course after hemostasis was achieved. In fact, no patients with isolated IMA injury had complications. All reported complications were related to the respiratory system and occurred in those with associated injuries.

Notably, not all IMA injuries were identified at the beginning. Nearly 10% (7 patients) had a delayed presentation (6, 8, 19, 20, 25, 30, 37), especially those with AVF (4 in 5 patients). The duration from the trauma to the delayed diagnosis ranged from 1 week to 10 months. Little is known about these injuries were not identified at first presentation, but we believe that sometimes subtle vessel injuries such as AV shunting do need time to become symptomatic and evident.

Figure 2 is an integrative algorithm for IMA injury that we created after reviewing all of the literature. After performing the initial assessment and resuscitation according to the principles of Advanced Trauma Life Support 10 ed., extremely unstable patients should undergo surgical treatment promptly. For those who could be stabilized, the NEXUS CT-major or NEXUS CT-all criteria should be applied to decide the next step for blunt injuries, and CT is recommended for penetrating injuries if an IMA injury is suspected. If there is no evidence of active bleeding, conservative treatment could be considered, but these patients need close observation. If there is evidence of active bleeding, i.e., contrast extravasation or aneurysm/pseudoaneurysm, TAE could be considered first if the patient is clinically stable. If the following indications exist, surgical exploration is preferred prior to nonsurgical treatment: massive hemothorax, extracardiac tamponade, foreign bodies that need to be removed, difficult approach for TAE (e.g., AVF or large aneurysm), or concomitant injuries that need surgery immediately (e.g., cardiac rupture).

Conclusions

IMA injury is uncommon but should be kept in mind from the initial to delayed phase when managing chest trauma to avoid unfavorable consequences. CT is thus far the main diagnostic tool for IMA injury.

TAE has a high success rate in stopping bleeding in stable patients, while surgery still plays an important role in unstable patients or in certain specific circumstances that could not be resolved by nonsurgical treatments.

Abbreviations

IMA: internal mammary artery; CT: computed tomography; TAE: transarterial embolization; AVF: arteriovenous fistula; NEXUS: National Emergency X-Radiography Utilization Study

Declarations

Ethics approval and consent to participate

This retrospective chart review study was approved by the Human Investigation Committee (IRB) of Chang Gung Memorial Hospital. The need for inform consent was waived

Consent for publication

Not applicable

Availability of data and materials

The datasets used and/or analysed during the current study are available from the corresponding author on reasonable request.

Competing interests

The authors declare that they have no competing interests

Funding

This research did not receive any specific grant from funding agencies in the public, commercial, or not-for-profit sectors.

Authors' contributions

Conceptualization: Yu-Tung Wu, Chien-Hung Liao; Literature review, data collection and analysis: Yu-Tung Wu, Chien-An Liao; Manuscript preparation: Yu-Tung Wu, Chi-Hsun Hsieh, Chih-Yuan Fu

Acknowledgements

Not applicable

References

1. Braatz T, Mirvis SE, Killeen K, Lightman NI. CT diagnosis of internal mammary artery injury caused by blunt trauma. Clin Radiol. 2001;56(2):120-3.
2. Hajjar RJ, Rose GA, Madsen JC, Levine RA, DeSanctis RW. Extrapericardial cardiac tamponade after blunt chest trauma. Am Heart J. 1995;130(3 Pt 1):620-1.
3. Greenfield LJ, Hatcher CR, Jr. Post-Traumatic Internal Mammary Arteriovenous Fistula: Diagnostic Considerations and Report of a Case. Ann Surg. 1963;158:129-30.
4. Al Hassani A, Abdul Rahman Y, Kanbar A, El-Menyar A, Al-Aieb A, Asim M, et al. Left internal mammary artery injury requiring resuscitative thoracotomy: a case presentation and review of the literature. Case Rep Surg. 2012;2012:459841.
5. Alpat S, Saydam O, Aydin H, Dogan R. Small but mighty: unusual cause of massive mediastinal hematoma. J Emerg Med. 2014;47(2):214-5.
6. al-Qudah AH. Traumatic internal mammary arteriovenous fistula. A case report and review of the literature. Thorac Cardiovasc Surg. 1988;36(3):164-6.
7. Betsch M, Jungbluth P, Grassmann JP, Furst G, Windolf J, Wild M. [Bilateral injuries of the internal mammary artery following blunt thoracic trauma]. Unfallchirurg. 2010;113(9):757-60.
8. Brimont O, Meurisse C, Vilarem D, Manouvrier J, Peltier JM, Cuignet P. [False traumatic aneurysm of the internal mammary artery caused by a stab wound. Apropos of a case]. Arch Mal Coeur Vaiss. 1993;86(3):377-9.
9. Cagini L, Vannucci J, Scialpi M, Puma F. Diagnosis and endovascular treatment of an internal mammary artery injury. J Emerg Med. 2013;44(1):e117-9.
10. Cardinale L, Cataldi A, Giardino R, Prato A, Volpicelli G. Delayed presentation of a huge mediastinal hematoma after blunt chest trauma with extrapericardial cardiac tamponade: a multiphase-multidetector spiral computed tomography study. J Trauma. 2010;69(4):996.
11. Cheng YC, Huang JW, Lee WC, Kuo LG, Lin TY, Shih MC. Retrosternal haematoma presenting as cardiac tamponade in a blunt trauma patient. Emerg Med J. 2009;26(6):462.
12. Cho DG, Chang YJ, Cho KD. A laceration of left internal mammary artery caused by an amateur golfer's swing. J Thorac Dis. 2017;9(11):E982-E4.
13. Corvino F, Giurazza F, Cangiano G, Cavaglia E, Amodio F, De Magistris G, et al. Safety and effectiveness of transcatheter embolization in the treatment of internal mammary artery injuries. Radiol Med. 2018;123(5):369-77.
14. Hartert M, Dahm M, Neufang A, Vahl CF. Minimum cause–maximum effect: the travelogue of a bullet. Interact Cardiovasc Thorac Surg. 2010;11(5):698-700.
15. Husted JW, Stock JR, Manella WJ. Traumatic anterior mediastinal hemorrhage: control by internal mammary artery embolization. Cardiovasc Intervent Radiol. 1982;5(5):268-70.
16. Iqbal Z, Gandhi SD, Markan S, Nicolosi AC, Pagel PS. A widened mediastinum in a patient with a left parasternal stab wound. J Cardiothorac Vasc Anesth. 2007;21(2):307-9.

17. Irgau I, Fulda GJ, Hailstone D, Tinkoff GH. Internal mammary artery injury, anterior mediastinal hematoma, and cardiac compromise after blunt chest trauma. J Trauma. 1995;39(5):1018-21.
18. Ishida I, Oura H, Kawakami T, Shiga K, Sakatsume K, Sasaki Y, et al. [Patient with massive hemothorax due to blunt trauma saved by transcatheter arterial embolization (TAE)]. Kyobu Geka. 2013;66(6):445-8.
19. Ishikawa T, Brown GR. Traumatic arteriovenous fistula of the internal mammary artery. J Trauma. 1977;17(12):978-80.
20. Ito T, Sakamoto T, Norio H, Kaji T, Okada Y. An arteriovenous fistula between the internal mammary artery and the pulmonary vein following blunt chest trauma. Cardiovasc Intervent Radiol. 2005;28(1):120-3.
21. Kawamura S, Nishimaki H, Takigawa M, Lin ZB, Imai H, Hayakawa K, et al. Internal mammary artery injury after blunt chest trauma treated with transcatheter arterial embolization. J Trauma. 2006;61(6):1536-9.
22. Khoynezhad A, Barrett L, Hayn E, Shaftan GW. Total mediastinal traverse with isolated internal mammary artery transection. J Card Surg. 2004;19(2):136-8.
23. Kim YH, Kwon JB, Park CB, Choi SY. Extrapericardial cardiac tamponade by a retrosternal haematoma after blunt chest trauma. Eur J Cardiothorac Surg. 2012;41(4):958.
24. Kwon OY, Chung SP, Yoo IS, Song CJ, Kim IB, Kim SW. Delayed presentation of internal mammary artery rupture after blunt chest trauma: characteristic CT and plain x ray findings. Emerg Med J. 2005;22(9):664-5.
25. Ma RY, Yang ZY, Jian Z, Chen L, Xiao YB. Traumatic aneurysm of the right internal thoracic artery. Ann Thorac Surg. 2012;93(4):e107.
26. Machin VG, Lau OJ. Extra-pleural haematoma secondary to blunt chest trauma. An unusual presentation. Eur J Cardiothorac Surg. 1995;9(2):109-10.
27. Madoff DC, Brathwaite CE, Manzione JV, Bilaniuk JW, Giron F, Char D, et al. Coexistent rupture of the proximal right subclavian and internal mammary arteries after blunt chest trauma. J Trauma. 2000;48(3):521-4.
28. Nomori H, Ootsuka T, Horio H, Naruke T, Suemasu K. Bilateral internal thoracic artery injury induced by blunt trauma. Jpn J Thorac Cardiovasc Surg. 2003;51(5):214-6.
29. Patel K, Kimbrell BJ, Marx MV, Petrone P, Asensio JA. Angiographic embolization of an expanding breast hematoma after blunt trauma: a novel approach to a rare injury. J Trauma. 2009;67(1):E14-6.
30. Radanovic B, Simunic S, Oberman BB, Jernej B, Tonkovic I, Kruzic Z. Arteriovenous fistula of the internal mammary artery (combat injury): transcatheter intravascular coil occlusion. Eur Radiol. 1996;6(2):236-8.
31. San Norberto EM, Cilleruelo A, Martin-Pedrosa M, Taylor J, Garcia-Yuste M, Vaquero C. Endovascular treatment of posttraumatic pseudoaneurysm of the internal mammary artery. Ann Vasc Surg. 2014;28(3):743 e1-5.

32. Sawamoto T, Aoki H, Otsuka H, Morita S, Inoue S, Nakagawa Y, et al. Successful Treatment of Blunt Musculophrenic Artery Injury by Transcatheter Arterial Embolization: A Case Report. Tokai J Exp Clin Med. 2017;42(3):126-9.
33. Sharma OP, Blaney J, Oswanski MF, Assi Z, Disalle R, Latocki V. Stab wound of the neck with contralateral hemo-pneumothorax. J Emerg Med. 2010;39(4):e135-8.
34. Smith DC, Senac MO, Bailey LL. Embolotherapy of a ruptured internal mammary artery secondary to blunt chest trauma. J Trauma. 1982;22(4):333-5.
35. Tourmousoglou C, Zambakis P, Koletsis E, Prokakis C, Charoulis N, Dougenis D. Coil embolization of traumatic pseudoaneurysm of right internal thoracic artery. Asian Cardiovasc Thorac Ann. 2015;23(8):982-4.
36. Whigham CJ, Jr., Fisher RG, Goodman CJ, Dodds CA, Trinh CC. Traumatic injury of the internal mammary artery: embolization versus surgical and nonoperative management. Emerg Radiol. 2002;9(4):201-7.
37. Wilkinson J, Jacob TD, Armitage J, Zajko A, Udekwu AO, Peitzman AB. Avulsion of the internal mammary artery caused by blunt trauma. Ann Emerg Med. 1993;22(11):1762-5.
38. Yeh CC, Hsieh CH, Wang YC, Chung PK, Chen RJ. Concomitant aortic valve and internal mammary artery injuries in blunt chest trauma: report of a case. Surg Today. 2009;39(9):790-4.
39. Rodriguez RM, Hendey GW, Mower WR. Selective chest imaging for blunt trauma patients: The national emergency X-ray utilization studies (NEXUS-chest algorithm). Am J Emerg Med. 2017;35(1):164-70.

Tables

Table 1. The demographics and injuries of all included patients (n=72).

	n (%)
Age (year, range)	40.9 (16–86)
Sex	
Male	57 (79.2)
Female	15 (20.8)
Injury type	
Blunt	46 (63.9)
Penetrating	26 (36.1)
Mechanism	
Traffic accident	25 (34.7)
Fall	8 (11.1)
Hit	7 (9.7)
Gun shot	8 (11.1)
Stab	16 (22.2)
Explosive	1 (1.4)
Not mentioned/others	7 (9.7)
Location	
Left	36 (66.7)
Right	9 (16.7)
Bilateral	9 (16.7)
Not mentioned	18
Combined injuries*	
Lung	18
Rib	12
Sternum	10
Hemopericardium	8
Abdomen	7
Extremities	7
Heart	6
Spine	5
Nearby vessels	2
Brain	1
Aorta	1

* The proportion was not shown here since associated injuries were not reported in many studies, so the proportion has little reference value.

Table 2. The clinical presentation, image modality used, and vessel findings of the included IMA injuries.

	n (%)
Presentations	
Mediastinal hematoma	45/72 (62.5)
Hemothorax	33/72 (45.8)
Extracardiac tamponade	11/72 (15.3)
Chest plain film	38/72 (52.8)
Mediastinal widening	24/38 (63.2)
CT	40/53 (75.5)
Angiography	53/72 (73.6)
IMA injury findings	
Transection	22/57 (38.6)
Extravasation	20/57 (35.1)
Aneurysm/pseudoaneurysm	10/57 (17.5)
AVF	5/57 (8.8)
NA	15

* NA: not available

Table 3. The management strategies and outcomes of all included cases.

	n (%)
Management	
Conservative	4 (5.6)
TAE	40 (55.6)
Sternotomy	16 (22.2)
Thoracotomy	4 (5.6)
ED Thoracotomy	1 (1.4)
Operation (procedure not mentioned)	7 (9.7)
Outcome	
Uneventful	56 (77.8)
Complications	8 (11.1)
Mortality	7 (9.7)
NA	1 (1.4)
Complications	
Delayed/retained hemothorax	3
Persistent pneumothorax	2
Respiratory failure requiring tracheostomy	2
Pleural effusion	1

* TAE: transarterial embolization, ED: emergency department, NA: not available

Figures

Figure 1.

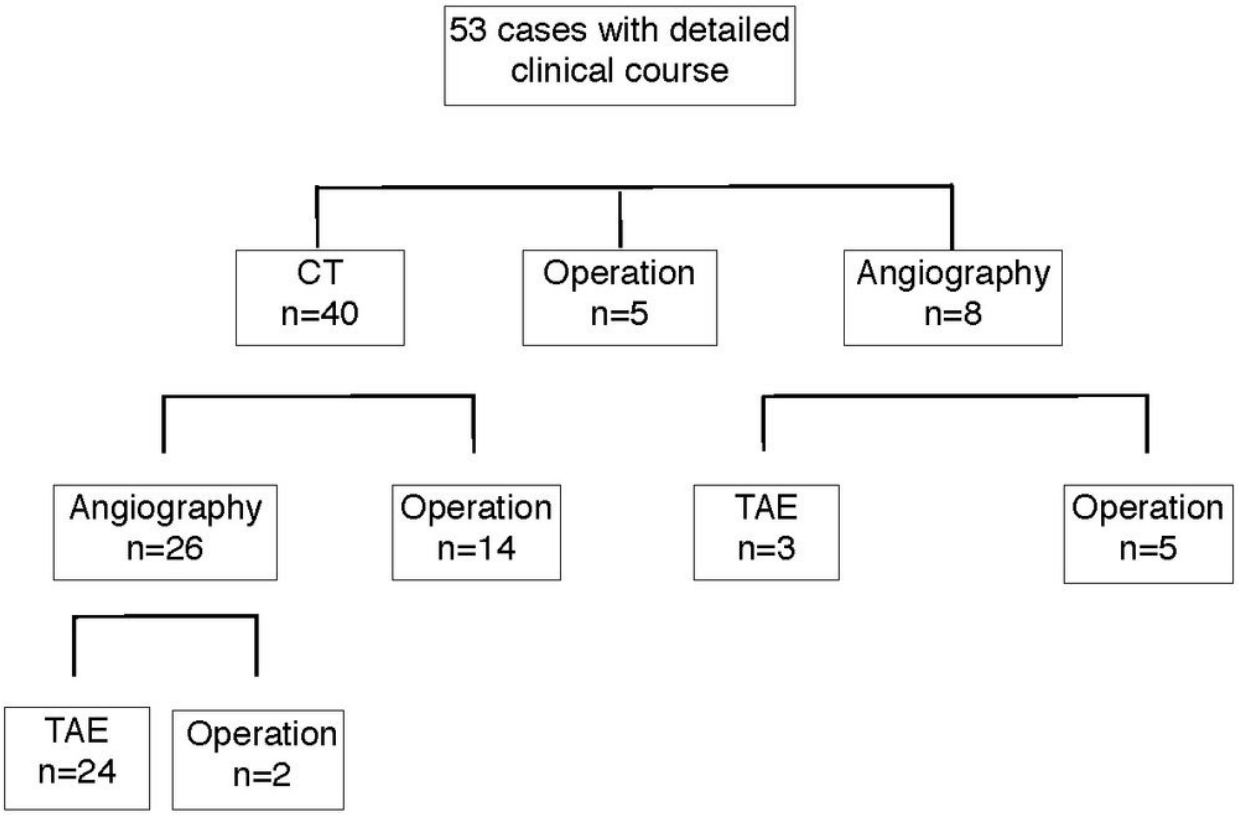

Figure 1

Summary of 53 patients whose treatment course was described in the literature. For these 53 patients, 27 were managed by transarterial embolization (TAE), and 26 underwent surgery. Among the 26 patients who underwent surgery, 5 underwent surgery directly, 14 underwent surgery after CT, 5 underwent angiography, and the remaining 2 underwent surgery following both CT and angiography.

Figure 2.

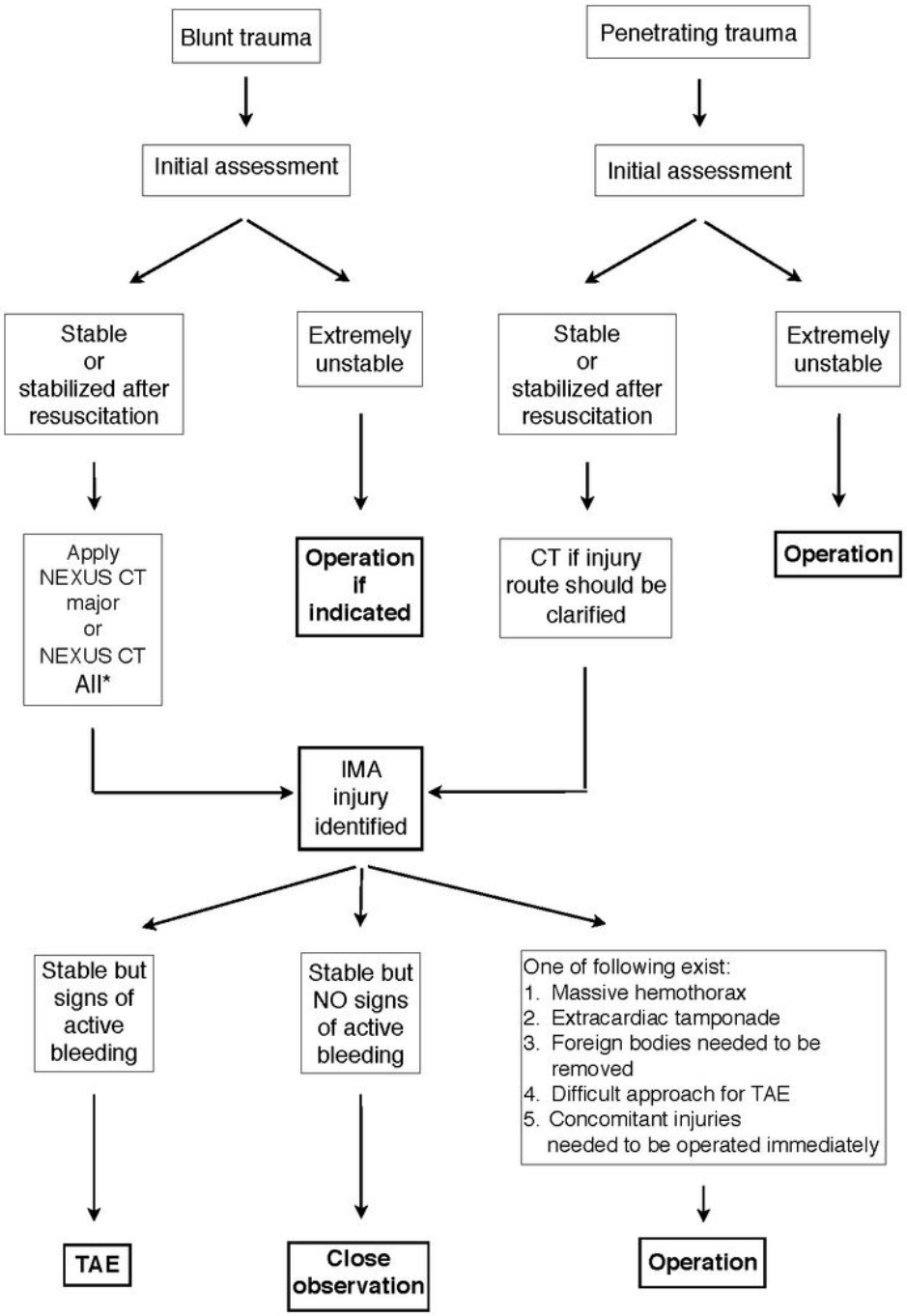

Figure 2

Proposed algorithm for the management of IMA injury. Immediate operation is indicated for patients with extremely unstable hemodynamics. The NEXUS CT-Major or All criteria were applied as selection criteria for CT in patients with blunt chest trauma (39). TAE should be considered for stable patients with active bleeding, while surgery should be considered for several situations, as shown in the algorithm. NEXUS CT-Major = 1) distracting injury; 2) chest wall tenderness; 3) sternal tenderness; 4) thoracic spine tenderness;

and 5) scapular tenderness. NEXUS CT-All = CT Major criteria + rapid deceleration mechanism. Patients having 2 or more criteria present should obtain chest CT. Patients having 1 criterion present should consider CT. Patients having all criteria absent are safe to forego chest CT.