Facial Nerve Outcome and Results in Hypervascular Large Vestibular Schwannomas: Our Personal Experience in A Series of 32 Cases.

Luciano Mastronardi (mastro@tin.it)
San Filippo Neri Hospital/ASLRoma1 https://orcid.org/0000-0003-0105-5786

Alberto Campione
San Filippo Neri Hospital/ASLRoma1

Fabio Boccacci
San Filippo Neri Hospital/ASLRoma1

Carlo Giacobbo Scavo
San Filippo Neri Hospital/ASLRoma1

Ettore Carpineta
San Filippo Neri Hospital/ASLRoma1

Guglielmo Cacciotti
San Filippo Neri Hospital/ASLRoma1

Raffaelino Roperto
San Filippo Neri Hospital/ASLRoma1

Albert Sufianov
Federal Centre of Neurosurgery, Tyumen, Russian Federation

James K. Liu
Rutgers University-New Jersey Medical School

Research Article

Keywords: Adhesions, hypervascular, facial nerve, microneurosurgery, vestibular schwannoma.

Posted Date: June 7th, 2021

DOI: https://doi.org/10.21203/rs.3.rs-515553/v1

Abstract

Background

Vestibular schwannomas (VS) are usually hypovascularized. Large VS with unusual vascular architecture are defined hyper-vascular (HVVS); excessive bleeding during microsurgery has negative impact on results.

Methods

Thirty-two consecutive patients were operated on for HVVS (Group-A). Results were compared with those of 25 patients (Group-B) operated on for large low-bleeding VS. Tendency to bleed and adherence of capsule to nervous structures were evaluated by reviewing video records. Cisternal facial nerve (FN) position was reported. Microsurgical removal was classified as total, near-total, subtotal or partial and MIB-1 index evaluated in all. FN results were classified according the House-Brackmann scale.

Results

Mean tumor diameter was 3,99cm in Group-A and 3,67 in Group-B; mean age was 42,3 and 58,1 years, respectively. Mean ASA class of Group-A was 1,72 versus 2,48 of Group-B ($p<0,001$). Total-NT resection was accomplished in 71,9% of HVVS versus 80,0% of Group-B. Tight capsule adhesion was observed in 68,7% HVVS versus 56,0% low-bleeding ones. Mean MIB-1 was 1,25% and 1,08%, respectively.

Anterior-superior position of FN was observed in 48,6% of HVVS versus 32,0% of low-bleeding tumors ($p<0,05$). FN anatomical preservation was possible in 81,2% of Group-A versus 100% of Group-B ($p<0,05$); 62,5% of HVVS had HBI-II FN outcome versus 96,0% of low-bleeding ($p<0,01$). In Group-A 25,0% experienced postoperative complications versus 8,0% of Group-B ($p<0,05$). Recurrence/re-growth was observed in 7 HVVS versus 1 low-bleeding ($p<0,05$).

Conclusions

Microsurgery of large HVVS was associated with higher complication and recurrence/re-growth rate and poorer FN outcome, especially in cases with tight capsule adhesion.

Introduction

According to Koos' classification (21), Grade IV vestibular schwannomas (VS) are large tumors (longitudinal diameter > 3 cm) compressing brainstem, displacing fourth ventricle and compromising the quality of life of patients. During the last decades their incidence has gradually reduced for the broad and earlier access to MRI imaging (48, 50, 51). In the past, Grade IV VS represented 40% of all tumors, whereas they accounted only a few percent during the last 10 years. (38). Surgical resection represents the treatment of choice in order to achieve a clinically significant improvement (38, 53, 54).

Microsurgery of Grade IV VS is technically challenging because of adhesions of tumor capsule to the brain stem and facial nerve (FN), unusual displacement of the nerve and, in several cases, tendency of tumor to bleeding. In particular, even if majority of VS are hypovascular tumors, some tumors may have an unusual vascular architecture and are better defined “hypervascular vestibular schwannoma” (HVVS). The rate of HVVS increases with size (49) of tumors and its incidence seems to be higher in large and solid VS and in younger patients (56). Blood supply of VS comes from branches of external carotid artery (ECA) and from vertebral-basilar (VB) system (49, 56). According to the angiographical analysis of Teranishi et al (49), HVVS have a high concentration of abnormal vessels, with or without arteriovenous (AV) shunts, with tumor stain from external carotid artery (ECA) and/or vertebral-basilar (VB) arteries.

Few Authors (23, 49, 56) analyzed in detail the behaviour and the outcome of HVVS in comparison to hypovascular ones. In this study, we retrospectively analyzed the clinical and surgical data and the outcome of a consecutive series of 32 patients with Grade IV HVVS consecutively operated on by retrosigmoid approach, highlighting the extent of tumor removal, postoperative FN outcome, and complications, in comparison to a 25 low-bleeding VS, surgically treated during the same period.

Materials And Methods

Study design

This observational single-center study was carried out at a tertiary care referral hospital. It was conducted after obtaining clearance from the Internal Ethics Committee of our institution and in accordance with the principles set forth in the Helsinki Declaration. A written consent for scientific treatment of personal data was obtained from any patient before surgery. Cohorts included all patients who underwent surgery for Koos Grade IV VS in the period between Department between December 2010 and December 2019: 32 hypervascular (Group A) and 25 hypovascular/low-bleeding tumors (Group B). All patients were followed up till June 2020. The mean follow-up duration for inclusion was 63 months (median 63,5).

Data Collection

Data was collected from case sheets, operative notes, neuro-imaging archiving and communication systems (PACS) and discharge summaries, after obtaining informed consent from patients. Subsequently, the patients were followed up on an out-patient basis. The parameters that were studied included demographic profiles, clinical features, duration of symptoms, neurological status, neuroimaging, operative details, histopathological data, recurrence, functional outcome, mortality and morbidity.

We reviewed 32 consecutive cases of Koos Grade IV hypervascular VS (HVVS) out of 220 unilateral VS surgically treated by the first Author between December 2010 and December 2019. Results were compared with those of 25 patients (Group B) operated on in the same period for hypovascular grade IV VS, presenting low intraoperative bleeding.

General conditions and preoperative risk were assessed according to the American Society of Anesthesiology (ASA) classification (30). Patients with neurofibromatosis type 2 were not included. Clinical data such as patients' age, sex, presenting symptoms and tumor size were recorded. Preoperative neuroimaging included temporal bone CT and contrast-enhanced MRI in all patients and allowed to evaluate VS size and possible presence of one or more intratumoral cysts. Tumor size was categorized according to the international criteria, measuring the largest extrameatal tumor diameter on post-contrast axial MRI. (19) The MRI-slices of HVVS consistently showed multiple "serpiginous" flow voids, representing large feeders and draining veins within the mass, especially in T2-weighted images (Fig. 1).

Preoperative audio-vestibular evaluation included pure tone audiometry and speech audiometry. Hearing level was assessed according to the American Academy of Otolaryngology–Head and Neck Surgery (AAO-HNS) classification (8): Class A and B were categorized as good hearing.

Microsurgery via retrosigmoid approach was performed in all cases. Location of FN and its adherence to the tumor were evaluated by reviewing radiological images, surgical and video records. The course of the FN was classified according to its position in relation to the tumor: anterior (A), anterior-inferior (AI), anterior-superior (AS), and dorsal (D) (26, 41). The extent of tumor removal was classified as total (T), near total (NT: tumor residue < 5%), subtotal (ST: residue 5–10%), and partial (P: residue > 10%). Since about 3 years, at the end of microsurgical resection, a 4-mm Flexible Video Endoscope (4-mm x 65-cm, Karl Storz, GmbH, Tuttlingen, Germany) has been inserted in the surgical cavity, handled by the surgeon (9, 10), in order to detect eventual tumor residues in the internal auditory canal (IAC). On pathological examination of tumor, MIB-1 index was evaluated in all cases.

We classified the extent of tumor removal as total (T), near total (NT: linear millimetric residual tumor), subtotal (ST: residual tumor volume < 10%), and partial (P: residual tumor volume > 10%). Extent of resection was evaluated by means the blind review of postoperative MRI performed by one member of our neurosurgical staff (coauthor) and one neuroradiologist.

FN function was assessed according to House-Brackmann (16) (HB) grading system and was evaluated preoperatively, at discharge and at final follow-up (≥6 months).

Neurophysiological monitoring

All the surgical procedures were performed with intraoperative FN monitoring system (Nimbus i-Care 100 intraoperative neurophysiologic monitoring; Newmedic Division of Hemodia, Labège, France), with electrodes inserted in orbicularis oris and orbicularis oculi muscles, to detect FN responsivity. The nerve stimulation was performed with monopolar (on tumor surface) or bipolar (close to the nerve) probes to locate the facial nerve and verify its functional state.

Operative technique

The retrosigmoid approach was used in all the surgical procedures. A slightly curved skin incision, 5 to 6 cm long, was performed behind the ear, 1–2 cm posteriorly to the mastoid process. The lateral occipital

bone was exposed, including superior and inferior nuchal lines. A retrosigmoid suboccipital craniotomy, 3cm in length and width, was performed, exposing sigmoid sinus anteriorly and transverse sinus superiorly. The retrosigmoid dura was incised in a semicircular fashion, lateral medullary cistern was opened and cerebrospinal fluid (CSF) was aspirated to obtain adequate cerebellar decompression. After cutting the dura along the “Tuebingen line” (3), a dural landmark on the IAC inferior limit on the posterior surface of the petrous temporal bone, the canal was opened through a 4mm extra-coarse diamond burr or by ultrasonic aspirator with dedicated bone tips. The tumor surface was exposed and the rare but possible dorsal displacement of FN was investigated by monopolar stimulation. The intracapsular, either subperineural (subcapsular) or subarachnoid plane of surgery (20) was used in any case for debulking, detachment and dissection, respectively, even if in all cases we tried to follow the arachnoid reflection over cranial nerves and brainstem for obtaining the best functional results.

A V-cut was performed on the dorsal surface of tumor with microscissors or hand-held laser thulium and debulking of tumor was obtained with microscissors, microcurettes, bipolar forceps, hand-held laser fiber, and ultrasonic aspirator.

In particular, capsule incision and tumor debulking of HVVS has been performed with hand-held 2μ-Thulium flexible laser fiber (Revolix jr®, Lisa laser USA, Pleasanton, CA, USA), with a range of power setting from 1 to 14W. Standard 0,9% saline solution irrigation has been used for cooling surrounding tissues and the fiber, which is not hindered in its function by the presence of water. The fiber is used for cutting, vaporizing, and coagulating the capsule and the intracapsular mass, in combination with low-power bipolar forceps, microscissors and Sonopet Ultrasonic Aspirator (Stryker, Kalamazoo, MI).

Following tumor debulking, the remaining tumor capsule was then dissected from brainstem and cranial nerves during continuous facial nerve monitoring with standard microsurgical tools. In some cases of strong tumor adherence to surrounding structures, a millimetric remnant of tumor capsule was left, thus yielding a near-total resection. In few cases with tight tumor capsule adherences to FN and/or brainstem and high-bleeding rate of tumor a ST removal was performed. Accurate hemostasis, mastoid cells obliteration, and tight dura closure by pericranial graft, hemostatic materials and sealants were performed and the bone operculum or a fitted titanium mesh was placed on the craniectomy with miniscrews.

Bleeding rate and Adhesion of tumor capsule

For assessing the tendency of tumor to bleed and the adherence of capsule to FN and brainstem, two independent “blinded” reviewers and coauthors espressed their opinion watching the surgical video, without considering the impression of surgeon wrote in the report.

Bleeding tumors, classified as HVVS, had an unusual and redundant superficial and internal vascular architecture. Except for the angiographical classification proposed by Teranishi et al (49), there is not in the literature any objective definition of “hypervascularity”. During surgery, in all these cases intra- and extratumoral vascularity was arterialized due to luxurious shuntings and removal was complicated by

high-rate bleeding during debulking and dissection, because of the rupture of the multiple vessels present in the capsular and intracapsular portion of tumor. The possible high-bleeding behaviour of tumor was suspected in the preoperative T2-weighted MRI images when multiple “serpiginous” flow voids, representing large feeders and draining veins, within the mass were detected. Reviewing the surgical videos, the “blind” independent observers rated the bleeding amount and classified tumors in hypervascular and hypovascular.

VS without a clear perineural dissection plane between nervous structures (in particular, FN and brainstem) and tumor capsule were considered more adherent, in comparison to VS with well recognizable dissection plane (less adherent). Unfortunately, there is no scale for the degree of adhesion: therefore, less strong adherences were defined as those in which the FN and brainstem could be separated from the tumor comparatively easily with a microdissector, and strong adherences were defined as those that were difficult to separate, requiring sharp dissection with microscissors. In cases where adhesions where too tight and in presence of brainstem edema, total resection was considered unsafe and a less than total resection was accepted.

Clinical follow-up

Long-term FN outcome evaluation was performed at 6 months after operation and at last follow-up and was categorized according to House-Brackmann grades I-VI. Clinical and radiological follow-up was scheduled at 6 months after operation and then once a year; follow-up period ranged between 6 and 117 months (mean 63, median 63,5).

Statistical analysis

Statistical analysis was performed by means chi-square test for categorical variables and Student’s t-test for continuous ones, using the software MS Excel (Microsoft Corporation, Redmond, WA, USA). Statistical significance was set at $p < 0,05$.

Results

Characteristics of the patients and clinical presentation

Maximal mean tumor diameter of Group A was 3,99cm (range 3,1–5,5m) in comparison to 3,67cm (range 3,1–4,5 cm) of Group B (p = NS). Among the 32 cases of HVVS, 17 were males and 15 females, whereas in Group B 11 were males and 14 females. Mean age of Group A was 42,3 years (range: 22–64; SD: 12,8), versus 58,1 (range 43–80; SD: 26,1) of Group B (p = NS). Preoperative general conditions of patients with HVVS were significant better than those with hypovascular tumors: mean ASA class was 1,72 in Group A (range 1–2) versus 2,48 (range 1–3) in Group B ($p < 0,001$), partly related to the younger mean age of patients with HVVS. In 7 cases of Group A (21,9%) and in 6 cases of Group B (24,0%) the VS had one or more cysts inside (p = NS). Severely impaired hearing or deafness was present in all cases of Group A and in 23 cases (92,0%) of Group B; hearing preservation was not possible in the 2 patients with low-bleeding VS with preoperative AAO-HNS hearing Class B.

Preoperative HBII to HBIV FN deficit was observed in 6 HVVS (18,7%) and in 3 (12,0%) low-bleeding VS (p = NS).

Preoperative patients data are summarized in Table 1.

Table 1. Preoperative clinical and radiological data of the study population.

CHARACTERISTICS		Group A (n=32) HVVS	Group B (n=25) Low-bleeding VS	Chi-test
SEX	Female	15 (46,9%)	14 (56,0%)	NS
	Male	17 (53,1%)	11 (44,0%)	
MEAN AGE ± SD (years)		42,3±12.8 (range 22 – 64)	58,1±26.1 (range 43 – 80)	NS
MEAN DIAMETER	(cm)	3,99cm (range 3,1-5,5)	3,67cm (range 3,1-4,5)	NS
ASA GRADE	Mean (range 1-3)	1,72	2,48	p<0,001
ONE OR MORE CYSTS		7 (21,9%)	6 (24,0%)	NS

HEARING LOSS	AAO-HNS Grade C	14 (40,0%)	12 (48,0%)	NS
	AAO-HNS Grade D	21 (60,0%)	11 (44,0%)	
PREOPERATIVE FACIAL NERVE DEFICIT	HB II	3	1	NS
	HB III	2	2	
	HB IV	1	0	

Extent of resection, MIB-1 index and Adhesions of Tumor Capsule

On considering the entire cohort, Total or NT resection was obtained in 43 cases (75,4%), in 23 patients with HVVS (71,9%) and in 20 (80,0%) with hypovascular tumors (p = NS). Mean MIB-1 index was 1,25% (range 1–3) in Group A and 1,08% (range 1–2) in Group B (p = NS).

Tight adhesion of capsule to nervous structures was observed in 22 HVVS (68,7%) versus 14 (56,0%) low-bleeding tumors (p = NS).

Data related to surgical and pathological details are summarized in Table 2.

Table 2. Extent of surgical removal and age, MIB-1 index, adhesion of capsule and recurrence rate

		Group A (32 cases)	Group B (25 cases)	Chi-test
Extent of resection	**T - NT**	23 (71,9%)	20 (80,0%)	
	ST	9 (28,1%)	5 (20,0%)	NS
MIB-1 index	mean	1,25% (range 1-3)	1,08% (range 1-2)	NS
Capsule adhesion to nervous structures	yes	22 (68,7%)	14 (56,0%)	NS
	not	10 (31,3%)	11 (44,0%)	
Recurrence rate		7 (21,9%)	1 (4,0%)	p<0,05

T=total; NT=near-total; ST=sub-total; NS=not significant

Long-term Facial Nerve Outcome

As a whole, in our patients a postoperative HBI-II outcome was observed in 44 out of 57 cases (77,2%). In particular, anatomical preservation of FN was possible in 26 HVVS (81,2%) versus 100% low-bleeding tumors ($p < 0,05$). Anterior-superior (AS) position of FN was observed in 48,6% (17 cases) of HVVS and in 32,0% (8 cases) of Group B ($p < 0,05$).

Twenty HVVS (62,5%) had a long-term HBI-II FN result versus 24 (96,0%) low-bleeding VS ($p < 0,01$). In addition, adhesions of tumor capsule to the nerve had a negative impact on FN outcome of patients of Group A: HBI-II FN result was obtained only in 40,0% (8/20) of adherent HVVS versus 95,8% (23/24) of low-bleeding adherent tumors ($p < 0,05$).

Data related to FN outcome are summarized in Table 3.

Table 3. FN position and results.

		Group A (n=32)	Group B (n=25)	Chi-test
Anatomical preservation of FN				
	yes	26 (81,2%)	25 (100%)	p<0,05
	not	6 (18,8%)	0	
FN position in the cisternal segment				
	AS	17 (48,6%)	8 (32,0%)	p<0,05
	A-AI	25 (51,4%)	17 (68,0%)	
FN results at follow-up				
	HBI-II	20 (62,5%)	24 (96,0%)	p<0,01
	HB>III	12 (27,5%)	1 (4,0%)	
HBI-II and adherence of capsule				
	Adherent	8/20 (40,0%)	1/24 (4,2%)	p<0,05
	Non-adherent	12/20 (60,0%)	23/24 (95,8%)	

Postoperative complications and recurrences

Mortality rate was zero in both Groups.

Postoperative complications have been observed in 8 cases of Group A (25,0%) versus 2 (8,0%) of Group B ($p < 0,05$). All complications were transient except for one patient of Group A presenting permanent diplopia for abducens nerve paralysis.

Postoperative transient complications consisted of: wound infection in 3 cases, transient diplopia in 2, cerebellar mutism, dysphagia and pneumonia (resolved with antibiotics), cerebellar infarction, and hydrocephalus (resolved with ventricular-peritoneal shunt) in 1 each.

At a mean follow-up of 63 months (median 63,5), a recurrence/re-growth of tumor was observed in 8 cases, all operated on with ST removal of tumor: 7 (21,9%) patients with HVVS (2 were re-operated, 2 performed SRS, and 3 are stable and under observation) and 1 (under observation) with low-bleeding tumor ($p < 0,05$). Re-operation or SRS were considered in those cases with progressive re-growth of VS; SRS is preferred in older subjects with ASA III or worst general conditions or if the patient refused a second surgery.

Complications and recurrences are summarized in Table 4.

Table 4. Mortality and morbidity (permanent and transient complications)

MORTALITY, MORBIDITY and SECOND SURGERY for RECURRENCE	Group A (n=32)	Group B (n=25)	Chi-test
MORTALITY	zero	zero	
COMPLICATIONS	8 (25,0%)	2 (8,0%)	p<0,05
PERMANENT COMPLICATIONS	1 (diplopia for abducens nerve paralysis)	zero	

Discussion

Grade IV VS represent a challenge for surgeons, especially if tumor has a high concentration of abnormal vessels and arteriovenous shunts (49). Few studies (23,49,56) report clinical behaviour and results of HVVS in comparison to hypovascular low-bleeding variant.

According to Yamakami et al (56), HVVS are large and solid tumors, presenting more often in younger patients. In our series, the mean diameter of HVVS (Group A) was about 4cm, solid tumors represented more than 78% of cases and mean age was 42,3 years, lower than that of patients with hypovascular VS (58,1 years), even if this difference was not statistically significant. Notwithstanding, preoperative mean ASA class of patients with HVVS was better than that of low-bleeding cases (1,72 versus 2,48; p<0,001); it is reasonable to believe that this difference could to be partially attributable to the mean younger age of Group A.

Large and bleeding VS

Microsurgery of Koos Grade IV HVVS is usually difficult, especially in those cases with the capsule adherent to nervous structures, namely to brainstem and FN.

The significance and relevance of bloody supply for microsurgery and outcome of VS has been only seldom reported in the literature (1,32). Although preoperative angiography provides characteristic findings (49), MRI can confirm the diagnosis of a HVVS by showing multiple flow-voids in the contest of the tumor (Fig.1). Teranishi et al (49) proposed a classification of HVVS in 5 types in relation to tumor feeders (VB system only or VB system and ECA branches) and to the presence or not of arterio-venous shunts. The presence of shunts resulted to be less frequent but was associated with statistically significant higher rate of recurrence, especially those cases with feeders from VB system and ECA branches and with arterio-venous shunts originating from vertebral-basilar arteries (p=0,0476).

Some Authors (23,56) proposed a 2-step surgical strategy for the treatment of HVVS, on considering that partial resection performed with the first surgery could reduce the hypervascularity of tumor, making total removal less risky and more feasible with the second surgical step. However, we agree with Teranishi et al (49) that it is seems to be preferable to attempt T/NT resection of HVVS during the first surgery, for the overall comfort of patients and for reducing the risk of postoperative hemorrhage possible after the first step of partial resection.

According to Peris-Celda et al. (35), large tumors are significantly more frequent among younger patients at diagnosis (p<0,001), similarly to what happens in patients affected by NF2, suggesting a possible more aggressive tumor biology. In particular, on comparing VS with maximal diameter >4cm (more than 7% of their series) with the rest of the cohort, they observed a statistically significant difference in terms of mean age at diagnosis: 52,3 years for smaller versus 42,4 years for larger tumors (p<0,001). (35)

Angiogenesis is essential for the enlargement of any solid tumor, including schwannomas: it has been demonstrated that VEGF expression of VS correlates with tumor growth pattern. (5,36) Vascular endothelial growth factor (VEGF) is considered to be a major regulator and VEGF receptor (VEGFR)-1 and VEGFR-2, have been identified on the cell surface of vascular endothelial cells. (13,55) In addition, VEGF and matrix metalloproteinases (MMPs) are strong mediators of tumor angiogenesis: Moller et al. (31) observed that tumor concentration of MMP-9 correlates with VS growth rate and adhesion to nerve structures, concluding that this collagenase is strongly involved in the growth of VS. Moreover, a relationship among vascularization, adhesions and tumor size is quite reasonable, probably through the expression of MEK/ERK effectors, oncogenic gene miR-21 and mTOR pathways (57), which regulate several cellular processes.

To date, few studies attempted to profile genome-wide alterations in sporadic VS. In a series of 23 sporadic VS, Carlson et al. (4) analyzed fresh frozen tumor specimens and matched peripheral blood leukocytes, in order to identify if more clinically aggressive variants possess different genetic alterations compared to the more indolent. Using high-throughput deep sequencing, “two-hit” alterations in the NF2 gene were identified in every tumor and were not present in peripheral blood supporting that all events

were somatic. (4) Type of NF2 gene alteration and accessory mutations outside the NF2 locus may predict phenotypic expression and clinical course.

Surgical dissection for large, vascularized and adherent VS.

The layers we encounter starting from the surface of VS are: (1) Arachnoid folder; (2) FN and cochlear nerve; (3) perineurium/nerve fibers of vestibular nerve of origin of VS (5,36,39). Thus, the capsule of VS is the perineurium of the vestibular nerve of origin: in large and giant VS frequently there is no arachnoid separating the tumor capsule from FN and cochlear nerve. (20)

According to Kohno et al. (20), there are 3 planes for possible tumor dissections: A. subarachnoid; B. subperineural (subcapsular); C. intracapsular. During the surgical removal of large VS, these Authors (20) suggest that bimanual dissection is an essential component of the technique and that it is necessary to take in account the tumor capsule and arachnoid reflection for obtaining the best functional results. (20,27,34,40,46)

Epiarachnoid tumors are defined by the absence of an arachnoid membrane on the tumor surface after moving the arachnoid fold (double layers of the arachnoid membrane) towards the brainstem. In contrast, subarachnoid VS maintain the arachnoid membrane on the tumor surface after moving the arachnoid fold. (34) Based on this hypothesis, Kohno et al. (20) used intraoperative views and light and electron microscopy to confirm the existence of an arachnoid membrane after the arachnoid fold had been moved: they observed VS are usually subarachnoid tumors, whereas epiarachnoid variant is considerably less common.

Extent of Removal of large VS and markers of tumor cells proliferation

Large tumor size often compromises safe and effective total resection; in the literature the rate of total resection of large VS ranges between 28,6% (61) and 95,5% 24); in two series total resection could be accomplished in all cases (43,47). Furthermore, factors that negatively affect results could associate, such as hypervascularity, which determines high-bleeding intraoperative rate and increased technical difficulties (23,49,56).

In our series of Koos IV HVVS, total or NT resection was accomplished in 23 cases (71,9%), versus 80,0% (20 cases) of hypovascular VS; these data are in line with other reported in the literature (17,18,44,61). In addition, tight adhesion of capsule to nervous structures was observed in 22 of our HVVS (68,7%) versus 14 (56,0%) low-bleeding VS (Table 2).

In order to limit bipolar coagulation and more heat thermal damage during HVVS microsurgical removal, we decide to use 2μ-Thulium flexible hand-held laser fiber, fot cutting, vaporizing, and coagulating the capsule and the intracapsular mass of the tumor, in combination with low-power bipolar forceps, microscissors and ultrasonic aspirator In a retrospective series on 78 consecutive cases (28), the use of 2μ-Thulium laser fiber in VS surgery proved to be safe, even if did not have significant influence on FN outcome, hearing preservation rate nor surgical time. On the other hand, the necessary reduction of tumor

volume of HVVS before microsurgical dissection of facial and cochlear nerve appears to be safer and easier with 2μ-Thulium laser fiber in association with ultrasonic aspirator and microsurgical dedicated instruments.

Antigen KI-67, tested with the MIB-1 index, is a nuclear protein that is associated with cellular proliferation. VS with MIB-1 index higher than 3% are actively proliferating with theoretical higher risk for regrowth or recurrence. (28) According to Teranashi et al (49), HVVS have a higher MIB-1 index: in their series, hypervascular VS had a mean MIB-1 of 4,3% versus 2,8% of non-hypervascular tumors (p<0,05). These data are not in accordance with those observed in our series, in which the mean MIB-1 index was 1,25% (range 1-3) in Group A and 1,08% (range 1-2) in Group B (p=NS).

Functional results

Hearing loss is one of the most common signs of VS at presentation (41,7% of cases) (2) and if socially useful hearing is present preoperatively, attempts should be made –when possible- to accomplish its preservation, especially in small-sized tumors. (12). As far as large and giant VS are concerned, in selected series hearing has been preserved in 21,4-50% (12,29,59,60) and 66,7% (43) of reported cases, respectively. In the present series, preoperative severely impaired hearing or deafness was present in all HVVS and in 23 cases (92,0%) of Group B; hearing preservation was not possible in the 2 AAO-HNS hearing Class B cases with low-bleeding VS.

Although great emphasis is currently placed on preserving FN function after VS resection, its injury still represents a relatively common postsurgical complication especially in large tumors. In addition, even if careful dissection is performed, an anatomically intact nerve does not necessarily predict a HBI FN function. According to the literature, preservation of FN functional state in VS surgery is accomplished in 32,9-83,3% of cases (15,17,24,43,47,58,61,62).

In our entire cohort, postoperative HBI-II outcome of FN was observed in 44 out of 57 patients (77,2%), T-NT resection was achieved in 75,4% of cases and 8 recurrences after ST removal were registered (2 re-operated, 2 treated with SRS, and 4 under observation). FN anatomical preservation was possible in 26 HVVS (81,2%) and in all low-bleeding tumors (p<0,05). Position and course of FN was statistically different too: it ran in anterior-superior (AS) position in 17 HVVS (48,6%) and in 8 low-bleeding tumors (32,0%) (p<0,05).

On considering long-term results, 20 HVVS (62,5%) had HBI-II FN result at last follow-up control versus 24 (96,0%) low-bleeding cases (p<0,01) (Table 3). Adhesions of tumor capsule to FN had a negative impact on FN outcome in Group A: HBI-II FN results were obtained only in 40,0% (8/20) of adherent HVVS versus 92,8% (13/14) of low-bleeding adherent tumors (p<0,05). It seems to be correct to underline one bias of the present study: any surgeon gains more experience during the years and therefore results could be better in later part of experience.

These lower HBI-II FN outcome in HVVS induced some surgeons to leave more residue. Zhang et al. (61) obtained the best functional outcome in patients who underwent subtotal resection instead of radical extirpation. Even if controversial results have been reported with planned less-than-total resection performed for FN preservation, according to some Authors (7,22,33,52,63) outcome might be improved in selected cases by combined surgical/radiosurgical treatment. Zumofen et al. (63) reported 89% HBI-II postoperative rate, with no need for salvage surgery after Gamma Knife on planned tumor residues. However, Iwai et al. (22) found that optimal FN outcome (95% postoperative HBI-II) could be jeopardized by the need for salvage surgery after Gamma Knife in case of large VS residues (at least 6cm^3). Notwithstanding, even if surgical removal should be attempted with the objective of maximal safe tumor eradication, such findings underline that SRS is not an enemy of microsurgery (52).

Complications and recurrences/re-growth of residue

In our series, mortality rate was zero and permanent complications (diplopia for abducens nerve paralysis) occurred only in one case of HVVS. Transient postoperative complications were observed in 8 patients (22,8%), without correlation with preoperative ASA class. As regard recurrence/re-growth of residue, at a follow-up ranging from 6 to 113 months, it was observed in 4 cases (3 ASA Class 2 and 1 Class 3): a re-operation was performed in 2 HVVS patients and SRS in other two (one patient ASA3 and one who refused second surgery).

These rates are in line with the literature (2,17,22,24,43,45,53,54,58,63) and confirm that retrosigmoid approach is safe and feasible to remove even giant VS (15,24,43,45,53,58). The translabyrynthine approach has been traditionally suggested for this kind of tumors, with good results in terms of extent of resection (rates of total resection around 90%), postoperative facial outcome (HBI-III close to 75%) and perioperative complications (CSF leaks in about 2% of cases) (6,11,25,61). On the other hand, other Authors reported perioperative complication rates as high as 14,3% (14). Even if translabyrinthyne approach is a feasible alternative, the results of our series contribute to support the use the retrosigmoid approach in large and HVVS too.

Surgical resection represents the ideal treatment for large and giant VS, including HVVS. It significantly and positively impacts on the patients' quality of life (54) and should be considered even in the case of elderly ones.

Conclusions

Compared to low-bleeding VS, microsurgery of Koos Grade IV HVVS seems to be associated with higher complication rate, higher recurrence/re-growth rate, and poorer FN outcome, especially in cases with tight capsule adhesion to the nerve.

Declarations

FUNDING STATEMENT

None (not applicable).

CONFLICT OF INTEREST

The authors declare that they have no known competing financial interests or personal relationships that could have appeared to influence the work reported in this paper.

AVAILABILITY OF DATA AND MATERIAL (Data Transparency)

Data available from the first Author on demand.

CODE AVAILABILITY

None (not applicable).

ETHICS APPROVAL

The study involves human participants: therefore, it has been reviewed and approved by local ethics committee of the Hospital. A written consent for scientific treatment of personal data was obtained from any patient before surgery. No potentially identifiable human images or data are presented in this study. All procedures performed in this study were in accordance with the ethical standards of the internal institutional ethics committee ("Comitato Etico Lazio 1" Members of ASLRoma1: Dr. Marco Tubaro, Dr. Teresa Calamia, Dr. Francesco Meo). A written consent was obtained from any patient included in the study.

Consent to participate and Consent for publication

All Co-Authors express formally their consent to participate to this study an to publish it, contributing in different ways.

Author's individual contributions

L.M.: study design, study conception, data extraction, data analysis, manuscript writing

A.C.: data extraction, data analysis

C.G.S.: data extraction, data analysis, radiological measurement

E.C.: data extraction, data analysis, radiological measurement

G.C.: data extraction, data analysis, statistical analysis,

R.R.: data analysis, statistical analysis, critical review of the manuscript

A.A.S.: critical review of the manuscript, study supervision

J.K.L.: critical review of the manuscript, study supervision

Data availability

The data associated with the paper are not publicly available but are available from the corresponding author on reasonable request.

References

1. Abe T, Izumiyama H, Imaizumi Y, et al. (2001) Staged resection of large hypervascular vestibular schwannomas in young adults. Skull Base 11(03):199-206
2. Boublata L, Belahreche M, Ouchtati R, et al. (2017) Facial Nerve Function and Quality of Resection in Large and Giant Vestibular Schwannomas Surgery Operated By Retrosigmoid Transmeatal Approach in Semi-sitting Position with Intraoperative Facial Nerve Monitoring. World Neurosurg 103:231-40
3. Campero A, Martins C, Rhoton A, Tatagiba M. (2011) Dural landmark to locate the internal auditory canal in large and giant vestibular schwannomas: the Tübingen line. Neurosurgery 69 (1 Suppl Operative): ons99-102
4. Carlson ML, Smadbeck JB, Link MJ, et al. (2018) Next Generation Sequencing of Sporadic Vestibular Schwannoma. Otology & Neurotology; 39(9):e860-e71
5. Caye-Thomasen P, Baandrup L, Jacobsen GK, et al. (2003) Immunohistochemical demonstration of vascular endothelial growth factor in vestibular schwannomas correlates to tumor growth rate. Laryngoscope 113(12):2129-34
6. Charpiot A, Tringali S, Zaouche S, et al. (2010) Perioperative complications after translabyrinthine removal of large or giant vestibular schwannoma: Outcomes for 123 patients. Acta Otolaryngol 130(11):1249-55
7. Chiluwal AK, Rothman A, Svrakic M, Dehdashti AR. (2018) Surgical outcome in smaller symptomatic vestibular schwannomas. Is there a role for surgery? Acta Neurochir (Wien) 160(11):2263-75
8. Committee on Hearing and Equilibrium Guidelines for the Evaluation of Hearing Preservation in Acoustic Neuroma (Vestibular Schwannoma): Committee on Hearing and Equilibrium. (1995) Otolaryngology–Head and Neck Surgery 113(3):179-80
9. Corrivetti F, Cacciotti G, Scavo CG, et al. (2018) Flexible Endoscopic-Assisted Microsurgical Radical Resection Of Intracanalicular Vestibular Schwannomas By Retrosigmoid Approach: Operative Technique. World Neurosurg 115: 229-233
10. Corrivetti F, Cacciotti G, Scavo CG, et al. (2019) Flexible endoscopic assistance in the surgical management of vestibular schwannomas. Neurosurgical Review doi: 10.1007/s10143-019-01195-0
11. Desgeorges M, Sterkers JM. (1984) [Surgery of large neurinomas of the acoustic nerve performed only by the translabyrinthine approach. Apropos of 50 cases]. Neurochirurgie 30(6):355-64
12. Di Maio S, Malebranche AD, Westerberg B, Akagami R. (2011) Hearing preservation after microsurgical resection of large vestibular schwannomas. Neurosurgery 68(3):632-40

13. Ferrara N, Gerber H-P, LeCouter J. (2003) The biology of VEGF and its receptors. Nature Medicine 9(6):669-76
14. Giordano AI, Domenech I, Torres A, et al. (2012) [Results in the surgical treatment of giant acoustic neuromas]. Acta Otorrinolaringol Esp 63(3):194-9
15. Hoshide R, Faulkner H, Teo M, Teo C. (2018) Keyhole retrosigmoid approach for large vestibular schwannomas: strategies to improve outcomes. Neurosurg Focus 44(3):E2
16. House JW, Brackmann DE. (1985) Facial nerve grading system. Otolaryngol Head Neck Surg 93(2):146-7
17. Huang X, Xu J, Xu M, et al. (2017) Functional outcome and complications after the microsurgical removal of giant vestibular schwannomas via the retrosigmoid approach: a retrospective review of 16-year experience in a single hospital. BMC Neurol 17(1):18
18. Huang X, Ji KY, Xu J, et al. (2016) [The surgical management of giant intracranial vestibular schwannoma via retrosigmoid approach: a retrospective review of 657 cases]. Zhonghua Er Bi Yan Hou Tou Jing Wai Ke Za Zhi 51(6):401-7
19. Kanzaki J, Tos M, Sanna M, Moffat DA. (2003) New and Modified Reporting Systems from the Consensus Meeting on Systems for Reporting Results in Vestibular Schwannoma. Otology & Neurotology 24(4):642-9
20. Kohno M, Sato H, Sora S, et al. (2011) Is an Acoustic Neuroma an Epiarachnoid or Subarachnoid Tumor? Neurosurgery 68(4):1006-17
21. Koos WT, Day JD, Matula C, Levy DI. (1998) Neurotopographic considerations in the microsurgical treatment of small acoustic neurinomas. Journal of Neurosurgery 88(3):506-12
22. Iwai Y, Ishibashi K, Watanabe Y, et al. (2015) Functional Preservation After Planned Partial Resection Followed by Gamma Knife Radiosurgery for Large Vestibular Schwannomas. World Neurosurg 84(2):292-300
23. Le May DR, Sun JK, Fishback D, Locke GE, Giannotta SL. (1998) Hypervascular acoustic neuroma. Neurol Res 20(8): 748-50
24. Li JM, Yuan XR, Liu Q, et al. (2011) [Facial nerve preservation following microsurgical removal of large and huge acoustic neuroma]. Zhonghua Wai Ke Za Zhi 49(3):240-4
25. Mamikoglu B, Wiet RJ, Esquivel CR. (2002) Translabyrinthine approach for the management of large and giant vestibular schwannomas. Otol Neurotol 23(2):224-7
26. Mastronardi L, Cacciotti G, Roperto R, et al. (2016) Position and Course of Facial Nerve and Postoperative Facial Nerve Results in Vestibular Schwannoma Microsurgery. World Neurosurgery 94:174-80
27. Mastronardi L, Fukushima T, Campione A. (2019) Advances in Vestibular Schwannoma Microneurosurgery. 1 ed. Cham, Switzerland: Springer International Publishing; p.174
28. Mastronardi L, Cacciotti G, Roperto R, Giacobbo Scavo C, Stati G. (2019) Microsurgical removal of vestibular schwannomas with flexible hand held 2μ- Thulium-fiber laser. Personal experience in 78

consecutive cases. Interdisciplinary Neurosurgery 16:82-86

29. Mendelsohn D, Westerberg BD, Dong C, Akagami R. (2016) Clinical and Radiographic Factors Predicting Hearing Preservation Rates in Large Vestibular Schwannomas. J Neurol Surg B Skull Base 77(3):193-8
30. Menke H, Klein A, John KD, Junginger T. (1993) Predictive value of ASA classification for the assessment of the perioperative risk. Int Surg 78(3):266-70.
31. Møller MN, Werther K, Nalla A, et al. (2010) Angiogenesis in vestibular schwannomas: Expression of extracellular matrix factors MMP-2, MMP-9, and TIMP-1. The Laryngoscope 120(4):657-62
32. Mom T, Gabrillargues J, Gilain L, Chazal J, Kemeny JL, Vanneuville G. (2002) Anatomy of the vestibulo-acoustico-facial neurovascular pedicle. Importance of therapeutic management of vestibular schwannomas. Neurochirurgie 48(5):387-397
33. Nutik SL. (1994) Facial nerve outcome after acoustic neuroma surgery. Surg Neurol 41(1):28-33
34. Ohata K, Tsuyuguchi N, Morino M, et al. (2002) A hypothesis of epiarachnoidal growth of vestibular schwannoma at the cerebello-pontine angle: surgical importance. J Postgrad Med 48(4):253-258
35. Peris-Celda M, Graffeo CS, Perry A, et al. (2019) Main Symptom that Led to Medical Evaluation and Diagnosis of Vestibular Schwannoma and Patient-Reported Tumor Size: Cross-sectional Study in 1,304 Patients. Journal of neurological surgery Part B, Skull Base 80(3):316-22
36. Plotkin SR, Stemmer-Rachamimov AO, Barker FG, 2nd, et al. (2009) Hearing improvement after bevacizumab in patients with neurofibromatosis type 2. N Engl J Med 361(4):358-67
37. Prueter J, Norvell D, Backous D. (2019) Ki-67 index as a predictor of vestibular schwannoma regrowth or recurrence. J Laryngol Otol 133:205-207
38. Reznitsky M, Petersen MMBS, West N, et al. (2019) Epidemiology Of Vestibular Schwannomas - Prospective 40-Year Data From An Unselected National Cohort. Clin Epidemiol;11:981-986
39. Roberti F, Sekhar LN, Kalavakonda C, Wright DC. (2001) Posterior fossa meningiomas: surgical experience in 161 cases. Surg Neurol 56(1):8-20
40. Roosli C, Linthicum FH, Jr., Cureoglu S, Merchant SN. (2012) What is the site of origin of cochleovestibular schwannomas? Audiol Neurootol 17(2):121-5
41. Sameshima T, Morita A, Tanikawa R, et al. (2013) Evaluation of variation in the course of the facial nerve, nerve adhesion to tumors, and postoperative facial palsy in acoustic neuroma. J Neurol Surg B Skull Base 74(1):39-43.
42. Sameshima T. (2007) Fukushima's Microanatomy and Dissection of The Temporal Bone. Second ed. Sameshima T, editor. Raleigh, USA: AF-Neurovideo, Inc., p. 115
43. Samii M, Gerganov VM, Samii A. (2010) Functional outcome after complete surgical removal of giant vestibular schwannomas. J Neurosurg 112(4):860-7
44. Samprón N, Altuna X, Armendáriz M, Urculo E. (2014) [Treatment of giant acoustic neuromas]. Neurocirugia (Astur) 25(6):247

45. Sanna M, Agarwal M, Mancini F, Taibah A. (2004) Transapical extension in difficult cerebellopontine angle tumors. Ann Otol Rhinol Laryngol 113(8):676-82
46. Sasaki T, Shono T, Hashiguchi K, et al. (2009) Histological considerations of the cleavage plane for preservation of facial and cochlear nerve functions in vestibular schwannoma surgery. Journal of Neurosurgery 110(4):648-55
47. Silva J, Cerejo A, Duarte F, et al. (2012) Surgical removal of giant acoustic neuromas. World Neurosurg 77(5-6):731-5
48. Stangerup SE, Tos M, Caye-Thomasen P, et al. (2004) Increasing annual incidence of vestibular schwannoma and age at diagnosis. J Laryngol Otol 118(8):622-7
49. Teranishi Y, Kohno M, Sora S, Sato H, Nagata O. (2018) Hypervascular Vestibular Schwannomas: Clinical Characteristics, Angiographical Classification, and Surgical Considerations. Oper Neurosurg 15(3): 251-261
50. Tos M, Stangerup SE, Cayé-Thomasen P, et al. (2004) What is the real incidence of vestibular schwannoma? Arch Otolaryngol Head Neck Surg 130(2):216-20
51. Tos M, Thomsen J, Charabi S. (1992) Incidence of acoustic neuromas. Ear Nose Throat J 71(9):391-3
52. Troude L, Boucekine M, Montava M, et al. (2019) Predictive Factors of Early Postoperative and Long-Term Facial Nerve Function After Large Vestibular Schwannoma Surgery. World Neurosurg 127:e599-e608
53. Turel MK, D'Souza WP, Chacko AG, Rajshekhar V. (2016) Giant vestibular schwannomas: Surgical nuances influencing outcome in 179 patients. Neurol India 64(3):478-84
54. Turel MK, Thakar S, Rajshekhar V. (2015) Quality of life following surgery for large and giant vestibular schwannomas: a prospective study. J Neurosurg 122(2):303-11
55. Uesaka T, Shon o T, Suzuki SO, et al. (2007) Expression of VEGF and its receptor genes in intracranial schwannomas. Journal of Neuro-Oncology 83(3):259-66
56. Yamakami I, Kobayashi E, Iwadate Y, Saeki N, Yamaura A. (2002) Hypervascular vestibular schwannomas. Surg Neurol 57(2):105-12
57. Yang P, Sun D, Jiang F. (2018) Ailanthone Promotes Human Vestibular Schwannoma Cell Apoptosis and Autophagy by Downregulation of miR-21. Oncology Research Featuring Preclinical and Clinical Cancer Therapeutics 26(6):941-8
58. Yang X, Zhang Y, Liu X, Ren Y. (2014) [Microsurgical treatment and facial nerve preservation in 400 cases of giant acoustic neuromas]. Zhongguo Xiu Fu Chong Jian Wai Ke Za Zhi 28(1):79-84
59. Wanibuchi M, Fukushima T, Friedman AH, et al. (2014) Hearing preservation surgery for vestibular schwannomas via the retrosigmoid transmeatal approach: surgical tips. Neurosurg Rev 37(3):431-44
60. Wanibuchi M, Fukushima T, McElveen JT, Friedman AH. (2009) Hearing preservation in surgery for large vestibular schwannomas. J Neurosurg 111(4):845-54

61. Zhang S, Liu W, Hui X, You C. (2016) Surgical Treatment of Giant Vestibular Schwannomas: Facial Nerve Outcome and Tumor Control. World Neurosurg 94:137-44
62. Zou P, Zhao L, Chen P, et al. (2014) Functional outcome and postoperative complications after the microsurgical removal of large vestibular schwannomas via the retrosigmoid approach: a meta-analysis. Neurosurg Rev 37(1):15-21
63. Zumofen DW, Guffi T, Epple C, et al. (2018) Intended Near-Total Removal of Koos Grade IV Vestibular Schwannomas: Reconsidering the Treatment Paradigm. Neurosurgery 82(2):202-10

Figures

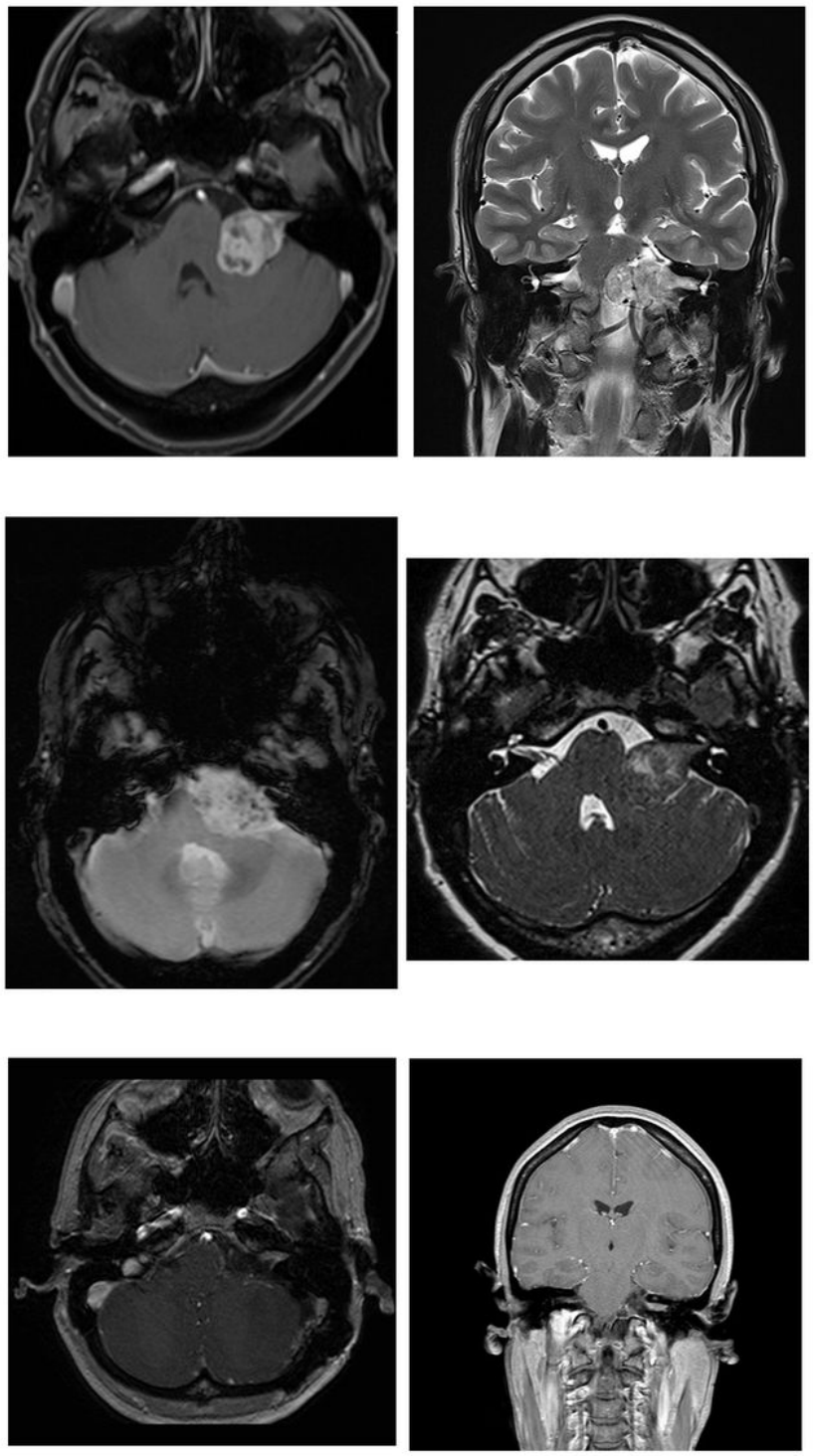

Figure 1

Preoperative and postoperative MR images of a 43y.o. lady with left Koos IV HVVS: near-total resection, without any neurological deficit (HBI FN result), except left hearing loss (preoperative AAO-HNS Class C). A. Axial slice of preoperative MRI-T1Gd showing vestibular schwannoma Koos IV on the left side. B. Coronal slice of MRI-T2, showing several serpiginous vessels inside the mass. C. Axial slice of MRI-T2 showing multiple black-spots, representing sections of intratumoral vessels. D. Axial slice of MRI-T2 3D,

showing an inhomogeneos tumor, with multiple spots inside, especially close to the interface with brainstem. E. Axial slice of postoperative MRI-T1Gd showing (residual tumor in the internal auditory canal). F. Coronal slice of postoperative MRI-T1Gd.