Failure of Internal Fixation of The Anterior Ring For Unstable Pelvic Fractures, The Experience of A Single Institute

Sheng Zhang (13233080@qq.com)
Southern Medical University Nanfang Hospital
Huagui Mo
Jiangmen Central Hospital
Yucheng Liu
Southern Medical University Nanfang Hospital
Guohua Zhu
Huazhou People's Hospital
Bin Yu
Southern Medical University Nanfang Hospital

Research Article

Keywords: pelvic fracture, anterior ring, failure

Posted Date: May 24th, 2021

DOI: https://doi.org/10.21203/rs.3.rs-519179/v1

Abstract

Background: This study aimed to share our experience of anterior ring fixation failure for unstable pelvic fractures and propose corresponding treatment strategies.

Materials: From January 2009 to December 2018, 93 patients with pelvic fractures were retrospectively reviewed. Patients with failure of the anterior ring internal fixation within 3 months after initial surgery were analyzed. Quality of reduction was evaluated using the Majeed scoring system.

Results: According to the Tile classification of fracture, there were 23 cases of type B1, 17 cases of type B2, 11 cases of type B3, 28 cases of type C1, 6 cases of type C2, and 8 cases of type C3. The duration from injury to pelvic internal fixation ranged from 5-28 days. Seven out of 93 patients experienced failure of internal fixation of the anterior pelvic ring within 3 months, including 2 patients fixed with an external fixator and 5 patients were fixed with a plate. Five patients undergoing revision surgery were followed up for 6-36 months with an average of 18 months. According to Majeedscore at the last follow-up, there were 2 cases of excellent, 2 cases of good, 1 case of fair, and the excellent and good rate reached 80%.

Conclusion: The treatment of complicated unstable pelvic fractures requires early multidisciplinary cooperation, proper management of hemodynamic stability and other comorbidities, and performing internal fixation surgery within 2 weeks. It is necessary to make a preoperative plan and stabilize the posterior ring first, avoiding a single steel plate crossing the pubic symphysis.

Background

Pelvis Fracture is a serious injury with a mortality rate of 10–16% and comprises about 2–8% of all fractures [1, 2]. Unstable pelvic fractures are often caused by high-energy force, such as road traffic accidents, falls from height, and localized crush injuries [3], and may result in uncontrolled hemorrhage leading to a higher rate of morbidity [4]. The initial treatment of unstable fractures includes managing the hemorrhage and the injured organs, blood vessels, and nerves [5]. It has become a consensus that surgical intervention is required for the treatment of unstable pelvic fractures [6–9]. Surgical intervention may be isolated posterior or combined posterior and anterior surgical fixation using screws and plates to achieve anatomical reduction and natural healing of the unstable pelvic fractures [10, 11].

Pelvic fractures are typically extra-articular fractures, which reduction requirements are not as high as intra-articular ones. In recent years, with the promotion of the concept of the AO (Arbeitsgemeinschaft für Osteosynthesefragen) principles of fracture management [12] and the development of 3D technology [13], many primary hospitals can perform the operation for pelvic fractures. However, due to the long learning curve of pelvic fracture surgery, some patients experienced internal fixation failure [14, 15] and secondary fracture displacement [16] after the initial surgery. Moreover, limited by the equipment and technology of the primary hospital, in case of the difficult reduction or massive perioperative bleeding, the surgeon may rush to complete the fixation step, which further increases the probability of failure of the internal fixation after the operation.

At present, the studies on the causes of failure of internal fixation for unstable pelvic fractures are extremely rare. From January 2009 to December 2018, 93 patients with unstable pelvic fractures received internal fixation in our hospital, of which 7 patients experienced postoperative internal fixation failure. The purpose of this study was to share our experience of anterior pelvic ring fixation failure for unstable pelvic fractures and propose the corresponding treatment strategies.

Materials

Study subjects

Patients with pelvic fractures treated in our hospital from January 2009 to December 2018 were retrospectively reviewed. The inclusion criteria were: 1) 18 years of age or older; 2) unstable pelvic fractures with a displacement greater than 1 cm; 3) type B and type C pelvic fractures (the Tile classification); 4) hemodynamically stable within 2 weeks after admission; 5) combined injury of other organs that did not affect the operation; 6) without important neurovascular damage. The exclusion criteria included: 1) pathological fracture, or combined with pelvic bone tumor or severe osteoporosis; 2) combined with femoral fracture and thoracolumbar fracture; 3) open pelvic fracture; 4) Morel-Lavallée injury; 5) combined with a complicated acetabular fracture. Finally, 93 eligible patients with pelvic fractures were included for analysis. This study was approved by the Ethics Committee of xxx Hospital, and informed patient consent was obtained from each patient.

Surgical methods

The methods for fixation of the anterior pelvic ring included 5 cases of external frame fixation, and 10 cases of anterior column screw fixation, and internal fixation of steel plate (conducted in the other remaining patients). The surgical incisions used were the Stoppa approach and the iliac-groin approach.

The methods for fixation of the posterior pelvic ring were steel plate (n=23), sacroiliac joint screw fixation (n=40), and 1 case of lumbar iliac fixation.

Data collection and definition

All patients were followed up for 3 months postoperatively. Patients with failure of the anterior ring internal fixation within 3 months after initial surgery were analyzed. The causes of injury, fracture type, operation timing, fixation sequence, internal fixation plan, operation time, intraoperative blood loss were collected.

Quality of reduction was evaluated using the Majeed scoring system[17]. On the x-ray film, the quality of the reduction of the anterior pelvic ring injury was evaluated. The fracture separation displacement of <4 mm was defined as excellent, of 4-10 mm was good, of 11-20 mm was fair, and of >20 mm was poor. This study only analyzed the reasons for the failure of internal fixation, and other issues, such as neurovascular injury, spermatic cord injury, and sexual function are not compared and analyzed here.

Results

Demographic and clinical characteristics of the 93 included patients

A total of 93 patients (66 males and 27 females, mean age = 46 ± 9.3 years: range 15 to 59) were included for analysis. The causes of injury included falls from height (n = 32 cases, 34.40%), car accidents (n = 47 cases, 50.53%), and injured by heavy objects (n = 14 cases, 15.05%). According to the Tile classification of fracture, there were 23 cases of type B1, 17 cases of type B2, 11 cases of type B3, 28 cases of type C1, 6 cases of type C2, and 8 cases of type C3. The duration from injury to pelvic internal fixation ranged from 5–28 days.

Sixteen patients combined with hemodynamic instability. Among them, 14 patients were hemodynamically stable after emergency fluid transfusion and using a pelvic girdle, and 9 patients received anterior ring fixation by external frame. Five patients combined with liver and spleen injury. After emergency surgery, they were hemodynamically stable within 2 weeks after surgical ICU treatment.

Twenty-two patients with multiple fractures at other anatomical sites were staged, treated, and fixed according to the Damage control orthopedics (DCO) surgical strategy [18]. Another 9 patients combined with rib fractures received conservative treatment. Ten patients with traumatic wet lung were treated with supportive antibiotics and their lung function recovered within 2 weeks. The injury severity score (ISS) score [19] was greater than 16 in 15 patients.

Clinical characteristics of patients with failure of internal fixation of anterior pelvic ring

A total of 7 patients experienced failure of internal fixation of the anterior pelvic ring within 3 months after the initial surgery. Clinical characteristics and surgical outcomes of the 7 patients were summarized in Table 1. According to the Tile classification of fracture, 2 cases were type B3, 3 cases were type C1, 1 case was type C2 (Fig. 1), and 1 case was type C3.

Table 1
Clinical characteristics and surgical outcomes of the patients

No.	Sex/age	Cause of injury	Fracture type	Combined with other organ injury	Surgical timing (days after injury)	First Internal fixation	Internal fixation method - anterior ring	Internal fixation method - posterior ring	Surgical duration (min)	Intraoperative blood loss (mL)	Quality of reduction of initial surgery (Majeed scoring system)
1	M/37	Car accident	B3	Yes	8	anterior ring	External frame	SI screw	121	3466	moderate
2	F/42	Car accident	B3	No	6	posterior ring	External frame	steel plate	143	511	good
3	M/33	Car accident	C1	No	4	posterior ring	steel plate	steel plate	245	1513	moderate
4	M/56	Fall from height	C1	Yes	10	posterior ring	steel plate	SI screw	135	927	good
5	M/43	Fall from height	C2	No	14	anterior ring	steel plate	steel plate	207	2330	moderate
6	F/29	Car accident	C3	Yes	15	posterior ring	steel plate	steel plate	263	1789	good
7	M/55	Car accident	C1	Yes	10	anterior ring	steel plate	SI screw	142	1392	moderate

Of them, the anterior pelvic ring was fixed with an external frame and a steel plate in 2 and 5 cases, respectively. In the 2 patients with an external frame, the fixation failure was due to the loosening of the Schanz's nail. The mean time from operation to fixation failure was 2.3 months. Of the 5 cases with internal fixation of steel plate, 4 cases failed within 2 weeks after the operation, and the other 2 cases failed at 4 weeks and 5 weeks after the operation, respectively.

Four out of the 7 patients had multiple injuries, including 1cases of traumatic brain injury, 2 cases of chest and abdomen trauma, and 1 case of urinary system injury. Four out of the 7 patients had multiple fractures, including 2 cases of femoral shaft fractures, 1 case of scapula fractures, and 1 case of fractures in more than 3 body parts.

The mean intraoperative blood loss of 5 patients with plate internal fixation was 1580 mL (range: 900–2300 mL). The mean surgical duration of all 7 patients was 178.6 min (range: 120–260 min). Quality of reduction based on the Majeed scoring system were 3 cases of good and 4 cases of moderate.

Revision surgery outcomes

Of the 7 cases of internal fixation failure, 5 patients underwent revision surgery, while two cases voluntarily gave up revision after malunion of the pelvic fracture.

The 5 revision cases were followed up for 6-36 months, with an average of 18 months. According to Majeed score at the last follow-up, there were 2 cases of excellent, 2 cases of good, 1 case of fair, and the excellent and good rate reached 80%.

Selective case presentation

Case 7 (in Table 1) had a medical history of blood transfusion in another hospital before surgery, and the emergency exploratory laparotomy at admission found a large retroperitoneal hematoma. After stable condition in the surgical ICU, the patient received internal fixation surgery 10 days after injury. The intraoperative hemorrhage was rapid. After reduction and fixation, the patient's blood pressure became unstable. After closing the abdominal cavity, the patient was transferred to the surgical ICU for further monitoring and treatment.

The patient was transferred to the general ward 5 days after surgery. X-ray examination indicated the failure of the internal fixation. A second revision operation was performed 111 days after the operation. The long steel plate was replaced via the Stoppa approach and then the fixation was stable until healed.

Discussion

In our study, the patients were mostly males (70.97%) and were aged between 19–59 years old (%). Fifty-three percent of the male patients were involved in road traffic accidents, including 36 males and 13 females. This demographic trend is similar to previous studies done in the United States and Singapore [1, 20, 21].

Bleeding from pelvic fractures is mainly originated from the surfaces of the fractured section, arteries, veins, and vascular plexus, or the main trunk or branches of iliac vessels [22, 23]. At an early stage of complicated pelvic fractures, maintaining hemodynamic stability is the primary task, especially for those with multiple organ injuries. Improper early management will delay the operation timing, increasing the risk of internal fixation failure, and even death. Up to 22% of all patients with pelvic fractures have unstable hemodynamics, thereby treatment for unstable pelvic fractures requires a multidisciplinary consultation and treatment [24, 25]. Once the patient is diagnosed with hemodynamic instability, the pelvis should be fixed by a pelvic girdle or external fixation frame. If the patient has an open fracture or other important organ injuries, vascular embolization or pelvic tamponade could be considered [26, 27]. It has been suggested that open reduction and internal fixation within 21 days after the injury is associated with higher rates of excellent reductions and better long-term outcomes [28]. However, 2 weeks after the injury, the patient is prone to develop pelvic adhesions, which increases the risk of intraoperative bleeding and the difficulty of reduction [29, 30]. Therefore, the optimal time window of open reduction and internal fixation for pelvic fracture should be within 2 weeks after injury. In this study. 2 patients (Case 5, Case 6) combined with rectal urethra rupture, abdominal hemorrhage, and hemodynamic instability. Due to a lack of close multidisciplinary cooperation in the early period in the surgical ICU, open reduction and internal fixation was performed at 14 or 15 days after injury, exceeding the optimal surgical timing. Due to the excessive intraoperative bleeding and subsequent rush of reduction, the internal fixation eventually failed.

Although the reduction requirements for pelvic fractures are not as high as those for acetabular fractures, satisfactory reduction quality can effectively reduce the failure rate of internal fixation and postoperative patient satisfaction. The learning curve for surgical management of pelvic fractures is relatively long. According to our experience of internal fixation failure in this study, some surgical technical points are proposed. First, CT examination is recommended for all pelvic fractures, 3D reconstruction or 3D printing could be conducted, which can help to understand the degree of fracture displacement, and to formulate detailed surgical plans. Especially for patients with head injury or receiving surgery more than 1 month after the injury, the fracture has become scarred or with bone callus, making intraoperative dissection difficult, and prolonged reduction time. If there is no clear preoperative plan, the intraoperative risk may increase [31, 32]. Secondly, the surgeon must be familiars with various surgical techniques and approaches. Commonly used anterior approaches are iliac-groin approach and Stoppa approach, and posterior iliac lumbar fixation, SI screws, and M steed plates can be used. Thirdly, the stability of the pelvic ring depends on the complete reconstruction of the anterior and posterior rings, especially the integrity of the posterior sacroiliac complex. Because the reduction of the anterior ring is relatively easy, most surgeons perform the reduction of the anterior ring first and then fix the posterior ring with sacroiliac joint screws or iliac lumbar fixation. However, if the rotation or vertical displacement of the posterior ring is not corrected when the anterior ring is fixed, the stress of the steel plate on the anterior ring will increase, eventually leading to internal fixation failure. Therefore, when the anterior ring and the posterior ring are both unstable, especially in the case of large displacement, it is necessary to use lower limb traction to correct the vertical displacement [33] or use C-clamps to correct the posterior ring rotation displacement [34], which can effectively reduce the risk of internal fixation failure.

These are also some instrument-related notes to avoid fixation failure for the unstable anterior ring. First, if the patient has a pubic symphysis separation instead of a pubic ramus fracture, a longer healing time and more stable fixation are required. Due to insufficient stability and an effective fixation time of fewer than 3 months, the external fixation is not recommended for patients with an unstable anterior ring, especially for patients with pubic symphysis separation and unstable vertical rotation. Internal fixation with a steel plate is preferred [35]. When the anterior ring is fixed with a steel plate, the screws often need to change the direction or shorten the length to avoid the joint surface, thereby reducing the strength of the internal fixation. Furthermore, due to the elasticity, when crossing the pubic symphysis, the pelvic steel plate needs to be better shaped and pre-bent to reduce the risk of internal fixation failure. In the case of an unstable posterior ring and the anterior ring involving the pubic symphysis, sacroiliac screws are used to fix the posterior ring, the requirement for the stability of the anterior ring is high. The steel plate should be placed above the top of the contralateral acetabulum to avoid screws pull-out. Near the pubic symphysis, long screws are recommended to be used to penetrate the two layers of the cortex.

There are still some limitations to this study. First, the sample size of internal fixation failure was too small, thereby we cannot conduct multivariate regression analysis to predict the independent risk factors for internal fixation failure of unstable pelvic fractures. In addition, this study was limited by its retrospective nature. A large prospective trial should be conducted to validate the findings of this study.

Conclusions

In summary, the treatment of complicated unstable pelvic fractures requires early multidisciplinary cooperation, proper management of hemodynamic stability and other comorbidities, and performing internal fixation surgery within 2 weeks. It is necessary to make a preoperative plan and stabilize the posterior ring first, avoiding a single steel plate crossing the pubic symphysis. Ensuring the above issue can effectively minimize the probability of failure of the internal fixation.

Abbreviations

DCO: Damage control orthopedics; ISS: injury severity score

Declarations

Ethics approval and consent to participate

This study was approved by the Ethics Committee of Huazhou People's Hospital, and informed patient consent was obtained from each patient.

Consent for publication

Informed patient consent was obtained from each patient for the publication of this study.

Availability of data and materials

All data generated or analysed during this study are included in this published article .

Competing interests

The authors declare that they have no competing interests.

Funding

None declared.

Authors' contributions

We declare that all the listed authors have participated actively in the study and all meet the requirements of the authorship. Dr. Sheng Zhang designed the study and wrote the protocol, Drs. Sheng Zhang, Huagui Mo and Yucheng Liu acquired the data of manuscript, Drs. Sheng Zhang, Guohua Zhu and Bin Yu analyzed the data, Drs. Sheng Zhang wrote the first draft of the manuscript and mainly revised the manuscript. All authors approved the final version of the manuscript.

Acknowledgements

None declared.

References

[1] Grotz, M. R. W., Allami, M. K., Harwood, P., Pape, H. C., Krettek, C., Giannoudis, P. V., (2005) Open Pelvic Fractures: Epidemiology, Current Concepts of Management and Outcome. Injury, 36(1): p. 1–13.

[2] Mohanty, K., Musso, D., Powell, J. N., Kortbeek, J. B., Kirkpatrick, A. W., (2005) Emergent Management of Pelvic Ring Injuries: An Update. Can J Surg, 48(1): p. 49–56.

[3] Schmal, H., Markmiller, M., Mehlhorn, A. T., Sudkamp, N. P., (2005) Epidemiology and Outcome of Complex Pelvic Injury. Acta Orthop Belg, 71(1): p. 41–47.

[4] White, C. E., Hsu, J. R., Holcomb, J. B., (2009) Haemodynamically Unstable Pelvic Fractures. Injury, 40(10): p. 1023–1030.

[5] Portela, R., (2019) Outcome of Unstable Pelvic Fractures after Internal Fixation: Our Experience. Ann Orthop Musculoskelet Disord, 2(1): p. 1023.

[6] Müller, F. J., Stosiek, W., Zellner, M., Neugebauer, R., Füchtmeier, B., (2013) The Anterior Subcutaneous Internal Fixator (ASIF) for Unstable Pelvic Ring Fractures. Clinical and Radiological Mid-Term Results. Int Orthop, 37(11): p. 2239–2245.

[7] Ochenjele, G., Reid, K. R., Castillo, R. C., Schoonover, C. D., Montalvo, R. N., Manson, T. T., Sciadini, M. F., Nascone, J. W., Carlini, A. R., O'Toole, R. V., (2018) Predictors of Unplanned Reoperation after Operative Treatment of Pelvic Ring Injuries Journal of Orthopaedic Trauma, p. E245–E250.

[8] Bott, A., Odutola, A., Halliday, R., Acharya, M. R., Ward, A., Chesser, T. J. S., (2019) Long-Term Patient-Reported Functional Outcome of Polytraumatized Patients with Operatively Treated Pelvic Fractures. J Orthop Trauma, 33(2): p. 64–70.

[9] Morshed, S., Choo, K., Kandemir, U., Kaiser, S. P., (2015) Internal Fixation of Posterior Pelvic Ring Injuries Using Iliosacral Screws in the Dysmorphic Upper Sacrum. JBJS Essent Surg Tech., 5(1): p. e3.

[10] Lindahl, J., Hirvensalo, E., Böstman, O., Santavirta, S., (1999) Failure of Reduction with an External Fixator in the Management of Injuries of the Pelvic Ring. Long-Term Evaluation of 110 Patients. J Bone Jt Surg - Ser B, 81(6): p. 955–962.

[11] Xu, R., Ebraheim, N. A., Robke, J., Yeasting, R. A., (1996) Radiologic Evaluation of Iliosacral Screw Placement. Spine (Phila. Pa. 1976), 21(5): p. 582–588.

[12] Helfet, D. L., Haas, N. P., Schatzker, J., Matter, P., Moser, R., Hanson, B., (2003) AO Philosophy and Principles of Fracture Management - Its Evolution and Evaluation. J Bone Jt Surg - Ser A, 85(6): p. 1156–1160.

[13] Thakkar, S. C., Thakkar, R. S., Sirisreetreerux, N., Carrino, J. A., Shafiq, B., Hasenboehler, E. A., (2017) 2D versus 3D Fluoroscopy-Based Navigation in Posterior Pelvic Fixation: Review of the Literature on Current Technology. Int J Comput Assist Radiol Surg, 12(1): p. 69–76.

[14] Eastman, J. G., Krieg, J. C., Routt, M. L. C., (2016) Early Failure of Symphysis Pubis Plating. Injury, 47(8): p. 1707–1712.

[15] Moed, B. R., Grimshaw, C. S., Segina, D. N., (2012) Failure of Locked Design-Specific Plate Fixation of the Pubic Symphysis: A Report of Six Cases. J Orthop Trauma, 26(7): p. e71–e75.

[16] Osterhoff, G., Ossendorf, C., Wanner, G. A., Simmen, H. P., Werner, C. M. L., (2011) Posterior Screw Fixation in Rotationally Unstable Pelvic Ring Injuries. Injury, 42(10): p. 992–996.

[17] Majeed, S. A., (1989) Grading the Outcome of Pelvic Fractures. J Bone Jt Surg - Ser B, 71(2): p. 304–306.

[18] Guerado, E., Bertrand, M. L., Cano, J. R., Cerván, A. M., Galán, A., (2019) Damage Control Orthopaedics: State of the Art. World J Orthop, 10(1): p. 1–13.

[19] Baker, S. P., O'Neill, B., Haddon, W., Long, W. B., (1974) The Injury Severity Score: A Method for Describing Patients with Multiple Injuries and Evaluating Emergency Care. J. Trauma, 14(3): p. 187–196.

[20] Deakin, D. E., Boulton, C., Moran, C. G., (2007) Mortality and Causes of Death among Patients with Isolated Limb and Pelvic Fractures. Injury, 38(3): p. 312–317.

[21] Ooi, C. K., Goh, H. K., Tay, S. Y., Phua, D. H., (2010) Patients with Pelvic Fracture: What Factors Are Associated with Mortality? Int J Emerg Med, 3(4): p. 299–304.

[22] Tötterman, A., Dormagen, J., Madsen, J., Kløw, N. E., Skaga, N., and Røise, O., (2006) A Protocol for Angiographic Embolization in Exsanguinating Pelvic Trauma: A Report on 31 Patients. Acta Orthop, 77(3): p. 462–468.

[23] Kataoka, Y., Maekawa, K., Nishimaki, H., Yamamoto, S., Soma, K., Scholten, D. J., Shackford, S. R., Poggetti, R. S., Wisner, D. H., Ivatury, R., (2005) Iliac Vein Injuries in Hemodynamically Unstable Patients with Pelvic Fracture Caused by Blunt Trauma. J Trauma - Inj Infect Crit Care, 58(4): p. 704–710.

[24] Wong, J. M. L., Bucknill, A., (2017) Fractures of the Pelvic Ring. Injury, 48(4): p. 795–802.

[25] Hauschild, O., Strohm, P. C., Culemann, U., Pohlemann, T., Suedkamp, N. P., Koestler, W., Schmal, H., (2008) Mortality in Patients with Pelvic Fractures: Results from the German Pelvic Injury Register. J Trauma - Inj Infect Crit Care, 64(2): p. 449–455.

[26] Toth, L., King, K. L., McGrath, B., Balogh, Z. J., (2014) Factors Associated with Pelvic Fracture-Related Arterial Bleeding during Trauma Resuscitation: A Prospective Clinical Study. Journal of Orthopaedic Trauma, p. 489–495.

[27] Incagnoli, P., Puidupin, A., Ausset, S., Beregi, J. P., Bessereau, J., Bobbia, X., Brun, J., Brunel, E., Buléon, C., Choukroun, J., Combes, X., David, J. S., Desfemmes, F. R., Garrigue, D., Hanouz, J. L., Plénier, I., Rongieras, F., Vivien, B., Gauss, T., Harrois, A., Bouzat, P., Kipnis, E., (2019) Early Management of Severe Pelvic Injury (First 24 Hours). Anaesth Crit Care Pain Med, 38(2): p. 199–207.

[28] Matta, J. M., Tornetta, P., (1996) Internal Fixation of Unstable Pelvic Ring Injuries. Clinical Orthopaedics and Related Research, p. 129–140.

[29] Vallier Heather, A., Super Dennis, M., Moore Timothy, A., Wilber John, H., (2013) Do Patients with Multiple System Injury Benefit from Early Fixation of Unstable Axial Fractures? The Effects of Timing of Surgery on Initial Hospital Course. J Orthop Trauma 27(7): p. 405–412.

[30] Benjamin, E., Aiolfi, A., Recinos, G., Inaba, K., Demetriades, D., (2019) Timing of Venous Thromboprophylaxis in Isolated Severe Pelvic Fracture: Effect on Mortality and Outcomes. Injury, 50(3): p. 697–702.

[31] Cai, L., Zhang, Y., Chen, C., Lou, Y., Guo, X., Wang, J., (2018) 3D Printing-Based Minimally Invasive Cannulated Screw Treatment of Unstable Pelvic Fracture. J Orthop Surg Res, 13(1): p. 71.

[32] Hung, C. C., Li, Y. T., Chou, Y. C., Chen, J. E., Wu, C. C., Shen, H. C., Yeh, T. Te, (2019) Conventional Plate Fixation Method versus Pre-Operative Virtual Simulation and Three-Dimensional Printing-Assisted Contoured Plate Fixation Method in the Treatment of Anterior Pelvic Ring Fracture. Int Orthop, 43(2): p. 425–431.

[33] Thaunat, M., Laude, F., Paillard, P., Saillant, G., and Catonné, Y., (2008) Transcondylar Traction as a Closed Reduction Technique in Vertically Unstable Pelvic Ring Disruption. Int Orthop, 32(1): p. 7–12.

[34] Wiznia, D. H., Swami, N., Kim, C.-Y., and Leslie, M. P., (2016) A Method of Using a Pelvic C-Clamp for Intraoperative Reduction of a Zone 3 Sacral Fracture. Case Rep Orthop, 2016: p. 1–5.

[35] Toth, L., King, K. L., McGrath, B., and Balogh, Z. J., (2012) Efficacy and Safety of Emergency Non-Invasive Pelvic Ring Stabilisation. Injury, 43(8): p. 1330–1334.

Figures

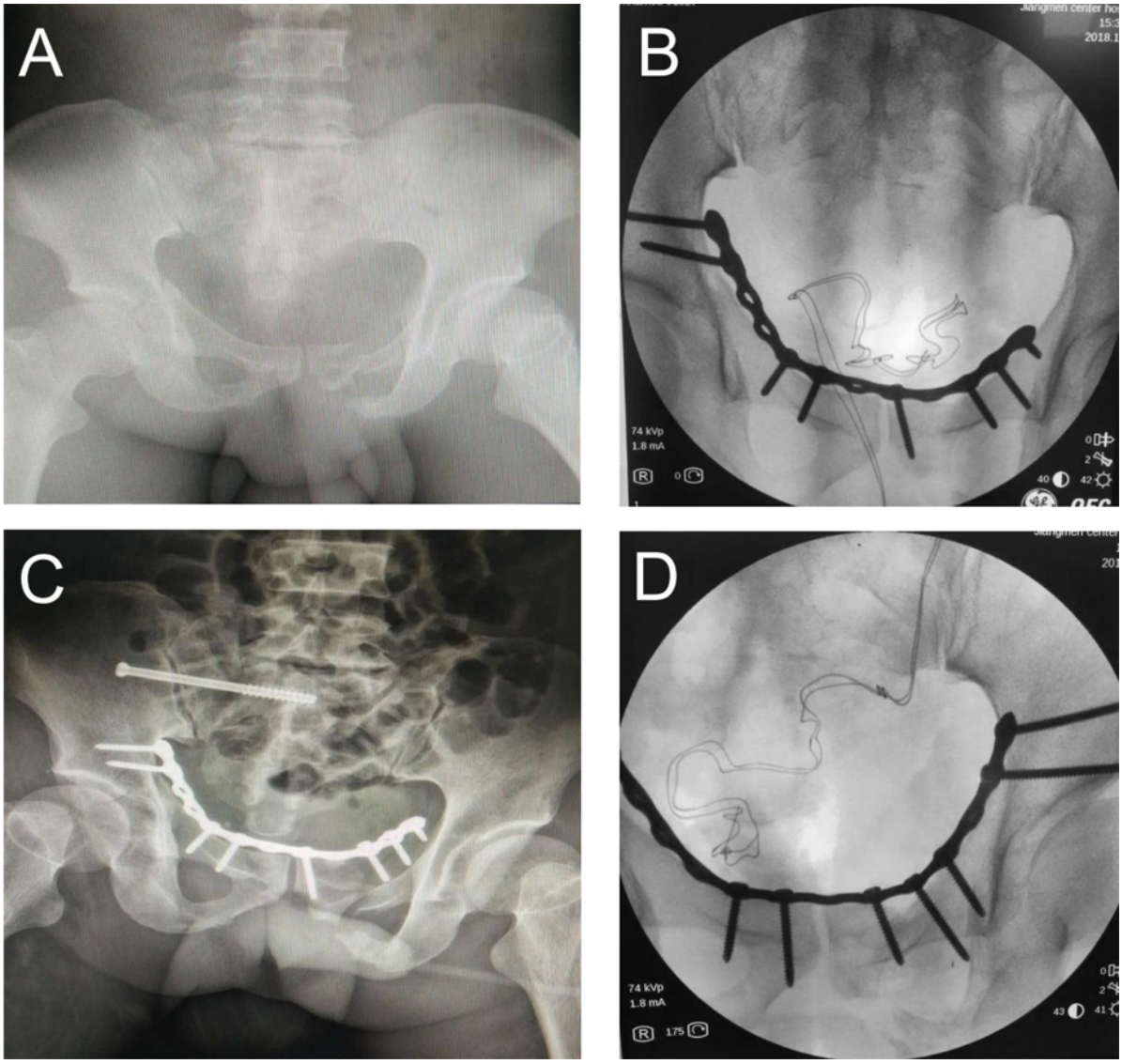

Figure 1

A 43-year-old man (Case 5 in Table 1) had a pelvic fracture (Tile C2 type) (A) due to falling from a height, without combined visceral organ damage. In the initial surgery, the anterior pelvic ring was fixed with a plate (B) and then the posterior ring was fixed with sacroiliac screws. Two weeks after surgery, (C) radiographic image showed failure of anterior ring internal fixation. (D) The patient underwent revision surgery to re-fix the anterior ring to the upper edge of the contralateral acetabulum with an extended steel plate.