Research Square

Preprints are preliminary reports that have not undergone peer review. They should not be considered conclusive, used to inform clinical practice, or referenced by the media as validated information.

The efficacy of superior oblique posterior tenectomy in the treatment of A-pattern exotropia without ocular intorsion: A retrospective study

Yan Wei
Shanghai Jiao Tong University School of Medicine
Ling-Yan Dong
Shanghai Jiao Tong University School of Medicine
Xiao-li Kang (kangxiaoli@xinhuamed.com.cn)
Pei-quan Zhao
Shanghai Jiao Tong University School of Medicine

Research article

Keywords: superior oblique posterior tenectomy; A-pattern; strabismus; intorsion

Posted Date: December 6th, 2019

DOI: https://doi.org/10.21203/rs.2.14556/v2

License: This work is licensed under a Creative Commons Attribution 4.0 International License. Read Full License

Version of Record: A version of this preprint was published on January 21st, 2020. See the published version at https://doi.org/10.1186/s12886-019-1298-4.

Abstract

Background: Superior oblique weakening is a common method to treat A-pattern strabismus. This study aims to evaluate the surgical results of the bilateral superior oblique posterior tenectomy procedure to treat A-pattern strabismus patients who had bilateral superior oblique overaction without objective ocular intorsion. Methods: The records of 18 consecutive patients who underwent surgery of superior oblique posterior tentomy close to its insertion with superior oblique overaction (SOOA)-associated A-pattern strabismus between September 1, 2015 and August 31, 2018 were retrospectively reviewed. Ocular alignment, objective torsion, A-pattern and ocular motility were assessed. Ocular alignment was measured in the primary position, 25° upgaze, and 25° downgaze using the prism bar cover test, and torsion was measured using fundus photographs. Results: A total of 18 patients (mean age: 15 years; 6 female, 12 male) underwent bilateral superior oblique posterior tenectomy and simultaneous horizontal rectus muscle surgery were included. The mean preoperative A-pattern deviation was 15 PD and the mean postoperative A-pattern deviation was 2.25 PD with a mean reduction of 12.75 PD. The mean preoperative superior oblique overaction was 2.28 and the mean postoperative superior oblique overaction was 0.43 with a mean reduction of 1.85. There was no significant correlation between the ocular torsional, vertical and horizontal alignment change and the superior oblique posterior tenectomy procedure. Conclusions: Superior oblique posterior tenectomy surgery selectively improved the A-pattern and superior oblique overaction but not affect the primary position vertical and horizontal deviation, as well as the ocular torsion. It is an effective procedure to treat the mild to moderate superior oblique overaction (SOOA)-associated A pattern strabismus without ocular intorsion.

Background

Superior oblique overaction is usually seen in A-pattern strabismus,and superior oblique weakening on one or both sides ishelpfulto solve this situation. Superior oblique posterior tenectomy (SOPT) was proposed first in 1976 to correct A-pattern deviations [1].The operation aims to weaken the abduction and depression effect of the superior oblique muscle through partial cutting of the posterior fibers at the insertion site, and induce clinically insignificant changes in the amount of torsion by leaving the anterior fibers intact. However, it has been reported that the magnitude of correction obtained by SOPT is less than that obtained by other procedures like a complete superior oblique tenotomy or split lengthening [2, 3], and few studies have evaluated concretely the A pattern, superior oblique function and torsional changes after selectively weakening of the superior oblique [4, 5]. The purpose of this study was to evaluate the effect of SOPT on A-pattern strabismus and its association with the preoperative primary position vertical and torsional deviation to provide further information for the preoperative planning of these patients with A-pattern and overaction of the superior obliques.

Methods

The clinical records of consecutive patients with A-pattern strabismus associated with bilateral superior oblique overaction from September 1, 2015 and August 31, 2018 were retrospectively reviewed, to identify

patients who had undergone bilateral superior oblique posterior 3/4 tenectomy for A-pattern strabismus without ocular objective intorsion during the study period, and had at least 3 months of postoperative follow-up.

The data collected included age, sex, preoperative and postoperative prism cover test at 33cm and 6 m, A-pattern, ocular movement, objective torsion and history of previous and subsequent squint surgery. An A pattern was defined as >10PD difference between up- and downgaze at 6 m by use of the alternate prism and cover test. A dilated fundus evaluation and fundus color photography were performed to evaluate objective torsion both before and after surgery. To evaluate the extent of torsion, a line is drawn from the center of the disc to the center of the fovea. The angle formed between this line and the line passing through the center of the disc is the extent of the torsion and measured by coreldraw 11.0 (Corel Corporation). The average value of the three measurement results is taken.

SO overaction was measured on a 9-cardinal system, from -4 to +4.Exaggerated traction test was performed before and after SO posterior tenectomy. Patients who had previous vertical or oblique muscle surgery or who previously underwent corrective surgery for A- or V-pattern strabismus were excluded.

The surgical technique of SO posterior tenectomy involved rotating the globe inferiorly. A conjunctival incision was fashioned in the superior temporal bulbar conjunctiva at the lateral border of the superior rectus (SR) muscle and 8 mm posterior to the superior limbus. The SO tendon was isolated on a muscle hook while care was taken to expose the whole posterior aspect of the tendon. A SO posterior tenectomy was performed, and the tenectomy extended from the insertion to just beneath the lateral border of the SR muscle. The anterior 1/4 of the tendon was left intact.

Statistical analysis was carried out using SPSS software version 12.0 (SPSS Inc, Chicago, Illinois, USA). A paired t-test was used to determine the statistical significance between pre- and 3 months postoperative results. P values less than 0.05 were considered statistically significant.

Results

Eighteen patients (thirty-six eyes) were included in the study. There were 6 female and 12 male patients in age ranging from 3 to 41 years, with a mean age of 15.22 years. The mean of follow up time was 19.33 month (ranging from 15 to 25 month). All patients showed A-pattern exotropia and bilateral superior oblique overaction without intorsion, and underwent bilateral superior oblique posterior tenectomy with horizontal strabismus surgery. None of the patient had diplopia prior to surgery. The operation was aim to improve the cosmetic appearance and tried to reconstruct binocular single vision.

<u>A Pattern</u>

Surgery was successful in collapsing the A pattern in all the patients. The mean A patterns were 15±3.87PD preoperatively (range, 10PD-22PD) and 2.25±2.73PD postoperatively (range, 0PD-8PD) (Figure 1). There was 12.75PD (85%) reduction in the size of the A pattern postoperatively.

Superior Oblique Overaction

The mean SO oblique overaction preoperative was 2.28±0.42 (range, 2 to 3), with a mean postoperative residual of 0.43±0.49 (range, 0 to 1) (Figure 2).

Objective Torsional Deviation

Based on the fundus examination, the mean preoperative extorsion was 5.97° ± 2.45° and postoperative extorsion was 5.8° ± 1.35° (Figure 3). No patient who underwent SO posterior tenectomy showed significant fundus torsion change or complained of torsional diplopia after surgery.

Primary Position Deviation

All the 18 patients showed primary position exotropia without vertical deviation at presentation, and had simultaneous surgery on their horizontal rectus muscles for exotropia. The mean exodeviations were 33.11 ±13.21PD preoperatively (range, 8-50PD) and 4.11±2.03PD postoperatively (range, 1-8PD). None of the patients showed postoperative primary position vertical deviation.

Complications

In our series, no complications such as consecutive superior oblique palsy, postoperative V pattern, or damage to the superior rectus muscle, were encountered.

Discussion

Our study recruited 18 patients with an overall A-pattern of 15 PD for whom a correction of12.75PD (85%) was achieved. The mean SO overaction grade decreased from 2.28 before surgery to 0.43 after surgery.This was a statistically significant change. No induced vertical deviations were seen in those patients and no patient showed significant fundus torsion change or complained of torsional diplopia postoperatively. This study suggests that SO posterior tenectomy effectively collapses mild to moderate A-pattern deviation and SO overaction, but not affect the primary position vertical and horizontal deviation, as well as the ocular torsion.

Several techniques have been described to weaken the superior oblique muscle, including superior oblique tenotomy or tenectomy, recession, posterior tenectomy and tenotomy with a prosthetic spacer. The main complications associated with complete tenectomy and tenotomy are that it may lead to iatrogenic superior oblique palsy, conversion of an A -pattern to a V -pattern and induced excyclotorsion[6, 7]. Superior oblique posterior tenectomy leaving the anterior fibers intact will result in selective weakening of the abduction in downgaze while preserving its intorsion, and the risks of inducing superior oblique palsy or V-pattern were not seen in our study. Therefore this procedure is an effective surgical approach for A pattern strabismus with superior oblique overaction but no intorsion.

Conclusions

In our study, bilateral superior oblique posterior tenectomy proved to be an effective treatment for mild to moderate A-pattern and superior oblique overaction, without causing torsional deviation change and vertical deviation in primary position. Compared with SO recession and complete SO tenotomy, SOPT spares the anterior fibers responsible for torsion, thus avoiding postoperative undesirable torsional complications. Further study may be necessary to answer those questions whether it can be helpful to treat patients with severe A-pattern strabismus or with objective ocular intorsion.

List Of Abbreviations

superior oblique overaction (SOOA); Superior oblique posterior tenotomy (SOPT)

Declarations

Ethics approval and consent to participate

This retrospective study has been approved by Shanghai Xinhua Hospitalethics committee, affiliated to Shanghai Jiao Tong UniversitySchool of Medicine.

Consent for publication

Not applicable.

Availability of data and materials

The datasets used and/or analysed during the current study are available from the corresponding author on reasonable request.

Competing interests

The authors declare that they have no competing interests.

Funding

This work was supported by the National Science Foundation of China (81770933), the role of this funding is in the collection, analysis, and interpretation of data and in writing the manuscript.

Authors' contributions

YW and LYD contributed to analysis and interpretation of data, and drafted the work; XLK and PQZ contributed participated in the research planning, provided clinical material, revised the manuscript and approved it to be published.All authors read and approved the final manuscript.

Acknowledgements

Not applicable.

References

1. Prieto-Diaz J. Posterior tenectomy of the superior oblique. Journal of pediatric ophthalmology and strabismus. 1979; 16(5):321-3.
2. Heo H, Lee KH, Ahn JK, Kim DH, Park YG, Park SW. Effect of 10-mm superior oblique posterior tenectomy combined with frenulum dissection in A-pattern with superior oblique overaction. Am J Ophthalmol. 2009; 148(5):794-9.
3. Sharma P, Saxena R, Rao BV, Menon V. Effect of posterior tenectomy of the superior oblique on objective and subjective torsion in cases of superior oblique overaction. J Pediatr Ophthalmol Strabismus. 2005; 42(5):284-9.
4. Ranka MP, Liu GT, Nam JN, Lustig MJ, Schwartz SR, Hall LS, Furlan LE, Ceisler EJ, Steele MA. Bilateral posterior tenectomy of the superior oblique muscle for the treatment of A-pattern strabismus. J AAPOS. 2014; 18(5):437-40.
5. Ung T, Raoof N, Burke J. Effect of superior oblique weakening on vertical alignment and horizontal and vertical incomitance in patients with A-pattern strabismus. J AAPOS. 2011; 15(1):9-13.
6. Santiago AP, Rosenbaum AL. Grave complications after superior oblique tenotomy or tenectomy for Brown syndrome. J AAPOS. 1997; 1(1):8-15.
7. Brooks DR, Morrison DG, Donahue SP. The efficacy of superior oblique Z-tenotomy in the treatment of overdepression in adduction (superior oblique overaction). J AAPOS. 2012; 16(4):342-4.

Figures

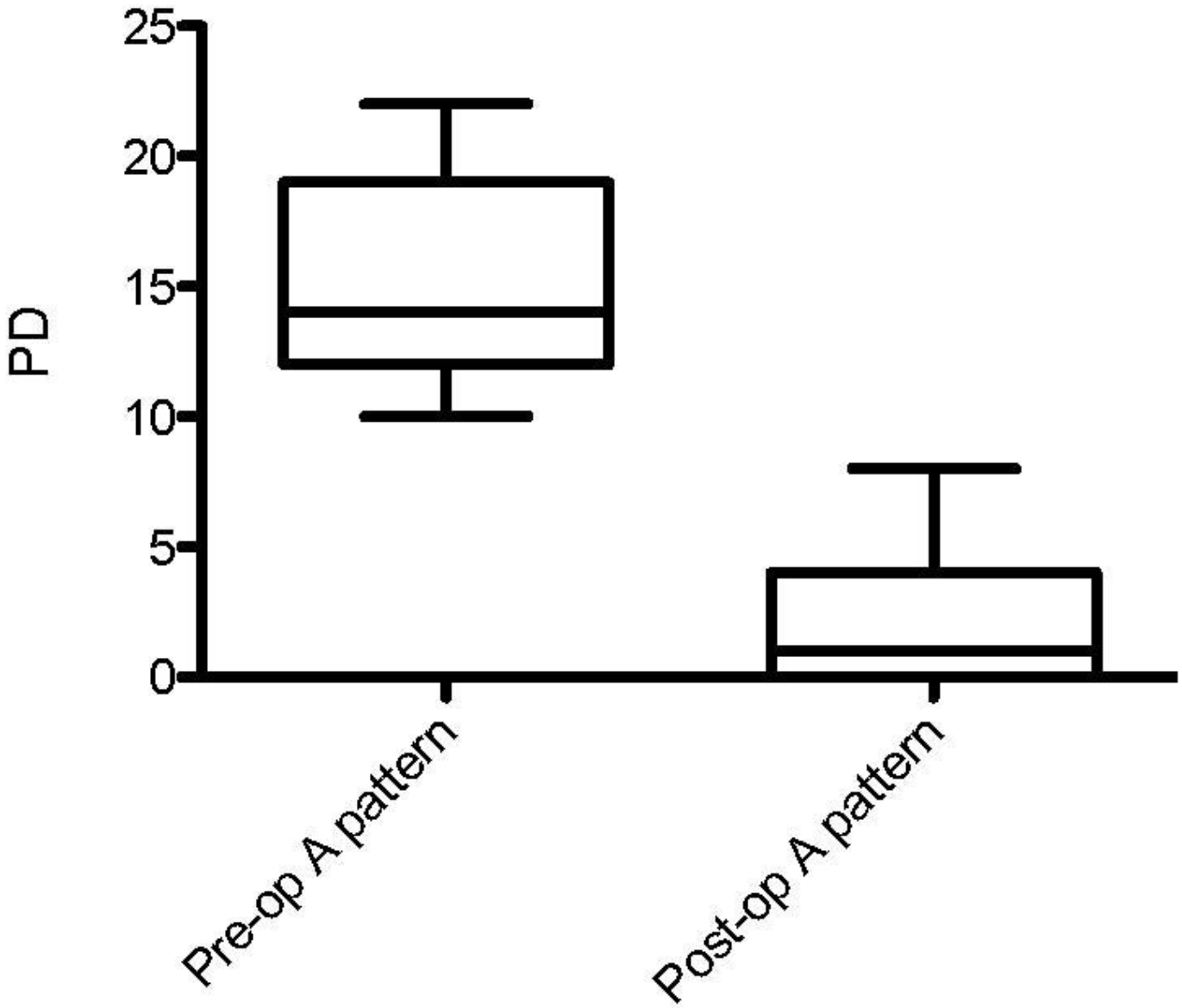

Figure 1

Box-and-whiskers plot demonstrating the median (range) values of the pre- and postoperative A-pattern size ($p<0.05$). PD: prism diopters

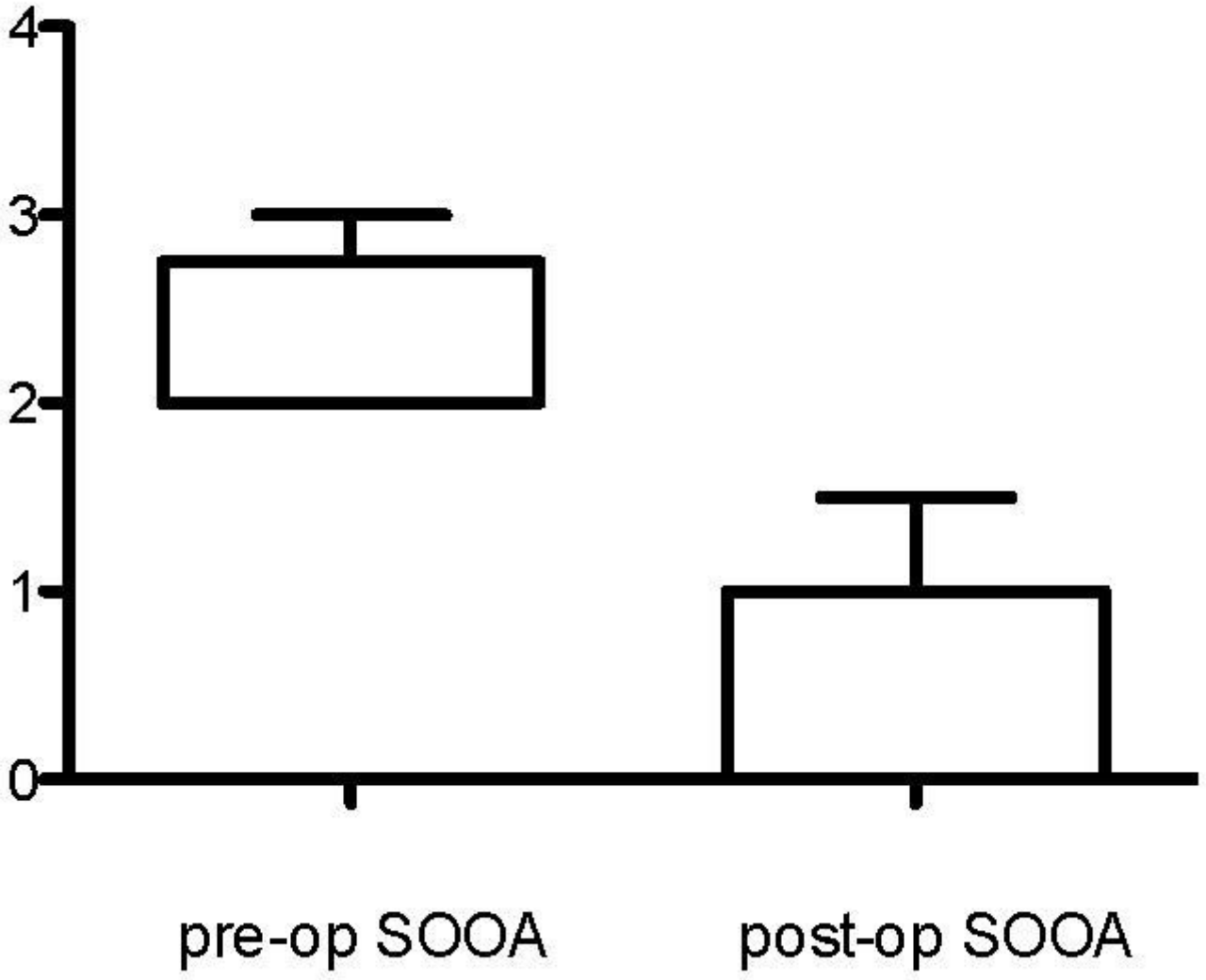

Figure 2

Preoperative and postoperative superior oblique overaction in patients who underwent bilateral SO posterior tenectomy (mean and SD).

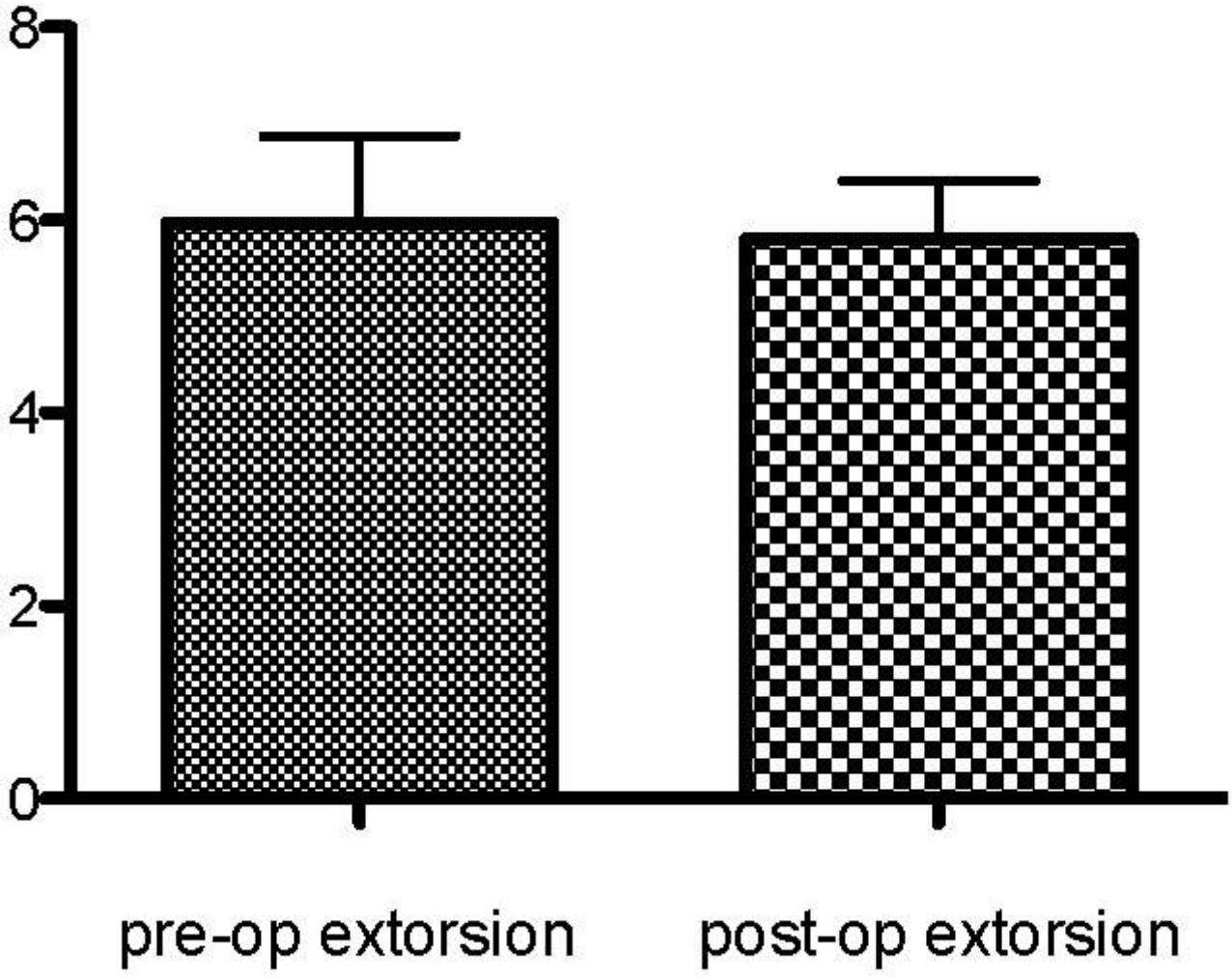

Figure 3

Preoperative and postoperative objective torsional deviation in patients who underwent bilateral SO posterior tenectomy (mean and SD).