Distance and Direction of Retained Root Migration After Lower Third Molar Coronectomy

Prattana Niyomthai
Mahidol University

Chakorn Vorakulpipat
Mahidol University

Pattamawan Manosuthi
Mahidol University

Aurasa Waikakul (Aurasa.wai@gmail.com)
Mahidol University

Research Article

Keywords: coronectomy, retained root migration, lower third molar, distance of migration, direction of migration, pattern of migration

Posted Date: June 2nd, 2021

DOI: https://doi.org/10.21203/rs.3.rs-524109/v1

Abstract

Background: The present study evaluated the pattern of root migration following coronectomy of the mandibular third molar in terms of distance, degree of direction, and relevant factors related to root migration.

Methods: This retrospective study included 50 coronectomies in 44 patients with at least 1-year follow-up. Panoramic radiographs were taken pre-operatively, within 2 weeks after surgery, and at 3, 6, and 12 months post-operatively. Multiple factors are possibly related to root migration, so we analyzed sex, age, tooth, figure of root, residual bone height, and also as Winter's and Pell& Gregory classification with respect to angulation, class, and position of tooth.

Results: Over the first three months after the coronectomies, all retained roots moved and/or changed their root axis. The respective mean distance of retained root migration in the horizontal (C1), coronal (C2), and oblique (C3) direction during the first year post-operatively was 3.14 ± 1.86 mm, 2.42 ± 1.61 mm, and 3.45 ±1.76 mm. The mean (±SD) root axis change was 11.26 ± 5.55 degrees. The significant influencing factors related to root migration were sex, age, and in particular tooth angulation (GEE: $P<0.05$). The mesio- and horizontal angulation (M, H) group migrated significantly further horizontally forward (C1) over time than the vertical (V) and distoangulation (D) group. The V, D group showed significantly greater coronal migration (C2) ($P=0.05$) than the M, H group. The V, D group had only mesial rotation.

Conclusion: These findings could contribute to evaluation and/or planning for root removal.

Background

Inferior alveolar nerve injury (IANI) is a common complication of surgical removal of deeply impacted teeth[1–6]. Evidence-based reviews showed that IANI is associated with age of the patient, depth of the impacted tooth, and proximity of the root to the inferior alveolar nerve (IAN) as indicated by radiographic signs[2,5–8].

Due to proximity of the root to the IAN canal, coronectomy of the lower third molar may be the preferred option. The procedure was first described in 1984 by Ecuyer and Debien[9–11]. This surgical procedure intentionally removes only the crown of the mandibular third molar, leaving the root in the alveolar bone in order to avoid IANI[1,3,4,12–23]. Several previous studies reported that coronectomy had a lower risk of nerve injury than total removal of the impacted tooth[1,3,4,12,13,18,20–23]. After coronectomy, the root may migrate or erupt into the oral cavity and, due to remnants of the root, local infection may occur, potentially necessitating re-operation[13–18,21]. The peak migration rate of the retained root is about 6 months after the coronectomy[6,9,21,24], which then gradually decreases[4,6,9] as bone grows over the retained roots[6,10].

A number of studies have addressed the magnitude of root migration with various measuring methods and reference points[1,10,12,24]. One study reported the pattern of root translation and rotation by using cone beam computed tomography (CBCT)[25]. Some researchers[1,10,12,25] reported on root migration distance and migration direction, while only one investigated the degree of root axis change to evaluate the directional change of the retained root[25].

The current study investigated the degree and pattern of retained root movement following coronectomy in terms of distance and movement in any direction using panoramic radiograph, and other related factors. Knowing the distance and direction of retained root migration and their related factors would be useful for planning coronectomy and determining its prognosis.

Methods

This retrospective study was approved by the Institutional Review Board, Faculty of Dentistry, Faculty of Pharmacy, Mahidol University (COA.No.MU-DT/PY-IRB 2013/005.2801).

Patients were recruited who underwent coronectomy of an impacted lower third molar at the Oral and Maxillofacial Clinic, Faculty of Dentistry, Mahidol University, between January 2011 and January 2016, and who were at high-risk of IAN injury signs, according to Roods and Shehab's criteria[26,27]. The inclusion criteria were healthy patients who were followed up at least 1 year after the coronectomy and who had signed informed consent, had complete charting together with 5 periods of panoramic radiographs. The radiographs were pre-operative, immediate (within 2 weeks), and 3, 6, and 12 months post-operatively. If the patients had pathologic lesions near the tooth, they were excluded[1,3].

We recorded patient demographics (sex, age), tooth status (side of tooth, angulation, classification, and position according to Winter's and Pell & Gregory's classification), figure of root, and residual bone height of the alveolar crest after coronectomy. Panoramic radiographs were taken with a Kodak CS 9000 Carestream radiographic machine (Carestream Health Inc. New York, USA). The retained root migration distance was measured in millimeters and the directional changes of the root axis were measured in degrees of angular rotation using PACS software (J.F. Advance Med Co., Ltd., Thailand)

Surgical technique

All lower third molar coronectomies were performed under local anesthesia as previously described[1–6, 9,10, 12–19,24]

The tooth crown was removed and the resection surface trimmed to 4 mm below the alveolar crest to ensure no remaining enamel. Wound closure was done with Silk (Mersilk 3 – 0).

Data measurement

Post-operative panoramic radiographs (immediate post-operative: within 2 weeks (T0), 3 months (T1), 6 months (T2), and 12 months (T3) post-operatively) were taken to measure root migration.

The X- and Y-axis were set to be the constant reference lines in all radiographs (Fig. 1A). The X-axis was the horizontal straight line passing both mesially and distally to the cementoenamel junctions (CEJs) of the lower second molar while the Y-axis was a vertical line perpendicular to the X-axis passing the distal CEJ of the lower second molar (A-point)

As for root migration distance, the C point was set at the most inferior point of the retained root. To determine the root migration distance in the horizontal, coronal, and oblique directions, we measured the distance from the C point parallel to the X-axis (C_1) and the C point parallel to the Y-axis (C_2), and an oblique line from the C-point to the intersecting point of the X and Y axes (C_3). Measurements were in millimeters (mm).

The difference between C_1, C_2, and C_3 at time point T_0, T_1, T_2, and T_3 ($\Delta CnTn$) were calculated to represent the distance of root migration in the horizontal, coronal, and oblique directions at each time point. For example, $\Delta C_1T_1 = C_1T_0 - C_1T_1$

As for measurement of the direction of root migration (Fig. 1B), the root axis (M3 axis) was established from the E-point: the midpoint between the mesial and distal coronectomy resection margin (H_1-H_2). The latter represented the coronectomy resection line. The M-point was the midpoint between the lowest point of the mesial and distal roots (G1 and G2) in the plane parallel to the H1-H2 line. The change of angle (Fig. 1C, 1D) in degrees ($\Delta \hat{a}T_n$) between the root axis and the X or Y axis ($\hat{a}$) from the immediate to post-operative time point (as T1, T2, or T3) was defined as the direction of root migration or rotation of the root.

Changing in reference line angle were used to interpret the degree of direction to determine the tendency to mesial or distal rotation. The Y-axis served as a reference line for the mesio and horizontal angulation (M, H) impaction group (Fig. 1C), while the X axis was used for the vertical and distoangulation (V, D) impaction group (Fig. 1D). Increased degrees implied more mesial rotation while decreased degrees indicated more distal rotation of the roots.

Statistical analysis

Statistical analysis was performed using SPSS version 22 and Stata version 15. Inter- and intra- examiner reliability was assessed using the intra-class correlation coefficient (ICC). The distance and direction of root migration were reported using descriptive data analysis. The measured parameters were divided into groups, according to each potentially related factor. The difference between these groups were then examined using an independent T-test and one-way ANOVA. Based on these results, the Generalized Estimating Equation (GEE) was applied to the factors showing statistically significant differences so as to reveal the factors predictive for changes in distance and direction of root migration over time. P values

< 0.05 were considered statistically significant. The Mann-Whitney U test was used to compare the rotational direction between the mesial and distal rotation groups.

Results

Fifty teeth from 44 patients were included. Patient demographics are presented in Table 1. Since only a small number of samples were available in each type of tooth angulation, two groups were formed as per similar characteristics of each impacted tooth: the M, H group, and the V, D group. The level of intra- and inter-examiner reliability was excellent with an ICC of 0.996 and 0.988, respectively. Root migration presented in all cases during the first year after surgery. Root migration distances in 3 directions and the angular rotation of the root axis at each time point are presented in Table 2. The average root migration at the 1-year follow-up in the horizontal direction (mean ΔC1T3 ± SD) was 3.14 ± 1.86 mm, while it was 2.42 ± 1.61 mm in the coronal direction (mean ΔC2T3 ± SD), and 3.45 ± 1.76 mm in the oblique direction (mean ΔC3T3 ± SD). The average angular rotation (mean ΔâT3 ± SD) was 11.26 ± 5.55 degrees.

Table 1
Demographic characteristics

Characteristic	n: teeth (patient)	% of teeth
Sex		
Female	39 (34)	78
Male	11 (10)	22
Age, years		
19–25	17 (15)	34
>25	33 (29)	66
Tooth		
38	22	44
48	28	56
Figure of root		
Cone	16	32
Clubbed	8	16
Diverge	26	52
Residual bone height		
< 4 mm.	12	24
4 mm. or more	38	76
Angulation (Winter's classification)		
M, H group	38	76
V, D group	12	24
Class (Pell & Gregory's classification)		
I	18	36
II	21	42
III	11	22
Position (Pell & Gregory's classification)		
A	22	44
M, H group: mesioangulation and horizontal angulation group		
V, D group: vertical angulation and distoangulation group		

Characteristic	n: teeth (patient)	% of teeth
B	16	32
C	12	24
M, H group: mesioangulation and horizontal angulation group		
V, D group: vertical angulation and distoangulation group		

Table 2
Mean ± SD of root migration in distance and root axis change at 3 (T1), 6 (T2), and 12 (T3) months after coronectomy

	Mean ± SD		
	T1	T2	T3
ΔC1 (mm) (n = 50)	1.16 ± 0.68	2.43 ± 1.49	3.14 ± 1.86
ΔC2 (mm) (n = 50)	0.80 ± 0.65	1.90 ± 1.36	2.42 ± 1.61
ΔC3 (mm) (n = 50)	0.99 ± 0.72	2.47 ± 1.31	3.45 ± 1.76
Δâ: angle (degree) (n = 50)	4.12 ± 3.98	8.80 ± 5.18	11.26 ± 5.55
Δâ (mesial) (n = 25)	5.08 ± 5.10	9.52 ± 6.21	11.72 ± 6.63
Δâ (distal) (n = 25)	3.16 ± 2.10	8.08 ± 3.90	10.80 ± 4.31

Retained roots were able to migrate either mesially or distally. Mesial and distal rotation were found equally (25:25). Mesial rotation occurred in both the M, H group and the V, D group (52% (13/25) and 48% (12/25), respectively), whereas all 25 distally-rotated roots were found only in the M, H group. There was no distal rotation in the V, D group.

Factors related to root migration

The Independent t-test and one-way ANOVA of factors relating to root migration at the 1-year follow-up are presented in Table 3. Tooth angulation was statistically related to both migration distances (ΔC1, ΔC2) and angular rotation (Δâ) while age and sex were related to coronal migration (ΔC2) and angular rotation (Δâ), respectively ($P < 0.05$).

Table 3
Factors possibly related to the distance and direction of root migration

Factors	Distance						Direction	
	ΔC1 at T3		ΔC2 at T3		ΔC3 at T3		Δâ at T3	
	Mean ± SD	P-value	Mean ± SD	P-value	Mean ± SD	P-value	Mean ± SD	P-value
Sex								
Male (n = 11)	3.88 ± 1.73	0.135	2.09 ± 0.83	0.451	3.78 ± 1.01	0.486	8.27 ± 4.65	0.042*
Female (n = 39)	2.93 ± 1.86		2.51 ± 1.77		3.36 ± 1.92		12.10 ± 5.55	
Age (Years)								
19–25 (n = 17)	3.58 ± 1.94	0.238	1.74 ± 0.86	0.031*	3.30 ± 1.53	0.667	10.00 ± 4.76	0.254
> 25 (n = 33)	2.92 ± 1.80		2.76 ± 1.80		3.53 ± 1.88		11.91 ± 5.89	
Tooth								
38 (n = 22)	3.17 ± 1.84	0.925	2.57 ± 1.51	0.546	3.62 ± 1.58	0.549	9.82 ± 4.85	0.104
48 (n = 28)	3.12 ± 1.90		2.29 ± 1.7		3.32 ± 1.91		12.39 ± 5.89	
Figure of root								
Cone (n = 16)	2.75 ± 1.70	0.333	2.07 ± 1.95	0.533	3.34 ± 2.14	0.191	12.50 ± 5.61	0.557
Club (n = 8)	3.95 ± 2.41		2.80 ± 2.21		4.48 ± 2.29		10.38 ± 4.84	
Diverge (n = 26)	3.14 ± 1.76		2.51 ± 1.14		3.21 ± 1.20		10.77 ± 5.79	

Table 3
(cont.) Factors possibly related to the distance and direction of root migration

Factors	Distance						Direction	
	ΔC1 at T3		ΔC2 at T3		ΔC3 at T3		Δâ at T3	
	Mean ± SD	P-value	Mean ± SD	P-value	Mean ± SD	P-value	Mean ± SD	P-value
Residual bone height (mm.)								
< 4 (n = 12)	2.84 ± 2.30	0.520	2.69 ± 2.27	0.499	3.50 ± 2.47	0.913	13.08 ± 5.50	0.195
4 (n = 38)	3.24 ± 1.72		2.33 ± 1.37		3.44 ± 1.51		10.68 ± 5.52	
Angulation of tooth								
M,H (n = 38)	3.47 ± 1.93	0.004*	2.13 ± 1.37	0.023*	3.52 ± 1.72	0.640	9.95 ± 4.32	0.024*
V,D (n = 22)	2.10 ± 1.07		3.33 ± 2.01		3.24 ± 1.95		15.42 ± 7.06	
Class								
I (n = 18)	3.27 ± 1.87	0.940	2.26 ± 1.02	0.069	3.37 ± 1.17	0.795	12.22 ± 4.86	0.086
II (n = 21)	3.06 ± 1.71		2.96 ± 2.10		3.65 ± 2.08		12.14 ± 6.16	
III (n = 11)	3.10 ± 2.25		1.62 ± 0.87		3.23 ± 2.02		8.00 ± 4.49	
Position								
A (n = 22)	2.83 ± 1.68	0.570	2.34 ± 1.21	0.950	2.89 ± 1.27	0.080	13.36 ± 5.91	0.054
B (n = 16)	3.33 ± 2.07		2.51 ± 1.44		3.62 ± 1.96		9.88 ± 4.76	
C (n = 12)	3.46 ± 1.93		2.44 ± 2.43		4.27 ± 2.03		9.25 ± 4.88	
* significant P-value < 0.05								

Although the shape of the root proved not to be statistically significant, it was considered in the GEE analysis because previous studies suggested it might influence root migration[10,13,20,25].

An assessment of all related factors in terms of distance in three directions (C1, C2, and C3), and angular rotation of the root axis revealed the progression of retained root migration followed similar patterns (Fig. 2–5). Peak migration rates of the root were found at 3–6 months then gradually decreased between

6–12 months post-operatively. According to the GEE analysis, only acceleration of horizontal (C1) and coronal (C2) root migration were significantly affected by tooth angulation.

The M, H group showed more horizontal migration (C1) than the V, D group over time ($P = 0.003$) (Fig. 2C) while the V, D group roots migrated more coronally (C2) than those in the M, H group ($P = 0.05$) (Fig. 3C). There was no significant relationship with any factors for oblique migration (C3) (Fig. 4) and angle changing (Fig. 5) (â). With respect to mesial and distal rotation, the changes in angular rotation were not statistically significant different between groups (Table 4).

Table 4
Median angle of mesial and distal rotation group (Mann-Whitney U test)

	Δâ (degree) : Median)P25, P75(		
	Distal rotation (n = 25)	**Mesial rotation (n = 25)**	**P-value**
T1 (3 months)	3 (1, 5)	3 (1.5, 7)	0.318
T2 (6 months)	7 (5, 11)	8 (4.5, 15.5)	0.633
T3 (12 months)	10 (8.5, 14)	11 (6.5, 17)	0.923
Significant P-value < 0.05			

Discussion

The results of the current study agreed with previous studies albeit follow-up times were different [1,10,12,13,20,25]. Goto et al.[10] and Dolanmaz et al.[28] reported mean root migration at 1-year post-operative as 3 mm and 4 mm, respectively. Meanwhile Leung and Cheung[1] reported that root migration distance was in the range of 0–6 mm at 2 years post-operatively. In 2012, Leung and Cheung[20] extended the follow-up time to 3 years, reporting a mean distance of 2.8 mm. A long-term study by Yeung et al.[25] revealed a mean root migration of 2.8 ± 2.27 mm at the 4-8.5 year follow-up. The current study described a change of retained root axis rotation in degrees, implying the actual alteration of direction of the root via panoramic radiographs. This technique uses many calibrated reference levels to improve the precision and accuracy measurement.

The current study showed an acceleration of root migration, coronally in the V, D group, and horizontally in the M, H group, up to 1 year post-operatively. These results agree with Leung and Cheung[(20)] and Yeung et al.[(25)] who reported predominantly mesial translation or towards the oral cavity over time which should be followed-up for more than 6 months.[(7,20)]

More than half of the roots in the M, H group were mesially-rotated, which should be a warning that the moving root may toward reimpacting to the second molar.

The distally-rotated roots were solely in the M, H group, suggesting an up-righting behavior of these roots, making them easier to be removed later. Furthermore, no roots in the V, D group had distal rotation, which would increase distal impaction of the root into the ramus region.

At a rapid migration rate, coronal and oblique movement of retained roots could emerge in the alveolar bone or be intraorally exposed within 1 year post-operatively. The V, D group migrated coronally a greater distance than the M, H group, which may be result in a greater chance of the retained root erupting into the oral cavities. Monaco et al.[12] reported that within the first year, 6% of those migrated root fragments need to be removed. If they were not removed, the consequence of horizontal and oblique migration was likely to re-impact the adjacent second molar. The M, H group had significant horizontal migration, perhaps because the M, H group is most likely to migrate in the original direction towards the lower second molar root.

Kohara et al.[13] reported a significant difference in root migration between patients of different ages and sex. The current study suggests the significant difference in coronal migration and angular rotation is primarily related to age and sex, respectively.

Taken together, our results indicate that coronectomy helps to avoid IANI and if a second operation is needed to remove retained root, it is a less complicated surgery than the original total removal. Post-operative follow-up is vital, especially during on-going root migration. Surgeons should be aware of the consequences of a retained root abutting the lower second molar root which can develop a deep periodontal pocket and dental caries at the distal surface of the lower second molar. By way of prevention, the retained roots should be removed when they migrate away from inferior alveolar canal. This procedure should be performed before the root migrates to touching the second molars.

In cases of a partially or fully erupted V, D impacted tooth (position A), where the crown resection level might be lower than usual, it is necessary to compensate for the migration distance so as to reduce the need for re-operation. Notwithstanding, to our knowledge no studies describe the effects on the lower second molar. Further studies are thus needed to improve surgical techniques.

Conclusion

All retained roots of coronectomies changed in location and direction up to 1 year post-operatively. The influencing factors were sex, age, and especially angulation of the tooth. There was significant acceleration of horizontal root migration in the M, H group compared to the V, D group. The latter trended to move more coronally. The V, D group change root migration direction only mesially and to a much greater degree than the M, H group.

These results could assist in managing impacted lower third molars at high risk of inferior alveolar nerve injuries with respect to surgical plans and information communicated to patients.

Abbreviations

C1: Horizontal direction

C2: Coronal direction

C3: Oblique direction

M: Mesioangulation

H: Horizontal angulation

V: Vertical angulation

D: Distoangulation

Declarations

Ethics approval and consent to participate:

The ethical approval was given by the Faculty of Dentistry and the Faculty of Pharmacy, Mahidol University, Institutional Review board (MU-DT/PY-IRB), reference number: COA.No.MU-DT/PY-IRB 2013/005.2801.

The patient consent was not required in this study.

Availability of data and material:

The datasets used and/or analyzed during the current study are available from the corresponding author on reasonable request.

Competing Interests:

The authors declare that they have no conflicts of interest or competing interests.

Funding:

Not applicable.

Authors' contributions:

PN: the acquisition, analysis, manuscript preparation, statistical analysis, literature research

CV: Interpretation of data, manuscript editing, definition of intellectual content, final approval.

PM: The acquisition, analysis, definition of intellectual content, manuscript review

AW: study conception, design of work, definition of intellectual content, manuscript review, manuscript editing, final approval.

All authors read and approved the final manuscript.

Acknowledgements:

Not applicable

References

1. Leung YY, Cheung LK.Safety of coronectomy versus excision of wisdom teeth: a randomized controlled trial.*Oral Surg Oral Med Oral Pathol Oral Radiol Endod* 2009;108(6):821–7.
2. Leung YY, Cheung LK.Long-term morbidities of coronectomy on lower third molar.*Oral Surg Oral Med Oral Pathol Oral Radiol* 2016;121(1):5–11.
3. Long H, Zhou Y, Liao L, Pyakurel U, Wang Y, Lai W.Coronectomy vs. total removal for third molar extraction: a systematic review.*J Dent Res* 2012;91(7):659–65.
4. Moreno-Vicente J, Schiavone-Mussano R, Clemente-Salas E, Mari-Roig A, Jane-Salas E, Lopez-Lopez J.Coronectomy versus surgical removal of the lower third molars with a high risk of injury to the inferior alveolar nerve. A bibliographical review.*Med Oral Patol Oral Cir Bucal* 2015;20(4):e508-17.
5. Mukherjee S, Vikraman B, Sankar D, Veerabahu MS.Evaluation of outcome following coronectomy for the management of mandibular third molars in close proximity to inferior alveolar nerve.*J Clin Diagn Res* 2016;10(8):ZC57-62.
6. Martin A, Perinetti G, Costantinides F, Maglione M.Coronectomy as a surgical approach to impacted mandibular third molars: A systematic review.*Head & Face Med* 2015;11:9.
7. Renton T, Hankins M, Sproate C, McGurk M.A randomized controlled clinical trial to compare the incidence of injury to the inferior alveolar nerve as a result of coronectomy and removal of mandibular third molars.*Br J Oral Maxillofac Surg* 2005;43:7–12.
8. Renton T.Prevention of Iatrogenic inferior alveolar nerve injuries in relation to dental procedures.*Dent Update* 2010;37:350–63.
9. Gady J, Fletcher MC.Coronectomy: indications, outcomes, and description of technique.*Atlas Oral Maxillofac Surg Clin North Am* 2013;21(2):221–6.
10. Goto S, Kurita K, Kuroiwa Y, Hatano Y, Kohara K, Izumi M, et al.Clinical and dental computed tomographic evaluation 1 year after coronectomy.*J Oral Maxillofac Surg* 2012;70(5):1023–9.
11. Ecuyer J, Debien J.[Surgical deductions].Actual Odontostomatol (Paris).1984;38:695–702.
12. Monaco G, De Santis G, Pulpito G, Gatto MR, Vignudelli E, Marchetti C.What are the types and frequencies of complications associated with mandibular third molar coronectomy? A follow-up study.*J Oral Maxillofac Surg* 2015;73(7):1246–53.
13. Kohara K, Kurita K, Kuroiwa Y, Goto S, Umemura E.Usefulness of mandibular third molar coronectomy assessed through clinical evaluation over three years of follow-up.*Int J Oral Maxillofac Surg* 2015;44(2):259–66.

14. Sencimen M, Ortakoglu K, Aydin C, Aydintug Y, Ozyigit A, Ozen T, et al.Is endodontic treatment necessary during coronectomy procedure?*J Oral Maxillofac Surg* 2010;68:2385–90.
15. Patel V.To retrieve or not to retrieve the coronectomy root-The clinical dilemma.*Dent Update* 2013;40:370–6.
16. O'Riordan BC.Coronectomy (intentional partial odontectomy of lower third molars).*Oral Surg Oral Med Oral Pathol Oral Radiol Endod* 2004;98(3):274–80.
17. Kouwenberg AJ, Stroy LP, Rijt ED, Mensink G, Gooris PJ.Coronectomy of the mandibular third molar: Respect for the inferior alveolar nerve.*J Craniomaxillofac Surg* 2016;44(5):616–21.
18. Monaco G, Vignudelli E, Diazzi M, Marchetti C, Corinaldesi G.Coronectomy of mandibular third molars: A clinical protocol to avoid inferior alveolar nerve injury.*J Craniomaxillofac Surg* 2015;43(8):1694–9.
19. Franco S, Vignudelli E, Monaco G, Marchetti C.Influence of secondary wound healing after mandibular third molar coronectomy.*Br J Oral Maxillofac Surg* 2017;55(2):145–9.
20. Leung YY, Cheung LK.Coronectomy of the lower third molar is safe within the first 3 years.*J Oral Maxillofac Surg* 2012;70:1515–22.
21. Barcellos BM, Velasques BD, Moura LB, Xavier CB.What are the parameters for reoperation in mandibular third molars submitted to coronectomy? A systematic review.*J Oral Maxillofac Surg* 2019;77:1108–15.
22. Hatano Y, Kurita K, Kuroiwa Y, Yuasa H, Ariji E.Clinical evaluation of coronectomy (intentional partial odontectomy) for mandibular third molars using dental computed tomography: A case-control study.*J Oral Maxillofac Surg* 2009;67:1806–14.
23. Pogrel MA, Lee JS, Muff DF.Coronectomy: a technique to protect the inferior alveolar nerve.*J Oral Maxillofac Surg* 2004;62(12):1447–52.
24. Leung YY, Cheung KY.Root migration pattern after third molar coronectomy: a long-term analysis.*Int J Oral Maxillofac Surg* 2018;47(6):802–8.
25. Yeung AW, Wong NS, Bornstein MM, Leung YY.Three-dimensional radiographic evaluation of root migration patterns 4–8.5 years after lower third molar coronectomy: a cone beam computed tomography study.*Int J Oral Maxillofac Surg* 2018;47(9):1145–52.
26. Rood JP, Shehab BA.The radiological prediction of inferior alveolar nerve injury during third molar surgery.*Br J Oral Maxillofac Surg* 1990;28(1):20–5.
27. Palma-Carrio C, Garcia-Mira B, Larrazabal-Moron C, Penarrocha-Diago M.Radiographic signs associated with inferior alveolar nerve damage following lower third molar extraction.*Med Oral Patol Oral Cir Bucal* 2010;15(6):e886-90.
28. Dolanmaz D, Yildirim G, Isik K, Kucuk K, Ozturk A.A preferable technique for protecting the inferior alveolar nerve: coronectomy.*J Oral Maxillofac Surg* 2009;67(6):1234–8.

Figures

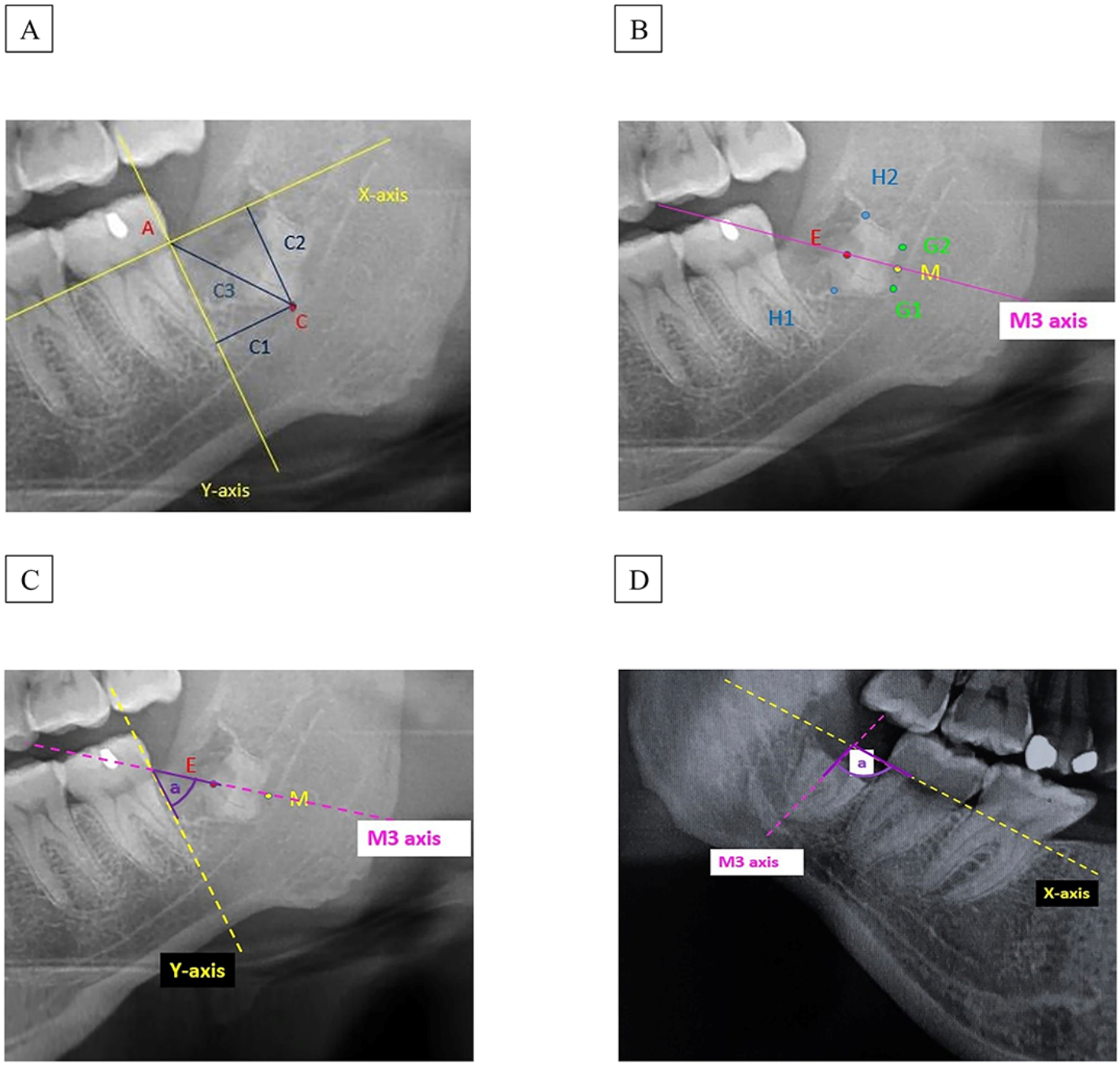

Figure 1

A: Measurement of root migration distance in 3 directions: Horizontal (C1), Coronal (C2), Oblique (C3); B, C, D: Measurement of angles of root axis related to reference lines. B: Establishment of root axis from reference points. C: Mesioangulation and horizontal angulation group used Y-axis as reference line. D: Vertical and distoangulation group used X-axis as reference line X-axis: Horizontal reference axis passing through mesial and distal of CEJ of the lower second molar Y-axis: Vertical reference axis perpendicular to X-axis passing through distal CEJ point of the lower second molar A-point: intersection point of X-axis and Y-axis at distal CEJ of lower second molar C-point: lowest point of root compartment of lower third molar in plane parallel to X-axis C1: distance from C-point parallel to X- axis (mm) C2: distance from C-

point parallel to Y- axis (mm) C3: distance from C-point to A-point (mm) H1: mesial margin of coronectomy resection line H2: distal margin of coronectomy resection line G1: lowest point of mesial root in plane parallel to coronectomy resection line (H1-H2) G2: lowest point of distal root in plane parallel to coronectomy resection line (H1-H2) E-point: midpoint of coronectomy resection line M-point: midpoint between lowest point of mesial and distal root in plane parallel to coronectomy resection line M3 axis: long axis of lower third molar root passing through M-point and E-point â: angle of x-axis or y-axis and M3 axis

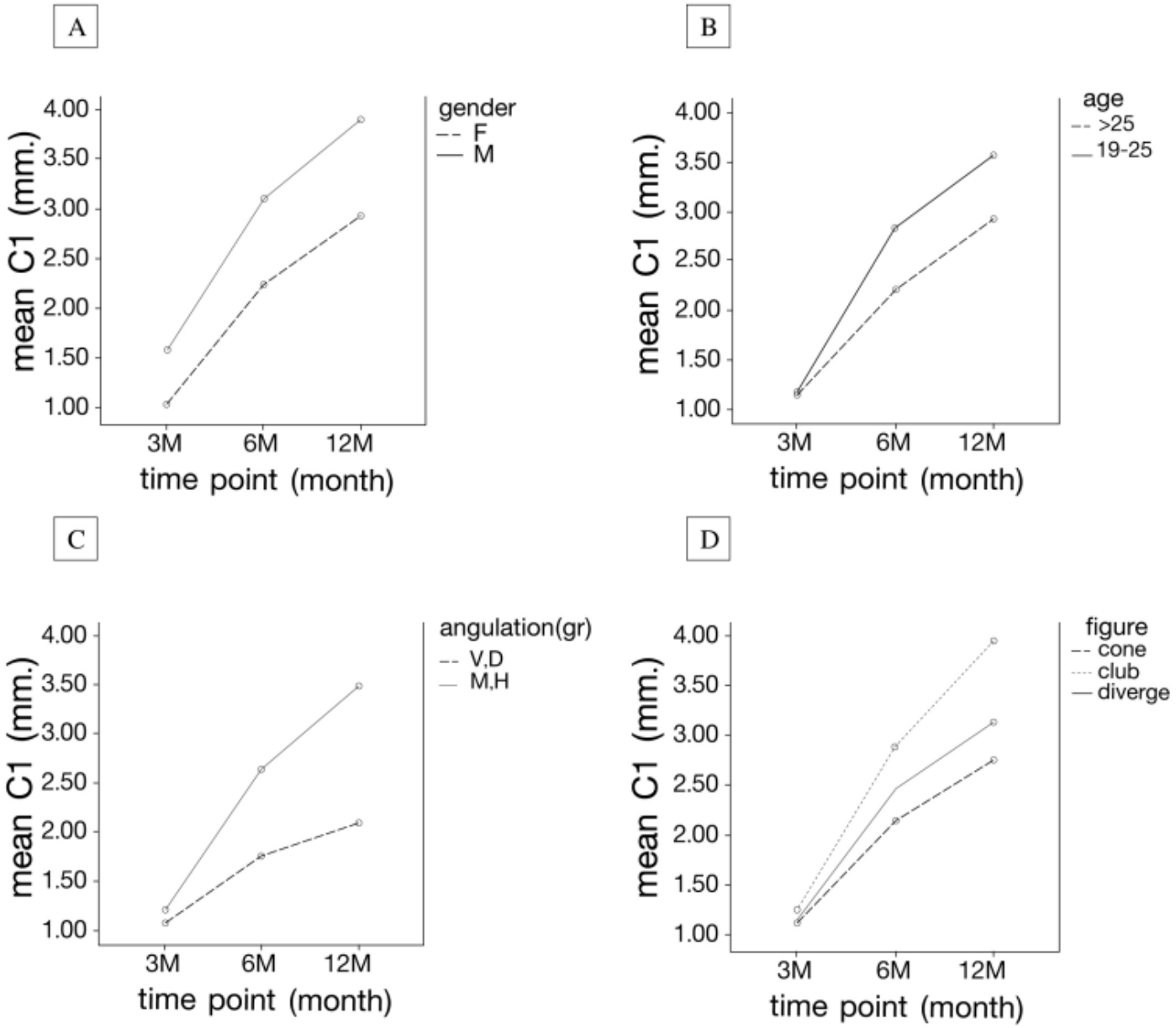

Figure 2

Mean horizontal root migration distance (C1) over follow-up time presented according to different related factors: (A) sex, (B) age, (C) angulation (GEE, P-value = 0.050), and (D) figure of root

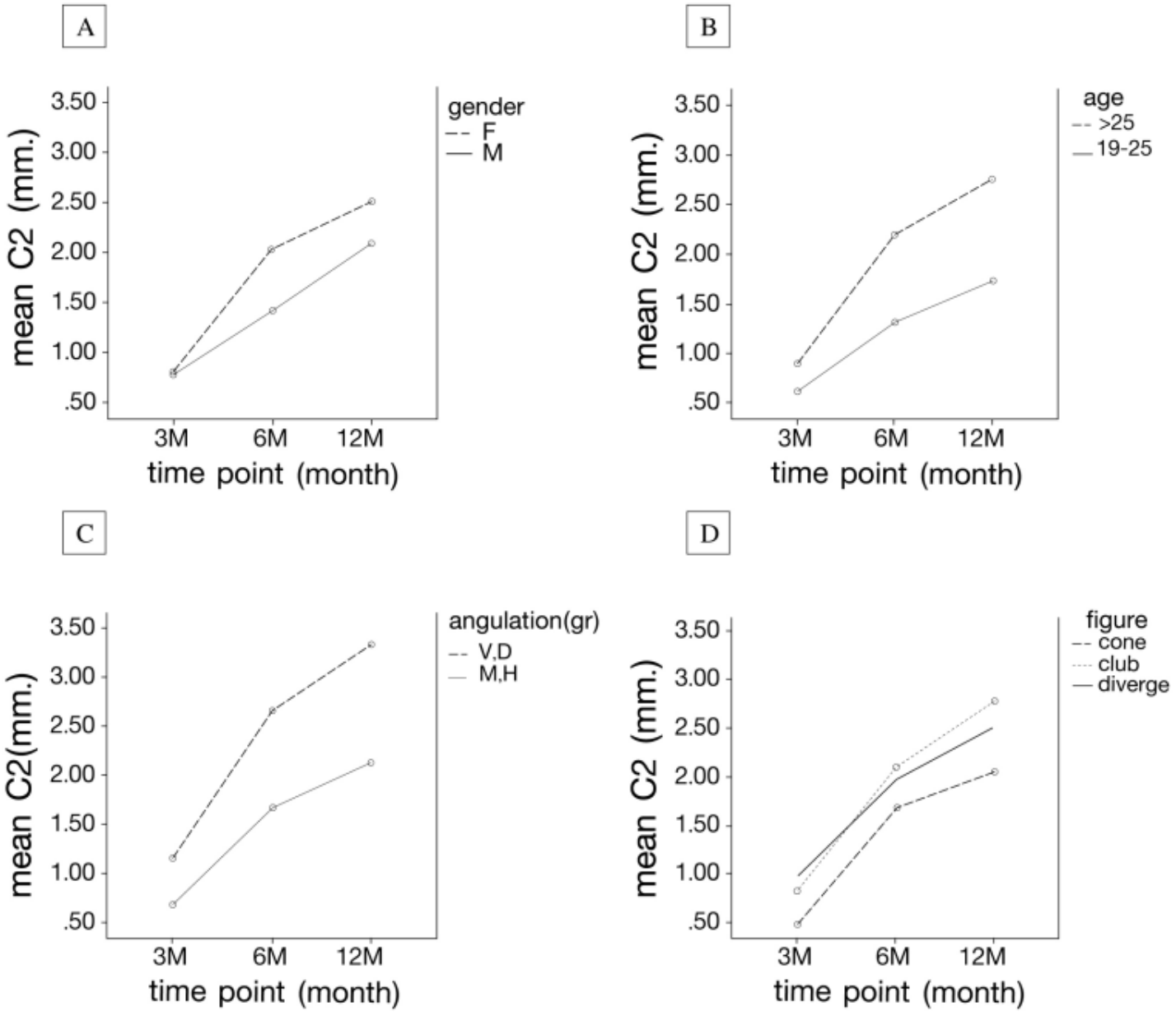

Figure 3

Mean coronal root migration distance (C2) over follow-up time presented according to different related factors: (A) sex, (B) age, (C) angulation (GEE, P-value = 0.003), and (D) figure of root

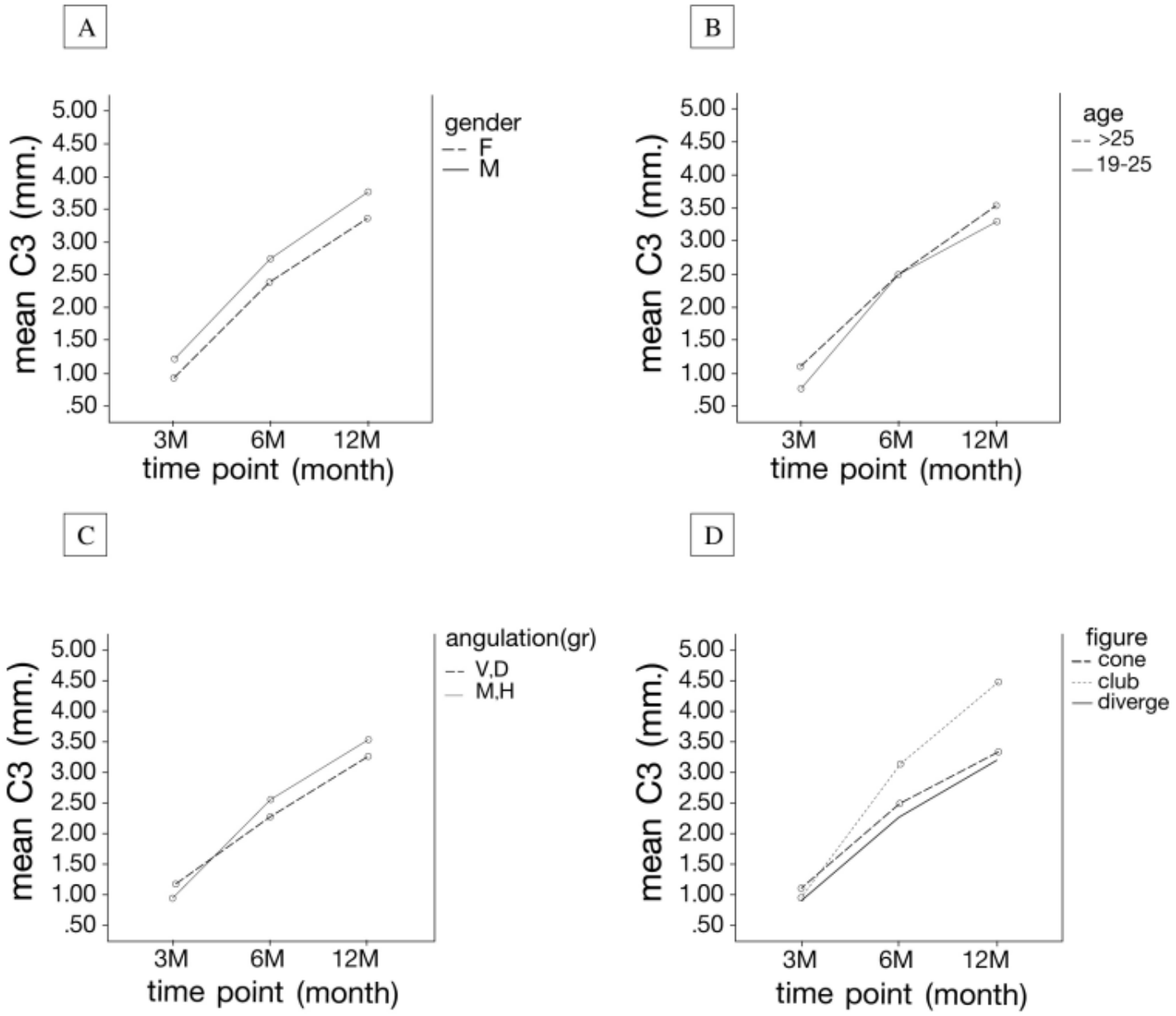

Figure 4

Mean oblique root migration distance (C3) over follow-up time presented according to different related factors: (A) sex, (B) age, (C) angulation, and (D) figure of root

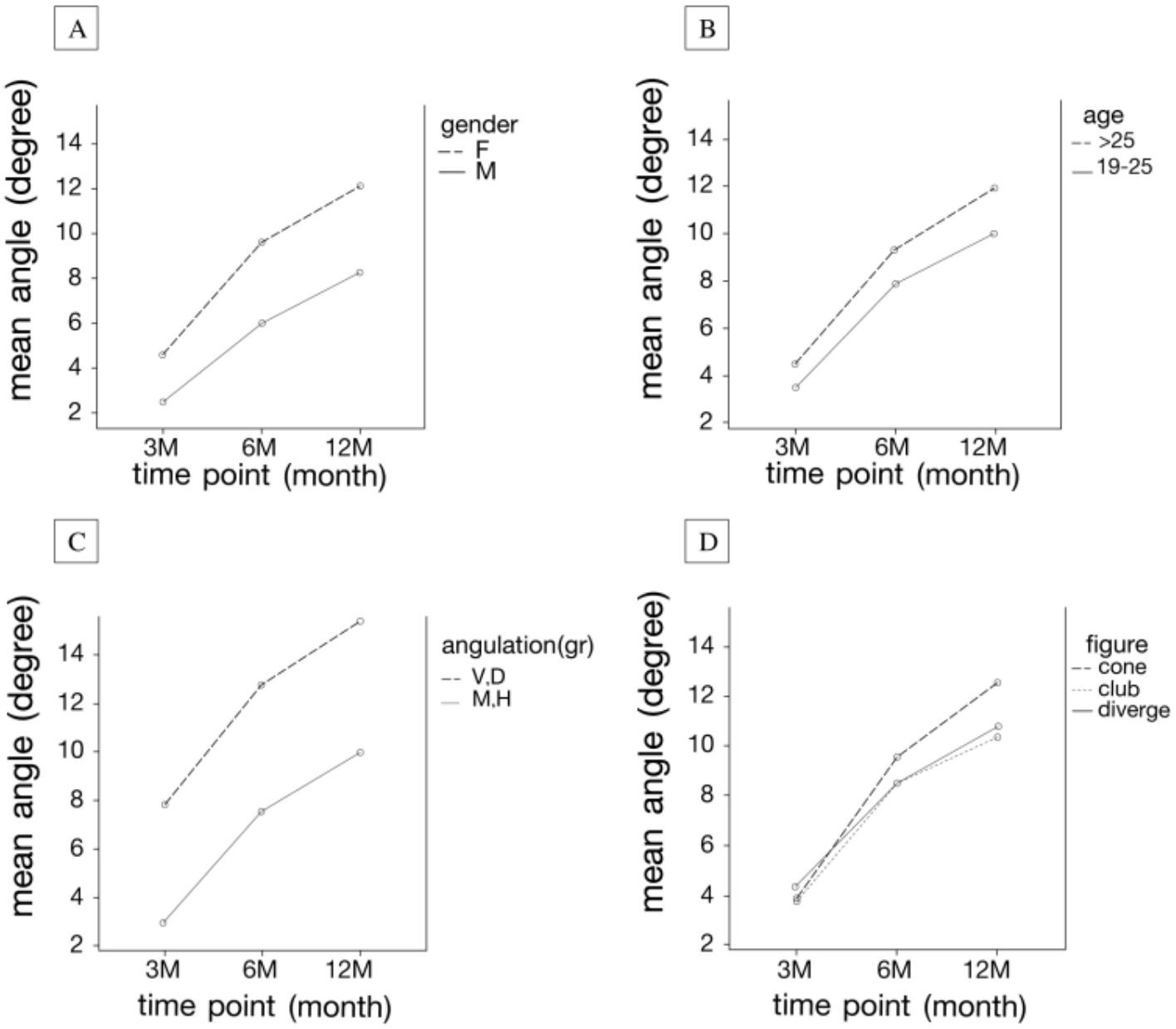

Figure 5

Mean angle of root rotation (â) over follow-up time presented according to different related factors: (A) sex, (B) age, (C) angulation, and (D) figure of root