Whether Evacuation surgery should be the first step for Postoperative Delayed Lumbar Epidural Hematomas?A Retrospective Comparative Study

Liangliang Cao
Zhengzhou Orthopaedic Hospital
Yumei Liu
Fudan University Shanghai Cancer Center
Rundong Guo
Zhengzhou Orthopaedic Hospital
Jianguang Xu
Shanghai Jiao Tong University Affiliated Sixth People's Hospital
Wei Mei (13613711661@163.com)
Zhengzhou Orthopaedic Hospital
Erzhu Yang
Shanghai Jiao Tong University Affiliated Ninth People's Hospital
Xiaofeng Lian
Shanghai Jiao Tong University Affiliated Sixth People's Hospital

Research article

Keywords: lumbar, epidural hematoma, lumbar puncture, evacuation surgery

Posted Date: September 18th, 2019

DOI: https://doi.org/10.21203/rs.2.14569/v1

Abstract

Background To analyze the efficacy and necessity of multiple lumbar punctures for postoperative delayed lumbar epidural hematoma(PDLEH).

Methods Patients who underwent lumbar spinal surgeries between 2012 and 2016 at our institution, were reviewed through their medical records. For patients with PDLEH, the therapies, duration to onset(DO), duration from onset to intervention (DOI), symptoms (ASIA grade), neurological outcomes, VAS before and after treatment were examined. Only patients that received evacuation surgery(Group A) or mutiple lumbar punctures(MLP)(Group B) were included. We compared ASIA grade and VAS before and after treatment, DOI between the two therapies, and analyzed the correlation among the parameters.

Results 15 cases(Group A) were performed with emergent surgical evacuation of the hematoma, and 16 cases(Group B) were treated with lumbar MLP at surgical site. The DOIs were 10.87±6.14h in group A and 2.05±5.33 in group B(P=0,P<0.05.). Preoperative neurological status in Group A were slighter than that in Group B.(P=0,P<0.05.). There was significant difference on VAS after treatment (P=0,P<0.05). Correlation analysis revealed that DOI were significantly positively correlated with neurological state before interventions (r=0.672, p=0,). In Group A, neurological outcomes at 2 years follow-up were correlated significantly with DOI (r=0.594, p=002) and neurological state before reoperation (r=0.665,p=0.007,). And in Group B, the correlation coefficient of neurological state and neurological outcomes at 2 years follow-up was r=o.584 (p=0.02),while there was no correlation between neurological outcomes and DOI(r=0.158,p=0.558).

Conclusions In addition to serving as a timely, minimally invasive treatment, MLP could also serve as a preliminary measure during preoperative preparation before surgical evacuation.

Background

Postoperative lumbar epidural hematoma(PLEH) is a rare but devastating complication following a lumbar spine decompressive surgery, especially for patients with neurological deficit. Most commonly, PLEH presents with rapid neurological deterioration so soon after the primary procedure[1−3] and can be timely identified with typical symptom and treated with emergency surgery[4, 5]. When neurological symptom develops gradually and atypically, usually called postoperative delayed lumbar epidural hematoma(PDLEH), misdiagnosis or delayed treatment will make it irremediable for neurological deterioration[6]. According to the reported researches, PDLEH is a rare emergent clinical condition that causes cauda equina compression and usually presents with sudden onset of back pain at the involved vertebral level, with radiating pain followed by rapidly progressive symptoms and signs of cauda equina compression[7−10]. To the best of our knowledge, combination of confirmation of the exist of epidural hematoma via MRI and surgical evacuation of epidural hematoma is the routine method to treat PDLEH. So MRI is critical for diagnosis treatment of PDLEH, and can reveal the location and extent of the hematoma and the severity of nerve compression. However, owing to some hematocele is frequently demonstrated at surgical site, the rationality of surgical evacuation epidural hematoma to ameliorate neurological deficit and pain is often questioned. In this study, we introduced the mutiple lumbar punctures(MLP) for PDLEH, and demonstrate the rationality of contribution of hematoma in neurological deterioration and escalation therapy in treatment of PDLEH.

Methods

Patients Selection

In our institution, emergent surgical evacuation of hematoma(ESEH) was the routine procedure to manage spinal epidural hematoma. These cases received MLP all persisted their refusal to reoperation. They were fully informed of this treatment and provided consent in medical record. This retrospective study was conducted with the approval of the Ethics Committee of our institution. We reviewed 4254 cases who underwent posterior lumbar spinal laminectomy decompression surgery

with or without interbody fusion in our department over a 4-year period (2012 to 2016) through medical records. The diagnosis of PDLEH in our medical center was made on the onset of sustained severe peri-incisional pain without remission by changing position and use of nonsteroidal antiinflammatory drugs(NSAIDS) more than 3 days after primary surgery, combined with manifestation of hematoma on MRI,with or without development of a new neurological deficit of lower extremities. All the cases included had a clear asymptomatic postoperative period of at least 3 days before the onset of the clinical symptomatology. These patients in accordance with the diagnosis and receiving traditional ESEH were included as Group A. Reviewing the medical record, these cases (Group B) persisting their refusal to reoperation and signing for the decision, as a backup, we performed emergent MLP on them with exclusion of uncorrected coagulopathy. Those patients that underwent conservati*ve* treatment or hybrid treatment were excluded.

Therapeutic Measures

For cases in Group A, during the evacuation operation, the original site of the surgery was reexplored and the clot evacuated. In many cases the hematoma was liquefied and exuded from the wound. Continuous irrigation and drainage technique was used when closed the wound to prevent recurrent DPOSEH[11].

For patients in Group B, lateral decubitus position of symptomatic side was adopted to achieve maximum aggregation of hematoma. The trajectory of needle during MLP needed to be planned seriously on postoperative MRI, as was showed on Fig1, to avoid failed bedside attempt and injury of pertinent anatomy. Entry point should be chosen on the symptomatic side and between the surface projections of screws or zygapophysial joint and lateral margin of dural sac, and the depth of needle between dorsal side and fascia. During operation, the characters including colour and turbidity of paracentesis fluid and reflection of patients including electrical sensation in the corresponding needed intensive observation. This method could also be processed under guidance of ultrasound and CT to improve safety and accuracy.

Postoperative treatment consisted of bed rest and intermittent pneumatic compression devices for all patients after surgery and individual Pharmacological prophylaxis with low molecular heparin for high-risk patients within 3–5 days postoperatively after consultation to cardiologists or thrombosis specialist considering the patients' comorbidities. Bed rest continued until two days after the symptoms improved.

Clinical Datas

The medical history of cases receiving emergency operation（Group A）and MLP(Group B) were recorded, including preoperative and postoperative neurological state of lower limbs and bladder and bowel disfunction(BBD) assessed by ASIA grade, plain radiographs and magnetic resonance imaging (MRI), the average time to onset clinical progression, duration from clinical progression to counter-meassures taking, puncture fluid volume, duration from intervention to remission, neurological outcomes, visual analogue scale(VAS) and complications were reviewed.

Statistical Analysis

The proportion of patients who met criteria was calculated. Independent-samples T test was used for data with normal distribution, and the Mann-Whitney U *for* non-parametric test. As for categorical variables, Pearson chi-square test and Fisher's exact test were used to assess the relationships. Correlations among DOI, neurological state before intervention and neurological outcomes were assessed using Spearman's rank correlation coefficient (r). A p-value less than 0.05 was considered significant. Statistical analyses were conducted with SPSS for Windows, Version 13.0 (SPSS Inc., Chicago, IL, USA), was used for statistical analysis.

Results

33 PDLEH cases were identified, including 15 regressive lumbar spinal stenosis and 8 lumbar disc herniation, 10 degenerative spondylolisthesis. All the cases received posterior lumbar interbody fusion, and had no coagulation disorders. 2 cases were precluded on account of successive adoption of MLP and surgical evacuation. According to medical record,

the interval time between MLP was less than 24h, and symptoms developed after a short catabasis, which indicated massive active bleeding needed to be stop*ped* via surgery. Mean follow-up was 26.4 months postoperatively (range, 25 to 32 months). Among them, 15 cases(Group A) were performed with emergent surgical evacuation of the hematoma, and 16 cases(GroupB) were treated with MLP at surgical site. One single trained surgeon completed these operations.

According to medical histories(*Table1),*, there was no significant statistical difference on patient demographics and baseline characteristics between the two groups(*Table2)*.. Symptoms were observed respectively between 4 and 25 days (mean 10.67±6.61days) and between 3 and 27(mean 10.69±6.67 days)after the original surgery in Group A and Group B, and the difference was not significant. The duration from onset to intervention(DOI) were 10.87±6.14h in group A and 2.05±5.33 in group B. Comparing the DOI and nuerological state before reoperation or MLP, the difference was significant(P = 0,P□0.05.) All the patients in group A presented with paralysis on lower extremity or perineal area, and 40% cases with BBD compared with 18.75% in Group B, but they all received emergency surgery in 24 hours. And postoperatively, some cases got a certain degree of neurological improvement and most got complete radicular symptom reli*ef.* Most of cases in Group B got timely(□3h) MLP, and immediate symptomatic relie*f,* especially for peri-incisinal pain and radicular symptoms. As shown in Table 1, case 20, showing weakness in her dorsiflexion of foot graded 0/5, got an immediate myodynamia improvement graded 3/5 at first puncture, and achieved neurological recovery 1 month later. Cases 23, who presented with severe peri-incisional pain and had discharged, received timely MLP via visiting medical service, while case 24 who felt left leg weakness after strolling outside failed receiving timely treatment owing to duration neglect of severity until complaining of difficulty in urinating, and resulted sequelae in spite of some remission. There was no significant difference between two groups on ASIA assessment at 2 years follow-up(P = 0.599,P□0.05) and VAS at onset,(P = 0.571,P□0.05)□but there was significant difference on VAS after treatment. The VAS in Group A was higher, which was linked mainly to incision pain(P = 0,P□0.05). All the patients in two groups got improvement in symptoms including paralysis, pain at surgical site or lower extremity and BBD at last follow-up. No patients got nerve injury or positive cultures for paracentesis fluid in Group B.

Correlation analysis revealed that DOI were significantly positively correlated with neurological state before intervention (r = 0.672, p = 0,). In Group A, neurological outcomes at 2 years follow-up were correlated significantly with DOI (r = 0.594, p = 002,) and neurological state before reoperation (r = 0.665,p = 0.007,). And in Group B, the correlation coefficient of neurological state and neurological outcomes at 2 years follow-up was r = o.584 (p = 0.02),while there was no correlation between neurological outcomes and DOI(r = 0.158,p = 0.558).

Discussion

In our medical center, patients discharged with wound healing, usually 2 weeks. Most of these cases received intact observation of PDLEH. The onset of sharp peri-incisional pain in most patients was *generally* the initial symptom. The characters of pain *were* different from postoperative incisive pain, which could not be relieved by using analgesics. After an interval, depending on the seepage velocity and quantity, dysesthesias, radicular symptoms and finally motor weakness of lower limb and even BBD followed[12, 13]. According to the reported researches, the diagnosis of PDLEH was made based on the development of a new neurological deficit in the distribution of the spinal cord or a nerve root of surgical site combined with the presence of a epidural hematoma seen on MRI[3, 8, 14]. Considering of the complex symptoms of delayed lumbar epidural hematoma, which presents paralysis, unbearable pain and BBD, the diagnostic basis in our medical center is the presence of severe sustained pain at surgical site or lower limbs without remission by changing position and use of nonsteroidal antiinflammatory drugs(NSAIDS) after a asymptomatic period of more than 3 days after surgery, with or without development of a new neurological deficit of lower extremities and bladder and bowel. The MRI was needed to confirm the presence of epidural hematoma, especially for these cases with only sever*e* back pain to exclude subcutaneous hematoma. Emergency surgical evacuation of epidural hematoma is the main treatment way to cope with this situation[8, 9, 15, 16]. However, it is frequently questioned *with* the contribution of epidural hematoma to pain or new neurological deficit after surgery. Owing to the demonstration of blood at surgical site on postoperative imaging, clinicians often perform emergent operation with hesitation, specially for the cases with slight neurological symptom. This is why the

symptoms in Group A were severer than that in Group B, DOI in Group A higher than that in Group B. In addition, *despite the fact that* discrete source of bleeding could be identified in most of acute postoperative spinal epidural hematoma, only not more than 30% cases were like this, which conformed to cases in group A[8, 12]. In many cases in group A, hematoma was liquefied, and apart from blood clot, a mass of turbid fluid existed, which was also reported in previous study[13]. And according to the previous study, some blood existed in the postoperative imaging, and hematomas resolved approximately one month after onset in conservatively treated cases on MRI, thus indicating that hematoma might not be evacuated clearly and evacuating these liquid also could realize decompression[17].

As a minimally invasive method, MLP was not only able to provide immediate intervention, but also demonstrated the rationality of evacuation of liquefied hematoma to release the neurological deficit, when seeing the immediate remission of pain or improvement of neurological state in cases in group B. This article revealed that neurological state progressed as DOI increased, and pre-reoperative neurological status generally predicted outcomes, even patients with complete neurologic deficits achieved better functional neurologic recovery when decompression was performed within 24h[6, 18]. The good remission rate of this study exactly resulted from timely treatment. Most of cases in group B could achieve an immediate remission of peri-incisional or radicular pain, but it was not for myodynamia and BBD improvement, usually 1 month later except Case 20. Compared with the cases in group B, all the cases in group A needed to experience at least 6h preoperative preparation, this time might be longer for discharged patients in other medical center[8, 12, 14]. In addition, to avoid bad preoperative neurological status, combined with presentation of epidural hematoma on MRI, these clinical entities with only sharp peri-incisional pain conformed to inclusion criteria also received MLP to arrest progression of neurological disfunction according to the pathogenetic process, and obtained immediate remission after intention. This was the reason why the rate of PDLEH in our study, about 0.78%, is slightly higher than previous studes[7, 9, 10, 19, 20]. Beyon*d* that, for those patient*s* with rapid neurological progression, MLP still could be a preliminary decompression measure during preparation for emergent surgery. So, MLP might be the first step for patients with the diagnosis of PDLEH(*Fig.2)*.. Considering the better recovery rate and less recover*y* time, in our medical center, patients in the last year of this study preferred to receive MLP to resolve their problem.

The duration to the onset of PDLEH suggests surgeons should maintain vigilance against any recurrence of clinical symptoms even up to 4 weeks after primary surgery, specially for new onset of sharp back or lower extremities. Owing to paracentesis around dural sac, intensive observation is necessary to avoid nerve injury including radicular lower limbs pain or dural laceration. The lateral margin of the superior facet or screw could be the reference for a safe puncture. In addition, rigid aseptic principle is prerequisite. No cases experienced iatrogenic infection or nerve injury in our study.

Our study has some limitations. Because of low incidence, the patient sample size was small, and considering of the retrospective analysis, potential selection bias is inevitable. The objective rationality of MLP is incomplete including whether the pressure inside is controlled under “safe margin” and what “safe margin”is, although symptomatic and subjective remission indicate safe pressure, and it still needs to be clarified in our future study.

Conclusions

In this study, MLP demonstrates an advantage in terms of timeliness and effectiveness, and as a simple, minimally invasive method, it also provides decisiveness for clinicians to take timely theorepic measures to avoid progressive symptom. However, for the cases with large amount of fluid consecutively more than 100ml by two punctures in two days, or remission interval less than 12h, emergency surgery is suggested for incision exploration and hemostasis. Nonetheless, as a simple decompression method, MLP still could be a way during preoperative preparation prior to surgical evacuation, and should be the first step to treat with PDLEH.

Abbreviations

Mutiple lumbar punctures(MLP)

Postoperative delayed lumbar epidural hematoma(PDLEH)

Postoperative lumbar epidural hematoma(PLEH)

Emergent surgical evacuation of hematoma(ESEH)

Duration to onset(DO)

Duration from onset to intervention (DOI)

Nonsteroidal antiinflammatory drugs(NSAIDS)

Bladder and bowel disfunction(BBD)

Declarations

Ethics approval and consent to participate

The study was approved by Ethics Committee of Shanghai Sixth People's Hospital . Written informed consents were available, and participants involved gave their consents for the use of the anonymised data including demographic data and MRI data.

Concent for publication

The manuscript is approved by all contributors for publication, and participants gave informed consent for publication.

Availability of data and materials

Data is available from the corresponding author upon any reasonable request.

Competing interests

All other authors declare that they have no competing interests.

Funding

No funding was obtained for this study.

Authors' contributions

LLC and YML were the major contributors in writing the manuscript. WM performed these operations and treatmens. LLC, YML and XTL performed the data collection and analysis. The collected data was discussed with RDG,JGX and WM. WM,

XFL and EZY supported the structuring of the manuscript and helped to finalise the manuscript. All authors read and approved the final manuscript.

Contributor Information

Liangliang Cao, caoliangliang1990@126.com

Yumei Liu, 14211230012@fudan.edu.cn

Rundong Guo, grd13803993300@163.com

Xiaofeng Lian, xf909@126.com

Erzhu Yang, yangerzhu2012@163.com

Jianguang Xu, xjgn6spine @126.com

Wei Mei, 13613711661 @163.com

Acknowledgements:

Not applicable.

References

1.Kim, J. E., et al., *Risk Factors of Postoperative Spinal Epidural Hematoma After Biportal Endoscopic Spinal Surgery.* World Neurosurg, 2019. *129:* p. e324-e329.

2.Yin, G. and B. Ni, *Acute postoperative cervical spinal epidural hematoma.* Acta Orthop Traumatol Turc, 2014. *48(*4): p. 437–42.

3.Yu, J., et al., *Retrospective analysis of 14 cases of remote epidural hematoma as a postoperative complication after intracranial tumor resection.* World J Surg Oncol, 2016. *14(*1): p. 1.

4.Shen, J., et al., *Surgery for contralateral acute epidural hematoma following acute subdural hematoma evacuation: five new cases and a short literature review.* Acta Neurochir (Wien), 2013. *155(*2): p. 335–41.

5.Su, T.-M., et al., *Contralateral Acute Epidural Hematoma After Decompressive Surgery of Acute Subdural Hematoma: Clinical Features and Outcome.* The Journal of Trauma: Injury, Infection, and Critical Care, 2008. *65(*6): p. 1298–1302.

6.Lawton. MT, P. R., Heiserman. J, *Surgical management of spinal epidural hematoma relationship between surgical timing and neurological outcome.* J Neurosurg, 1995. *83(*1): p. 1–7.

7.Anno, M., et al., *The Incidence, Clinical Features, and a Comparison Between Early and Delayed Onset of Postoperative Spinal Epidural Hematoma.* Spine, 2019. *44(*6): p. 420–423.

8.Kanematsu, R., et al., *Radiologic Features and Clinical Course of Chronic Spinal Epidural Hematoma: Report of 4 Cases and Literature Review.* World Neurosurg, 2018. *120:* p. 82–89.

9.Amiri, A. R., et al., *Postoperative spinal epidural hematoma (SEH): incidence, risk factors, onset, and management.* Spine J, 2013. *13(*2): p. 134–40.

10.Aono H, O. T., Hosono N, *Incidence of postoperative symptomatic epidural hematoma in spinal decompression surgery.* J Neurosurg Spine, 2011. *15(*2): p. 202–205.

11.Lian XF, X. J., Zeng BF, *Continuous irrigation and drainage for early postoperative deep wound infection after posterior instrumented spinal fusion.* J Spinal Disord Tech, 2014. *27(*8): p. 315–7.

12.Scavarda, D., et al., *Postoperative spinal extradural hematomas. 14 cases.* Neurochirurgie, 1997. *43(*4): p. 220–7.

13.Juan Uribe, K. M., Omar Jimenez,el, *Delayed postoperative spinal epidural hematomas.* The Spine Journal, 2003. *3(*2): p. 125–129.

14.Solheim O, J. J., Nygaard OP., *Lumbar epidural hematoma after chiropractic manipulation for lower-back pain: case report.* Neurosurgery, 2007. *61(*1): p. 170–1.

15.Rodriguez y Baena, R., et al., *Spinal epidural hematoma during anticoagulant therapy. A case report and review of the literature.* J Neurosurg Sci, 1995. *39(*1): p. 87–94.

16.Heyun Sung Kim, S. K. L., el, *Chronic Spinal Epidural Hematoma Related to Kummell's Disease.* J Korean Neurosurg Soc 2011. *49:* p. 2231–233.

17.Nagata, K., et al., *Consecutive images of conservatively treated cervical spontaneous spinal epidural hematoma.* J Clin Neurosci, 2019. *59:* p. 270–275.

18.Baron, H. C., et al., *Continuous epidural analgesia in the heparinized vascular surgical patient: a retrospective review of 912 patients.* J Vasc Surg, 1987. *6(*2): p. 144–6.

19.Lillemae, K., et al., *Incidence of Postoperative Hematomas Requiring Surgical Treatment in Neurosurgery: A Retrospective Observational Study.* World Neurosurg, 2017. *108:* p. 491–497.

20.Fujita, N., et al., *Impact of lumbar hypolordosis on the incidence of symptomatic postoperative spinal epidural hematoma after decompression surgery for lumbar spinal canal stenosis.* Eur Spine J, 2019. *28(*1): p. 87–93.

Tables

Table 1. Clinical parameters from medical records

		Year	Age	Gender	Symptoms			DO (days)	DOI (hours)	ASIA (Onset)	PLW	VAS (onset/after intervention)	ASIA (At 2 years)
					Paralysis	Pain	BBD						
	Case1	2016	55	F	+	+	+	8	7.9	B	/	8\6	E
	Case2	2016	64	M	+	+	+	12	16.7	A	/	8\5	D
	Case3	2016	63	F	+	-	-	5	8	D	/	4\5	E
	Case4	2016	72	F	+	+	-	6	7	C	/	8\5	E
	Case5	2017	58	F	+	+	-	6	7.5	C	/	8\3	E
	Case6	2017	67	M	+	+	-	13	6.5	C	/	8\5	E
	Case7	2017	75	F	+	+	+	14	13	B	/	8\3	E
A	Case8	2017	73	M	+	-	+	5	12.5	B	/	5\5	D
	Case9	2017	69	M	+	+	-	13	7.5	C	/	8\3	E
	Case10	2017	67	F	+	+	-	15	7.2	D	/	8\6	E
	Case11	2017	71	F	+	-	+	23	18.2	B	/	4\6	E
	Case12	2017	76	M	+	+	+	25	28.5	A	/	8\3	C
	Case13	2017	68	F	+	+	-	4	8	D	/	8\5	E
	Case14	2017	66	F	+	+	-	5	7	C	/	8\5	E
	Case15	2018	70	F	+	+	-	6	7.5	D	/	8\3	E
	Case16	2017	59	M	+	+	-	13	0.3	D	40/20/10/5	8\3	E
	Case17	2017	71	F	+	-	+	16	4.5	B	60/45/35/25/10/5	5\2	E
	Case18	2017	68	M	+	-	-	6	0.2	D	30/15/5	3\2	E
	Case19	2017	63	M	+	+	-	4	0.5	D	35/15/5	8\3	E
	Case20	2018	73	M	+	-	-	3	0.3	C	40/35/30/20/10/5	5\3	E
	Case21	2018	72	F	-	+	-	14	0.3	E	35/15/5	8\3	E
	Case22	2018	62	F	+	+	+	13	0.2	B	100/70/50/35/15/5	8\3	D
	Case23	2018	69	M	-	+	-	26	3.2	E	50/35/15/5	8\3	E
B	Case24	2018	68	F	+	-	+	21	21.5	B	50/30/15/5	5\2	C
	Case25	2018	70	F	+	+	-	5	0.3	D	25/15/5	8\3	E
	Case26	2018	66	M	-	+	-	4	0.1	E	30/20/5	8\3	E
	Case27	2018	72	M	+	+	-	7	0.2	D	35/25/10/5	8\3	E
	Case28	2018	74	F	+	+	-	6	0.5	D	40/30/15/5	8\3	E
	Case29	2018	67	F	-	+	-	13	0.3	E	45/30/15/5	8\3	E
	Case30	2018	61	F	+	-	-	14	0.2	E	35/20/10/5	5\2	E
	Case31	2018	72	M	-	+	-	6	0.2	E	40/25/10/5	8\3	E

BBD= bladder and bowel disfunction, DO=duration from onset, DOI= duration from onset to intervention,PLW= Puncture fluid volume

Table 2: baseline characteristics and statistic analysis

	Group A 15 Patients)	Group B 16 Patients)	P Value
Age (yr)	67.9	67.6	0.895*
Female/Male	10/5	8/8	0.347&
DOI(hours)	2.05±5.33	10.87±6.14	0
DO(day)	10.67±6.61	10.69±6.67	0.968*
ASIA(onset) A/B/C/D/E	2/4/5/4/0	0/3/1/6/6	0.005#
VAS(onset)	7.27±1.53	6.97±1.69	0.571#
ASIA(2 years) A/B/C/D/E	0/0/1/2/12	0/0/1/1/14	0.599#
VAS(after intervention)	4.53±1.19	2.75±0.45	0#

* The p values were determined with the T test. # The p values were determined with the Mann-Whitney U test. &The p values were determined with the chi-square test

Figures

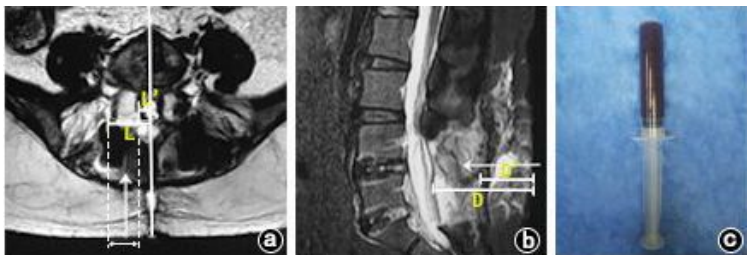

Figure 1

The journey of a needle during LP (a and b) and puncture fluid (c). With perpendicular direction, needle (white arrow) should lacate between lateral margin of thecal sac and screws in coronal plan- usually 1.5-2.0cm from middle line, and between thecal sac and lumbodorsal fascia in sagittal plan (b). The character of hematoma-suspension(c) is obviously different from cerebrospinal fluid and needs intensive observation during operation.

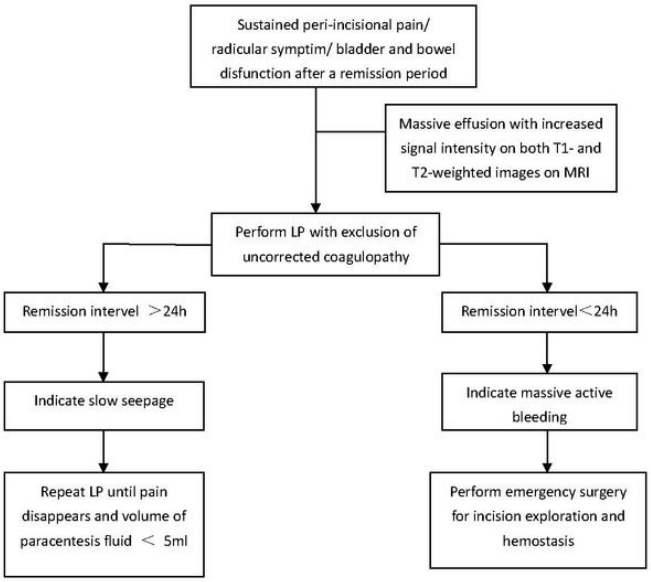

Figure 2

Recommended steps for treatment of postoperative delayed lumbar epidural hematoma.