Comparative analysis of clinical factors associated with pedicle screw pull-out between intraoperative cone-beam computed tomography and postoperative computed tomography

Satoshi Sumiya (sumiya.orth.7077@gmail.com)
Saku Central Hospital Advanced Care Center https://orcid.org/0000-0002-2700-9860

Kazuyuki Fukushima
Saku Central Hospital Advanced Care Center

Yoshiro Kurosa
Saku Central Hospital Advanced Care Center

Takashi Hirai
Tokyo Medical and Dental University

Hiroyuki Inose
Tokyo Medical and Dental University

Toshitaka Yoshii
Tokyo Medical and Dental University

Atsushi Okawa
Tokyo Medical and Dental University

Research article

Keywords: Pedicle screw pull-out, cone-beam computed tomography (CBCT), Diffuse Idiopathic Skeletal Hyperostosis (DISH), applying the connecting rod

Posted Date: August 18th, 2020

DOI: https://doi.org/10.21203/rs.3.rs-52538/v1

Version of Record: A version of this preprint was published on January 9th, 2021. See the published version at https://doi.org/10.1186/s12891-020-03916-9.

Abstract

Background

No studies to date have elucidated the clinical factors associated with pedicle screw pull-out. The aim of this study was to assess the frequency of pedicle screw pull-out by comparing intraoperative scans obtained using cone-beam computed tomography (CBCT) with scans acquired postoperatively using computed tomography (CT). We also sought to determine the incidence of pedicle screw pull-out and identify relevant risk factors.

Methods

This was a retrospective analysis of prospectively collected data for 636 pedicle screws placed in 66 consecutive patients who underwent at least triple-level posterior fixation of the thoracic or lumbar spine between April 2014 and March 2020. Pedicle screw pull-out distance in the axial and sagittal planes was compared between CT scans obtained 2 days postoperatively and CBCT images acquired intraoperatively. The risk factors associated with pedicle screw pull-out were investigated by multivariate logistic regression analysis.

Results

Pedicle screw pull-out was seen with 17 pedicle screws (2.7%) in 13 (19.7%) patients. There were significant differences in age, number of fused segments, frequency of diffuse idiopathic skeletal hyperostosis (DISH), presence of osteoporosis, and advanced elderly medical service system insurance for pedicle screw pull-out. Risk factors for pedicle screw pull-out were older age (odds ratio 1.15, 95% confidence interval 1.04–1.272) and a diagnosis of DISH (odds ratio 6.10, 95% confidence interval, 1.23–30.20).

Conclusions

Several cases of intraoperative pedicle screw pull-out may be caused by use of connecting rods. Older age and DISH are risk factors for pedicle screw pull-out.

Background

Many authors have described the efficacy of posterior pedicle screw instrumentation[1, 2], which is widely used in patients with spinal diseases. In recent years, the use of long instrumented fusion using pedicle screw has increased in patients with trauma, degenerative diseases and deformity. However, pedicle screw insertion may not only cause serious complications such as neurovascular injury due to

misplacement[3, 4], but also cause delayed complication such as screw loosening. These are associated with neurological impairment, back pain, neuropathy, non-union, and correction loss[4, 5].

Nowadays, many institutions can perform spinal instrumentation surgery using intraoperative cone beam computed tomography (CBCT) in a hybrid operating room[6, 7]or an O-arm imaging system (Medtronic, Minneapolis, MN)[8, 9]. CBCT is a three-dimensional (3D) imaging tool that reconstructs projection data by a rotational C-arm with a flat panel detector[7]. It can visualize low-contrast objects, such as soft tissue or small vessels, as well as high-contrast structures, including enhanced vessels or bone. Several authors have reported the utility of CBCT[6, 7], and thus it is being increasingly used in spine surgeries. The recent advent of a 3D-CT-based navigation system for intraoperative CBCT has improved the accuracy of pedicle screw insertion. Further, intraoperative CBCT has made it possible to confirm the presence or absence of screw deviation during surgery.

Long instrumented fusion requires insertion of a large number of pedicle screws, and the above-mentioned intraoperative modalities help to ensure surgical safety. The position of the pedicle screws can be confirmed using intraoperative CBCT in a hybrid operating room after pedicle screw insertion before rod connection. We have encountered several cases of intraoperative pedicle screw pull-out as a result of rod connection during posterior thoracic or lumbar spine surgery. In long instrumented fusion especially, pedicle screw pull-out was found to be a risk factor for pedicle screw loosening[10]. It is reported that pedicle screw pull-out can occur during, but not after, surgery[10, 11].

A previous study investigated the percutaneous pedicle screw (PPS) pull-out during rod reduction and reported its association with screw loosening. However, the clinical factors associated with pedicle screw pull-out have not been elucidated.

Hence, in this study, we investigated the frequency of pedicle screw pull-out by comparing intraoperative CBCT images and postoperative CT images acquired 2 days after surgery. We also sought to identify and evaluate the relevant risk factors for screw pull-out.

Materials And Methods

This study was approved by the Institutional Ethics Committee (Approval No. R201904-06). In this study, we conducted a retrospective analysis of prospectively collected data from 66 consecutive patients who underwent long posterior spinal instrumented fixation at 3 levels or more for thoracic or lumbar spinal injury, spinal metastasis, or pyogenic spondylitis between April 2014 and March 2020. The patients were evaluated using CBCT intraoperatively in a hybrid operating room. Evaluation by CT was performed again on postoperative day 2 before mobilization. Demographic and surgical data collected included age, sex, BMI, operating time, estimated blood loss, underlying disease, number of fused segments, use of a Hook system, PPS insertion, presence of diffuse idiopathic skeletal hyperostosis (DISH), medical history of osteoporosis, smoking, type of health insurance cover, and preoperative comorbidities.

Surgical procedure

All patients underwent posterior spinal fixation in the prone position with the trunk on a radiolucent operating table in a hybrid operating room. Following anesthesia, standard surgical exposure was performed via a midline skin incision using an open approach. PPS placement was performed via a 1.5-cm stab incision made laterally. The targeting needle was inserted into the pedicle at the superolateral border based on the anterior-posterior view under rotational C-arm fluoroscopic guidance. The guidewire was inserted through the targeting device and into the pedicle. The pedicle was then tapped using the guidewire. Next, the pedicle screw was inserted over the guidewire. CBCT images were obtained at this timing to confirm the screw position. Finally, rods were installed aligned to each screw placed in the open surgery and were inserted starting from the most cranial skin incision in the PPS surgery. The order in which the set-screws were installed varied among the operators(Fig. 1). A Solera Voyager spinal system (Medtronic, Memphis, TN) or Reline spinal system (NuVasive, San Diego, CA) was used for posterior spinal fixation.

Evaluation of screw position

In all cases, the implant position was assessed intraoperatively using CBCT scans obtained using a DynaCT system (Artis Zeego; Siemens Healthcare, Erlangen, Germany), a 3D imaging tool that reconstructs projection data obtained by a rotational C-arm with a flat panel detector. The series consisted of 0.616-mm CBCT sections reconstructed at 0.616-mm intervals. Raw data were used to reconstruct axial 2.0 mm-thick CBCT sections every 2.0 mm with a field of view adequate for visualization of the spine, as well as sagittal and coronal reformat images of the thoracolumbar spine. The position of the implant was assessed postoperatively on CT scans obtained using a 320-row area-detector CT system (Toshiba Medical Systems, Tokyo, Japan). The series consisted of 0.5-mm-thick CT sections reconstructed at 0.5-mm intervals. Raw data were reconstructed with 2.0 mm-thick axial CT sections every 2.0 mm with a field of view that was adequate for spine visualization and for sagittal and coronal reconstruction of the thoracolumbar spine.

Screw misplacement was classified according to the system devised by Schizas et al.[12]. Screw malposition was categorized as minor (< 3 mm), moderate (3–6 mm), or severe (> 6 mm) and the direction of perforation was classified as medial or lateral. Screw pull-out distances measured in the axial and sagittal planes on CT scans obtained 2 days postoperatively were compared with those on intraoperative CBCT images by two independent observers. Screw pull-out was defined as a distance of more than 4 mm change in the axial and sagittal views on postoperative CT compared with the position on the intraoperative CBCT views (Fig. 2). Data were also compared between the cases with screw pull-out and cases without screw pull-out. Risk factors for pedicle screw pull-out were identified by multivariate analysis.

Statistical analysis

Statistical analysis was performed using Fisher's exact test and the Mann-Whitney *U* test, with statistical significance set at $P < 0.05$. Risk factors were determined using logistic regression analysis with a

forward stepwise procedure (P < 0.1 for entry). The threshold of alpha and forward selection was chosen to stabilize the statistical model during stepwise covariate selection considering the relatively small number of our outcomes. Inter-observer agreement was measured using kappa coefficient scores. Any discrepancy between the observers was resolved by discussion. All statistical analysis was performed using JMP version 13.1.0 software (SAS Institute Inc., Cary, NC).

Results

A total of 636 pedicle screws were inserted in the thoracic or lumbar spine of the 66 patients. Patient demographics are shown in Table 1. Mean age of the 40 men and 26 women was 68.6 ± 14.8 years (range, 25–93 years) and mean BMI was 22.2 ± 3.3. Mean operating time was 174.9 ± 83.9 min and mean estimated blood loss was 219.5 ± 252.2 g. The diagnosis was spinal injury in 47 cases (71.2%), spinal metastasis in 14 (21.2%), and pyogenic spondylitis in 5 (7.6%). Mean number of fused segments was 4.8 ± 1.3. A hook system was used in 5 cases (7.6%) and the PPS method in 47 cases (71.2%). Eleven patients (16.7%) were smokers. Other diagnoses included DISH (n = 22, 33.3%), osteoporosis (n = 27, 40.9%), rheumatoid arthritis (n = 2, 3.0%), diabetes (n = 13, 19.7%), and asthma (n = 6, 9.1%). Two patients (3.0%) were on dialysis. Twenty-two patients (33.3%) were covered by national health insurance, 10 by employees' pension insurance (15.2%), 25 (37.9%) by the advanced elderly medical service system, 7 (10.6%) by workers' accident compensation insurance, and 2 (3.0%) by livelihood subsidies public assistance.

Table 1
Patient demographics and clinical details

Variable	N = 66
Patients with pedicle screw pullout	13 (19.7)
Age, years	68.6 ± 14.8
Sex	40 (60.6)
Male	26 (39.4)
Female	
Body mass index	22.2 ± 3.3
Operating time, min	174.9 ± 83.9
Estimated blood loss, mL	219.5 ± 252.2
Disease	47 (71.2)
Injury	14 (21.2)
Metastasis	5 (7.6)
Spondylitis	
Segments fused, n	4.8 ± 1.3
Surgical procedure	47 (71.2)
PPS	19 (28.8)
Open	
Use of a hook system	5 (7.6)
Preoperative complications	22 (33.3)
DISH	27 (40.9)
Osteoporosis	2 (3.0)
Rheumatoid arthritis	13 (19.7)
Diabetes	6 (9.1)
Asthma	2 (3.0)
Requirement for dialysis	
Smoking	11 (16.7)

Variable	N = 66
Type of health insurance	22 (33.3)
National health	10 (15.2)
Employees’ pension	25 (37.9)
Advanced elderly medical service system	7 (10.6)
Industrial injury insurance workers' accident compensation	2 (3.0)
Livelihood subsidies public assistance	
Data are presented as mean ± standard deviation or as number (%). DISH, diffuse idiopathic skeletal hyperostosis; PPS, percutaneous pedicle screw	

Screw pull-out occurred for 17 of the 636 pedicle screws (2.7%) inserted, in 13 of the 66 patients (19.7%). For almost all cases of pull-out, insertion had been via PPS. The pedicle screw-related variables are shown in Table 2. Twenty-eight of the pedicle screws (4.4%) were found to be misplaced on the postoperative CT views. Sub-classification analysis revealed minor perforation of 14 screws (2.2%), moderate perforation of 8 screws (1.3%), and severe perforation of 6 screws (0.9%). Both pull-out and misplacement occurred with 2 screws (0.3%). Pull-out screws were observed in the upper instrumented vertebra in 3 cases (17.6%), in the lower instrumented vertebra in 6 (35.3%), and in the inter-levels in 8 (47.1%; Fig. 3). There was substantial inter-observer agreement in judging screw pull-out distance (κ = 0.79). All values indicated substantial agreement.

Table 2
Pedicle screw-related variables

Variable	N = 636
Adequate insertion	608 (95.6)
Misplacement	28 (4.4)
Penetration	14 (2.2)
Minor	8 (1.3)
Moderate	6 (0.9)
Severe	
Pedicle screw pull-out	17 (2.7)
Pedicle screw pull-out and misplacement	2 (0.3)
Pull-out area	3 (17.6)
Upper instrumented vertebra	8 (47.1)
Inter-levels	6 (35.3)
Lower instrumented vertebra	
Data are presented as number (%)	

There was no significant difference in sex, BMI, operating time, estimated blood loss, underlying disease, surgical procedure, or smoking status between the non-pull-out and pull-out group. Patients in the pull-out group were more likely to be elderly, have more fused segments, have a diagnosis of DISH or osteoporosis, and have advanced elderly medical service system insurance cover (Table 3).

Table 3
Comparison of the screw pull-out group and the normal group

Variable	Non-pull-out group	Pull-out group	P-value
Patients	53 (80.3%)	13 (19.7%)	
Age, years	65.3 ± 14.5	81.9 ± 5.7	P = 0.0001*
Sex	32	8	P = 1.00
Male	21	5	P = 1.00
Female			
Body mass index	22.1 ± 3.5	22.6 ± 2.5	P = 0.40
Operating time, min	169.2 ± 81.1	198.2 ± 94.6	P = 0.32
Estimated blood loss, g	234.8 ± 261.9	157.3 ± 205.1	P = 0.055
Disease	37	10	P = 0.74
Injury	11	3	P = 1.00
Metastasis	5	0	P = 1.00
Spondylitis			
Fused segments, n	4.6 ± 1.4	5.4 ± 0.9	P = 0.0199*
Surgical procedure	35	12	P = 0.088
PPS	18	1	P = 1.00
Open			
Use of a hook system	4	1	P = 1.00
Preoperative complications	12	10	P = 0.0005*
DISH	18	9	
Osteoporosis	1	1	P = 0.0287*
Rheumatoid arthritis	10	3	P = 1.00
Diabetes	6	0	P = 1.00
Asthma	2	0	P = 1.00
Requirement for dialysis			P = 1.00
Smoking	11	0	P = 1.00

Variable	Non-pull-out group	Pull-out group	P-value
Type of health insurance	20	2	P = 1.00
National health	10	0	P = 1.00
Employees' pension	15	10	P = 0.0028*
Advanced elderly medical service system	7	0	P = 1.00
Industrial injury insurance workers' accident compensation	1	1	P = 1.00
Livelihood subsidies public assistance			
Data are presented as mean standard deviation or as number unless otherwise stated. DISH, diffuse idiopathic skeletal hyperostosis; NS, not statistically significant; PPS, percutaneous pedicle screw. *P < 0.05			

The risk factors for pedicle screw pull-out were evaluated using logistic regression analysis. From univariate analysis, the dependent variable was defined as the presence of screw pull-out and the independent variables were age, number of fused segments, DISH, osteoporosis, advanced elderly medical service system insurance, estimated blood loss and PPS procedure. As a result, the independent risk factors identified were older age (odds ratio 1.15, 95% confidence interval 1.04–1.272, P = 0.007) and DISH (odds ratio 6.10, 95% confidence interval 1.23–30.20, P = 0.027; Table 4).

Table 4
Multivariate logistic regression analysis of risk factors for pedicle screw pull-out

Risk factor	Odds ratio	95% CI	P-value
Age	1.15	(1.04–1.272)	P = 0.007
DISH	6.10	(1.23–30.20)	P = 0.027
CI, confidence interval; DISH, diffuse idiopathic skeletal hyperostosis			

Discussion

Previous reports have shown that pedicle screw loosening after surgery is a serious complication of spinal fixation surgery. Screw loosening causes nonunion back pain and sometimes neurological impairment, and it can be an indication for reoperation[13, 14]. Ohba et al. reported that pedicle screw pull-out was a risk factor for postoperative screw loosening[10]. In the current study, we investigated the incidence of screw pull-out and attempted to identify relevant risk factors.

In our study, pull-out occurred for a total of 17 pedicle screws in 13 cases, giving an overall pedicle screw pull-out rate of 2.7%, which is relatively low compared with the rate of 16.2% reported previously[10]. Although screw pull-out has been recognized as a distance of > 1 mm in previous studies, we defined it as ≥ 4 mm in our study. Considering that one pitch of the screw is 4 mm for the Voyager spinal system and 2.7 mm for the Reline spinal system, it seems reasonable to define pull-out as 1 or more pitches for the Voyager screw and as 2 or more pitches for the Reline screw. Thus, the inter-observer agreement was high (κ = 0.79) in this study. The difference in the cutoff value may explain why the incidence of screw pull-out was lower in this study than in previous investigations. Pedicle screw pull-out was detected in 19.7% of the patients in this study. Of note, all the postoperative CT images were obtained on postoperative day 2 before the patients started to mobilize, meaning that screw pull-out is most likely to occur during the operation. Other studies also mentioned that pedicle screw pull-out occurs during rod connection [10, 11]. Generally, screw pull-out can occur if there is a gap between the shape of the rod and the actual spinal alignment. In the PPS system especially, pull-out may easily occur at the time of inserting set screws because the gap between the rod and the screw head is not visible [10, 11]. Furthermore, we found that pedicle screw pull-out could occur at any of the levels including the cranial end, caudal end and inter-levels. The force in the direction in which the screw comes off is considered to vary according to the order in which the set screws are placed.

In this study, patients in the pull-out group were more likely to be elderly, to have a diagnosis of DISH or osteoporosis, and to have advanced elderly medical service system insurance cover. Other researchers have also identified that older age and osteoporosis are risk factors for pedicle screw loosening[13, 15]. Advanced elderly medical service system insurance is available for citizens over 75 years of age only, meaning that our patients with this type of insurance cover were indeed elderly. The number of fused segments was also associated with screw pull-out. In long fusion, force may be applied to the direction in which the rod does not fit the screw head and the force on the lever arm of the rod is increased, thereby increasing the risk of pedicle screw pull-out compared with short fusion. Additionally, in long spinal fusion, there are multiple screws to be connected to the rod, making it difficult to achieve appropriate rod-bending and to fit the rod completely to each screw head.

Logistic regression analysis identified advanced age and presence of DISH to be independent risk factors for pedicle screw pull-out. DISH appears on radiographs and CT images as ossification along the anterolateral aspect of the vertebral bodies[16, 17]. Therefore, movement of the spine becomes limited by spinal ossification. Given that DISH restricts the segmental motion of the spine, the screw-rod system applies force in the direction in which the screw comes off if the fused segments were over-corrected by de-kyphotic rod placement. Additionally, although there was no significant difference in DISH in this study, DISH is often performed PPS surgery, as it is considered that the screw comes off because the fitting between the rod and the screw head cannot be checked directly. Patients with DISH also tend to be elderly and have poor bone quality [18–20]. Therefore, posterior segmental fusion extending at least three levels above and below has been recommended in patients with DISH[21]. To our knowledge, there have been no reports showing that the presence of DISH is associated with pedicle screw pull-out, and ours is

the first to clearly demonstrate that DISH is a significant risk factor for intraoperative screw pull-out with an odds ratio of 6.10.

The most important factor is to ensure appropriate rod bending and gently connecting it to each screw head. As it is sometimes difficult to create a perfect curve by manual bending, a new automatic rod bending system may be useful to improve the fitting of the rod[22]. Also, a new pedicle screw device using cement augmentation has recently become available as a strategy to prevent pull-out[23].

There are several limitations in this study. First, we did not evaluate the screw design, position, or trajectory as factors affecting pull-out. Second, radiation exposure is a risk for patients, although we used intraoperative CBCT, in which the radiation exposure is reduced. Third, the sample size is limited; Nevertheless, this study identified age and the presence of DISH as the important risk factors for screw pull-out during surgery.

Conclusions

This study analyzed the clinical factors associated with pedicle screw pull-out by comparing findings on both intraoperative CBCT and postoperative CT. Our findings suggest that age, number of fused segments, the presence of DISH and osteoporosis are risk factors for pedicle screw pull-out, with the greatest being advanced older age and DISH.

Abbreviations

CBCT
cone beam computed tomography
CT
computed tomography
PPS
percutaneous pedicle screw
DISH
diffuse idiopathic skeletal hyperostosis

Declarations

Acknowledgements

Not applicable.

Funding

Not applicable.

Availability of data and material

The data and materials may be made available upon request through sending e-mail to first author.

Code availability

Statistical analysis were performed using the commercial package JMP Version 13.1.0 software (SAS Institute Inc., Cary, NC, USA).

Authors' contributions

Experimental design was done by S.S., K.F. and Y.K.; data collection by S.S., K.F. and Y.K.; data analysis and interpretation by S.S., K.F., T.Y., A.O. and Y.K.; and manuscript preparation by S.S., K.F., T.H., H.I., and T.Y.

Ethics approval and consent to participate

Data acquisition and analysis were done in accordance with ethical guidelines and approved by our institutional review board of Saku Central Hospital Advanced Care Center Research Ethical Committee. No. R201904-06. Patients provided their written consent for participation.

Consent for publication

Not applicable.

Competing interests

The authors declare that they have no competing interests.

References

1. Gelalis ID, Paschos NK, Pakos EE, Politis AN, Arnaoutoglou CM, Karageorgos AC, Ploumis A, Xenakis TA. Accuracy of pedicle screw placement: a systematic review of prospective in vivo studies comparing free hand, fluoroscopy guidance and navigation techniques. European spine journal: official publication of the European Spine Society, the European Spinal Deformity Society, and the European Section of the Cervical. Spine Research Society. 2012;21:247–55. doi:10.1007/s00586-011-2011-3.
2. Hicks JM, Singla A, Shen FH, Arlet V. Complications of pedicle screw fixation in scoliosis surgery: a systematic review. Spine. 2010;35:E465–70. doi:10.1097/BRS.0b013e3181d1021a.
3. Okuda S, Miyauchi A, Oda T, Haku T, Yamamoto T, Iwasaki M. Surgical complications of posterior lumbar interbody fusion with total facetectomy in 251 patients. Journal of neurosurgery Spine. 2006;4:304–9. doi:10.3171/spi.2006.4.4.304.
4. Jutte PC, Castelein RM. Complications of pedicle screws in lumbar and lumbosacral fusions in 105 consecutive primary operations. European spine journal: official publication of the European Spine

Society, the European Spinal Deformity Society, and the European Section of the Cervical. Spine Research Society. 2002;11:594–8. doi:10.1007/s00586-002-0469-8.

5. Kang DG, Lehman RA Jr, Wagner SC, Bevevino AJ, Tracey RW, Gaume RE, Dmitriev AE. Effects of rod reduction on pedicle screw fixation strength in the setting of Ponte osteotomies. The spine journal: official journal of the North American Spine Society. 2015;15:146–52. doi:10.1016/j.spinee.2014.07.017.
6. Bohoun CA, Naito K, Yamagata T, Tamrakar S, Ohata K, Takami T. Safety and accuracy of spinal instrumentation surgery in a hybrid operating room with an intraoperative cone-beam computed tomography. Neurosurgical review. 2019;42:417–26. doi:10.1007/s10143-018-0977-6.
7. Fomekong E, Safi SE, Raftopoulos C. Spine Navigation Based on 3-Dimensional Robotic Fluoroscopy for Accurate Percutaneous Pedicle Screw Placement: A Prospective Study of 66 Consecutive Cases. World neurosurgery. 2017;108:76–83. doi:10.1016/j.wneu.2017.08.149.
8. Oba H, Ebata S, Takahashi J, Koyama K, Uehara M, Kato H, Haro H, Ohba T. Pedicle Perforation While Inserting Screws Using O-arm Navigation During Surgery for Adolescent Idiopathic Scoliosis: Risk Factors and Effect of Insertion Order. Spine. 2018;43:E1463–8. doi:10.1097/BRS.0000000000002737.
9. Kotani T, Akazawa T, Sakuma T, Nakayama K, Kishida S, Muramatsu Y, Sasaki Y, Ueno K, Iijima Y, Minami S, Ohtori S. Accuracy of powered surgical instruments compared with manual instruments for pedicle screw insertion: Evaluation using o-arm-based navigation in scoliosis surgery. Journal of orthopaedic science: official journal of the Japanese Orthopaedic Association. 2018;23:765–9. doi:10.1016/j.jos.2018.05.007.
10. Ohba T, Ebata S, Oba H, Koyama K, Haro H. Risk Factors for Clinically Relevant Loosening of Percutaneous Pedicle Screws. Spine Surg Relat Res. 2019;3:79–85. doi:10.22603/ssrr.2018-0018.
11. Okada E, Shiono Y, Nishida M, Mima Y, Funao H, Shimizu K, Kato M, Fukuda K, Fujita N, Yagi M, Nagoshi N, Tsuji O, Ishii K, Nakamura M, Matsumoto M, Watanabe K. Spinal fractures in diffuse idiopathic skeletal hyperostosis: Advantages of percutaneous pedicle screw fixation. J Orthop Surg (Hong Kong). 2019;27:2309499019843407. doi:10.1177/2309499019843407.
12. Schizas C, Michel J, Kosmopoulos V, Theumann N. Computer tomography assessment of pedicle screw insertion in percutaneous posterior transpedicular stabilization. European spine journal: official publication of the European Spine Society, the European Spinal Deformity Society, and the European Section of the Cervical. Spine Research Society. 2007;16:613–7. doi:10.1007/s00586-006-0221-x.
13. Galbusera F, Volkheimer D, Reitmaier S, Berger-Roscher N, Kienle A, Wilke HJ. Pedicle screw loosening: a clinically relevant complication? European spine journal: official publication of the European Spine Society, the European Spinal Deformity Society, and the European Section of the Cervical. Spine Research Society. 2015;24:1005–16. doi:10.1007/s00586-015-3768-6.
14. Bredow J, Boese CK, Werner CM, Siewe J, Lohrer L, Zarghooni K, Eysel P, Scheyerer MJ. Predictive validity of preoperative CT scans and the risk of pedicle screw loosening in spinal surgery. Arch

Orthop Trauma Surg. 2016;136:1063–7. doi:10.1007/s00402-016-2487-8.

15. Wu ZX, Gong FT, Liu L, Ma ZS, Zhang Y, Zhao X, Yang M, Lei W, Sang HX. A comparative study on screw loosening in osteoporotic lumbar spine fusion between expandable and conventional pedicle screws. Arch Orthop Trauma Surg. 2012;132:471–6. doi:10.1007/s00402-011-1439-6.
16. Resnick D, Shaul SR, Robins JM. Diffuse idiopathic skeletal hyperostosis (DISH): Forestier's disease with extraspinal manifestations. Radiology. 1975;115:513–24. doi:10.1148/15.3.513.
17. Resnick D, Niwayama G. Radiographic and pathologic features of spinal involvement in diffuse idiopathic skeletal hyperostosis (DISH). Radiology. 1976;119:559–68. doi:10.1148/119.3.559.
18. Westerveld LA, Verlaan JJ, Lam MG, Scholten WP, Bleys RL, Dhert WJ, Oner FC. The influence of diffuse idiopathic skeletal hyperostosis on bone mineral density measurements of the spine. Rheumatology. 2009;48:1133–6. doi:10.1093/rheumatology/kep177.
19. Kagotani R, Yoshida M, Muraki S, Oka H, Hashizume H, Yamada H, Enyo Y, Nagata K, Ishimoto Y, Teraguchi M, Tanaka S, Nakamura K, Kawaguchi H, Akune T, Yoshimura N. Prevalence of diffuse idiopathic skeletal hyperostosis (DISH) of the whole spine and its association with lumbar spondylosis and knee osteoarthritis: the ROAD study. J Bone Miner Metab. 2015;33:221–9. doi:10.1007/s00774-014-0583-9.
20. Kim SK, Choi BR, Kim CG, Chung SH, Choe JY, Joo KB, Bae SC, Yoo DH, Jun JB. The prevalence of diffuse idiopathic skeletal hyperostosis in Korea. J Rheumatol. 2004;31:2032–5.
21. Caron T, Bransford R, Nguyen Q, Agel J, Chapman J, Bellabarba C. Spine fractures in patients with ankylosing spinal disorders. Spine. 2010;35:E458–64. doi:10.1097/BRS.0b013e3181cc764f.
22. Tohmeh AG, Isaacs RE, Dooley ZA, Turner AW. (2014) Long Construct Pedicle Screw Reduction and Residual Forces are Decreased Using a Computer-assisted Rod Bending System. Journal of Spine Neurosurgery S2. doi:http://dx.doi.org/10.4172/2325-9701.S2-002.
23. Costa F, Ortolina A, Galbusera F, Cardia A, Sala G, Ronchi F, Uccelli C, Grosso R, Fornari M. Pedicle screw cement augmentation. A mechanical pullout study on different cement augmentation techniques. Med Eng Phys. 2016;38:181–6. doi:10.1016/j.medengphy.2015.11.020.

Figures

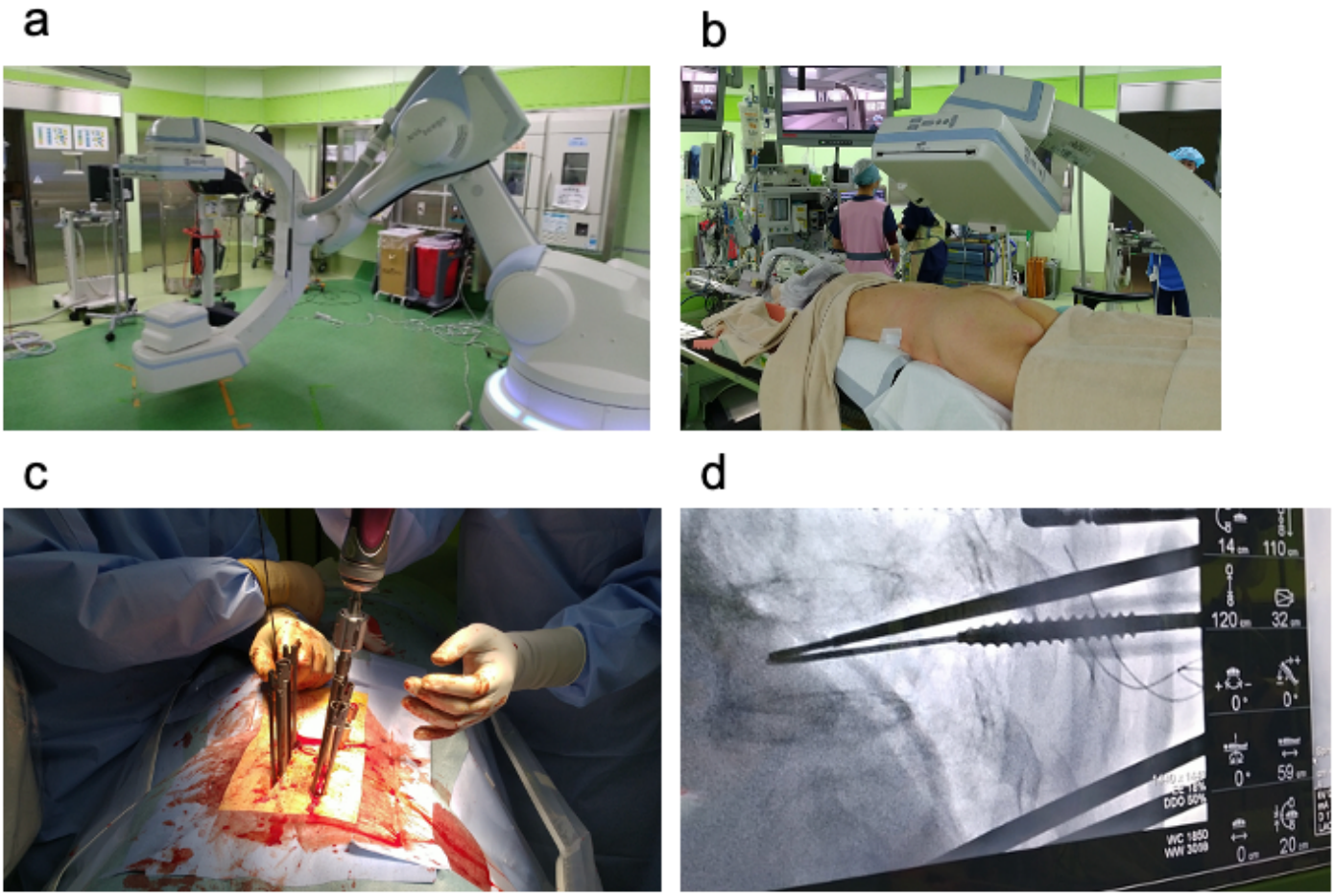

Figure 1

Photograph showing the hybrid operating room. (a) The Artis Zeego system, a 3D imaging tool that reconstructs projection data obtained by a rotational C-arm with a flat panel detector. (b) The patient is placed prone with the trunk on a radiolucent operation table. (c) Percutaneous pedicle screw insertion. (d) The targeting needle is inserted into the pedicle, which is projected onto the Zeego control screen.

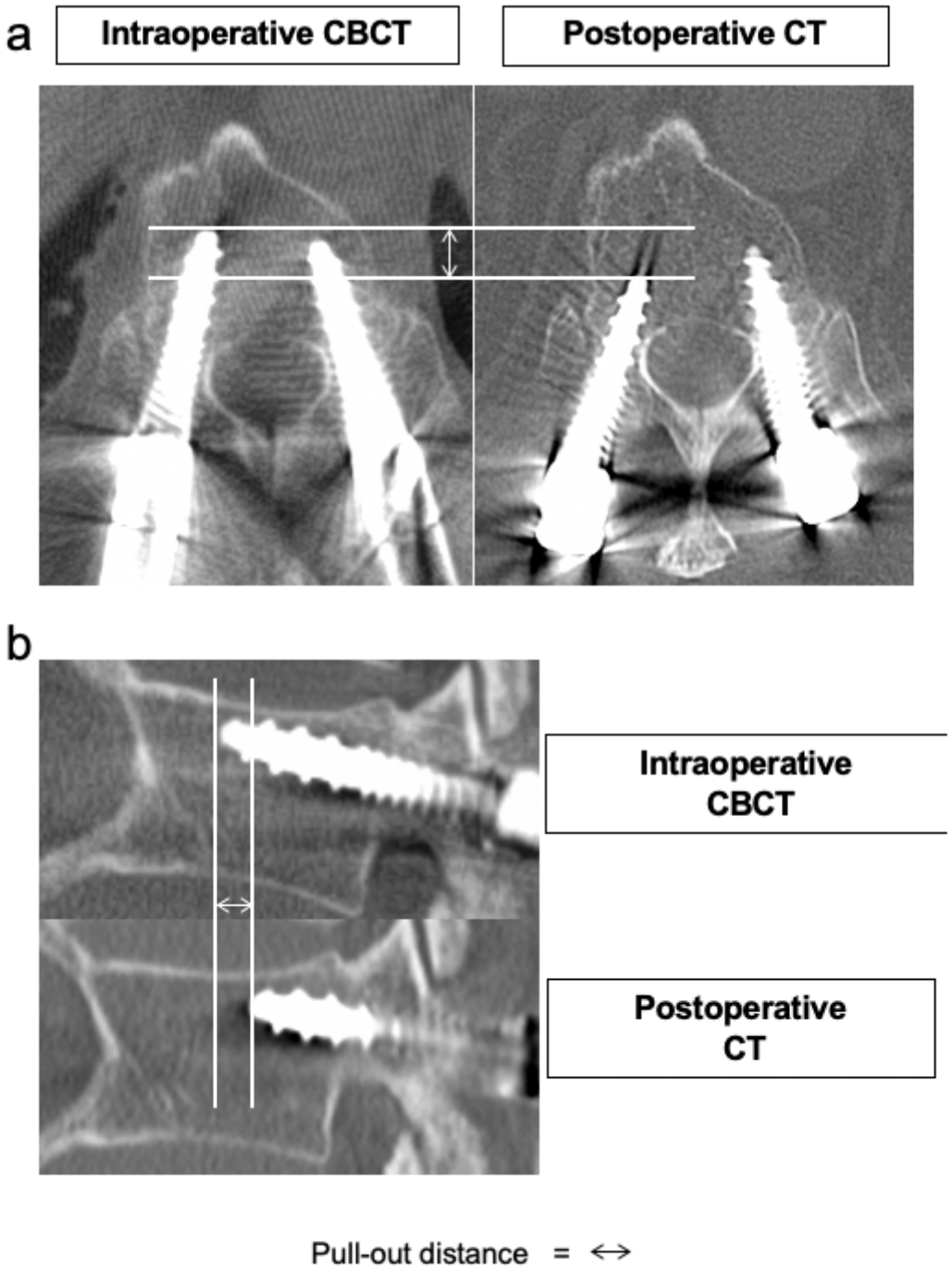

Figure 2

Evaluation of pedicle screw pullout distance. Pedicle screw pull-out was defined as a distance of >4 mm in the (a) axial and (b) sagittal CBCT and CT planes CBCT, cone beam computed tomography; CT, computed tomography

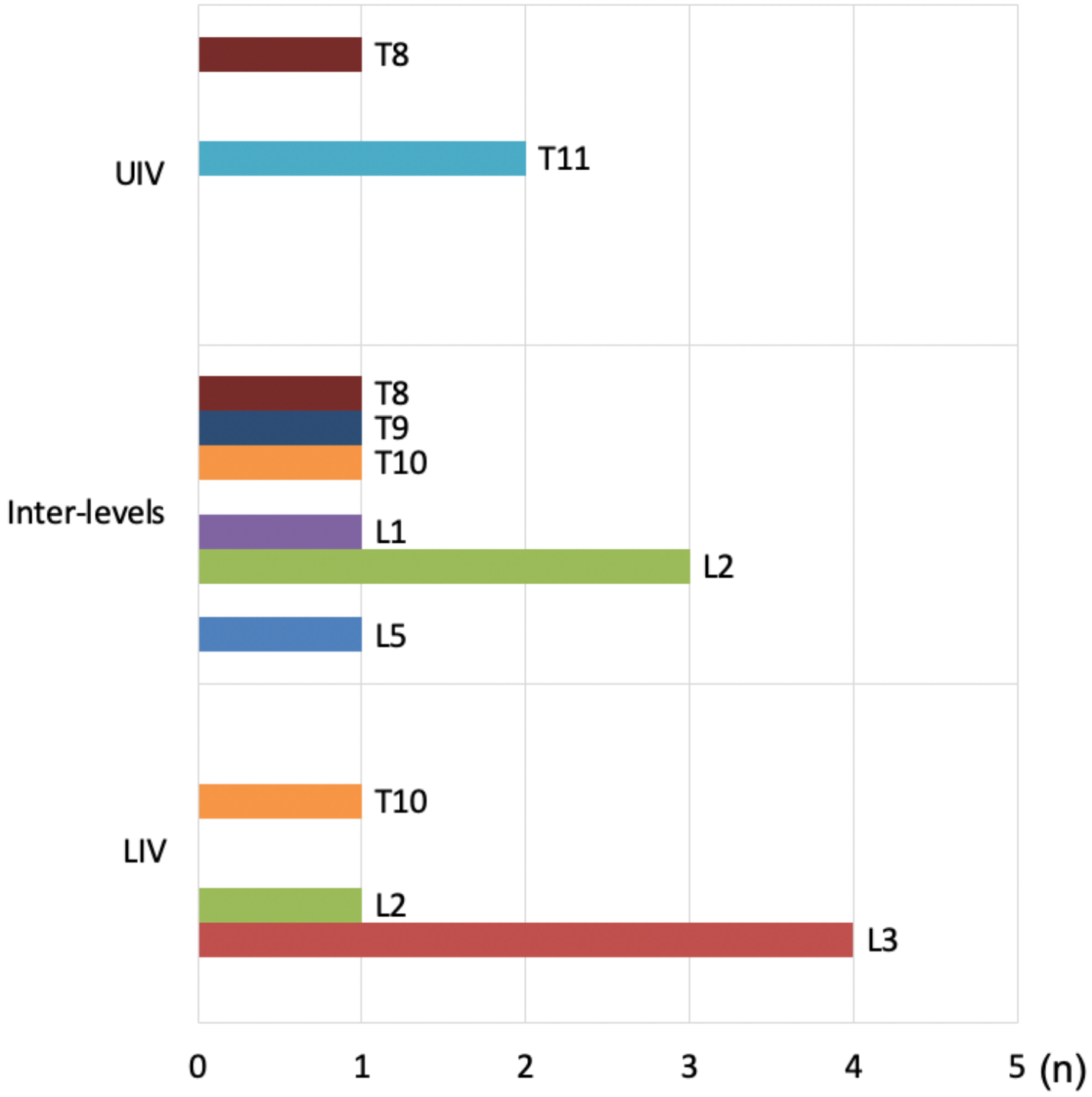

Figure 3

Distribution and frequency of pedicle screw pull-out. UIV, upper instrumented vertebra; LIV, lower instrumented vertebra