Comparison of Clinical Outcomes With Proximal Femoral Nail Anti-rotation Versus Bipolar Hemiarthroplasty for the Treatment of Elderly Intertrochanteric Fractures

Wen-Bo Wei
Shaanxi Provincial People's Hospital
Sha-Jie Dang
Shaanxi Provincial Cancer Hospital
Ling Wei
Yangling demonstration zone hospital
MengXi Xin (drwwb560@126.com)
YangLing Demonstration Zone Hospital

Research article

Keywords: Intertrochanteric fracture, Elderly, Proximal femoral nail antirotation, Bipolar hemiarthroplasty

Posted Date: May 28th, 2021

DOI: https://doi.org/10.21203/rs.3.rs-527679/v1

Abstract

Background: Although proximal femoral nail anti-rotation (PFNA) and bipolar hemiarthroplasty (BHA) are selected by most of the orthopaedic surgeons for elderly intertrochanteric fractures (ITFs) patients, there is still no consensus on the superiority of PFNA and BPH for ITFs in the elderly. The study aims to compare the curative effects of proximal femoral nail anti-rotation (PFNA) and cementless bipolar hemiarthroplasty (BHA) on ITFs in the elderly.

Methods: From January 2012 to December 2016, a total of 62 patients participated in the study: BHA (Group B, n=30), PFNA (Group P, n=32). The fractures were classified according to Evans-Jensen. Hospitalization time, operation time, bleeding loss, Harris scores and postoperative complications were compared between the two groups.

Results: The operation time was (125.76 ± 33.49) min and (94.38 ± 20.94) min in PFNA group and BHA group ($P < 0.05$); bleeding loss was (153.33 ± 59.96) mL and (335.31 ± 90.87) mL($P < 0.05$); hospitalization time was (17.13 ± 2.92) days and (16.63 ± 3.64) days ($P > 0.05$); and the Harris scores were (73.20 ± 6.56) points and (68.91 ± 8.15) points ($P < 0.05$). There was no significant difference in postoperative complications between the two groups ($P > 0.05$).

Conclusion: Both PFNA and BHA are safe and effective treatments for femoral intertrochanteric fractures in elderly patients. Nonetheless, BHA can be considered for those with the poor bone condition and short life expectancy.

Introduction

Femoral intertrochanteric fracture (ITFs), in particular, unstable comminuted fractures, is a common hip fracture that occurs in the elderly[1, 2]. The incidence is gradually increasing with the recent growth of the elderly population[3]. Due to the higher mean age, poor quality of bone mass, and a large number of underlying diseases, patients with this fracture have high rates of complications and mortality[4, 5]. To reduce disability and mortality rates, the early surgical procedure has become the general consensus for the ITFs treatment[6]. The key point of the surgical treatment is stable fixation and early weight-bearing. Considering the elderly's age, underlying comorbidities, quality of bone, and type of fracture, different from the various operation methods for young ITFs patients, proximal femoral nail antirotation (PFNA) and Bipolar hemiarthroplasty (BHA) are the two main methods used for ITFs in the elderly[7]. PFNA has many advantages in terms of the small surgical wound, easy implant insertion, and stable fixation[8], but failure to achieve early weight-bearing[9]. BHA, which is advantageous in terms of operation time and allowing early weight-bearing, has been suggested as another surgical option for elderly patients[10]. However, there is currently no consensus for elderly patients with ITFs[11]. In this retrospective study, we compared the efficacy and complications of PFNA and BHA, and want to address which is optimal for treat ITFs PFNA or BHA.

Methods

1.1 Study design

We retrospectively reviewed the medical records of 62 patients, who were treated at the Department of Orthopedic Surgery, Shannxi Provincial People's Hospital between January 2012 and December 2016. This study was approved by the clinical research ethics committee of Shannxi Provincial People's Hospital (No. 2017-018). This study followed the Good Clinical Practice guidelines and the guidelines of the Helsinki Declaration. The study included 32 cases underwent PFNA (Group P) and 30 cases underwent BHA (Group B).

1.2 Patients

Patients (aged 65 ~ 98 years old) undergoing PFNA or BHA operation as ITFs were screened in this study. Inclusion criteria were 1) ≥ 65 years old; 2) patients with a fracture that occurred after trauma. Exclusion criteria were 1) pathologic fractures; 2) fractures associated with polytrauma; 3) immobility or walking difficulties before fracture; 4) Patients who are unable to operate due to mental or organ dysfunction, and 5) patients who are lost to follow-up.

1.3 Procedures

Operations were performed under spinal anaesthesia or general anaesthesia.

PFNA group

The patient was lying on the traction bed in supine position. The fracture was reset under C-arm fluoroscopy guidance by a standard program. After satisfactory reduction, a straight incision 3- to 5- cm long was made from the top of the greater trochanter toward the proximal side. A rhombus-shaped awl was used to drill a hole at the front and middle 1/3 between the tip of the greater trochanter. Then the proximal femoral nail was inserted, which was matched with the femoral bone marrow cavity. Under C-arm fluoroscopy, the column screw was knocked in until its tip as close as 5 mm to the subchondral bone. We fix the locking bolt and the end cap, then close the wound in layers. The PFNA material was provided by the WeiGao Company (Weihai, China) and the DaBo Company (Xiamen, China).

BHA group

The patient was in a lateral decubitus position. Using posterolateral invasive approach,layer- by-layer incisions were made to expose the fracture site. We cut the joint capsule, performed femoral neck osteotomy, and expanded the medullary cavity by use of medullary cavity burs. A suitable biological long-stem femoral prosthesis was selected according to the preoperative X-ray measurement and the actual intraoperative status of the medullary cavity. The anteversion angle of the femoral stem was maintained at 15°-20°, the femoral head model was inserted, and the hip joint was reduced. Displaced greater trochanter fracture fragments were fixed by wire as a '8' shape. The stability of the reduction was tested

after ensuring the absence of dislocation. After satisfactory results were obtained, the corresponding femoral prosthesis and the femoral bipolar head were implanted. We sutured the joint capsule, reconstructed the external rotator muscles, and stitched the wound. Long-stem biotype artificial joint was provided by the Chunli Company (Beijing, China) and the Link Company (Germany).

All the patients used antibiotic prophylaxis within 30 min before incision and the first 24 h postoperatively. Low molecular weight heparin or rivaroxaban was used within 30 days after the operation.

1.4 Outcomes

The patients' medical information was obtained from the patients' clinical history and Medical Records Department. The patients' general conditions were ranked by the American Society of Anesthesiologists (ASA) grading. The fractures were classified according to association for the Study of Evans-Jensen classification together by two surgeons through radiographs. When patients visit, anteroposterior and lateral radiograph with a standard questionnaire was performed, and hip function was evaluated according to the Harris Hip Score included in the standard questionnaire.

1.5 Statistical analysis

The statistical analysis was performed with SPSS 24.0 for Windows (SPSS, Inc., IBM). Measured data were tested for normal distribution and the homogeneity of variance. Numeric variables were expressed as Mean ± SD and analyzed by Independent-Samples T-test. Categorical data were expressed by N (%) and were analyzed with the $\chi 2$ test. The value of $p < 0.05$ was taken as a significant difference.

Results

A total of 245 ITFs patients were reviewed, 42 patients were excluded for there were 3 pathologic fractures, 10 with walking difficulties before fracture, 29 fractures associated with polytrauma, and 129 patients were lost due to failed followed up. Finally, 62 patients were followed up successfully.

The mean total follow-up period was 27.4 ± 9.80 months (range 12 ~ 49 months) for the BHA group and for the PFNA group it was 28.8 ± 9.6 months (range 12 ~ 45 months). The difference was not significant between the groups ($P = 0.570$, T-test).

General information

There was no significant difference in the gender, age, the American Society of Anesthesiologists (ASA) grading, and Evans-Jensen classification between the two groups ($P > 0.05$). As for the combining metabolic disease, the number of diseases per patient in the BHA group was higher than that in PFNA group($P = 0.039$, T-test). There were no differences in cardiovascular disease, diabetes, chronic pulmonary disease, cerebrovascular disease, neurological disease,and hypertension between the two groups (Table 1).

Table 1
The comparison of baseline characteristics between BHA and PFNA.

Characteristics		BHA	PFNA	x^2/t	*P*
Cases (n)		32	30	-	-
Gender (M/F)		5/27	9/21	1.830	0.230
Age(x ± s, years)		81.0 ± 9.1	79.9 ± 6.1	0.541	0.591
ASA grading	3	11	16	2.264	0.132
	4	21	14		
Evans-Jensen classification	3	5	5	2.246	0.884
	4	20	17		
	5	7	8		
Mean N of diseases per patient		2.47 ± 0.567	2.07 ± 0.907	2.107	0.039
Hypertension		15	11	0.663	0.416
Cardiovascular disease		19	12	2.325	0.127
Diabetes		8	8	0.022	0.881
Chronic pulmonary disease		16	14	0.069	0.793
Cerebrovascular disease		15	15	0.061	0.806
Neurological disease		6	2	2.246	0.156

Notes: Numeric data were expressed as Mean ± SD and analyzed by Independent-Samples T-test. Categorical data were expressed by the number of patients (%) and were analyzed with the χ2 test.
*P<0.05, Group BHA vs Group PFNA.

Abbreviations: ASA, American Society of Anesthesiologists; PFNA, proximal femoral nail antirotation; BHA, bipolar hemiarthroplasty

Comparison of Hospitalization time and operation time

There was no significant difference between the groups in the time from injury to operation and hospital stay. However, the operative statistics including the operating time (P< 0.001, T-test), the bleeding volume (P< 0.001, T-test) were quite different. The BHA group trended to have a shorter operation (94.38 vs. 125.67min), and a larger volume of blood loss (335.31 vs. 153.33 ml) (Table 2).

Table 2
The comparison of hospitalisation and operation between BHA and PFNA

Characteristics	BHA	PFNA	*t*	*P*
operating time	94.38 ± 20.94	125.67 ± 33.49	-4.441	< 0.001
Bleeding volume	335.31 ± 90.87	153.33 ± 59.96	9.241	< 0.001
Hospital stay	16.63 ± 3.64	17.13 ± 2.92	-0.604	0.548
Harris Hip Score	68.91 ± 8.15	73.20 ± 6.56	-2.276	0.026
Time from injury to operation	5.06 ± 2.17	4.70 ± 1.17	0.766	0.447

Notes: Numeric data were expressed as Mean ± SD and analyzed by Independent-Samples T-test.
*P<0.05, Group BHA vs Group PFNA.

Abbreviations: PFNA, proximal femoral nail antirotation; BHA, bipolar hemiarthroplasty

Comparison of functional outcomes

As for the functional aspects evaluated by the Harris Hip Score, PFNA seemed to be better than BHA. The PFNA group scored 73.20 ± 6.56 and the BHA group scored 68.91 ± 8.15 (P = 0.026, T-test, T = -2.276) (Table 2).

Postoperative complications

Postoperative complications in the PFNA group include infection in three, Symptomatic deep venous thrombosis (DVT) in one case, Cutout in three, and new fracture around the implant in eight; in the BHA group includes infection in two cases, Symptomatic DVT in five and New fracture around the implant in three. There was no significant difference between the groups (Table 3).

Table 3
Postoperative complications of BHA and PFNA

Characteristics	BHA	PFNA	χ^2	*P*
infection	2	3	0.294	0.588
Symptomatic DVT	5	1	2.676	0.102
Cutout	0	3	3.363	0.067
New fracture around the implant	3	8	3.172	0.075

Notes: Categorical data were expressed by the number of patients (%) and were analyzed with the χ2 test.
*P<0.05, Group BHA vs Group PFNA.

Abbreviations: PFNA, proximal femoral nail antirotation; BHA, bipolar hemiarthroplasty

Discussion

Due to the aging of the population, the number of elderly patients with ITFs is increasing gradually. Elderly ITFs patients have difficulties to return to prefracture function levels and display poor treatment results because of low bone quality, additional morbidities, and mobilization problems. An ideal surgical technique for elderly ITFs patients should be less trauma and postoperative complications[12]. However, it is still unclear whether BPH or PFNA is the better choice for elderly ITFs patients. Thus, our study was initiated to compare the PFNA and BHA groups and to help orthopedic surgeons to choose a suitable implant to fix ITFs in elderly patients.

As a minimally invasive procedure, PFNA offers the advantages of micro-trauma, minimal bleeding, and short operation times[13]. PFNA nails not only reduces movement, sliding compression but also increases the anti-rotation screw, which significantly enhances the anti-rotation, anti-compression, and anti-tension abilities of the fracture end, increases the stability of the fracture end[14]. Thus, PFNA is particularly suitable for elderly patients with the poor bone condition, which minimizes the risk of medical complications.

In our results, the PFNA group has less blood loss, but longer operating time than BHA, which is different from the previous literature[13]. The patients in our study have severely comminuted fractures, so intraoperative closed traction reductions take longer time. Besides, a lot of intraoperative fluoroscopies are used, to avoid intraoperative complications, such as the internal fixation point explosion, needle's cut-off from the medial wall of femur, the separation of the end of fracture, etc. Although PFNA has been selected by most surgeons for elderly ITFs patients[15–17], failures of PFNA have also been reported due to extensive comminution, osteoporosis, or long bedridden duration[17]. PFNA complications include cutout of the femoral screw, breakage of the nail, Split of the lateral cortex of the proximal femur, and fracture of the femoral shaft[18]. In our results, two patients cutout the femoral head, eight patients split of the lateral cortex of the proximal femur, and fracture of the femoral shaft, these may be related to comminution fracture and osteoporosis.

BHA, which is advantageous in terms of operation time and allowing early weight-bearing, was first used in 1978 and subsequently used by other surgeons for ITFs treatment with satisfying results[19], has been suggested as an alternative method for elderly ITFs patients[7, 20]. BHA is recommended as a prior treatment for ITFs with poor stability in the elderly with severe osteoporosis, poor prognosis after internal fixation, and a short life expectancy[21]. Long-stem cementless prosthesis is conducive to biological fixation and can prevent cardiovascular toxicity caused by bone cement. Our study indicates that the use of long-stem cementless prosthesis can relieve pain, restore ambulatory function, provide long-term stability of the implant, and is associated with fewer complications in ITFs of elderly patients.

PFNA offers the advantages of micro-trauma and minimal bleeding, while patients who were treated with BPH can begin functional exercise earlier. However, long-term follow-up results reflect that both procedures can reduce postoperative bedrest-related complications, obtain reliable fixation, relieve patients' pain, and significantly improve patients' quality of life. The amount of intra- and postoperative

early bleeding was significantly higher in patients undergoing BHA. However, problems such as postoperative early weight-bearing loss and more radiation are encountered with the applications of PFNA[22, 23].

This study reveals that the volume of blood loss in the PFNA group was significantly lower than those of the BHA group ($P < 0.05$), and the operating time in the BHA group was significantly shorter than that of the PFNA group ($P < 0.05$). The average hospital stay, Harris score, and postoperative complications had no significant differences between the two groups ($P > 0.05$).

The benefit of early weight-bearing doesn't advantage elderly patients to recover from our BHA group. Effects of early weight-bearing on postoperative recovery for fractures in BHA are generally publicized[10]. But after the physical injury by fracture, the elder patients have the psychological barriers to do exercises. Avoiding falling again, the elderly patients just stand around the bed, extend the knee and hip joints mildly. Correspondingly, the early weight-bearing shows limited effect in the BHA group.

There were several limitations in our study. Firstly, it was a retrospective controlled study. Although the patient groups appeared similar, patients were not randomly assigned to the groups. Secondly, some patients were excluded due to a lack of follow-up. This exclusion also procures the mortality and morbidity rates of the study decreased. Lastly, study groups could not be selected according to each fracture type in the Evans-Jensen classification.

Conclusion

In conclusion, long-term follow-up results show that both BHA and PFNA can reduce postoperative bedrest-related complications, obtain reliable fixation, relieve patients’ pain, and significantly improve patients’ quality of life. The choice of appropriate treatment should be determined by the patient's condition. For elderly ITFs patients, PFNA is preferred. BHA can be considered for those with the poor bone condition and short life expectancy.

Abbreviations

PFNA: proximal femoral nail anti-rotation

BHA: bipolar hemiarthroplasty

ITFs: intertrochanteric fracture

ASA: American Society of Anesthesiologists

DVT: deep venous thrombosis

Declarations

Ethics approval and consent to participate

This study was approved by the clinical research ethics committee of Shannxi Provincial People's Hospital (No. 2017-018). The authors declare that all the patients provided written informed consent and this study followed the Good Clinical Practice guidelines and the guidelines of the Helsinki Declaration.

Consent for publication

Not applicable.

Availability of data and materials

The authors will allow the sharing of participant data. The data will be available to anyone who wishes to access them for any purpose. The data will be accessible from immediately the following publication to 6 months after publication, and contact should be made via the first author by email.

Competing interests

The authors declare that they have no competing interests.

Funding

No funding was obtained for this study.

Authors' contributions

All authors participated in the interpretation of study results, and in the drafting, critical revision, and approval of the final version of the manuscript, and all authors agree to be accountable for all aspects of the work. WBW was in charge and contributed to all stages of the present study; LW was responsible for participated in the design of the study, made revisions of the manuscript and approved the final version. SJD contributed to interpreting the data and writing the final manuscript; MXX was contributors in writing and editing the manuscript.

Acknowledgements

The authors would like to thank all the study participants.

References

1. Reindl R, Harvey EJ, Berry GK, Rahme E: Intramedullary Versus Extramedullary Fixation for Unstable Intertrochanteric Fractures: A Prospective Randomized Controlled Trial. *The Journal of bone and joint surgery American volume* 2015, 97(23):1905-1912.
2. Xue D, Yu J, Zheng Q, Feng G, Li W, Pan Z, Wang J, Li H: The treatment strategies of intertrochanteric fractures nonunion: An experience of 23 nonunion patients. *Injury* 2017, 48(3):708-714.

3. Senohradski K, Markovic-Denic L, Lesic A, Bumbasirevic V, Bumbasirevic M: Trends in the incidence of hip fractures. *Osteoporosis international : a journal established as result of cooperation between the European Foundation for Osteoporosis and the National Osteoporosis Foundation of the USA* 2013, 24(5):1759-1763.
4. Görmeli G, Korkmaz MF, Görmeli CA, Adanaş C, Karataş T, Şimşek SA: Comparison of femur intertrochanteric fracture fixation with hemiarthroplasty and proximal femoral nail systems. *Ulusal travma ve acil cerrahi dergisi = Turkish journal of trauma & emergency surgery : TJTES* 2015, 21(6):503-508.
5. S D, Patil D, P D, A D: Functional outcome of unstable intertrochanteric femur fracture in elderly osteoporotic patients treated by primary cemented bipolar hemiarthroplasty versus internal fixation with proximal femoral nailing. *International Journal of Orthopaedics Sciences* 2017, 3:321-325.
6. Yu J, Zhang C, Li L, Kwong JS, Xue L, Zeng X, Tang L, Li Y, Sun X: Internal fixation treatments for intertrochanteric fracture: a systematic review and meta-analysis of randomized evidence. *Sci Rep* 2015, 5:18195.
7. Tang P, Hu F, Shen J, Zhang L, Zhang L: Proximal femoral nail antirotation versus hemiarthroplasty: a study for the treatment of intertrochanteric fractures. *Injury* 2012, 43(6):876-881.
8. Müller F, Doblinger M, Kottmann T, Füchtmeier B: PFNA and DHS for AO/OTA 31-A2 fractures: radiographic measurements, morbidity and mortality. *European journal of trauma and emergency surgery : official publication of the European Trauma Society*
9. Zhang W, Antony Xavier RP, Decruz J, Chen YD, Park DH: Risk factors for mechanical failure of intertrochanteric fractures after fixation with proximal femoral nail antirotation (PFNA II): a study in a Southeast Asian population. *Archives of orthopaedic and trauma surgery*
10. Lee JM, Cho Y, Kim J, Kim DW: Wiring Techniques for the Fixation of Trochanteric Fragments during Bipolar Hemiarthroplasty for Femoral Intertrochanteric Fracture: Clinical Study and Technical Note. *Hip & pelvis* 2017, 29(1):44-53.
11. Nie B, Wu D, Yang Z, Liu Q: Comparison of intramedullary fixation and arthroplasty for the treatment of intertrochanteric hip fractures in the elderly: A meta-analysis. *Medicine (Baltimore)* 2017, 96(27):e7446.
12. Ong JCY, Gill JR, Parker MJ: Mobility after intertrochanteric hip fracture fixation with either a sliding hip screw or a cephalomedullary nail: Sub group analysis of a randomised trial of 1000 patients. *Injury* 2019, 50(10):1709-1714.
13. Wang HH, Shu WB, Lan GH, Zhang XB, Jiang ZQ, Xu DH, Bao XX, Li AB: Network meta-analysis of surgical treatment for unstable femoral intertrochanteric fractures. *Oncotarget* 2018, 9(35):24168-24177.
14. Li J, Cheng L, Jing J: The Asia proximal femoral nail antirotation versus the standard proximal femoral antirotation nail for unstable intertrochanteric fractures in elderly Chinese patients. *Orthopaedics & traumatology, surgery & research : OTSR* 2015, 101(2):143-146.

15. Dehghan N, McKee MD: What's New in Orthopaedic Trauma. *The Journal of bone and joint surgery American volume* 2018, 100(13):1158-1164.
16. Maroun G, Chaftari R, Chokr J, Maroun C, El-Jerdi M, Saade C: High comorbidity index is not associated with high morbidity and mortality when employing constrained arthroplasty as a primary treatment for intertrochanteric fractures in elderly patients. *European journal of orthopaedic surgery & traumatology : orthopedie traumatologie* 2019, 29(5):1009-1015.
17. Socci AR, Casemyr NE, Leslie MP, Baumgaertner MR: Implant options for the treatment of intertrochanteric fractures of the hip: rationale, evidence, and recommendations. *The bone & joint journal* 2017, 99-B(1):128-133.
18. von Rüden C, Hungerer S, Augat P, Trapp O, Bühren V, Hierholzer C: Breakage of cephalomedullary nailing in operative treatment of trochanteric and subtrochanteric femoral fractures. *Archives of orthopaedic and trauma surgery* 2015, 135(2):179-185.
19. Green S, Moore T, Proano F: Bipolar prosthetic replacement for the management of unstable intertrochanteric hip fractures in the elderly. *Clinical orthopaedics and related research* 1987(224):169-177.
20. Fahad S, Nawaz Khan MZ, Khattak MJ, Umer M, Hashmi P: Primary Proximal femur replacement for unstable osteoporotic intertrochanteric and subtrochanteric fractures in the elderly: A retrospective case series. *Annals of medicine and surgery (2012)* 2019, 44:94-97.
21. Huang CG, Ye JJ: [Comparison of three methods for the treatment of aged femoral intertrochanteric fracture]. *Zhongguo gu shang = China journal of orthopaedics and traumatology* 2012, 25(7):549-553.
22. Esen E, Dur H, Ataoğlu MB, Ayanoğlu T, Turanlı S: Evaluation of proximal femoral nail-antirotation and cemented, bipolar hemiarthroplasty with calcar replacement in treatment of intertrochanteric femoral fractures in terms of mortality and morbidity ratios. *Eklem hastaliklari ve cerrahisi = Joint diseases & related surgery* 2017, 28(1):35-40.
23. Kumar P, Rajnish RK, Sharma S, Dhillon MS: Proximal femoral nailing is superior to hemiarthroplasty in AO/OTA A2 and A3 intertrochanteric femur fractures in the elderly: a systematic literature review and meta-analysis. *International orthopaedics* 2020, 44(4):623-633.

Figures

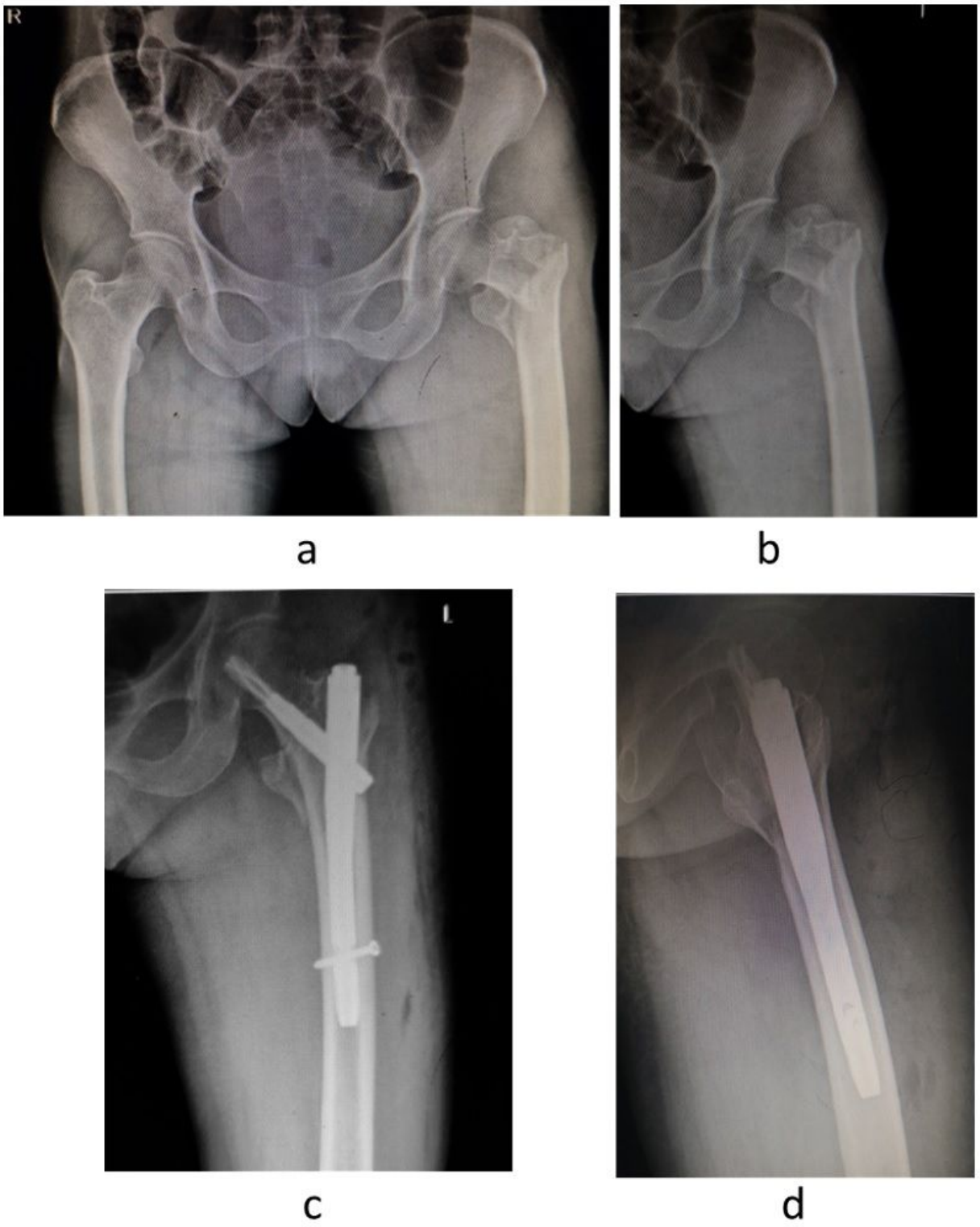

Figure 1

Anteroposterior radiograph showing an unstable intertrochanteric fracture of left hip in a 76-year-old female patient who fell at home (a.b). Anteroposterior pelvis and lateral femoral examination after the operation showed good fracture alignment and satisfactory fixation (c.d).

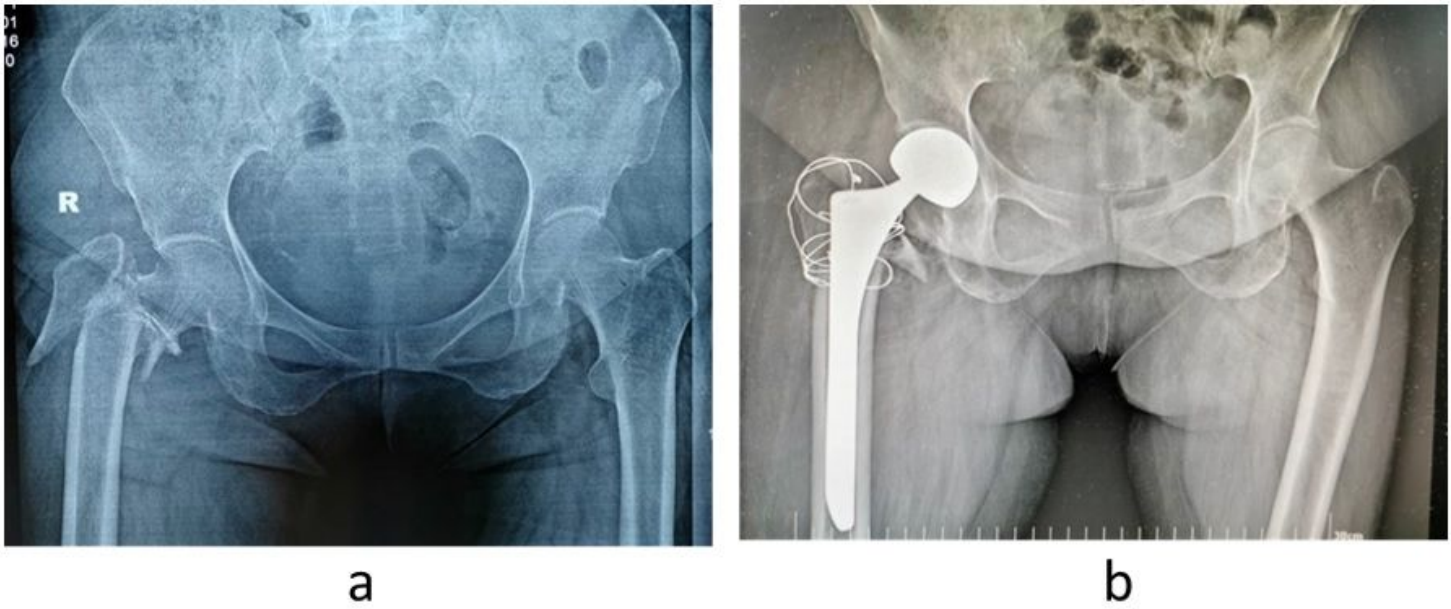

Figure 2

(a) Anteroposterior radiograph showing an unstable intertrochanteric fracture of right hip in a 82-year-old male patient who fell at home. (b) Radiograph one year after hemiarthroplasty.