Treatment experience of large intraventricular central neurocytoma: a retrospective cohort study

Chaocai Zhang
Hainan General Hospital
Lanbing Yu
Beijing Tiantan Hospital
Shuyu Hao
Beijing Tiantan Hospital
Yehong Fang
Beijing Tiantan Hospital
Heyuan Jia
Beijing Tiantan Hospital
Junling Wang
Beijing Tiantan Hospital
Nan Ji
Beijing Tiantan Hospital
Bo Cen
Wuhan brain hospital
Jiannong Zhao
Hainan General Hospital
Zhixian Gao (gaozx@ccmu.edu.cn)
Beijing Tiantan Hospital, Capital Medical University

Research

Keywords: central neurocytoma, hydrocephalus, radiotherapy, transcortical approach

Posted Date: August 5th, 2020

DOI: https://doi.org/10.21203/rs.3.rs-52813/v1

Abstract

Background: Central neurocytoma is a rare intracranial tumor. Due to the limited number of reported cases, the treatment strategy for central neurocytomas, especially large central neurocytomas, remains controversial. This paper discusses our clinical experience in the treatment of large central neurocytomas.

Methods: A retrospective analysis of 29 patients with intraventricular central neurocytomas diagnosed and treated by the same surgeon between April 2012 and September 2019 at the Neurosurgery Departments of Beijing Tiantan Hospital and Hainan General Hospital was performed. The clinical characteristics, treatment plans and prognoses of these patients were reviewed.

Results: Among the 29 patients, the average age of onset was 31.93 (17-61) years, and the average maximum tumor diameter was 54.17 ± 15.62 mm. Twenty-three patients (79.3%) had an average maximum diameter greater than 50 mm. Twenty-seven patients (93.1%) underwent transcortical tumor resection. Twenty-seven patients (93.1%) underwent gross total tumor resection. Five patients (17.2%) received radiotherapy after the first operation, and 3 patients (10.3%) had tumor recurrence. None of the patients died.

Conclusions: Surgical resection via transcortical fistulotomy is a reliable approach for removal of large central neurocytomas in the ventricle. Patients should be closely observed postoperatively, and MRI of the head should be performed regularly. If a tumor shows progression, then radiotherapy should be considered.

Background

Central neurocytoma is a rare brain tumor mainly located in the lateral ventricle near the interventricular foramen [1] and accounts for approximately 0.1-0.5% of primary central nervous system tumors. Hassoun et al. [2] proposed the concept of the pathological diagnosis of central neurocytoma for the first time in 1982, and it was classified as grade II by the World Health Organization (WHO) in 2007 and 2016 [3]. Central neurocytomas present as either benign entities or as more aggressive atypical variants, depending on histological atypia and the MIB-1 labeling index, which is a cell proliferation marker [4, 5]. Surgical resection of as much tumor as possible is recommended as a first-line measure in central neurocytoma management. However, due to the proximity of intraventricular vasculature and the basal ganglia, achieving total tumor resection is difficult, especially for large central neurocytomas. Additionally, the choice of surgical approach and whether postoperative radiotherapy should be applied are still controversial [5-8]. In this study, we retrospectively analyzed the treatment outcome of 29 intraventricular central neurocytoma patients. Most patients had central neurocytomas with a diameter ≥ 50 mm. With surgical resection via transcortical fistulotomy, most patients had achieved tumor gross total resection. Additionally, we did not suggest that the patients receive radiotherapy directly after the operation.

Methods

Patients

This retrospective study was approved by the Institutional Review Board of Beijing Tiantan Hospital of the Capital Medical University of Medicine. A portion of patients pathologically diagnosed with central neurocytomas or tumors located in the brain ventricles at the Neurosurgery Departments of Beijing Tiantan Hospital and Hainan General Hospital from 2012 to 2019 were included. The same surgeon performed the operations for all patients.

Surgical procedure

The same surgeon performed surgeries for all patients. The surgical approach was selected based on the tumor location and tumor volume, which were evaluated by preoperative imaging. All patients chose unilateral craniotomy and a transventricular approach for tumor resection without using neuro navigation technology. Except for two patients whose tumors were located at the posterior part of the ventricle, the other patients chose to tumor resection through frontal cortex fistulation.

Data collection

Patient medical records, including resident admission notes, progress notes, surgical records, discharge records and preoperative and postoperative imaging materials, in the medical records system of Beijing Tiantan Hospital and Hainan General Hospital were examined to select patients who conformed to the inclusion criteria. Patient demographics, including age, sex, initial complaint, preoperative Karnofsky Performance Status (KPS) score, comorbidities, preoperative and postoperative neurological examination results, tumor volume, resection extent, postoperative complications and pathology, were recorded. The patients were followed up for adjuvant treatment, tumor progression and recovery status. The last follow-up evaluation was March 2020.

Grouping method

The preoperative KPS score was used for classification of functional status. A better functional status resulted in a more favorable KPS score. We identified the extent of resection by comparing preoperative and postoperative imaging data. Gross total resection was defined as complete resection of the main parts of enhanced lesions observed on preoperative imaging (as shown in Figure 1). Other surgical outcomes were categorized as non-gross total resection. Tumors with a diameter ≥ 50 mm were defined as large central neurocytomas. Memory decline was defined as a patient's or family member's description of the patient's frequent forgetting during postoperative telephone follow-up.

Statistical analysis

Continuous and categorical variables are expressed as the medians and percentages, respectively. Differences in patient characteristics and outcomes between the two groups were estimated using the $\chi 2$, Student’s, or Wilcoxon’s rank tests. All statistical analyses were performed using the statistical analysis

software package SPSS, version 22.0 (IBM Corp, Armonk, New York, USA). Statistical significance was defined as a P value < 0.05.

Results

Twenty-nine patients met the enrollment criteria (Table 1). The average age of the patients was 31.93 years (range 17-61 years). Seventeen male patients were enrolled (males:females = 1.4:1), the average preoperative KPS score was 88.62 ± 6.39, and the average maximum tumor diameter was 54.17 ± 15.62 mm; 23 patients (79.3%) had an average maximum diameter ≥ 50 mm. The median length of stay was 25 days (12-110 days), and the mean follow-up time was 49.52 ± 25.40 months.

Table 1. Clinical characteristics, treatments and prognoses of 29 patients with central neurocytoma.

	Total/average
Age	29
Male	31.93(17-61)
KPS1	17(58.6%)
KPS2	88.62±6.39
KPS3	77.59±7.40
Large central neurocytoma	90.34±6.81
Treatment	23(79.3%)
Gross total resection	27(93.1%)
Radiotherapy*	5(17.2%)
Postoperative complications	10(34.5%)
Hemiplegia	10(34.5%)
Aphasia	4(13.8%)
Epilepsy	12(41.4%)
Fever	15(51.7%)
Memory decline	5(17.2%)
V-P shunt	25(12-110)
*Median length of stay	49.52±25.40
Mean follow-up time	3(10.3%)
Tumor recurrence	

One patient was hospitalized for 110 days, which was several times longer than the hospitalization durations of the other patients. Radiotherapy: denotes patients who received radiotherapy after primary surgery. KPS1: Preoperative Karnofsky Performance Status (KPS); KPS2: Discharge KPS; KPS3: KPS at the last follow-up.

Treatment outcome

Twenty-seven patients (93.1%) were treated by gross total tumor resection, and no operative deaths occurred. Among these 27 patients, 3 suffered from tumor occurrence. Twenty-seven patients underwent surgery with the transcortical approach, and a surgical approach through the trigone of the lateral ventricle was also used in 2 cases. Among the 27 patients who received a transcortical surgical approach, 25 achieved gross total tumor resection. Ten patients (34.5%) had hemiplegia, 10 aphasia (34.5%), 4 epilepsy (13.8%), 15 memory decline (51.7%) and 12 fever (41.4%). Five patients (17.2%) with hydrocephalus underwent ventriculoperitoneal shunting. Five patients (17.2%) received radiotherapy after the first operation, and none of the patients who received postoperative radiotherapy had tumor progression. Among the 24 patients who did not receive radiotherapy, 3 patients had tumor recurrence, one each in the first year, the second year and the third year. The first patient received radiotherapy after the second operation, and the other two patients received radiotherapy directly. At the last follow-up visit, no signs of tumor progression were noted, and no deaths occurred.

Statistical analysis

We compared the treatment outcome between the large central neurocytoma and non-large central neurocytoma groups. Hemiplegia occurred more frequently in patients with large central neurocytomas than in patients with non-large central neurocytomas (P = 0.046) (Table 2), but no significant correlation was identified between other postoperative complications and tumor volume. We also analyzed the association between treatment strategies and postoperative complications. Statistical analysis revealed that memory decline was significantly correlated with radiotherapy (P = 0.017) (Table 3). In addition, no significant correlation was identified between gross total resection or radiotherapy and the recurrence rate (Table 4).

Table 2. Comparison of treatments and prognoses between large central neurocytoma and non-large central neurocytoma.

	Large CN	Non-large CN	Chi-square value	P value
Treatment				
Extent of resection			0.56	0.454
Gross total resection	21	6		
Non-gross total resection	2	0		
V-P shunt			1.373	0.241
Yes	3	2		
No	20	4		
Radiotherapy			1.576	0.209
Yes	5	0		
No	18	6		
Postoperative complications				
Hemiplegia			3.982	**0.046**
Yes	10	0		
No	13	6		
Aphasia			0.004	0.950
Yes	8	2		
No	15	4		
Epilepsy			1.21	0.271
Yes	4	0		
No	19	6		
Fever			0.232	0.630
Yes	9	3		
No	14	3		
Memory decline			1.025	0.311
Yes	13	2		
No	10	4		
Recurrence			0.873	0.350
Yes	3	0		
No	20	6		

Table 3. Relationship between treatment and memory decline.

	Memory decline	Without memory decline	Chi-square value	P value
Gross total resection			2.005	0.157
Yes	13	14		
No	2	0		
V-P shunt			0.166	0.684
Yes	3	2		
No	12	12		
*Radiotherapy			5.663	**0.017**
Yes	7	1		
No	8	13		

*Including direct postoperative radiotherapy and repeat radiotherapy after recurrence.

Table 4. Correlation between tumor recurrence and treatment.

	Recurrence	Non recurrence	Chi-square value	P value
Gross total resection			0.248	0.618
Yes	3	24		
No	0	2		
Radiotherapy			0.697	0.403
Yes	0	5		
No	3	21		

Discussion

Most central neurocytomas show benign biological behavior, and patients can have a favorable prognosis when gross total tumor resection is achieved [9, 10]. However, since aggressive surgical resection of tumors in deep brain areas may be associated with a high risk of damaging crucial neurovascular structures, it is important for surgeons to understand the natural history of central neurocytomas. In particular, tumors with a large volume can occupy the bilateral ventricles. The key to

treatment is to select the appropriate surgical approach to achieve the maximum range of safe tumor resection and to prevent postoperative complications, such as brain edema and hydrocephalus. At the same time, whether radiotherapy should be directly performed after surgical resection is still controversial [11]. Of the 29 patients in this group, 23 patients had an average maximum tumor diameter greater than 50 mm, 27 patients achieved gross total tumor resection, and 5 patients received radiotherapy after the first operation. We subsequently discuss these patients' clinical treatment experiences.

Surgical resection is the most fundamental treatment for central neurocytoma [12, 13]. The common surgical approaches are transcortical and transcallosal approaches [14]. However, the optimal surgical approach remains controversial [15, 16]. Some studies have suggested that the transcortical approach is more appropriate when the tumor is located in the lateral ventricle, while the transcallosal approach is considered more appropriate for tumors located in the third ventricle due to a shorter surgical path and reduced damage to the cortex [17]. In the present study, although some patients experienced hemiplegia, aphasia, fever, epilepsy and other complications, except for one case, patients did not have permanent neurological deficits. This result indicated that these complications are related to temporary brain swelling after damage to normal brain tissue, but no major reflux veins were injured. The surgeon suggested that although many of the tumors in this group occupied the bilateral ventricles, most of the tumors originated from unilateral ventricles and squeezed the septum pellucidum to the contralateral ventricle. Therefore, large tumors can be completely removed through a unilateral transcortical approach. At the same time, transcortical access to the ventricles is more direct, and it can avoid damaging the corpus callosum and the main frontal cortical veins. However, in addition to the tumor volume, other major factors influencing the effect of surgery include the degree of calcification of the tumor, the degree of adhesion between the tumor and its surroundings, the blood supply of the tumor, and the experience of the surgeon.

Hydrocephalus is a serious postoperative complication of intraventricular central neurocytoma. In this group, 5 patients with hydrocephalus were treated with ventriculoperitoneal shunts after dehydration therapy failure. In summary, according to our experience, the normal veins and tissues of the ventricle should be protected as much as possible and over-stretching of brain tissue should be avoided during surgery to prevent postoperative hydrocephalus [14]. Extraventricular drainage should be performed during long operations, and the drainage tube should be strictly controlled at the appropriate height after the operation to prevent collapse of the ventricle caused by rapid drainage. Moreover, bleeding should be strictly controlled during the operation to prevent blood from flowing into the ventricle, which may induce inflammatory adhesion of the ventricle.

Whether radiotherapy should be used after central neurocytoma surgery remains controversial. Some reports suggest that patients should be treated with postoperative radiotherapy to prevent and treat residual tumor recurrence [18-21]. In this group, 5 patients (23.8%) received radiotherapy after the first operation. None of the patients who received radiotherapy had tumor progression. Among the patients without radiotherapy, three had tumor recurrence. One patient had tumor recurrence one year after the operation and then underwent reoperation and radiotherapy. The other two patients had tumor recurrence

two and three years after the operation and received radiotherapy. At the last follow-up visit, these three patients had no signs of tumor recurrence. However, in recent years, postoperative radiotherapy has been reported to have no effect on the overall survival rate of patients [17], and the delayed complications of radiotherapy, such as radiation necrosis, leukoencephalopathy, cognitive dysfunction and even radiation-induced malignant tumors, have received increasing attention in recent years [9]. No statistical correlation was found between radiotherapy and the tumor recurrence rate in this group of patients, but we found a significant statistical correlation between memory decline and radiotherapy (P = 0.017). Considering that the most common pathological grade of central neurocytoma is WHO II, which applies to benign tumors, theoretically, progression is slow. Therefore, since 2015, we no longer suggest that patients should receive radiotherapy directly after surgery. Instead, we suggest that, for these patients, MRI should be reviewed regularly after the operation. Changes in the condition should be monitored closely, and radiotherapy should be considered if progression is observed.

Immunohistochemical results are mainly used to determine the diagnosis and prognosis of central neurocytoma. Syn [22] and NeuN are reliable diagnostic indexes of central neurocytoma. In most cases, syn staining was positive. NeuN is mainly used to distinguish clear cell tumors of the central nervous system (central neurocytoma, oligodendrocytoma, clear cell ependymoma). According to previous studies, MIB-1 (Ki-67) may be a prognostic indicator [23]. When MIB-1 (Ki-67) expression is greater than 2%/3%, the prognosis of patients may be poor [24]. This indicator plays an important role in guiding postoperative adjuvant treatment and judging prognosis. Patients with high levels of MIB-1 expression are more likely to relapse than patients with low MIB-1 expression of. However, in contrast to previous reports, we did not find that MIB-1 expression was related to tumor recurrence in this group of patients, which may be related to our small number of cases.

Limitations

Although we presented the clinical data of 29 patients with central neurocytomas, some limitations of this study remain. Due to the limited number of cases, a certain degree of statistical deviation exists. For example, we hold that the extent of resection and radiotherapy may be related to tumor recurrence, but our data analysis showed no statistical correlation. Therefore, a larger sample size is needed in future studies. Additionally, in this group, most patients were treated with surgical resection via transcortical fistulotomy, and the results could not be directly compared with those of other surgical methods.

Conclusions

Surgical resection of the tumor is the basis of treatment for central neurocytoma. With total resection of the tumor, patients may be completely cured. At the same time, the transcortical approach is a reliable approach for removal of large tumors in the ventricles. This approach is not only conducive to total removal of large central neurocytomas in the ventricles but also better avoids injury to the corpus callosum and protects normal ventricular structure and venous return. Finally, patients should be

observed closely after surgery, and MRI of the head should be reevaluated regularly. If a tumor shows progression, then radiotherapy should be considered.

Abbreviations

CN: Central Neurocytoma;

KPS: Karnofsky Performance Status

CT: Computed Tomography

Declarations

Ethics approval and consent to participate

This study was approved by the ethics committees of the two medical centers. The requirement for obtaining informed consent from patients was waived because the data sets were anonymous.

Consent for publication

Not applicable.

Availability of data and materials

The datasets supporting the conclusions of this study are available from the corresponding author upon reasonable request.

Competing interests

The authors declare that they have no competing interests.

Funding

The study was supported by the Hainan Provincial Natural Science Foundation of China (Funding code: 819QN351) and the Key Research and Development Projects of Hainan Province (Funding code: ZDYF2019173).

Authors' contributions

Conception and design: Zhixian Gao, Jiannong Zhao and Nan Ji. Acquisition of the data: Lanbing Yu, Bo Cen, Yehong Fang, and Heyuan Jia. Analysis and interpretation of the data: Chaocai Zhang and Junling Wang. Drafting of the article: Chaocai Zhang. Critical revision of the article: Zhixian Gao, Jiannong Zhao and Nan Ji. Review of the submitted version of the manuscript: Zhixian Gao, Jiannong Zhao, Nan Ji, Lanbing Yu, and Shuyu Hao. Statistical analysis: Chaocai Zhang. Study supervision: Zhixian Gao.

Acknowledgements

Not applicable.

References

1. Choudhari KA, Kaliaperumal C, Jain A, Sarkar C, Soo MY, Rades D, et al. Central neurocytoma: a multi-disciplinary review. Br J Neurosurg. 2009;23:585-95.
2. Hassoun J, Gambarelli D, Grisoli F, Pellet W, Salamon G, Pellissier JF, et al. Central neurocytoma. An electron-microscopic study of two cases. Acta Neuropathol. 1982;56:151-6.
3. Louis DN, Perry A, Reifenberger G, von Deimling A, Figarella-Branger D, Cavenee WK, et al. The 2016 World Health Organization classification of tumors of the central nervous system: a summary. Acta Neuropathol. 2016;131:803-20.
4. Vajrala G, Jain PK, Surana S, Madigubba S, Immaneni SR, Panigrahi MK. Atypical neurocytoma: dilemma in diagnosis and management. Surg Neurol Int. 2014;5:183.
5. Mahavadi AK, Patel PM, Kuchakulla M, Shah AH, Eichberg D, Luther EM, et al. Central neurocytoma treatment modalities: a systematic review assessing the outcomes of combined maximal safe resection and radiotherapy with gross total resection. World Neurosurg. 2020;137:e176-82.
6. Dutta SW, Kaleem TA, Muller DA, Peterson J, Harrell AC, Quinones-Hinojosa A, et al. Central neurocytoma: clinical characteristics, patterns of care, and survival. J Clin Neurosci. 2018;53:106-11.
7. Byun J, Hong SH, Yoon MJ, Kwon SM, Cho YH, Kim JH, et al. Prognosis and treatment outcomes of central neurocytomas: clinical interrogation based on a single center experience. J Neurooncol. 2018;140:669-77.
8. Wang M, Zhou P, Zhang S, Liu X, Lv L, Wang Z, et al. Clinical features, treatment, and long-term outcomes of central neurocytoma: a 20-year experience at a single center. World Neurosurg. 2018;109:e59-66.
9. Kim JW, Kim DG, Kim IK, Kim YH, Choi SH, Han JH, et al. Central neurocytoma: long-term outcomes of multimodal treatments and management strategies based on 30 years' experience in a single institute. Neurosurgery. 2013;72:407-13; discussion 413-4.
10. Yang I, Ung N, Chung LK, Nagasawa DT, Thill K, Park J, et al. Clinical manifestations of central neurocytoma. Neurosurg Clin N Am. 2015;26:5-10.
11. Chen YD, Li WB, Feng J, Qiu XG. Long-term outcomes of adjuvant radiotherapy after surgical resection of central neurocytoma. Radiat Oncol. 2014;9:242.
12. Imber BS, Braunstein SE, Wu FY, Nabavizadeh N, Boehling N, Weinberg VK, et al. Clinical outcome and prognostic factors for central neurocytoma: twenty year institutional experience. J Neurooncol. 2016;126:193-200.
13. Lubrano V, François P, Loundou A, Vasiljevic A, Roche PH. Outcomes after surgery for central neurocytoma: results of a French multicentre retrospective study. Acta Neurochir (Wien).

2013;155:1261-9.
14. Wang X, Liu YH, Mao Q. Retractorless surgery for third ventricle tumor resection through the transcallosal approach. Clin Neurol Neurosurg. 2017;155:58-62.
15. Milligan BD, Meyer FB. Morbidity of transcallosal and transcortical approaches to lesions in and around the lateral and third ventricles: a single-institution experience. Neurosurgery. 2010;67:1483-96; discussion 1496.
16. Seçer HI, Düz B, Izci Y, Tehli O, Solmaz I, Gönül E. Tumors of the lateral ventricle: the factors that affected the preference of the surgical approach in 46 patiens. Turk Neurosurg. 2008;18:345-55.
17. Patel DM, Schmidt RF, Liu JK. Update on the diagnosis, pathogenesis, and treatment strategies for central neurocytoma. J Clin Neurosci. 2013;20:1193-9.
18. Monaco EA, 3rd, Niranjan A, Lunsford LD. The management of central neurocytoma: radiosurgery. Neurosurg Clin N Am. 2015;26:37-44.
19. Yamanaka K, Iwai Y, Shuto T, Kida Y, Sato M, Hayashi M, et al. Treatment results of gamma knife radiosurgery for central neurocytoma: report of a Japanese multi-institutional cooperative study. World Neurosurg. 2016;90:300-5.
20. Kim JW, Kim DG, Chung HT, Choi SH, Han JH, Park CK, et al. Radiosurgery for central neurocytoma: long-term outcome and failure pattern. J Neurooncol. 2013;115:505-11.
21. Nakamura A, Kano H, Niranjan A, Lunsford LD. Radiosurgery for central neurocytoma. Prog Neurol Surg. 2019;34:232-7.
22. Xiao X, Zhou J, Wang J, Yang L, Wang C, Xu Y, et al. Clinical, radiological, pathological and prognostic aspects of intraventricular oligodendroglioma: comparison with central neurocytoma. J Neurooncol. 2017;135:57-65.
23. Lee SJ, Bui TT, Chen CHJ, Lagman C, Chung LK, Sidhu S, et al. Central neurocytoma: a review of clinical management and histopathologic features. Brain Tumor Res Treat. 2016;4:49-57.
24. Rades D, Schild SE, Fehlauer F. Prognostic value of the MIB-1 labeling index for central neurocytomas. Neurology. 2004;62:987-9.

Figures

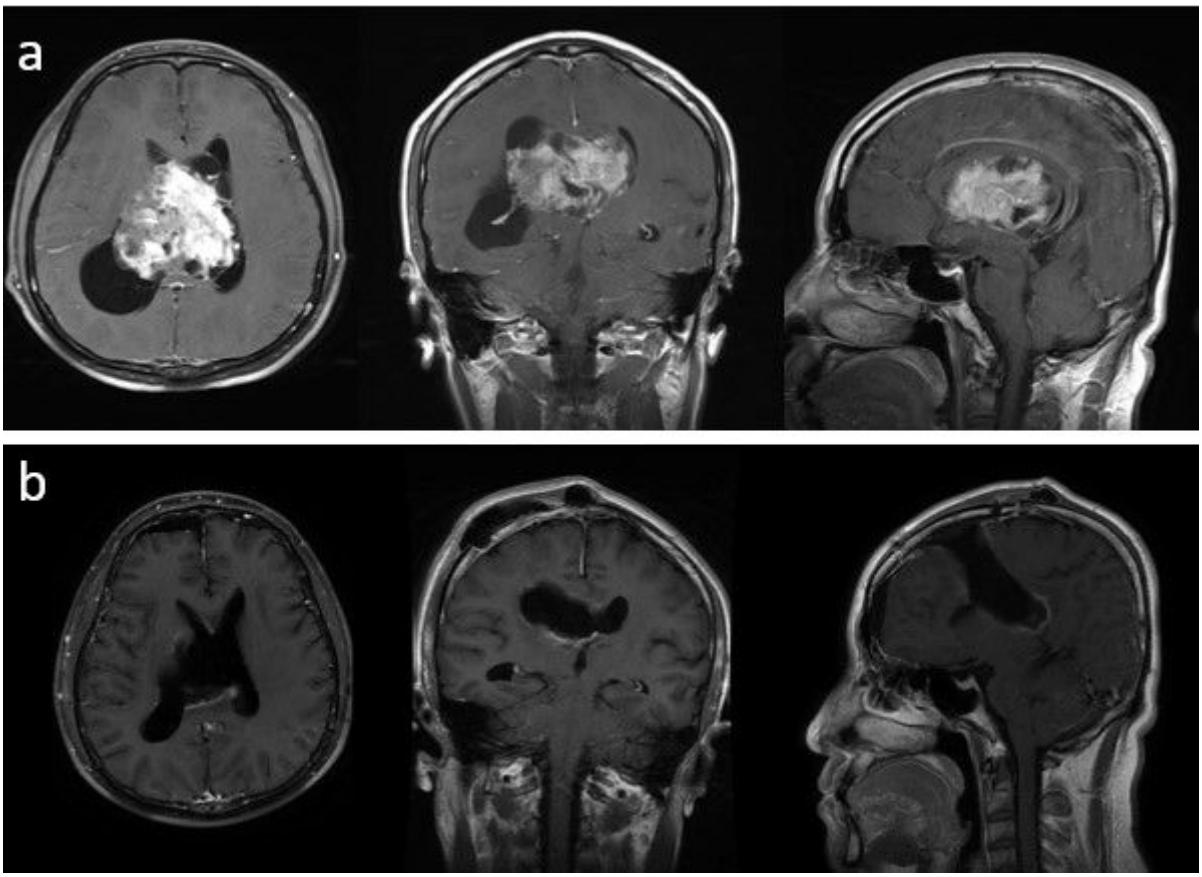

Figure 1

Head MRI of a central neurocytoma patient who underwent tumor resection with a transcortical approach. a: Preoperative enhanced head MRI; b: Postoperative enhanced head MRI. The tumor was subjected to gross total resection.

Supplementary Files

This is a list of supplementary files associated with this preprint. Click to download.

- 4CJHQ2966653A279246E1A836F8P.pdf