Does Myocardial Bridge Appear More Frequently and Diffusely on Radial Access Coronary Angiography?

oktay senoz (oktaysenoz@hotmail.com)

Bakırcay University Cigli Training and Research Hospital Department of Cardiology

zeynep yapan emren

Bakırcay University Cigli Training and Research Hospital Department of Cardiology

Research Article

Keywords: myocardial bridge, conventional coronary angiography (CCA), radial access coronary angiography (RACA)

Posted Date: May 28th, 2021

DOI: https://doi.org/10.21203/rs.3.rs-537384/v1

Abstract

Background: Although the incidence of myocardial bridge (MB) has been defined in different conventional coronary angiography (CCA) studies,the frequency of MB in radial access coronary angiography (RACA) is unknown.The aim of this study was to determine the incidence of MB in patients undergoing RACA.

Method: A total of 2600 consecutive patients who underwent RACA were retrospectively investigated to detect the presence of MB.The clinical,laboratory, and angiographic features of the patients with MB were analyzed.

Results: MB was detected at an incidence of 10.2%, in 255/2600 patients who underwent RACA.The most involved coronary artery was the left anterior descending artery (LAD) (86.9%) and the mid segment (84.9%) was the most affected section.Co-involvement of multiple coronary arteries by MB was 7.8%. Coronary artery disease (CAD) was determined in 102 (36.2%) of the coronary arteries with MB, 82.4% which were proximal to the MB.

Conclusion: These data demonstrated that the incidence of MB able to be detected on RACA was much higher than reported in previous CCA studies.

Introduction

Myocardial bridge (MB) is an anatomic variation in which some of the epicardial coronary arterial segments run into the myocardium.MB is characterized by narrowing during systole of the coronary artery by overlying muscle fibers [1, 2].It usually occurs in the mid-segment of the left anterior descending coronary artery (LAD) [3, 4].MB may affect other coronary arteries less frequently and occasionally, all of them [5].Although MB is known to be usually benign, it may sometimes cause myocardial ischemia,arrhythmia,syncope and sudden cardiac death [6, 7].Coronary heart disease can be caused by MB both by direct compression in cardiac systole and by exacerbation of atherosclerosis progression in the vessel proximal to the MB [8, 9]. There is a great difference in the incidence of MB reported in angiographic series (0.5–2.5%) and in autopsy series (15–85%) [10].It has been shown that the frequency and extent of MB may differ according to imaging techniques.In comparative studies of the same patient population,the frequency of MB was 6% with conventional coronary angiography (CCA), and 30% with computed tomography coronary angiography (CTCA) [11].Those results confirmed that CCA is not sensitive enough to detect MB, especially of a mild type [12].Radial access for coronary angiography has been shown to reduce major bleeding and ischemic events compared to femoral access [13].Therefore,radial access has been the principal approach for coronary angiography in recent years.The aim of this study was to determine the incidence of MB in patients undergoing RACA with the administration of nitroglycerin and diltiazem.

Method

A retrospective evaluation was made of the coronary angiographies of 2600 consecutive patients who underwent RACA between January 2018 and February 2021.Patients with a history of coronary artery bypass grafting (CABG) were excluded from the study.Patients who underwent RACA for the diagnosis of coronary artery disease were grouped according to clinical conditions as non-anginal symptoms,stable angina pectoris (SAP),unstable angina pectoris (USAP), non-ST segment elevation myocardial infarction (NSTEMI), and ST segment elevation myocardial infarction (STEMI).Cardiac single photon emission computed tomography (SPECT) was positive in 24 and the treadmill exercise test was positive in 60 of these patients.The clinical,laboratory and angiographic features of patients with MB were analyzed.

The right radial artery was cannulated with a 6-f radial sheath after local infiltration with 2% lidocaine.All patients received 5000 units of unfractionated heparin, 100–200 µg (depending on blood pressure) of nitroglycerin and 5 mg of diltiazem unless there was an absolute contraindication to diltiazem and anticoagulants.Coronary angiography was performed using the standard Judkins` technique via right radial access with a 5-f diagnostic catheter.Standard angiography images were obtained with a biplane cine-angiography system.Each angiogram was reviewed by the same two qualified cardiologists.The presence of MB was defined as the narrowing of the coronary artery lumen in systole and dilatation in diastole with no evidence of coronary vasospasm.The extent and severity of MB and its relationship with coronary artery disease (CAD) were examined on cine-angiograms.The quantification of systolic lumen compression and atherosclerotic stenosis in the coronary artery was performed using a digital caliper program to measure the lumen diameter reduction.The patients were separated into 3 groups according to the degree of systolic lumen compression caused by MB.

Group – 1 (mild): Systolic lumen compression < 50%,

Group – 2 (moderate): Systolic lumen compression between 51% and 70%,

Group – 3 (severe): Systolic lumen compression > 71%.

The patients were also separated into 3 groups according to the degree of luminal narrowing caused by atherosclerotic stenosis.

Group – 1 (mild): Luminal narrowing between 30% and 50%,

Group – 2 (moderate): Luminal narrowing between 51% and 70%,

Group – 3 (severe): Luminal narrowing > 71% .

Statistical analysis

Data obtained in the study were analyzed statistically using SPSS for Windows, vn.15.0 (SPSS Inc., Chicago, IL, USA).Conformity of the data to normal distribution was assessed using the Kolmogorov-Smirnov test.Continuous variables were reported as mean ± standard deviation (SD),median,minimum and maximum values, and categorical variables as number (n) and percentage (%).

Results

MB was detected in 255 of 2600 patients who underwent RACA,giving a total incidence of 10.2%.The 255 patients comprised 196 (76.9%) males and 59 (23.1%) females with a mean age of 57.5 ± 11.3 years (range, 25–83 years; median, 59 years).Hypertension was determined in 137 (53.7%) patients.The echocardiographic findings showed left ventricular concentric hypertrophy (LVCH) in 86 patients,hypertrophic obstructive cardiomyopathy (HOCM) in 4, and aortic stenosis (AS) in 4.The demographic data and clinical features of the patients are presented in Table 1, and the laboratory features in Table 2.More than 90% (235/255) of patients had single vessel MB (Fig. 1), and 20 cases had more than one vessel MB (2 vessels in 13 patients, 3 vessels in 7) (Table 3).These patients had a total of 282 coronary arteries with MB.The most involved coronary artery was LAD (86.9%, 245/282) and the most affected section of LAD was the mid segment (84.9%, 208/245) followed by distal (13.9%, 34/245) and proximal (1.2%, 3/245) segments.The mean length of MBs on angiography was 18.2 ± 4.9 mm.Three groups were constituted according to the degree of systolic compression of the epicardial coronary artery among single vessel MBs; Group 1 comprised 45.9% of the patients, Group 2 25.1%, and Group 3 28.9%.The angiographic characteristics of the patients according to the MB grades are presented in Table 4.Of the coronary arteries with MB, 102 (36.2%) had CAD, of which 82.4% (84/102) were proximal to the MB. Of these cases with proximal CAD, 62 were mild, 2 were moderate, and 20 were severe.

Table 1
Demographic and clinical characteristics of the patients.

Variables		Patients (n:255)
Age, years (mean ± SD)		57.5 ± 11.3
male gender, n (%)		196 (76.9)
Hypertension, n (%)		137 (53.7)
Diabetes mellitus, n (%)		63 (24.7)
Smoking, n (%)		104 (40.8)
Hypercholesterolemia, n (%)		127 (49.8)
Chronic renal failure, n (%)		20 (7.8)
CVD history, n (%)		5 (1.9)
HOCM, n (%)		4 (1.6)
LVCH, n (%)		86 (33.7)
Aortic stenosis, n (%)		4 (1.6)
LVDD, n (%)		188 (73.7)
LVEF, % (mean ± SD)		57.1 ± 6
Admission clinic, n (%)	Non-anginal symptoms	59 (23.1)
	Stable angına	107 (42)
	Unstabil angına	33 (12.9)
	Anterior MI	3 (1.2)
	Inferior MI	15 (5.9)
	Other MIs	38 (14.9)
Arrhythmia, n (%)	Atrial	3 (1.2)
	Ventricular	2 (0.8)

Abbreviations: SD, standard deviation; n, number of patients; CVD, cerebrovascular diseases; HOCM, hypertrophic obstructive cardiomyopathy; LVCH, left ventricular concentric hypertrophy; LVDD, left ventricular diastolic dysfunction; LVEF, left ventricular ejection fraction.

Table 2
Laboratory features of the patients.

Variables (mean ± SD)	Patients (n:255)
Creatinine, mg/dl	0.98 ± 0.5
Fasting blood glucose, mg/dl	120.1 ± 46.8
Total cholesterol, mg/dl	187.6 ± 47.4
HDL-cholesterol, mg/dl	40.1 ± 11.9
LDL-cholesterol, mg/dl	114.1 ± 42.2
Plasma triglycerides, mg/dl	172.4 ± 105.8
White blood cell count, × 10^9 /L	8.8 ± 3.1
Neutrophil count, × 10^9 /L	5.6 ± 2.5
Lymphocyte count, × 10^9 /L	2.2 ± 1.1
Platelet count, × 10^9 /L	248.7 ± 63.9
Hemoglobin, g/dl	13.7 ± 1.6
Hematocrit, %	41.3 ± 5.4
Mean platelet volume, fl	8.4 ± 1.1

Table 3
Distribution of MBs on coronary arteries

Coronary Artery	Patients n:255
LAD, n (%)	225 (88.2)
CX, n (%)	2 (0.8)
RCA, n (%)	8 (3.1)
LAD and CX, n (%)	9 (3.5)
LAD and RCA, n (%)	4 (1.6)
LAD,CX and RCA, n (%)	7 (2.7)
Abbreviations: n, number of patients; CX, circumflex artery;	
LAD, left anterior descending artery; RCA, right coronary artery.	

Table 4
Angiographic characteristics of the single vessel MB patients according to MB grades

Variables		Group 1 (MB < 50%) (n:108)	Group 2 (51%< MB < 70%) (n:59)	Group 3 (MB > 71%) (n:68)	Total (n:235)
LAD, n (%)		103 (95.4)	57 (96.6)	65 (95.6)	225 (95.7)
CX, n (%)		2 (1.9)	0	0	2 (0.9)
RCA, n (%)		3 (2.8)	2 (3.4)	3 (4.4)	8 (3.4)
Mean length of MB, mm (mean ± SD)		17.8 ± 4.9	16.5 ± 4.2	20.3 ± 4.6	18.2 ± 4.9
Affected segment of vessel from MB, n (%)	Proximal	1 (0.9)	2 (3.4)	1 (1.5)	4 (1.7)
	Mid	92 (85.2)	51 (86.4)	61 (89.7)	204 (86.8)
	Distal	15 (13.9)	6 (10.2)	6 (8.8)	27 (11.5)

Abbreviations: SD, standard deviation; n, number of patients; CX, circumflex artery; LAD, left anterior descending artery; MB, myocardial bridge; RCA, right coronary artery.

Discussion

The results of this study showed the incidence of MB to be 10.2% in patients who underwent RACA.

MB is a congenital coronary artery anomaly,which is usually detected incidentally in coronary angiography performed for the diagnosis of coronary atherosclerosis.The incidence of MB differs between autopsy studies (15–85%) and angiographic studies (0.5-2.5%) [10]. Furthermore, the incidence of MB varies according to the coronary angiography method.For example, 0.6% incidence of MB in CCA was reported by Harikishen et al, whereas Kantarci et al. determined MB incidence of 3.5% in CTCA [14,15].In another study, Lu et al. found the incidence of MB to be 6% with CCA, and 30% with CTCA in the same population [11].The main reason for this difference is the variability in the sensitivity of coronary angiography methods in the detection of MB.Other factors that may affect the incidence of MB are the size and ethnicity of the study samples.Luminal narrowing is dynamic in CCA and mild systolic compressions may be overlooked.Structural evaluation can be performed with CTCA and the coronary artery course can be clearly observed, but superficial MBs may not be seen.In the current study,the main reason for the higher MB incidence compared to CCA studies was thought to be the routine use of nitroglycerin and diltiazem during the procedure.Nitroglycerin and diltiazem reduce coronary artery

resistance [16,17].As a result of the synergistic effect of nitroglycerin and diltiazem, even low doses can dramatically modify coronary artery resistance. Nitroglycerin augments vessel wall constriction in patients with MB and previously unseen MBs can appear after the administration of nitroglycerin in coronary angiography.In addition, nitroglycerin increases vascular compliance, and facilitates diastolic expansion as well as systolic compression, so MB can be easily detected [18].

The most common coronary artery affected by MB is the LAD mid segment, as indicated both in the current study and many other studies [19-22].Although a previous study from Turkey reported almost equal distribution of MBs in the LAD middle and distal segments and no MB present in the proximal segment, the current study results showed much higher involvement of the LAD mid segment than proximal and distal segments [23].Compared to previous CCA studies, not only the MB incidence but also the number of simultaneously affected coronary arteries was higher in the current study.Although some studies [2,5,14,23] have shown that more than one coronary artery was almost never involved simultaneously, the involvement of two or three coronary arteries together was 5.1% and 2.7%, respectively in the current study. The reason for this,just like the incidence difference,can be attributed to the use of nitroglycerin and diltiazem enabling the detection of previously unseen MBs.In a cadaver study, it was shown that almost all major branches of both coronary arteries were affected and 36% of the samples had more than one MB[5].

There has been considerable controversy regarding the functional significance of MB.Some studies have stated that MB may be associated with ischemia,arrhythmia, and sudden cardiac death,while others have claimed that it is benign and may even protect against atherosclerosis [24-28].In the current study,ventricular tachycardia was observed in 2 patients before coronary angiography, but in both cases was due to acute myocardial infarction.It is generally accepted that MB causes coronary atherosclerosis in the LAD segment proximal to the MB and enhances its natural progression through several different mechanisms [3,9,10,29].Similar to those studies, 36.2% of the current study patients with MB had CAD, of which more than 80% were proximal to the MB, and the majority were mild degree (luminal narrowing between 30% and 50%).

There are 3 different therapeutic approaches for patients with symptomatic MB: Medication, stent placement in the bridged segment, and surgical treatment [8].Due to reducing coronary compression,beta-blocker therapy is the first choice of treatment for symptomatic patients [30].Stent implantation therapy in the bridge segment remains controversial.Some studies [31,32] have stated that this therapy reduces direct coronary compression and improves coronary reserve flow,while others [32-34] have highlighted adverse effects of this therapy, such as coronary perforation,stent fracture, and early in-stent re-stenosis.Myotomy as a surgical treatment is a good option for patients refractory to medical therapy with good long-term results [8,35].All the patients in the current study were treated medically and none required surgical treatment.

This study had some important limitations,primarily that it was a retrospective,observational, single-centre study.Therefore,the population investigated might have been heterogeneous. Further investigation

was not performed for the incidence of MB in patients who underwent femoral access coronary angiography and the incidence of MB in those who underwent RACA was compared with previous CCA studies.The clinical significance of MB and its relationship with symptoms was not investigated.Dedicated clinical studies would be required to determine the relationship of MB with clinical symptoms by proving the presence of ischemia,especially in the absence of atherosclerotic coronary artery stenosis.

Conclusion

The results of this study demonstrated that the MB incidence in RACA patients was much higher than the rates reported in previous CCA studies.The LAD mid segment was the most affected coronary artery.Multiple coronary artery involvement was not uncommon and approximately one-third of the patients with MB had CAD proximal to MB.

Declarations

Ethics approval and consent to participate

The study was designed in accordance with the principles of the declaration of Helsinki and got approval from the local ethics committee of our hospital (Bakırcay University Medicine Faculty (Decision number: 223).

Written informed consent was obtained from all patients included in the study.Patients younger than 18 years old were not included in the study.

Consent for publication

Not applicable.

Availability of data and materials

The datasets used and/or analysed during the current study available from the corresponding author on reasonable request.

Competing interests

The authors have no financial conflicts of interest.

Funding

None

Authors' contributions

O.S. collected study data,wrote the main manuscript text and prepared figures and tables

Z.YE. applied statistics and reviewed the manuscript

Acknowledgements

Not applicable

References

1. Zoghi M, Duygu H, Nalbantgil S, et al. Impaired Endothelial Function in Patients with Myocardial Bridge. Echocardiography 2006; 23: 577–581.https://doi.org/10.1111/j.1540-8175.2006.00279.x
2. Li J, Shang Z, Min Y, et al. Angiographic prevalence of myocardial bridging in a defined very large number of Chinese patients with chest pain. Chinese medical journal 2008; 21: 405–408.
3. Angelini P, Trivellato M, Donis J, Leachman RD. Myocardial bridges: A review. Prog Cardiovasc Dis 1983; 26: 75–88.
4. Ishii T, Asuwa N, Masuda S, Ishikawa Y. The effects of a myocardial bridge on coronary atherosclerosis and ischaemia. J Pathol 1998; 185: 4–9.
5. Bandyopadhyay M, Das P, Baral K, Chakroborty P. Morphological study of myocardial bridge on the coronary arteries. Indian J Thorac Cardiovasc Surg 2010; 26: 193–197.
6. Bauters C, Chmait A, Tricot O, et al. Coronary thrombosis and myocardial bridging. Circulation 2002;105: 130. https://doi.org/10.1161/hc0102.100421
7. Rossi L, Dander B, Nidasio GP, et al. Myocardial bridges and ischemic heart disease. Eur Heart J 1980; 1:239–245.
8. Ishikawa Y, Kawawa Y, Kohda E, et al. Significance of the Anatomical Properties of a Myocardial Bridge in Coronary Heart Disease: A review. Circulation Journal J-stage 2011; 75: 1559.
9. Möhlenkamp S, Hort W, Ge J, Erbel R. Update on myocardial bridging. Circulation 2002; 106: 2616–2622. https://doi.org/10.1161/01.CIR.0000038420.14867.7A
10. Bourassa MG, Butanaru A, Lesparance J, Tardiff JC. Symptomatic myocardial bridges: overview of ischemic mechanisms and current diagnostic and treatment strategies. J Am Coll Cardiol. 2003;41:351–9.
11. Lu GM, Zhang LJ, Guo H, Huang W, Merges RD. Comparison of myocardial bridging by dual-source CT with conventional coronary angiography. Circ J 2008;72:1079–1085.

12. Hwang J H, Ko S M,Roh H G, et al. Myocardial Bridging of the Left Anterior Descending Coronary Artery: Depiction Rate and Morphologic Features by Dual Source CT Coronary Angiography.Korean J Radiol 2010;11:514–521.
13. Jolly S S, Amlan S, Hamon M, et al. Radial versus femoral access for coronary angiography or intervention and the impact on major bleeding and ischemic events: A systematic review and meta-analysis of randomized trials.American Heart J. 2009; 157: 132–140.
14. Harikrishnan S, Sunder KR, Tharakan J, et al. Clinical and angiographic profile and follow-up of myocardial bridges: a study of 21 cases. Indian Heart J. 1999;51:503–7.
15. Kantarci M, Duran C, Durur I, et al. Detection of myocardial bridge with ECG-gated MDCT and multiplanar reconstruction. AJR 2006; 186:391–394.
16. Joyal M, Cremer F. K, Pieper A. J, et al. Systemic, left ventricular and coronary hemodynamic effects of intravenous diltiazem in coronary artery disease. American Journal of Cardiology 1985; 56:413–417.
17. Fam M.W, McGregor M. Effect of Nitroglycerin and Dipyridamole on Regional Coronary Resistance. Circulation 1968;22:649–659.
18. Hongo Y, Tada H, Ito K, et al. Augmentation of vessel squeezing at coronary-myocardial bridge by nitroglycerin: Study by quantitative coronary angiography and intravascular ultrasound.American heart journal 1999; 138: 345–350.
19. Geiringer E. The mural coronary. Am Heart J 1951; 41:359–368.
20. Polacek P. Relation of myocardial bridges and loops on the coronary arteries to coronary occlusion. Am Heart J 1961; 61:44–52.
21. Noble J, Bourassa MG, Petitclerc R, Dyrda I. Myocardial bridge and milking effect of the left anterior descending coronary artery: normal variant or obstruction? Am J Cardiol 1976; 37:993–999.
22. Kramer JR, Kitazume H, Proudfit WL, Sones FM Jr. Clinical significance of isolated coronary bridges: benign and frequent condition involving the left anterior descending artery. Am Heart J 1982; 103:283–288.
23. Cay S, Oztürk S, Cihan G, Kisacik HL, Korkmaz. Angiographic prevalence of myocardial bridging. Anadolu Kardiyol Derg 2006; 6: 9–12.
24. Dean JW, Mills PG: Abnormal ventricular repolarization in association with myocardial bridging. Br Heart J 1994;71: 366–367.
25. Faruqui AMA, Maloy WC, Feiner JM, Schilant RC, Logan WD, Symbas P: Symptomatic myocardial bridging of coronary artery. Am J Cardiol 1978; 41: 1305–11.
26. Feldman AM, Baughman KL: Myocardial infarction associated with a myocardial bridge. Am Heart J:1986; 1, 784.
27. Ishii T, Asuwa N, Masuda S, Ishikawa Y, Kiguchi H, Shimada K: Atherosclerosis suppression in the left anterior descending coronary artery by the presence of a myocardial bridge: an ultrastructural study. Modern Pathology 1991; 4: 424–431.

28. Soran O, Pamir G, Erol C, et al. The incidence and significance of myocardial bridge in a prospectively defined population of patients undergoing coronary angiography for chest pain. Tokai J Exp Clin Med. 2000;25:57–60.
29. Ishikawa Y, Akasaka Y, Suzuki K, Fujiwara M, Ogawa T, Yamazaki K, et al. Anatomic properties of myocardial bridge predisposing to myocardial infarction. Circulation 2009; 120: 376–383.
30. Bestetti RB, Finzi LA, Amaral FTV, Secches AL, Oliveira JSM. Myocardial bridging of coronary arteries associated with an impending acute myocardial infarction. Clin Cardiol 1987; 10: 129–131.
31. Klue HG, Schwarz ER, vom Dahl J, Reffelmann T, Reul H, Potthast K, et al. Disturbed intracoronary hemodynamics in myocardial bridging: Early normalization by intracoronary stent placement. Circulation 1997; 96: 2905–2913.
32. Haager PK, Schwarz ER, vom Dahl J, Klues HG, Reffelmann T, Hanrath P. Long term angiographic and clinical follow up in patients with stent implantation for symptomatic myocardial bridging. Heart 2000; 84: 403–408.
33. Berry JF, von Mering GO, Schmalfuss C, Hill JA, Kerensky RA. Systolic compression of the left anterior descending coronary artery: A case series, review of the literature, and therapeutic options including stenting. Cathet Cardiovasc Interv 2002; 56: 58–63.
34. Tandar A, Whisenant BK, Michaels AD. Stent fracture following stenting of a myocardial bridge: Report of two cases. Cathet Cardiovasc Interv 2008; 71: 191–196. https://doi.org/10.1002/ccd.21365
35. Rezayat P, Hassan D, Amirreza S, Susan H. Myocardial bridge: Surgical outcome and midterm follow up. Saudi Med J 2006; 27: 1530–1533.

Figures

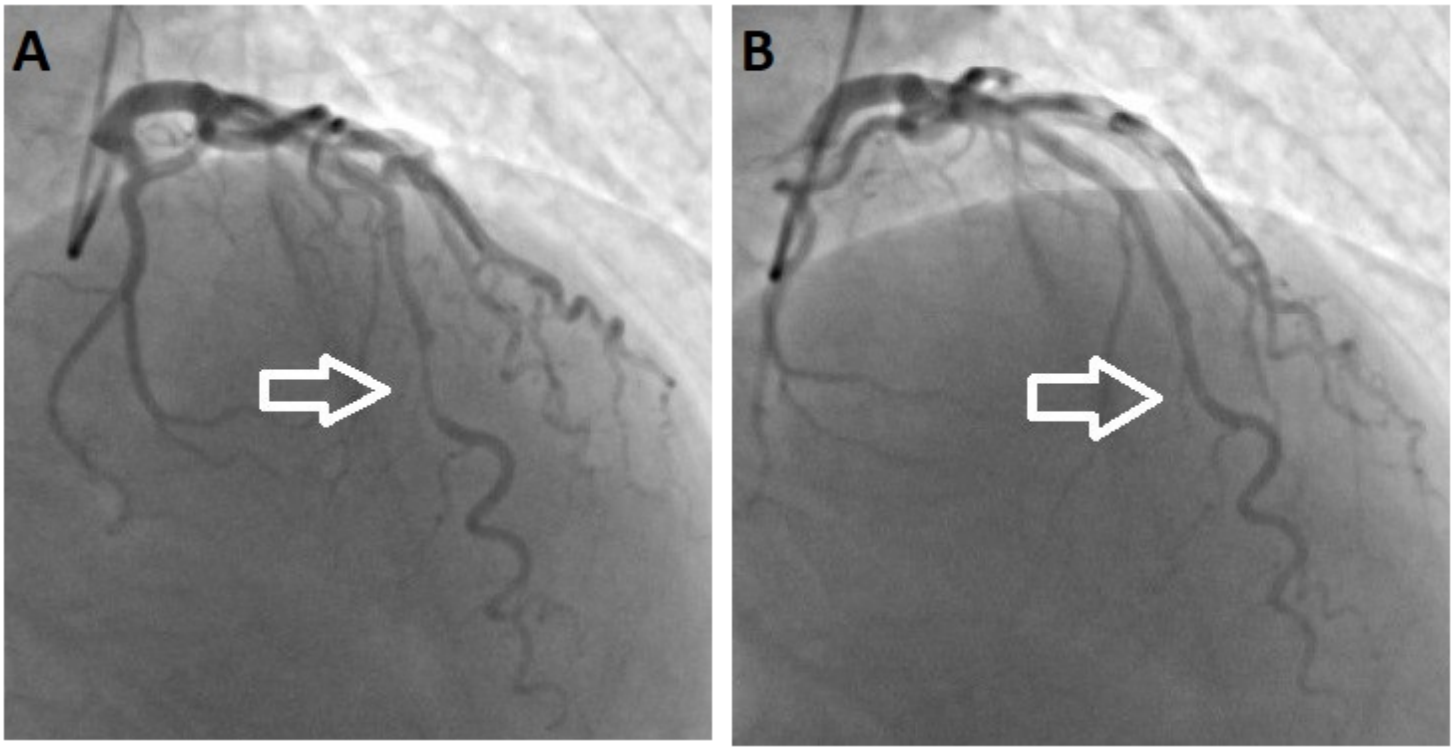

Figure 1

Severe degree MB in LAD, arrows show systolic compression (A) and diastolic expansion (B).