Assessing the Quality of Life Among Pediatric Population After Surgery for Recurrent Patellar Dislocation: a Prospective Cohort Study

Alexandru Herdea
Emergency Hospital for Children Grigore Alexandrescu: Spitalul Clinic de Urgenta pentru Copii Grigore Alexandrescu

Charkaoui Adham (charkaoui.adham@gmail.com)
Universitatea Dunarea de Jos din Galati Facultatea de Medicina si Farmacie https://orcid.org/0000-0002-3233-4393

Alexandra Toma
Universitatea Dunarea de Jos din Galati Facultatea de Medicina si Farmacie

Mihai-Codrut Dragomirescu
Emergency Hospital for Children Grigore Alexandrescu: Spitalul Clinic de Urgenta pentru Copii Grigore Alexandrescu

Vlad Pencea
Carol Davila University of Medicine and Pharmacy: Universitatea de Medicina si Farmacie Carol Davila

Alexandru Ulici
Emergency Hospital for Children Grigore Alexandrescu: Spitalul Clinic de Urgenta pentru Copii Grigore Alexandrescu

---

Research Article

Keywords: recurrent patellar dislocation, pediatric surgery, knee injury, lateral release and medial imbrication, medial patellofemoral ligament reconstruction, quality of life, pediatric orthopedics

Posted Date: May 20th, 2021

DOI: https://doi.org/10.21203/rs.3.rs-538327/v1

Abstract

Patellofemoral instability is a common cause of knee pathology that is affecting the quality of life among pediatric population.

Methods: We performed a prospective cohort study, including patients that underwent surgical management by using the Lateral Release and Medial Imbrication approach (LRMI) or Medial Patellofemoral Ligament Reconstruction (MPFL-R). The purpose of this study was the assessment of the quality of life among pediatric population that underwent surgery for patellar dislocation. The quality of life was evaluated before and after surgery using the Pediatric International Knee Documentation Committee form (Pedi-IKDC). The postoperative scar was evaluated using The Stony Brook Scar Evaluation Scale. 108 patients were selected and grouped according to the type of procedure.

Results: before surgery, the calculated Pedi-IKDC scores were similar between the two groups of patients. We identified substantial improvement in the postoperative score after surgery and the Medial Patellofemoral Ligament Reconstruction technique showed better results. The difference regarding the Pedi-IKDC score between the two groups was significant, in favor of the Medial Patellofemoral Ligament Reconstruction. By using the Stony Brook Scar Evaluation Scale, an important difference emerged between the two groups of patients in favor of the Medial Patellofemoral Ligament Reconstruction technique, revealing that it is a minimally invasive approach, improves recovery, reduces postoperative stay and increases the patients quality of life.

Conclusions: This study provides further evidence based results that support the recommendations regarding the Medial Patellofemoral Ligament Reconstruction technique as the gold standard for the patellofemoral instability.

Trial registration: The Ethics Committee of „Grigore Alexandrescu" Children's Emergency Clinical Hospital of Bucharest approved this study on 1st of March 2013. The project code is 7/01.03.2013. An informed parental consent was obtained for every participant.

Background:

The pain and the functional limitations represent the two main features of the pathology that implies the dislocation of the patella. Patellar dislocation requires a very complex approach starting with the diagnosis phase and ending with the final step, the treatment. An extensive anatomical knowledge and understanding the biomechanics of the patellofemoral joint is mandatory for an excellent therapeutic result.

The patellofemoral joint is a very elaborated articular system that gathers multiple static, active and also passive stablishing factors. The patellofemoral joint includes the undersurface of the patella bone and the cartilaginous anterior surface of the distal part of the femur, the trochlear groove. The acknowledgement of the significance of the bony alignment regarding the tibial tubercle and the trochlear

groove distance, trochlear dysplasia, patella alta and the femoral origin of the medial patellofemoral ligament (MPFL) is indispensable [1].

When referring to the patellofemoral instability we define it as the pathology generated by the disarticulation of the patellar bone from the patellofemoral joint. It is crucial that the specialist must fully understand the biomechanics of the knee articulation in order to apply the correct and most effective personalized treatment.

Patellofemoral instability is a common cause of knee injury that occurs in the pediatric population [1, 2]. Having an incidence rate of 29–43 per 100.000 patients, it often causes functional impairment in children [1]. The incidence of chronic instability is particularly high regarding the girls between 10 and 17 years old [3]. The stability of the patellofemoral joint depends on both bony and soft tissue structures [4]. Developmental anomalies, traumatic disruption of static restraints, and weak dynamic stabilizers can all lead to symptomatic instability [5].

Conservative treatment usually consists of cast or splint immobilization that will result in increased time in the rehabilitation period [6, 7]. The recurrence rate after conservative treatment can be up to 15–44% [8]. Even without recurrence, 70% of patients report residual pain or instability [9]. Physiotherapy also has an important role comprising quadriceps programs that focus on medial to lateral balance improvement as well as walking pattern re-education and jumping techniques [9, 10]. If conservative management fails to improve the patients' symptoms significantly, surgical treatment is the next recommended step [11].

In order to correctly asses a patellofemoral instability, clinical examination, conventional X-ray imaging and Magnetic resonance imaging are needed [12]. In most severe cases, Computed tomography followed by 3D reconstruction and 3D printing can help the orthopedic surgeon plan the safest and the most effective surgery approach [13].

Patient follow-up after surgery shows significant improvement in performing various tasks and thereby enhancement in quality of life for the patients [14]. There have been many useful techniques in the treatment of patellar dislocation but so far none of them have proven absolute superiority [15].

Methods:

The purpose of this study was to assess the quality of life (QOL) of patients that suffered from episodic patellar dislocation who were surgically treated by using the Lateral Release Medial Imbrication (LRMI) or Medial Patellofemoral Ligament reconstruction (MPFL-R).

The study was performed in an urban area emergency hospital for children, between 2013–2018, after positive diagnosis for patellofemoral recurrent dislocation. The Ethics Committee of "Grigore Alexandrescu" Children's Emergency Clinical Hospital of Bucharest approved this study on 1st of March 2013. The project code is 7/01.03.2013. An informed parental consent was obtained for every participant.

The diagnosis was established based on clinical findings, radiologic exams and magnetic resonance imaging scans, using the following inclusion criteria:

- history of multiple locked dislocations or locked dislocation present at admission
- presence of hemarthrosis
- positive apprehension test
- painful medial parapatellar structures and femoral epicondyle
- minimum follow-up of 24 months.

Knee radiographs performed in the antero-posterior and lateral view were used to identify complications such as avulsion fracture or femoral condyle osteochondral fracture, for these were among exclusion criteria. Lack of preoperative and postoperative knee radiographs, lack of informed consent were also considered exclusion criteria. Magnetic resonance imaging scans was used to evaluate the lesions involving the soft tissue. Magnetic resonance imaging was also used preoperatively in order to decide on a treatment plan by examining the growth plate, and to assess whether other additional procedures were needed, such as trochleoplasty or patellar tendon realignment.

The quality of life was evaluated before and after surgery using the Pediatric International Knee Documentation Committee (IKDC-Pedi) form. The postoperative evaluation of the quality of life was conducted after at least 24 months of follow-up. The average interval from surgery to follow-up was 30 months (25–50 months). The postoperative scar was also assessed using The Stony Brook Scar Evaluation Scale (SBSES) in conjunction with the quality of life. The questionnaires were filled out by the patients under parental guidance in the presence of the attending physician.

The acquired and statistically analyzed data comprised the following variables: age, sex, type of surgery, date of surgery, athletic level, preoperative IKDC-Pedi score, postoperative IKDC-Pedi score, postoperative The Stony Brook Scar Evaluation Scale.

For statistical analysis we assumed a null hypothesis of equal efficacy of MPFL-R and LRMI. We set the significance level at 5% (0.05). We modelled the frequency by running a Shapiro-Wilk Test. As the data went through normal distribution, the independent Student-T test was used to compare IKDC-Pedi scores between patients who underwent LRMI surgery and those who experienced MPFL-R. The response to the athletic ability related question of the Pedi-IKDC form could not be used to express a normal distribution so a Mann-Whitney U test was run to check for statistical significance. As the scar evaluation data was not equally distributed, a Mann-Whitney U test was also needed. Standard deviation (SD) was calculated and a confidence interval (CI) of 95% was used.

Results:

A total number of 130 patients were operated for episodic patellar dislocation in the selected time interval. Five of them were eliminated from the study due to lack of adequate postoperative radiographs.

Twelve more were excluded because they underwent other surgical techniques. Five patients did not consent to take part in the study. 108 recreational athletes fulfilled both the inclusion and exclusion criteria, completed the questionnaires and presented at follow-up, as seen in Fig. 1.

The average age of the patient in the moment of the diagnosis of patellar dislocation was 13.3 years ± 2 years. Between diagnosis and surgery most of the patients (96%) had at least two more luxation episodes. Following the randomization, 80 patients were assigned to the LRMI group and 28 to the MPFL-R group. The mean age at surgery was 14.2 years ± 3.3 in the LRMI group and 14.5 years ± 2.7 in the MPFL-R group. In the LRMI group 30% were boys and 70% were girls. The MPFL-R group comprised 18% boys and 82% girls, as seen in Table 1. There were no statistically significant differences pertaining age, sex or athletic level.

Table 1
Age and sex distribution according to the surgery group

	MPFL-R group		**LRMI group**	
Sex	Male	Female	Male	Female
Total	5	23	24	56
Average Age	14.7	14.1	14.9	14.3

Preoperatively the Pedi-IKDC scores were similar between the two surgical groups (MPFL-R 41.4 points vs LRMI 39.4 points) and the difference was not statistically significant ($p = 0.314$).

We found significant improvement following both surgical approaches, the MPFL-R group scoring better that LRMI in postoperative IKDC-Pedi forms comparing to preoperative assessment (MPFL-R + 36.36 points – 95%CI [27.76–44.97] vs. LRMI + 20 points – 95% CI [15.11–25.53], $p < 0.0001$).

There was also a statistically significant difference in the postoperative IKDC-Pedi score between the 2 groups (MPFL-R 77.71 points vs. LRMI 59.74 points, $p < 0.0001$–95% CI [11.22–24.72]) as seen in Table 2.

Table 2
Preoperatory and postoperatory questionnaire scores from the MPFL-R and LRMI groups

	LRMP	**MPFL-R**	**P**
# of patients	80	28	
IKDC-Pedi preop	39.41	41.35	0.314
IKDC-Pedi post op	59.74	77.71	< 0.001
SBSES	2.76	4.50	0.002

The postoperative scars yielded different SBSES scores, MPFL-R having an average of 4,50 and LRMI 2,76 with a statistically significant p-value ($p = 0.002$).

There were no redislocations noted in the MPFL-R group and eight 10% redislocations in the LRMI group.

Discussion:

IKDC-Pedi was chosen as the quality of life measurement because it had better responsiveness than KOOS-Child. Being a shorter questionnaire makes it more likely to be fully completed in a clinical setting [16].

The Stony Brook Scar Evaluation Scale (SBSES) was selected for the same reason: a short time to complete and good clinical relevancy [17].

The different Pedi-IKDC scores were largely tied to the patients' ability to improve, or at least return to their previous level of activity. The questions related to athletic ability showed the biggest differences in favor of MPFL-R. One possible explanation may by the faster mobilization post-surgery which would provide protection against the muscular atrophy caused by immobilization [18].

In our study we noticed better outcomes related to pain assessment among the MPFL-R group. MPFL-R restores the normal anatomy of the knee thus facilitating normal joint reaction forces [19]. In the case of LRMI the increased joint forces could cause un-pleasant sensations like pressure or pain in the knee joint [19].

The postoperative score for the MPFL-R group is correlated to other studies found in literature, indicating adequate surgical technique and rehabilitation programs [20]. The LRMI group had fewer reported redislocations than most studies using a similar surgical technique, yet the IKDC-Pedi score was lower than expected [21] [22]. Although patellar redislocations affect QoL, there are other negative factors, such as failure to return to sport that also lower it as seen in our study.

The cosmetic differences between the two procedures are also undeniable. MPFL-R is by far less invasive and results in a significantly better looking postsurgical scar. The SBSES does not take into account scar length, and it should be mentioned that the MPFL-R group has two short scars while the LRMI has one long scar. As observed in our study this is a cause of distress for patients even if the scar itself has healed without abnormal pigmentation, elevation or depression.

One factor that is particularly important in this patient group is the status of the tibial and femoral physes [11]. While the surgical technique used for MPFL-R in this study does not usually affect the growth plate, there is still a slight risk. In contrast, the LRMI procedure only involves the soft tissues surrounding the knee, eliminating any risk of damage to the growth plate.

Lateral release on its own has yielded unsatisfactory outcomes in the history of patellar dislocation treatment [23], and release of a normal lateral retinaculum may increase lateral patellar translation and cause even more instability, due to the role of the lateral retinaculum in resisting lateral patellar translation [24]. In one study, which compared MPFL-R without lateral release and MPFL-R with lateral release, the groups had similar outcomes thus showing that Lateral release is not mandatory [25]. Lateral release also presents a risk of overly reducing lateral forces on the patella and thus inducing a medial dislocation, worsening the patients' quality of life and requiring further corrective surgery [26].

The follow-up period was clinically relevant because most redislocations (70%) occur within 24 months postoperatively [27]. It is insufficient to determine whether differences in joint anatomy that result after surgery remotely affect the incidence of osteoarthritis, and this would require a lengthy, hard to manage longitudinal study.

The strength points in our study are the homogeneity of the surgical techniques that were identical for all patients as well as the homogeneity of the study groups concerning risk factors for patellar dislocation.

Conclusions:

Recurrent patellar dislocation is a disabling condition that can be prevented both by MPFL-R and by LRMI.

MPFL-R interventions are minimally invasive, reduce postoperative recovery time and increase quality of life.

This study provides further evidence for the recommendation of MPFL-R as the gold standard for patellofemoral instability. Further studies can be done in order to verify the long term stability and side effects on MPFL-R.

List Of Abbreviations:

LRMI = Lateral Release and Medial Imbrication approach

MPFL-R = Medial Patellofemoral Ligament Reconstruction

Pedi-IKDC = Pediatric International Knee Documentation Committee form

MPFL = The medial patellofemoral ligament

QOL = The quality of life

SBSES = The Stony Brook Scar Evaluation Scale

SD = Standard deviation

CI = Confidence interval

Declarations:

Ethics approval and consent to participate:

The study was conducted according to the guidelines of the Declaration of Helsinki, and ap-proved by the Ethics Committee of “Grigore Alexandrescu” Children’s Emergency Clinical Hospital of Bucharest on 1st of March 2013. Study code is 7/01.03.2013.

Consent for publication:

Informed consent was obtained from the parents of all subjects involved in the study.

Availability of data and materials:

The datasets used and/or analyzed during the current study are available from the corresponding author on reasonable request.

Competing interests:

The authors declare that they have no competing interests.

Funding:

Not applicable.

Author’s contributions:

AH, AC and AU collected, analyzed and interpreted the patient data. AH, AC, AT, MCD, VP and AU made substantial contributions to the conception of the work and interpretation of the data; also, they drafted the manuscript and were major contributors in writing the manuscript. All the authors agreed to be accountable for all aspects of the work in ensuring that questions related to the accuracy or integrity of any part of the work are appropriately investigated and resolved. All authors read and approved the final manuscript.

References:

1. D. C. Fithian, E. W. Paxton and M. L. Stone, "Epidemiology and natural history of acute patellar dislocation," Am J Sports Med, pp. 1114-1121, 2004.
2. W. Hennrikus and T. Pylawka, "Patellofemoral instability in skeletally immature athletes.," J Bone Joint Surge Am., pp. 176-183, 2013.
3. D. Atkin, D. Fithian, K. Marangi , M. Stone , B. Dobson and C. Mendelsohn, "Characteristics of patients with primary acute lateral patelar dislocation and their recovery within the first 6 months," Am J

Sports Med, pp. 472-479, 2008.

4. R. N. Steense, J. C. Bentley, T. O. Trinh, J. R. Backes and R. E. Wiltfong, " The prevalence and combined prevalences of an-atomic factors associated with recurrent patellar dislocaton : a magnetic resonance imaging study," Am J Sports Med, pp. 921-927, 2015.
5. Z. Ries and M. Bollier, "Patellofemoral Instability in Active Adolescents," J Knee Surg, pp. 265-278, 2015.
6. E. Arendt, J. Agel and A. Moore, "First time patella dislocations: characterizing their readiness for return to activity.," Br J Sports Med, 2011.
7. R. Cofield and R. Bryan, "Acute dislocations of the patella: Results of conservative treatment.," J Trauma, pp. 526-531, 1977.
8. R. Hawkins, R. Bell and G. Anisette, "Acute patellar dislocations. The natural history.," Am J Sports Med., pp. 117-120, 1986.
9. D. S. Johnson and P. G. Turner, "Management of the first-time lateral patellar dislocation," 2019.
10. M. Moiz, N. Smith, T. O. Smith, P. Thompson and A. Metcalfe, "Clinical outcomes after the nonoperative management of lateral patellar dislocation:a systematic review," The Orthopaedic Journal of Sports Science, pp. 1-7, 2018.
11. E. E. Vellios, M. Trivellas, A. Arshi and J. J. Beck, "Recurrent Patellofemoral Instability in the Pediatric Patient: Manage-ment and Pitfalls," Curr Rev Musculoskelet Med, pp. 58-68, 2020.
12. D. Clark, A. Metcalfe, C. Wogan, V. Mandalia and J. Eldridge, "Adolescent patellar instability," Bone Joint J, pp. 159-70, 2017.
13. I. Tevanov, E. Liciu, M. Chirila, A. Dusca and A. Ulici, "The use of 3D printing in impoving patient-doctor relationship and malpractice prevention," Rom J Leg Med, vol. 25, pp. 279-282, 2017.
14. F. Migliorini, R. Bjorn, M. Tingart, N. Meisen and J. Eschweiller, "Surgical management for recurrent patellar disloca-tions in skeletally immature patients," European Journal of Orthopaedic Surgery & Traumatology, 2019.
15. P. Antinolfi, M. Bartoli, G. Placella, A. Speziali, V. Pace, M. Delcogliano and C. Mazzola, "Acute patellofemoral instabil-ity in children and adolescents," Joints, pp. 47-51, 2016.
16. C. A. van der Velden, M. C. van der Steen, J. Leenders, Q. Florens, M. P. van Douveren, R. P. Janssen and M. Reijman, "Pedi-IKDC or KOOS-child: which questionnaire should be used in children with knee disorders?," BMC Musculoskele-tal Disorders 20, p. 240, 2019.
17. A. J. Singer , B. Arora, A. Dagum, S. Valentine and J. Hollander , "Development and Validation of a Novel Scar Evalua-tion Score," Plastic and Reconstructive Surgery, pp. 1892-1897, 2007.
18. H. Appel, "Muscular atrophy following immobilisation. A review," Sports Med, pp. 42-58, 1990.
19. E. W. Edmonds and D. A. Glaser, "Adolescent Patella Instability Extensor Mechanics: Insall Extensor Realignment Ver-sus Medial Patellofemoral Ligament Reconstruction," J Pediatri Orthop., pp. 262-267, 2016.

20. D. K. Schneider, B. Grawe, R. A. Magnussen and e. al, "Outcomes after isolated medial patellofemoral ligament recon-struction for the treatment of recurrent lateral patellar dislocations: a systematic review and meta-analysis," pp. 2993-3005, 2006.
21. U. G. Longo, G. Rizzello, M. Ciuffreda and e. al, "Elmslie-Trillat, Maquet, Fulkerson, Roux Goldthwait, and Other Distal Realignment Procedures for the Management of Patellar Dislocation: Systematic Review and Quantitative Synthesis of the Literature," Arthroscopy, pp. 929-943, 2016.
22. B. U. Nwachukwu, C. So, W. W. Schairer, D. W. Green and E. E. Dodwell, "Surgical versus conservative management of acute patellar dislocation in children and adolescents: a systematic review," Knee Surgery, Sports Traumatology, Ar-throscopy,, pp. 760-767, 2015.
23. S. Ostermeier, M. Holst, C. Hurschler, H. Windhagen and C. Stukenborg-Colsman, "Dynamic measurement of patello-femoral kinematics and contact pressure after lateral retinacular," Knee Surg Sports Traumatol Arthrosc, pp. 547-554, 2007.
24. S. M. Desio, R. T. Burks and K. N. Bachus, "Soft tissue restraints to lateral patellar translation in the human knee," Am J Sports Med, pp. 59-65.
25. M. R. L. S. S. E. Malatray M, "Lateral retinacular release is not recommended in association to MPFL reconstruction in recurrent patellar dislocation.," nee Surg Sports Traumatol Arthrosc, pp. 2659-2664, 2019.
26. M. A. McCarthy and M. J. Bollier, "Medial Patella Subluxation: Diagnosis and Treatment," Iowa Orthop J, pp. 26-33, 2015.
27. K. Studer, A. Vacariu, E. Rutz and C. Camathias, "High failure rate 10.8 years after vastus medialis transfer and lateral release (Green's quadricepsplasty) for recurrent dislocation of the patella," Archives of Orthopaedic and Trauma Sur-gery, 2019.
28. E. W. Edmonds and D. A. Glaser, "Adolescent Patella Instability Extensor Mechanics.," J Pediatr Orthop, pp. 262-267, 2015.
29. M. Apostolovic, B. Vukomanovic , N. Slavkovic, V. Vuckovic, G. Djuricic and Kocev N, "Acute patellar dislocation in adolescents: operative versus nonoperative treatment," International Orthopaedics, pp. 1483-1487, 2011.
30. J. G. Song, S. B. Kang, S. H. Oh and e. al, "Medial soft tissue realignment versus medial patellofemoral ligament recon-struction for recurrent patellar dislocation:Systematic review," Arthroscopy, pp. 507-516, 2016.
31. C. Ihle, J. Maurer, P. Ziegler, Stockle U, A. Ateschrang , M. -D. Ahremd and S. Schroter , "Sporting activity is reduced fol-lowing medial reefing performed for patellar dislocation," BMC Musculoskeltal Disorders, 2019.
32. H. Shtarker , M. Assaf and M. N. Deltoff, "A new minimally invasive surgical technique for medial retinaculum repair following traumatic patellar dislocation," European Journal of Orthopaedic Surgery & Traumatology, pp. 811-817, 2018.
33. P. B. Schottle, S. U. Scheffler, A. Schwarck and A. Weiler, "Arthroscopic medial retinacular repair after patellar disloca-tion with and without underlying trochlear dysplasia: a preliminary report.,"

Arthroscopy, pp. 1192-1198, 2006.

34. J. H. Ahn, J. H. Kang, N. S. Kasat and J. G. Kim, "atellar instability with and without trochlear dysplasia: new arthro-scopic medial soft tissue plication with pullout technique.," pp. 1385-1393, 2013.
35. K. L. Stupay, E. Swart and B. E. Shubin Stein, "Widespread implementation of medial patellofemoral ligament recon-struction for recurrent patellar instability maintains functional outcomes at midterm to long-term follow-up while de-creasing complication rates: a systematic review.," pp. 1372-1380, 2015.
36. M. A. Tompkins and E. A. Arendt, "Patellar instability factors in isolated medial patellofemoral ligament reconstruc-tions—what does the literature tell us? A systematic review.," Am J Sports Med., p. 2318–2327, 2015.
37. V. B. Duthon, "Acute traumatic patellar dislocation," Orthopaedics & Traumatology: Surgery & Research, pp. 59-67, 2015.

Figures

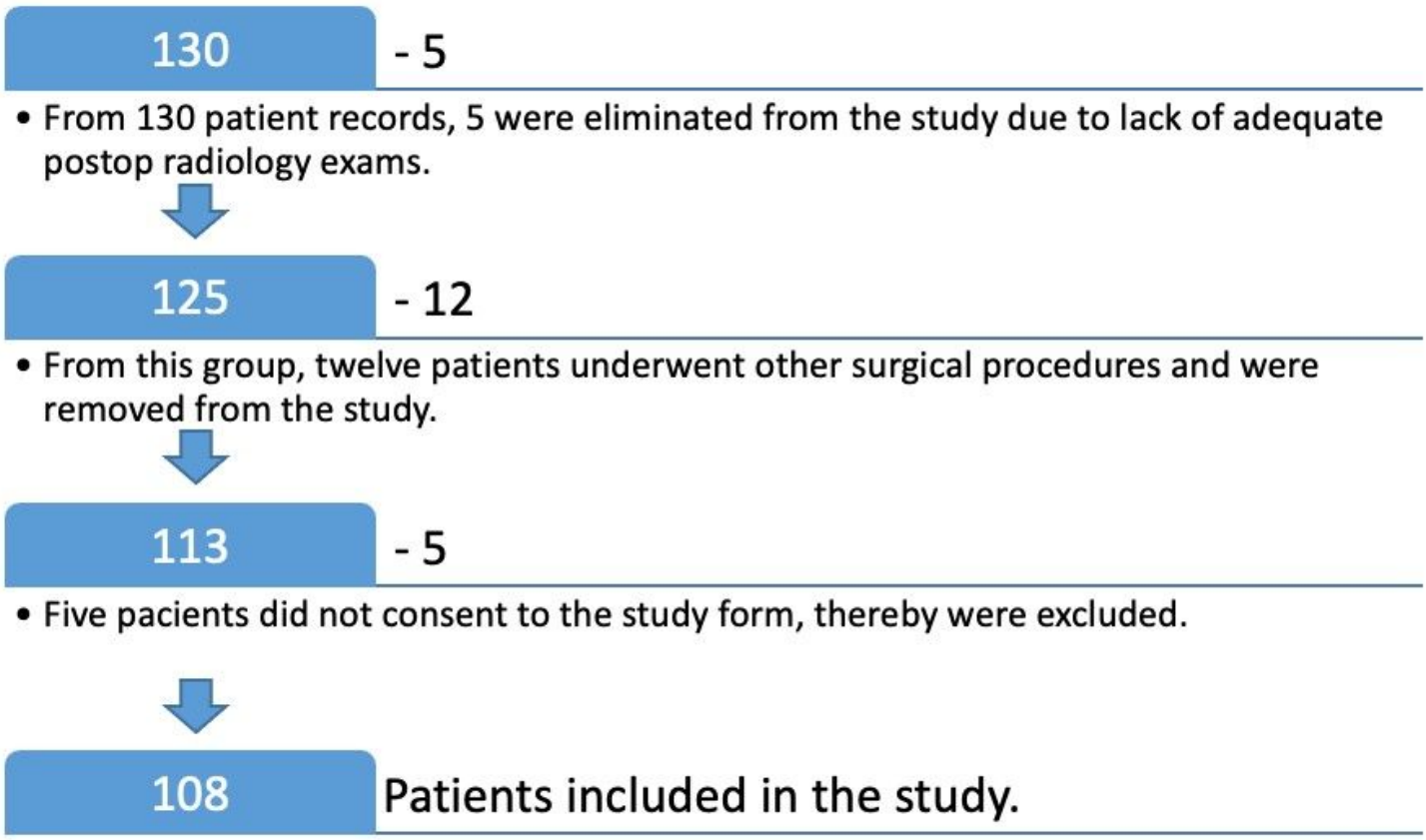

Figure 1

Patient selection by exclusion criteria