# Apical Periodontitis in Endodontically Treated Teeth: Cross-sectional Study of New Investigated Risk Factors

**IMANE EL OUARTI** ( imanegemini@gmail.com )

Department of Endodontics and Restorative Dentistry, Faculty of Dental Medicine, Mohammed V University in Rabat, Rabat, Morocco.

**CHALA SANAA**

Department of Endodontics and Restorative Dentistry, Faculty of Dental Medicine, Mohammed V University in Rabat, Rabat, Morocco.

**MAJID SAKOUT**

Department of Endodontics and Restorative Dentistry, Faculty of Dental Medicine, Mohammed V University in Rabat, Rabat, Morocco.

**ABDALLAOUI FAIZA**

Department of Endodontics and Restorative Dentistry, Faculty of Dental Medicine, Mohammed V University in Rabat, Rabat, Morocco.

**Research article**

**Keywords:** apical periodontitis, endodontic treatment, Risk factors

**Posted Date:** August 25th, 2020

**DOI:** https://doi.org/10.21203/rs.3.rs-53961/v1



**Version of Record:** A version of this preprint was published on March 17th, 2021. See the published version at https://doi.org/10.1186/s12903-021-01491-6.

# Abstract

**Background:** The present study aimed at investigating risk factors associated to apical periodontitis in endodontically treated teeth and highlight the potential risk of some factors not assessed before in previous studies.

**Methods**:

A total of 358 endodontically treated teeth were evaluated after more than 1-year period in a Moroccan population according to predetermined criteria. Studied parameters were assessed clinically and radiographically. The association between coronal restoration quality, cavity design, periodontal status, root canal filling quality, coronal restoration related features, presence or absence of the opposing dentition and the periapical status was determined. Data were analyzed using chi-square test, odds ratio and logistic regression.

**Results**:

The present study revealed that gingival health, coronal restoration with CL II cavity design, and root canal filling quality influenced periapical status of endodontically treated teeth. Multivariate analysis showed that this association was statistically significant for gingival inflammation (95% IC: 1.08-3.91, OR: 2.05, p=0.02), inadequate coronal restoration (95%IC: 1.16-4.04, OR: 2.16, p: 0.01), inadequate root canal filling length and homogeneity (95%IC: 1.24-3.01, OR: 1.93, P:0.004), (95%IC: 1.41-4.44, OR: 2.50, p:0.002) respectively.

**Conclusions**:

The present study revealed that inadequate coronal restorations especially with large proximal margins (CL II cavity design) and gingival inflammation increased the risk of apical periodontitis in endodontically treated teeth.


# Background

Apical periodontitis (AP) represents inflammation and destruction of the periradicular tissues occurring in response to the presence of microorganisms and their irritants within the root canal system[1] **.**

The ultimate goal of endodontic treatment is then to eliminate or at least reduce the microbial load within the root canal system through chemomechanical debridement followed by root filling[2]. Even though, post-treatment apical periodontitis is still raising despite technical developments of root canal treatment procedures and the evolution of the understanding of wound healing conditions[3,4]. Bacterial infection/reinfection has been confirmed as the most important etiologic factor related to endodontic treatment failure. Chàvez de Paz revealed in a study carried out on root canals persistent infections that oral microorganisms are able to survive in root canals by adhering to dentine walls. [5]

Several factors can lead to endodontic treatment failure, technical quality of coronal restoration seems to have greater impact on periapical status than the quality of root canal filling as reported by many previous studies [6,7]**.** Nevertheless, contradictory results were revealed by other reports [8,9]. In fact, one of the recognized limitations of these studies that can explain the previous controversial findings is the only radiographic assessment of coronal restoration quality and periapical status. A clinical and radiologic assessment should be adopted to identify apical periodontitis occurring or persisting after endodontic treatment to refrain from uncertainties that may lead to overdiagnosis or misdiagnosis [10].

It’s also conceivable that scoring the quality of coronal restoration from a radiograph is not possible with certainty as it only provides a two dimensional image, and this is supported by previous findings which stated a weak correlation between radiographic and clinical data related to coronal restoration quality[11–13].

Gingival inflammation was reported to be associated with progressing caries and bacterial biofilm activity on approximal surfaces of teeth . Mjör reported that the gingival wall in proximal restorations with overhangs is the most common site of

plaque accumulation and the development of recurrent caries [14,15]. To the best of our knowledge, there is no study investigating risk of apical periodontitis in endodontically treated teeth (ETT) related to gingival inflammation and proximal restorations.

The aim of the present study was to assess both clinically and radiographically risk factors associated to apical periodontitis in ETT and to highlight the combined risk of AP assigned to proximal restorations and gingiva status in ETT not investigated previously.

# Methods

**-study design**

This cross-sectional study was carried out on patients attending the Department of Conservative dentistry and endodontics within the dental faculty hospital, Rabat (CCTD Rabat). The study was conducted in compliance with the ethical principles stated in the declaration of Helsinki and was approved by the Research Ethics Committee, Mohammed V University, Rabat (comité d'éthique pour la recherche biomédicale de Rabat [CERB]) under ID Number 08/18).

**-Patient selection**

The Study sample size was calculated considering error α at 0.05 and on the basis of a prevalence of apical periodontitis of (63,79%) in an urban Moroccan adult population seeking routine dental care at the faculty of dental medicine in Rabat .[16]

-Inclusion criteria

- Subjects with no medical history who agreed to participate in the study.
- Teeth endodontically treated for more than 1year.
- Periapical radiographs with no processing artefacts allowing visualization of the investing bone beyond the radiographic apex at 2mm at least with good density and contrast.

-Exclusion criteria

- Patients with medical conditions that may affect the healing process or the immune system conditions included: Diabetes, chemotherapy, Jaw bones radiotherapy, autoimmune disease and patients taking any medication known to alter metabolism such as : immunosuppressive drugs, corticosteroids, Biphosphonates.
- Immature teeth
- Teeth that have undergone endodontic surgery and apical resection.
- Missing information or incomplete record.

-Clinical and radiographic examination

Patients participating in the study and seeking routine dental care (no emergency care) were examined clinically and radiographically. All radiographs had been examined using an x-ray viewer under good illumination and 5 × magnification , optimal conditions were adopted for the best possible radiographic contrast.

A clinical examination was carried out including periodontal probing, palpation of the adjacent mucosa and vertical percussion of the endodontically treated teeth. The coronal restorations were clinically assessed using explorary probe 6 (Dentsply Maillefer, Ballaigues, Switzerland).

**-Data collection**

For each subject, the following informations were recorded:

-Patient’s age and Sex.

-Tooth group: incisor, canine, Premolar or Molar.

-Existence of opposing tooth: opposing tooth present or absent.

-Date of root canal treatment completion.

-Type of coronal restoration of the endodontically treated teeth:

* full coverage crown: restoration of the coronal part of the tooth which appeared to be a cast restoration or a porcelain crown.

* coronal filling inserted during plastic phase: restoration of the coronal part of the tooth which appeared radiopaque on the radiographs.

-The coronal filling material was specified: a composite resin or amalgam restoration.

-cavity design: the cavities were matched according to cavity type (Black’s classification)

-Periodontal health status was classified as follows:

Presence of dental plaque, bleeding, calculus during probing, gingival recession, loss of periodontal attachment, pocket depth, bone loss in the alveolar crest or in the furcation area and tooth mobility were considered in the assessment of periodontal health. All the periodontal pockets deeper than 4mm were considered pathologic accordingly with the criteria established by the American Academy of Periodontology (2015). [17]

*Healthy: no visible biofilm, no gingival bleeding on periodontal probing, physiologic tooth mobility, no probing depth recorded on buccal, lingual, mesial and distal surfaces.

*Periodontal disease: presence of gingival bleeding on periodontal probing, pocket depth 4mm, bone loss visible on radiographs, pathologic tooth mobility due to insertion loss.

-Periapical status was classified as follows:

*Healthy: No clinical symptoms, no rarefaction of bone visible on the radiograph, periodontal ligament of normal width or slightly widened.

*Apical periodontitis: clinical signs and symptoms of periapical inflammation, infection or both, widened periodontal ligament, presence of any discernible periapical radiolucency.

The periapical status of endodontically treated teeth was evaluated clinically and radiographically, radiographic criteria used by De Moor et al (2000) and Song et al (2014) were retained [18,19]. The worst periapical status of all canals was taken to represent the periapical status in multi-rooted teeth.

- Coronal restoration quality was assessed as follows:

*Adequate: any permanent restoration that appeared clinically and radiographically intact.

*Inadequate: any permanent restoration with detectable clinical and radiographic signs of open margins, overhangs or caries, or no restoration at all.

Coronal restoration was clinically and radiographically determined to have well-sealed margins, to restore tooth anatomy and to be without any recurrent caries. Modified and simplified Ryge’s Criteria were used [20]. (Table1)

-The root canal filling quality was classified as follows:

*Adequate: when all root canals were obturated with dense fillings, no visible space between the material and the walls of the canal or within the body of the obturating material, the root canal filling ending within 0-2mm short of the radiographic apex with a consistent taper from the orifice to the apex.

*Inadequate: when the root canal fillings were poorly condensed, the canal space visible laterally and apically with no consistent taper and when the root canal fillings were overfilled or ended 2mm shorter than the radiographic apex or in the presence of unfilled canals.

In Multi-rooted teeth, the worst root canal filling quality was considered.

The root canal fillings were evaluated according to the European Society of Endodontology (ESE 2006)[21]. Root canal conicity was evaluated on periapical radiographs of endodontically treated teeth according to Shilder's design objectives for root canal shaping and filling as a continuously tapering funneled preparation from the canal orifice to the apex [22].

A well performed endodontic treatment was assessed according to the previous recommendations as dense with radiopaque appearance of the filled canals and no voids seen between canal filling and canal walls, and the root canal filling ending at 0-2mm from the radiographic apex.

Table 1 shows criteria used to assess the quality of coronal restorations and root canal fillings.

**Data Analysis**

Data analysis was performed by using the SPSS Software (Statistical Package for the Social Sciences, version 13.0, IBM, Chicago , IL), continuous variables were presented as means and Standards deviation, or as medians and interquartile range, as appropriate. Categorical variables were presented as numbers and percentages. Association between risk factors and AP was identified by a chi-square test or Fisher's exact test, as appropriate. Odds ratio (OR) and 95% confidence interval (CI) were also calculated for each association. Significance level was set at $p<0.05$.

The main outcome measure was the absence versus the presence of apical periodontitis. Apical periodontitis (AP) was the dependent variable , explanatory variables (covariates) were coronal restoration quality, cavity design, coronal filling type and material, root canal filling quality, periodontal health, tooth location, existing of opposing tooth, age and gender.

Univariate and multivariate logistic regressions were used to relate patient and treatment variables with the AP prevalence. Explanatory variables to be included on multivariate analysis were identified in multivariate analysis.

# Results

AP was detected on 258(72.1%) of the studied endodontically treated teeth. Coronal restoration with open margins and recurrent decay were recorded in 68(19%) and 45 (12.6%) of endodontically treated teeth respectively. 160 (65%) of the restored teeth matched CL II cavity design. (Table 3) shows descriptive data of coronal restoration and root canal filling quality.

(Table 2) gives an overview of the study sample.

Univariate regression analysis showed that inadequate coronal restoration, inadequate root canal filling quality, gingival inflammation and coronal restorations with CL II cavity design were identified as risk factors associated with higher rate of apical periodontitis. The results of unadjusted (univariable model) are shown in (table 4).

Multivariate analysis (Table 5) showed that teeth with inadequate coronal restoration, inadequate root canal filling length, inadequate root canal filling homogeneity, and with gingival inflammation had a **(2.16) fold (95% CI, 1.16-4.04)**, **(1.93) fold**

**(95%CI, 1.24-3.01)**, **(2.50) fold** (**95%CI, 1.41-4.44)** and **(2.05) fold (95% CI: 1.08-3.91)** greater chance respectively of apical periodontitis than teeth with adequate coronal restoration, with adequate root canal filling and endodontically treated teeth with healthy gingival status.

# Discussion

The current study aimed to investigate risk factors associated to apical periodontitis and to highlight the combined risk of AP assigned to proximal restorations and gingival status in endodontically treated teeth not investigated previously. Epidemiological studies in different populations often reveal a high rate of AP associated with root filled teeth [23–25]. The results of the present study indicate that (72.1%) of the root filled teeth had AP, this figure is in the range of those found in previous studies [26–29], and higher than other reports [30]**.**

The interpretation of radiographs is the most common method used to evaluate AP in epidemiological studies [31,32], clinical symptoms such as pain, swelling, sinus tract formation and tenderness are moderately specific. In the current study AP was diagnosed clinically and radiographically for a better accuracy. In this study periapical radiography was preferred to panoramic examination because not only the presence of AP but also endodontic treatment and coronal restoration quality were assessed.

The present study revealed that both quality of root filling and coronal restoration are equally important for periapical health in endodontically treated teeth and this is in accordance with Hommez et al findings [11]. On the other hand, according to the present study, when the root canal filling was inadequate, the good coronal seal did not prevent AP in endodontically treated teeth. **(Figure A)**

The present study revealed that inadequate coronal restorations especially those with large proximal margins (CL II cavity design), and gingival inflammation increased the risk of AP in endodontically treated teeth. Only few studies have linked gingival disease to periapical status, Costa et al (2017) reported that gingival bleeding on probing was significantly associated to periapical status, however periodontal bone loss didn't influence periapical health[33]. This is in agreement with the present study results. In similar context, Skupien et al and Khalighinejad et al confirmed in two recent studies the high predictable survival rate of endodontically treated teeth after root canal treatment in cases with a healthy periodontium [34,35].

We can suggest that in endodontically treated teeth several factors can interact with each other, absence of immune defense mechanisms related to vital pulp tissue, coronal restoration with inadequate proximal margins, gingival disease, and inadequate root canal filling if concurrent can potentiate diffusion of micro-organisms in relation to gingival inflammation into root canal space. Gingivitis and apical periodontitis are both a bacterial biofilm-induced diseases, bacteria exert their pathogenicity through direct and/or indirect mechanisms, they can damage host cells and/or the intercellular matrix of connective tissue; host cells can also be stimulated by bacterial components and release chemical mediators involved in the induction of bone resorption [5,36].

In the same context, it was stated that Biofilm formation in root canals is probably initiated after the first invasion of the pulp chamber by planktonic oral organisms after some tissue breakdown [36]. The invading planktonic organisms can multiply and continue attaching to the root canals, an inflammatory lesion frontage moves successively toward the apex, and bacteria can detach from inner root canal surfaces and mass in the inflammatory lesion [37]. These inflammatory changes occurring in the periapical periodontium are responsible for the disease. The host defenses can eliminate bacteria egressing from the canal, but are unable to eradicate bacteria confined in the canal because of the absence of an active microcirculation , therefore bacterial infection stays beyond the reaches of body defenses [38]. According to the present study findings, we can suggest that coronal restorations with inadequate proximal margins especially when gingival inflammation is concurrent and the root canal filling is inadequate are the most affected by bacterial leakage, therefore

endodontic treatment failure. Thus the importance of a well sealing coronal restorations for lasting success of endodontic treatment that was stressed by several reports was evident in this study as well [39,40].

Recontamination of the root canal system by coronal leakage has been emphasized. Root canal filling leakage studies reported root canal system reinfection due to micro-organisms and their products after root canal filling exposure [41,42]. Although there is a need to establish the relationship between bacterial leakage and periapical inflammation, thereby the combination of our results and those of other studies [43,44] provide a clinical significance to the in vitro findings.

Frisk reported that association between type of restoration and AP in endodontically treated teeth has significance for recurrent caries [45]. However, contrarily to previous studies findings, the type of coronal restoration in the present study was not associated with AP [46]. This may be explained by the fact that the current study was not statistically powered to demonstrate such differences.

Root canal filling >2mm short from the radiographic apex and root canal fillings with inadequate homogeneity were associated with AP in the current study, these results agree with the findings of previous studies [2] supporting the necessity of instrumentation closer to the radiographic apex and adequate filling of the root canal system . Histopathologic observation studies reported in cases of under-fillings, bacterial proliferation in unsealed spaces of the root canal system, over-fillings are also associated with extrusion of infected debris toward periapical tissues [1,47]. Eventhough, residual bacteria can not always maintain an infectious process, this is supported by apical periodontitis healing even when bacteria are found in the canal at the filling stage [29], and this could be explained by the fact that a tridimensional and homogenous root canal filling can entomb bacteria in the canal denying them access to periradicular tissues [48].

In the literature, a few reports have been published on the influence of root canal filling conicity on periapical health [28,49], controversial results were reported in this respect. In the present study, inadequate root canal filling conicity was associated to apical periodontitis when studied as a separate variable, in combination with the above findings we could suggest that root canal filling conicity can affect periapical health when root canal filling length and homogeneity are inadequate.

## Conclusions

Within the limitations of this retrospective study, we can assume that periapical health is a multifactorial disease. Root canal filling and coronal restoration adequacy, gingival inflammation are the most risk factors of apical periodontitis in endodontically treated teeth according to the present study. In addition to the reportings of many surveys, the present study gives an overview of the high prevalence of apical periodontitis still recorded despite restorative and endodontic advances. High prevalence of apical periodontitis within endodontically treated teeth in the current study, should make practitioners aware of the multifactorial aspect of the disease, therefore key features in relation to restorative and endodontic procedures must be well managed to improve periapical health conditions.

## Abbreviations

AP: Apical periodontitis

ETT: Endodontically treated teeth

## Declarations

**-Ethical approval and consent to participate:** this study was approved by the Research Ethics Committee, Mohammed V University, Rabat (comité d'éthique pour la recherche biomédicale de Rabat [CERB]) under ID Number 08/18). A written consent to participate in the study was obtained from patients, only patients that approved to participate were included in the study.

-**Consent for publication:** Not applicable

-**Availability of data and materials:** all data generated or analyzed during this study are included in this published article.

-**Competing interests**: the authors declare that they have no competing interests.

-**Funding:** the present study didn't receive any funding.

-**Author's contributions**:

I E: Investigation, Data curation, Visualization, Data analysis &interpretation Writing-original draft, writing-review & editing

S C: advised Methodology and statistical analysis, Data interpretation and reviewed manuscript

M F: reviewed manuscript

F A: Conceptualization, supervision, review &editing.

All authors read and approved the manuscript.

**-Acknowledgement**: None

# References

1. Ricucci D, Siqueira Jr JF. Biofilms and apical periodontitis: study of prevalence and association with clinical and histopathologic findings. J Endod. 2010;36(8):1277–88.
2. Chugal NM, Clive JM, Spångberg LS. Endodontic infection: some biologic and treatment factors associated with outcome. Oral Surg Oral Med Oral Pathol Oral Radiol Endodontology. 2003;96(1):81–90.
3. Olcay K, Ataoglu H, Belli S. Evaluation of related factors in the failure of endodontically treated teeth: a cross-sectional study. J Endod. 2018;44(1):38–45.
4. Holland R, Gomes Filho JE, Cintra LTA, Queiroz ÍO de A, Estrela C. Factors affecting the periapical healing process of endodontically treated teeth. J Appl Oral Sci. 2017;25(5):465–76.
5. de Paz LC. Redefining the persistent infection in root canals: possible role of biofilm communities. J Endod. 2007;33(6):652–62.
6. Ray H, Trope M. Periapical status of endodontically treated teeth in relation to the technical quality of the root filling and the coronal restoration. Int Endod J. 1995;28(1):12–8.
7. Van der Veken D, Curvers F, Fieuws S, Lambrechts P. Prevalence of apical periodontitis and root filled teeth in a Belgian subpopulation found on CBCT images. Int Endod J. 2017;50(4):317–29.
8. Tronstad L, Asbjørnsen K, Døving L, Pedersen I, Eriksen H. Influence of coronal restorations on the periapical health of endodontically treated teeth. Dent Traumatol. 2000;16(5):218–21.
9. Al-Nuaimi N, Patel S, Austin R, Mannocci F. A prospective study assessing the effect of coronal tooth structure loss on the outcome of root canal retreatment. Int Endod J. 2017;50(12):1143–57.
10. Jonasson P, Kvist T. Diagnosis of apical periodontitis in root-filled teeth. Clin Dent Rev. 2018;2(1):15.
11. Hommez G, Coppens C, De Moor R. Abstract. Int Endod J. 2002;35(8):680–9.
12. Dugas N, Lawrence H, Teplitsky P, Pharoah M, Friedman S. Abstract. Int Endod J. 2003;36(3):181–92.
13. Craveiro MA, Fontana CE, de Martin AS, da Silveira Bueno CE. Influence of coronal restoration and root canal filling quality on periapical status: clinical and radiographic evaluation. J Endod. 2015;41(6):836–40.
14. Mjor I, Gordan V. Failure, repair, refurbishing and longevity of restorations. Oper Dent. 2002;27(5):528–34.
15. Mjör IA. Clinical diagnosis of recurrent caries. J Am Dent Assoc. 2005;136(10):1426–33.

16. Chala S, Abouqal R, Abdallaoui F. Prevalence of apical periodontitis and factors associated with the periradicular status. Acta Odontol Scand. 2011;69(6):355–9.
17. Periodontitis O. American Academy of Periodontology Task Force report on the update to the 1999 classification of periodontal diseases and conditions. J Periodontol. 2015;86(7):835–8.
18. De Moor R, Hommez G, De Boever J, Delmé K, Martens G. Periapical health related to the quality of root canal treatment in a Belgian population. Int Endod J. 2000;33(2):113–20.
19. Song M, Park M, Lee C-Y, Kim E. Periapical status related to the quality of coronal restorations and root fillings in a Korean population. J Endod. 2014;40(2):182–6.
20. Cvar JF. Reprint of criteria for the clinical evaluation of dental restorative materials. Clin Oral Investig. 2005;9:215–32.
21. European Society of Endodontology. Quality guidelines for endodontic treatment: consensus report of the European Society of Endodontology. Int Endod J. 2006;39(12):921–30.
22. Schilder H. Cleaning and shaping the root canal. Dent Clin North Am. 1974;18:269–96.
23. Kirkevang L, Ørstavik D, Hörsted-Bindslev P, Wenzel A. Periapical status and quality of root fillings and coronal restorations in a Danish population. Int Endod J. 2000;33(6):509–15.
24. Tavares PB, Bonte E, Boukpessi T, Siqueira Jr JF, Lasfargues J-J. Prevalence of apical periodontitis in root canal–treated teeth from an urban French population: influence of the quality of root canal fillings and coronal restorations. J Endod. 2009;35(6):810–3.
25. El Merini H, Amarir H, Lamzawaq A, Hamza M. Periapical Status and Quality of Root Canal Fillings in a Moroccan Subpopulation. Int J Dent. 2017;2017.
26. Touré B, Kane A, Sarr M, Ngom C, Boucher Y. Prevalence and technical quality of root fillings in Dakar, Senegal. Int Endod J. 2008;41(1):41–9.
27. Vengerfeldt V, Mändar R, Nguyen MS, Saukas S, Saag M. Apical periodontitis in southern Estonian population: prevalence and associations with quality of root canal fillings and coronal restorations. BMC Oral Health. 2017;17(1):147.
28. Madfa A, Al-Hamzi M, Senan E. Cross-sectional assessment of the periapical status as related to quality of root canal fillings and coronal restorations in a Yemeni population. J Oral Res. 2017;6(1):19–24.
29. Nascimento EHL, Gaêta-Araujo H, Andrade MFS, Freitas DQ. Prevalence of technical errors and periapical lesions in a sample of endodontically treated teeth: a CBCT analysis. Clin Oral Investig. 2018;22(7):2495–503.
30. Timmerman A, Calache H, Parashos P. A cross sectional and longitudinal study of endodontic and periapical status in an Australian population. Aust Dent J. 2017;62(3):345–54.
31. Loftus J, Keating A, McCartan B. Periapical status and quality of endodontic treatment in an adult Irish population. Int Endod J. 2005;38(2):81–6.
32. Di Filippo G, Sidhu S, Chong B. Apical periodontitis and the technical quality of root canal treatment in an adult sub-population in London. Br Dent J. 2014;216(10):E22.
33. Costa GM, Santos Soares SM, Pelli Paiva PC, Verli FD, Gonçalves PF, Pereira SM da S, De Jesus Tavarez RR, Soares JA, Maia Filho M. Factors Affecting the Periapical Status of Root-Filled Canals: A Cross-Sectional Study at the Undergraduate Level. Int J Dent. 2017;2017.
34. Skupien JA, Opdam NJ, Winnen R, Bronkhorst EM, Kreulen CM, Pereira-Cenci T, Huysmans M-C. Survival of restored endodontically treated teeth in relation to periodontal status. Braz Dent J. 2016;27(1):37–40.
35. Khalighinejad N, Aminoshariae A, Kulild JC, Wang J, Mickel A. The influence of periodontal status on endodontically treated teeth: 9-year survival analysis. J Endod. 2017;43(11):1781–5.
36. Svensäter G, Bergenholtz G. Biofilms in endodontic infections. Endod Top. 2004;9(1):27–36.
37. Nair P, Henry S, Cano V, Vera J. Microbial status of apical root canal system of human mandibular first molars with primary apical periodontitis after “one-visit” endodontic treatment. Oral Surg Oral Med Oral Pathol Oral Radiol

Endodontology. 2005;99(2):231–52.
38. Siqueira Jr JF, Rôças IN. Bacterial pathogenesis and mediators in apical periodontitis. Braz Dent J. 2007;18(4):267–80.
39. Chen C-Y, Hasselgren G, Serman N, Elkind MS, Desvarieux M, Engebretson SP. Prevalence and quality of endodontic treatment in the Northern Manhattan elderly. J Endod. 2007;33(3):230–4.
40. Maslamani M, Behbahani J, Mitra AK. Radiographic evaluation and predictors of periapical lesions in patients with root-filled and nonroot-filled teeth in Kuwait. Indian J Dent Sci. 2017;9(4):237.
41. Torabinejad M, Ung B, Kettering JD. In vitro bacterial penetration of coronally unsealed endodontically treated teeth. J Endod. 1990;16(12):566–9.
42. Alves J, Walton R, Drake D. Coronal leakage: endotoxin penetration from mixed bacterial communities through obturated, post-prepared root canals. J Endod. 1998;24(9):587–91.
43. Gomes AC, Nejaim Y, Silva AI, Haiter-Neto F, Cohenca N, Zaia AA, Silva EJNL. Influence of endodontic treatment and coronal restoration on status of periapical tissues: a cone-beam computed tomographic study. J Endod. 2015;41(10):1614–8.
44. Gillen BM, Looney SW, Gu L-S, Loushine BA, Weller RN, Loushine RJ, Pashley DH, Tay FR. Impact of the quality of coronal restoration versus the quality of root canal fillings on success of root canal treatment: a systematic review and meta-analysis. J Endod. 2011;37(7):895–902.
45. Frisk F, Hugosson A, Kvist T. Is apical periodontitis in root filled teeth associated with the type of restoration? Acta Odontol Scand. 2015;73(3):169–75.
46. Pratt I, Aminoshariae A, Montagnese TA, Williams KA, Khalighinejad N, Mickel A. Eight-year retrospective study of the critical time lapse between root canal completion and crown placement: its influence on the survival of endodontically treated teeth. J Endod. 2016;42(11):1598–603.
47. Noiri Y, Ehara A, Kawahara T, Takemura N, Ebisu S. Participation of bacterial biofilms in refractory and chronic periapical periodontitis. J Endod. 2002;28(10):679–83.
48. Tabassum S, Khan FR. Failure of endodontic treatment: The usual suspects. Eur J Dent. 2016;10(01):144–7.
49. Barrieshi-Nusair K, Al-Omari M, Al-Hiyasat A. Radiographic technical quality of root canal treatment performed by dental students at the Dental Teaching Center in Jordan. J Dent. 2004;32(4):301–7.

# Tables

**Table 1: Coronal restoration quality and root canal filling quality scored on endodontically treated teeth**

| Variables | Score |
| --- | --- |
| **Clinical and radiographic quality of coronal restorations** | 0 : Anatomical restoration with no open margins, no overhangs, and no recurrent decay (Adequate)<br>1 : Restoration with overhangs (Inadequate)<br>2 : Restoration with open margin (Inadequate)<br>3 : Restoration with unsatisfactory anatomic form (Inadequate)<br>4 : Restoration with recurrent decay (Inadequate)<br>5 : Fractured, detached, or lost restoration (Inadequate)<br>6 : tooth cusp or tooth wall fracture (Inadequate) |
| **Radiographic quality of root canal filling** | -<br>-<br>- |
| **Length of the root filling** | 0 : root filling ending from 0 to 2mm short of the radiographic apex.(Adequate)<br>1 : root filling ending more than 2mm short of the radiographic apex, unfilled canals, detectable void between the intra-radicular post and the filling material.(Inadequate)<br>2 : filling extruded beyond the apex.(Inadequate) |
| **Homogeneity of the root filling** | 0 : root canal filling with good radiographic density, no detectable voids between filling material and root canal walls.(Adequate)<br>1 : root canal filling with low radiographic density, detectable voids. (Inadequate) |
| **Conicity of root canal filling** | 0: continuously tapering funneled preparation from the canal orifice to the apex, and cross-sectional diameter narrower at every point apically. (Adequate)<br>1: inconsistant taper from the coronal to the apical part of the filling, or root filling deviated from the original canal. (Inadequate) |

**Table 2: Description of the study population**

| Variables | Values (N %) |
|---|---|
| **Age* (Y) (N=148)** | 41.7±11.7 |
| **Sex N(%) (N=148)** | |
| Female | 112(75.7) |
| Male | 36(24.3) |
| **Tooth type N(%) (N=358)** | |
| Molars | 131(36.6) |
| Premolars | 129(36) |
| Incisors | 80(22.3) |
| Canines | 18(5) |
| **Coronal restoration type N(%) (N=358)** | |
| Filling inserted during plastic phase | |
| Full coverage crown | 250(69.7) |
| Temporary or absent | 85(23.7) |
| | 22(6.1) |
| **Intracanal posts N(%) (N=358)** | 58(16.3) |
| **Opposing tooth N(%) (N=358)** | |
| Present | 318(90.1) |
| Absent | 34(9,6) |
| **Coronal restoration quality N(%) (N=358)** | |
| Adequate | |
| Inadequate | 159(44.4) |
| | 199(55.6) |
| **Periapical status N(%)(N=358)** | |
| Healthy | 100(27.9) |
| | 258(72.1) |
| (N=148): number of patients (N=358): number of teeth | |
| Y: Years *: mean ± Standard deviation | |
| Apical periodontitis | |

Table 3: Descriptive data of coronal restoration and root canal filling quality in the study population

| Variables | N(%) (N=358) | |
|---|---|---|
| **Coronal restoration Index** | | |
| Adequate | 159(44.4) | |
| Overhangs | | 32(8.9) |
| Open margins | | 68(19) |
| Non –anatomic | | 21(5.9) |
| Recurrent decay | | 45(12.6) |
| Fractured or missing restoration | | 27(7.5) |
| Fractured tooth | | 6(1.7) |
| **Root canal filling quality** | | |
| Under and over-filling | 218(60.8) | |
| Inadequate homogeneity | | 247(69) |
| Inadequate conicity | | 251(70.1) |

Table 4: Univariate logistic Regression for the association of study variables with periapical status

| Variable | Apical periodontitis N (%) | OR | 95%CI | P value |
|---|---|---|---|---|
| **Age (Years)** | - | 1.02 | 0.99-1.05 | 0.08 |
| **Sex** | | | | |
| Female | 75(66.4%) | 1.11 | 0.50-2.44 | 0.78 |
| **Tooth type** | | | | |
| Incisors | 57 (71.2%) | 1 | | |
| Canines | 11(61.1%) | 0.63 | 0.21-1.83 | 0.40 |
| Premolars | 94(72.9%) | 1.06 | 0.57-1.97 | 0.85 |
| Molars | 96(73.3%) | 1.10 | 0.59-2.05 | 0.74 |
| **Coronal restoration quality** | | | | |
| Adequate | | | | |
| Inadequate | 105(66%) | 1 | | |
| | 153(76.9%) | 1.71 | 1.07-2.72 | 0.02 |
| **Coronal restoration type** | | | | |
| Temporary or absent | | | | |
| Filling inserted during plastic phase | 20(90.9%) | 1 | | |
| Full coverage crown | 169(76.3%) | 0.20 | 0.04-0.90 | 0.03 |
| | 69 (81.2%) | 0.43 | 0.09-2.03 | 0.28 |
| **Cavity design** | | | | |
| CL IV | 1(20%) | 1 | | |
| CL I | 20(64.5%) | 7.27 | 0.72-73.3 | 0.09 |
| CL II | 113 (70.6%) | 9.61 | 1.07-88.3 | 0.04 |
| CL III | 31 (62%) | 6.52 | 0.67-62.8 | 0.10 |
| **Gingival status** | | | | |
| Healthy | 122(66.3%) | 1 | | |
| Gingival inflammation | 126(78.3%) | 1.85 | 1.14-2.99 | 0.01 |
| **Periodontal status** | | | | |
| Healthy | 207 (74.2%) | 1 | | |

| | | | | |
|---|---|---|---|---|
| Periodontal disease | 38(63.3%) | 1.66 | 0.92-3.00 | 0.09 |
| **Intracanal posts** | | - | | |
| Present | 46 (79.3%) | 1 | | |
| absent | 210 (70.7%) | 0.63 | 0.31-1.24 | 0.18 |
| **Opposing tooth** | | - | | |
| Present | 225 (70.8%) | 1 | | |
| Absent | 28(82.4%) | 1.40 | 0.62-3.13 | 0.40 |
| **Root canal filling quality** | - | | | - |
| Under and over-filling | | | | |
| Inadequate homogeneity | 158(78.6%) | 2.57 | 1.66-4.002 | <0.001 |
| Inadequate conicity | 199(80.6%) | 3.65 | 2.24-5.95 | <0.001 |
| - | 198(78.9%) | 2.92 | 1.79-4.76 | <0.001 |
| | | | | - |

# Figures

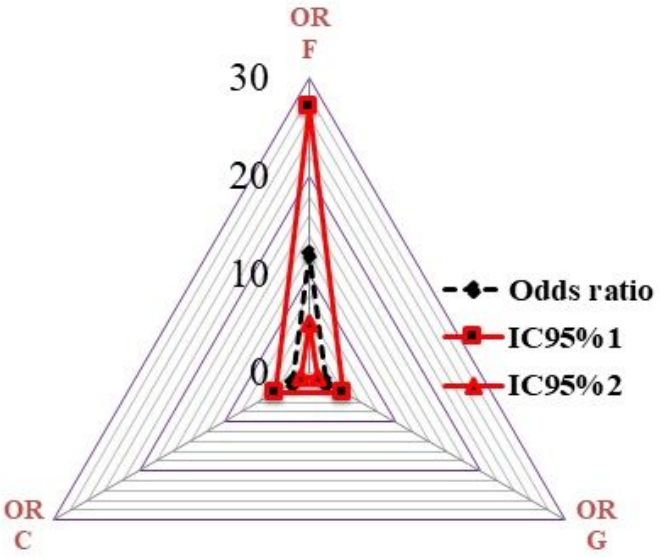


**(Figure A)**

OR: Odds ratio (dashed line) and 95% confidence interval (solid line), **F**: root canal filling quality; **C**: coronal restoration quality; **G**: gingival inflammation.

**Figure 1**

OR:odds ratio (dashed line) and 95% confidence interval (solid line), F: root canal filling quality, C: coronal restoration quality, G: gingival inflammation.