The SD-OCT Characteristics After 577nm Laser Membranotomy of Sub-inner Limiting Membrane Hemorrhage

Yongpeng Zhang
Beijing Tongren Hospital
Jipeng Li
Beijing Tongren Hospital
Xusheng Cao
Beijing Tongren Hospital
Haiying Zhou
Beijing Tongren Hospital
Liyun Jia
Beijing Tongren Hospital
Kai Ma
Beijing Tongren Hospital
Xiaoyan Peng (drpengxy@163.com)
Beijing Tongren Hospital

Research Article

Keywords: Inner limiting membrane, hemorrhage, laser membranotomy, OCT

Posted Date: May 27th, 2021

DOI: https://doi.org/10.21203/rs.3.rs-540756/v1

Abstract

Background We investigate the SD-OCT features of sub-inner limiting membrane (sub-ILM) hemorrhage after 577nm laser membranotomy.

Methods The ocular fundus photography and SD-OCT of patients who received 577nm laser membranotomy for sub-ILM hemorrhage were assessed from January 2017 to March 2021 in this retrospective cases series study.

Results Total of 7 patients (7 eyes) were enrolled in this study, in which 3 were female and 4 were male. The SD-OCT of ILM after laser treatment showed two distinctive features: the ILM falling back to retina (4 cases) or persistent unsealed ILM which forming premacular cavity (3 cases). The SD-OCT of macular fovea after laser treatment showed three features: normal contour (3 cases), macular hole (1 cases) and epiretinal membrane (1 case). The outer retina showed “peg-like” or “patchy-like” structure on the site of ILM attached to retina.

Conclusions 577nm laser is effective in treating of sub-ILM hemorrhage and SD-OCT is effective for diagnosis and following-up of sub-ILM hemorrhage.

Background

Sub-inner limiting membrane(sub-ILM)hemorrhage is less common in clinic which can cause sudden and severe vision loss. Spontaneous resorption of the blood entrapped in the sub-ILM space tends to be slow and may result irreversible retinal damage and long-standing visual impairment[1–5].

Sub-ILM hemorrhage has been associated with various causes, the most common being Valsalva retinopathy and Terson’s syndrome, other causes being blunt trauma, ruptured retinal macroanuerysm, blood dyscrasias, proliferative diabatic retinopathy(PDR), age-related macular degeneration, shaken baby syndrome, Dengue maculopathy, Weil's disease, and so on[1 3 6–17,].

Sub-ILM hemorrhage appear as sharply demarcated, dome-shaped hemorrhage at the posterior pole and generally not across vascular arc. A glistening light reflex reflected from the ILM overlying the hemorrhage can often be observed. However, it is usually difficult to distinguish between a sub-ILM and a subhyaloid hemorrhage funduscopically[2–4]. Some new methods were used recently to assess the exact location of hemorrhage, such as “double ring” sign with the “inner ring” caused by the sub-ILM hemorrhage and the “outer ring” caused by the sub-hyaloid hemorrhage[13,18,19]. Perimacular folds may be seen with large sub-ILM hemorrhage[12] and "Arcus retinalis" may be a novel clinical marker of sub-ILM hemorrhage[20].

OCT is the most effective and noninvasive method for diagnosis of sub-ILM hemorrhage before treatment. Just above the level of sedimented blood it can demonstrate two distinct membranes: a highly reflective band immediately above the hemorrhage corresponding to the ILM, and an overlying patchy membrane with low optical reflectivity consistent with the posterior hyaloid[3 4] and in some cases vertical “peg-like” structure can be seen in the outer retina[20]. The systemic demonstration of SD-OCT characteristics after laser treatment is insufficient.

The treatment methods of sub-ILM hemorrhage include Observation[17 20 21], membranotomy by argon, krypton, or YAG laser[1 3 9 11 18 20 22 23,] intravitreal gas injection[14], intravitreal injection of tissue plasminogen activator(t-

PA)[8],intravitreal injection of anti-VEGF and vitrectomy with ILM peeling[3 5–8 10 13 15 16 20 24].

Here we present 7 cases of sub-ILM hemorrhage treated by 577nm semiconductor laser and assess the clinical and OCT features after laser.

Methods

9 patients (9 eyes) of sub-ILM hemorrhage from Tongren eye center, Capital Medical University were analyzed in this retrospective cases series study from January 2017 to March 2021. Two patients had persistent vitreous opacity after laser and the OCT could not be obtained, so there were total 7 patients (7 eyes) were enrolled in the study. The study adhered to the tenet of declarations of Helsinki and All the patients were informed of the risks and benefits of lasers and other treatment choice. Informed consent was obtained from all subjects or, if subjects are under 18, from a parent and/or legal guardian.

A comprehensive ophthalmologic examination, including best corrected visual acuity (BCVA), slit-lamp examination, intraocular pressure, ocular fundus examination with biomicroscopy and indirect ophthalmoscopy, were performed preoperatively as well as postoperatively.

Fundus photographs (Canon™ or Optos™) and SD-OCT (Heidelberg™ or Optovue™) were taken for every patient before and after laser.

The laser wavelength applied in this study was 577nm (Lumenis™). The power of laser was from 300mw to 400mw. The laser spot size was 200γm. The exposure time of laser was 200ms. The number of laser spots was 1 to 14.

Results

A total of 7 patients (7 eyes) were eligible for OCT analyses after 577nm membranotomy of sub-ILM hemorrhage. There were 3 female and 4 male with age 15 to 78 years old (average 44.43 years). The causes of sub-ILM hemorrhage were Valsalva retinopathy (4 cases), diabetic retinopathy (1 cases) and macroaneurysm (2case).

The time of symptom to laser interval was 1 to 25 days with average of 11 days. Drainage of sub-ILM hemorrhage was successful in all patients after laser membranotomy. Drainage could be seen immediately after laser burst in 5 cases and one day later in other 2 cases. The follow-up time was from 1.5 to 9 months (average 3.71 months) (Table 1).

Table 1
The general information of 7 patients

No.	Sex	Diagnosis	Eye	Symptom to laser interval (day)	Size of hemorrhage (DD)	Power of laser (mv)	Folliow-up time (month)	Initial BCVA	Final BCVA
1	female	Valsalva	R	8	4×4	300	3	0.01	0.05
2	male	Valsalva	L	7	3×3	300	3.5	0.01	1.0
3	male	Valsalva	R	12	5×5	300–400	9	0.02	0.7
4	female	macroanuerysm	R	15	3×3	400	4	Fingue count	0.01
5	female	diabetic retinopathy	R	25	4×4	320–340	2.5	Fingue count	0.2
6	male	Valsalva	R	11	4×5	300	2.5	0.02	0.2
7	male	macroanuerysm	R	1	4×3	320	1.5	0.02	0.1

The OCT features of sub-ILM hemorrhage after 577nm laser membranotomy could be classified into 3 aspects, that was the morphology of ILM, macular fovea and the outer retina. The ILM could reattached to retina (3 cases). The hole on ILM could be unsealed and formed a cavity between the ILM and the retina (4 cases). The macular fovea might be normal contour (3 cases), macular hole (MH) (1 case), epiretinal membrane (1 case), or the macular fovea be coved by insufficient drainage of sub-ILM hemorrhage(2 case). There were “peg-like” or “patchy-like” structure in outer retina (4 cases). (Table 2, Fig. 1–3)

Table 2
OCT features after laser treatment

No.	ILM morphology after laser		Macular contour after laser				Outer retina morphology after laser
	ILM falling back	ILM stiff and forming sub-ILM cavity	Normal fovea contour	Macular hole	Epiretinal membrane	Fovea covered by sub-ILM hemorrhage	“peg-like” or “patchy -ike” structure
1	Yes			Yes			Yes
2		Yes	Yes				
3		Yes	Yes				
4	Yes		Yes				Yes
5		Yes			Yes		
6		Yes				Yes	Yes
7	Yes					Yes	Yes

Discussion

Premacular or preretinal hemorrhage and subhyaloidal hemorrhage were the commonly used synonyms for subhyaloidal and sub-ILM hemorrhages, Hemorrhage beneath the ILM is located within the neuroretina and the anatomically correct description should be sub-ILM hemorrhage[4]. The figures in some researches published before may be incorrect according to the anatomy definition and may be confused between subhyaloidal and sub-ILM hemorrhage.

Sub-ILM hemorrhages are caused by multiple reasons including Valsalva retinopathy, blood dyscrasias, Terson syndrome, and ocular trauma[3 4]. In this study, 4 cases were Valsalva retinopathy, 2 case was macroaneurysm, 1 case was diabetic retinopathy. Blood in sub-ILM hemorrhages spontaneously clears significantly slower than that of sub-hyaloid hemorrhages and sub-hyaloid hemorrhages can often be observed for spontaneous improvement. The catabolites in sub-ILM hemorrhage may lead to retinal toxicity and proliferative vitreoretinopathy[3–5]. In conclusion, the patients of sub-ILM hemorrhage with earlier intervention have better visual outcomes[5].

Differentiating between the two types of hemorrhages clinically is a challenge. Some signs in fundus photography may be the clue to sub-ILM hemorrhage, Sub-ILM hemorrhages appear as sharply demarcated, round hemorrhages at the posterior pole and a glistening light reflex of ILM can often be observed[2 3]. Another sing is “double ring” with the “inner ring” caused by the sub-ILM hemorrhage and the “outer ring” caused by the sub-hyaloid hemorrhage[13 18 19],but this may not be true in some cases (as case 7). Some authors emphasized “perimacular folds” may be seen with large sub-ILM hemorrhage[12] and “Arcus retinalis" might be a novel clinical marker of sub-ILM hemorrhage[20]. Until now the only method to confirm the sub-ILM hemorrhage still remains intraoperative staining of the membrane overlying the hemorrhage and pathological approval[10]. OCT remains the non-invasive mainstay for accurate diagnosis[1–4 10 11 20].

Normally ILM cannot be distinguished on OCT because of its thickness and anatomical characteristics. Foveal ILM has a thickness of approximately 100 nm, whereas the parafoveal ILM has a thickness of up to 3 μm[25]. The OCT features of sub-ILM hemorrhage is mentioned above. If there is coexistence of sub-ILM with sub-hyaloid hemorrhage or the posterior vitreous detachment is visible, the diagnosis is easy, otherwise OCT as a tool for diagnosis of sub-ILM hemorrhage is still difficult[3–5].

The OCT features of sub-ILM hemorrhage after laser membranotomy has three main aspects, that is the change of ILM, the macular fovea and the outer retina.

The ILM is obviously thicken in sub-ILM hemorrhage. The ILM is straight and stiff in most cases but also can be undulant (case 7) after laser. The ILM can reattach to retina, or do not attach and form a cavity between the ILM and the retina after membranotomy (Fig. 1–3).

In this study, the ILM did not attach to retina and had the “cavity-structure” in 4 cases. This phenomenon was not less common. Zhou et al[9] had demonstrate some reasons for this complication, such as large perforating puncture of the ILM and liquefaction of vitreous[9]. In our study, the average age of ILM fallen back group was 63 years old and the average age of ILM not fallen back was 30.5 years old, so we thought vitreous liquefaction might be the reason of ILM fallen back instead of “cavity-structure” formation.

The macular fovea might be normal contour after laser. But MH and epiretinal membrane could also be seen[2 5 7 8 13 15 21 24]. In this study, the macular fovea have normal contour in 3 cases, MH in 1 case and epiretinal membrane in 1 case. The macular fovea are covered by insufficient drainage of sub-ILM hemorrhage in 2 case. Several causes may contribute to the formation of MH. It could be induced by hemorrhage breaking through the neurosensory layers, traction of ILM to the fovea or toxicity of the long lasting blood [21 24]. The primary closure rate of MH after sub-ILM hemorrhage seems to be low (57%) when compared with the rate for idiopathic MH (> 90%)[14]. In this the study (case 1) the MH is unsealed even after vitrectomy and silicone oil tamponade.

There were “peg-like” structure or “patchy-like” structure in outer retina in 4 cases of this study. Kumar V et al[20] described a retinal yellowish-white arc (“arcus retinalis”) corresponding to the outer margin of sub-ILM hemorrhage. The “peg-like” structures on OCT are the result of localized traction on the retina by the ILM. Another reason may be exudates or hemorrhage in the outer retina derived from the sub-ILM hemorrhage (“patchy-like”) (Fig. 1).

Other OCT changes of sub-ILM hemorrhage after laser include hyperreflective spots in vitreous cavity and on the retina side of ILM (residual hemorrhage), the undulant surface of the retinal nerve fiber layer and retinoschisis at the attachment of ILM to retina (Fig. 2).

Laser is an effective method to treat sub-ILM hemorrhage but some attention should be paid to. Firstly, the best time of laser is no more than 21 days from the onset of hemorrhage[7 9]. The size and thickness (Cushing effect to prevent damage to the retina) of hemorrhage should be taken into count. Too small or too thin hemorrhage should avoid laser. Do not try to do laser If the lower boundary of the sub-ILM hemorrhage is near the central area of the macula. If the patient has frequent eye movement the laser should be avoided. Secondly, if sub-ILM combined with PDR, the laser membranotomy must be combined with photocoagulation in the lower periphery retina. Lastly, there is the possibility of immediate drainage or delayed drainage (1 day to 1 week). The

hemorrhage with obvious fluid level is easy to be drained immediately, while hemorrhage without obvious fluid level is not easy to be drained. Even if the hemorrhage is drained into the vitreous cavity, the absorption is sometimes very slow which still affect the recovery of visual acuity and fundus observation (such as case 6 and 7) and vitrectomy may be applied.

The shortcoming of this study is limited cases and short time of follow-up, also there is no control groups of other types of laser or surgery. Prospective and randomized trials with large patient numbers will be required to validate the effectiveness and safety of 577nm laser as a treatment modality for sub-ILM hemorrhage.

Conclusions

Sub-inner limiting membrane hemorrhage is seldom seen in clinic and OCT is an effective tool in diagnosis. Inner limiting membrane, macular fovea and outer retina are the three sites we should note after laser membranotomy.

Declarations

Ethics approval and consent to participate

The research were approved by the ethics committee of Beijing Tongren Hospital.

Informed consent was obtained from all subjects or, if subjects are under 18, from a parent and/or legal guardian.

Consent for publication

Informed consent for publication of the data was obtained from all subjects or, if subjects are under 18, from a parent and/or legal guardian.

Availability of data and materials

All data generated or analysed during this study are included in this published article and its supplementary information files.

Competing interests

The authors declare that they have no competing interests.

Funding

NO funding in this study.

Authors' contributions

Zhang Yongpeng wrote the main manuscript text and provided a case.

Li Jipeng provided a case and reviewed the manuscript.

Cao Xusheng provided a case and reviewed the manuscript.

Zhou Haiying provided a case and reviewed the manuscript.

Jia Liyun provided a case and reviewed the manuscript.

Ma Kai provided two cases and reviewed the manuscript.

Peng Xiaoyan reviewed the manuscript and gave the ieda for case analysis and discussion.

Acknowledgements

The authors thanks to Zhang Cong, Hou Simeng, Jiao Xuan, Yan Wei, Xiong Ying for taking pictures of OCT and fundus.

References

1. De Miranda Cordeiro F, De Pinho Botelho D, Braga CS, et al. YAG laser membranotomy for sub-inner limiting membrane hemorrhage due to ruptured macroaneurysm. Can J Ophthalmol. 2020;14:S0008-4182(20)30745-6.
2. Ulbig MW, Mangouritsas G, Rothbacher HH, et al. Long-term results after drainage of premacular subhyaloid hemorrhage into the vitreous with a pulsed Nd:YAG laser. Arch Ophthalmol. 1998;116:1465-9.
3. De Maeyer K, Van Ginderdeuren R, Postelmans L ,et al. Sub-inner limiting membrane haemorrhage: causes and treatment with vitrectomy. Br J Ophthalmol. 2007;91:869-72.
4. Mennel S. Subhyaloidal and macular haemorrhage: localisation and treatment strategies. Br J Ophthalmol. 2007;91:850-2.
5. Hussain RN, Stappler T, Hiscott P, et al. Histopathological Changes and Clinical Outcomes following Intervention for Sub-Internal Limiting Membrane Haemorrhage. Ophthalmologica. 2020;243:217-23.
6. Adán A, Pelegrin L, Alforja S, et al. Optical coherence tomography findings and management of sub-internal limiting membrane haemorrhage. Acta Ophthalmol. 2008 ;86:582-3.
7. Munteanu M, Rosca C, Stanca H. Sub-inner limiting membrane hemorrhage in a patient with Terson syndrome. Int Ophthalmol. 2019;39:461-4.
8. Tsuiki E, Kusano M, Kitaoka T. Complication associated with intravitreal injection of tissue plasminogen activator for treatment of submacular hemorrhage due to rupture of retinal arterial macroaneurysm. Am J Ophthalmol Case Rep. 2019;16:100556.
9. Zou M, Gao S, Zhang J, et al. Persistent unsealed internal limiting membrane after Nd:YAG laser treatment for valsalva retinopathy. BMC Ophthalmol. 2013;13:15.
10. Alvarez-Torres E, Acaba LA, Berrocal MH. Sub-internal limiting membrane hemorrhage associated with Weil's disease. Am J Ophthalmol Case Rep. 2019;16:100546.
11. Adel B, Israel A, Friedman Z. Dense subhyaloid hemorrhage or subinternal limiting membrane hemorrhage in the macula treated by Nd:YAG laser. Arch Ophthalmol. 1998;116:1542-3.
12. Bhatnagar A, Wilkinson LB, Tyagi AK, et al. Subinternal limiting membrane hemorrhage with perimacular fold in leukemia. Arch Ophthalmol. 2009;127:1548-50.
13. Kim KY, Yu SY, Kim M, et al. Macular hole formation after pars plana vitrectomy for the treatment of Valsalva retinopathy: a case report. Korean J Ophthalmol. 2014;28:91-5.

14. Kumar A, Ambiya V, Baranwal VK, et al. Pneumatic Displacement of a Dense Sub-inner Limiting Membrane Pre-macular Hemorrhage in Dengue Maculopathy: A Novel Treatment Approach. Turk J Ophthalmol. 2019;49:51-54.
15. Nakamura H, Hayakawa K, Sawaguchi S, et al. Visual outcome after vitreous, sub-internal limiting membrane, and/or submacular hemorrhage removal associated with ruptured retinal arterial macroaneurysms. Graefes Arch Clin Exp Ophthalmol. 2008;246:661-9.
16. Gao L, Dong C. Sub-inner limiting membrane haemorrhages. Lancet. 2013;382:535.
17. Tatlipinar S, Shah SM, Nguyen QD. Optical coherence tomography features of sub-internal limiting membrane hemorrhage and preretinal membrane in Valsalva retinopathy. Can J Ophthalmol. 2007;42:129-30.
18. Roth M, Eisenkopf L, Engineer D, et al. Lasermembranotomie beim Management einer akuten prämakulären Blutung : Fallvorstellung und Überblick zum Vorgehen [Laser membranotomy in the management of acute premacular hemorrhage : Case report and overview on the approach]. Ophthalmologe. 2018;115:1059-65. German.
19. Völcker D, Junker B, Hansen LL. Spontane Makulablutung. Subhyaloidal/Sub-Membrana limitans interna (MLI) [Spontaneous macula hemorrhage. Subhyaloid/sub-inner limiting membrane (ILM)]. Ophthalmologe. 2012;109:702-6. German.
20. Kumar V, Goel N. "Arcus retinalis": A novel clinical marker of sub-internal limiting membrane hemorrhage. Eur J Ophthalmol. 2020;22:1120672120934958.
21. Xie ZG, Yu SQ, Chen X, et al. Macular hole secondary to Valsalva retinopathy after doing push-up exercise. BMC Ophthalmol. 2014;14:98.
22. Krohn J, Kjersem B. Laser treatment of premacular haemorrhage. Tidsskr Nor Laegeforen. 2013;133:41. English, Norwegian.
23. Emre S, Doganay S, Demirel S, et al. A new technique: argon green laser-Nd:YAG laser combination for the treatment of premacular haemorrhage. Acta Ophthalmol. 2010;88:e94-5.
24. Sagara N, Kawaji T, Koshiyama Y, et al. Macular hole formation after macular haemorrhage associated with rupture of retinal arterial macroaneurysm. Br J Ophthalmol. 2009;93:1337-40.
25. J. Sebag. Vitreous-in Health and Disease,2014;ISBN 978-1-4939-1085-4, Springer New York.

Figures

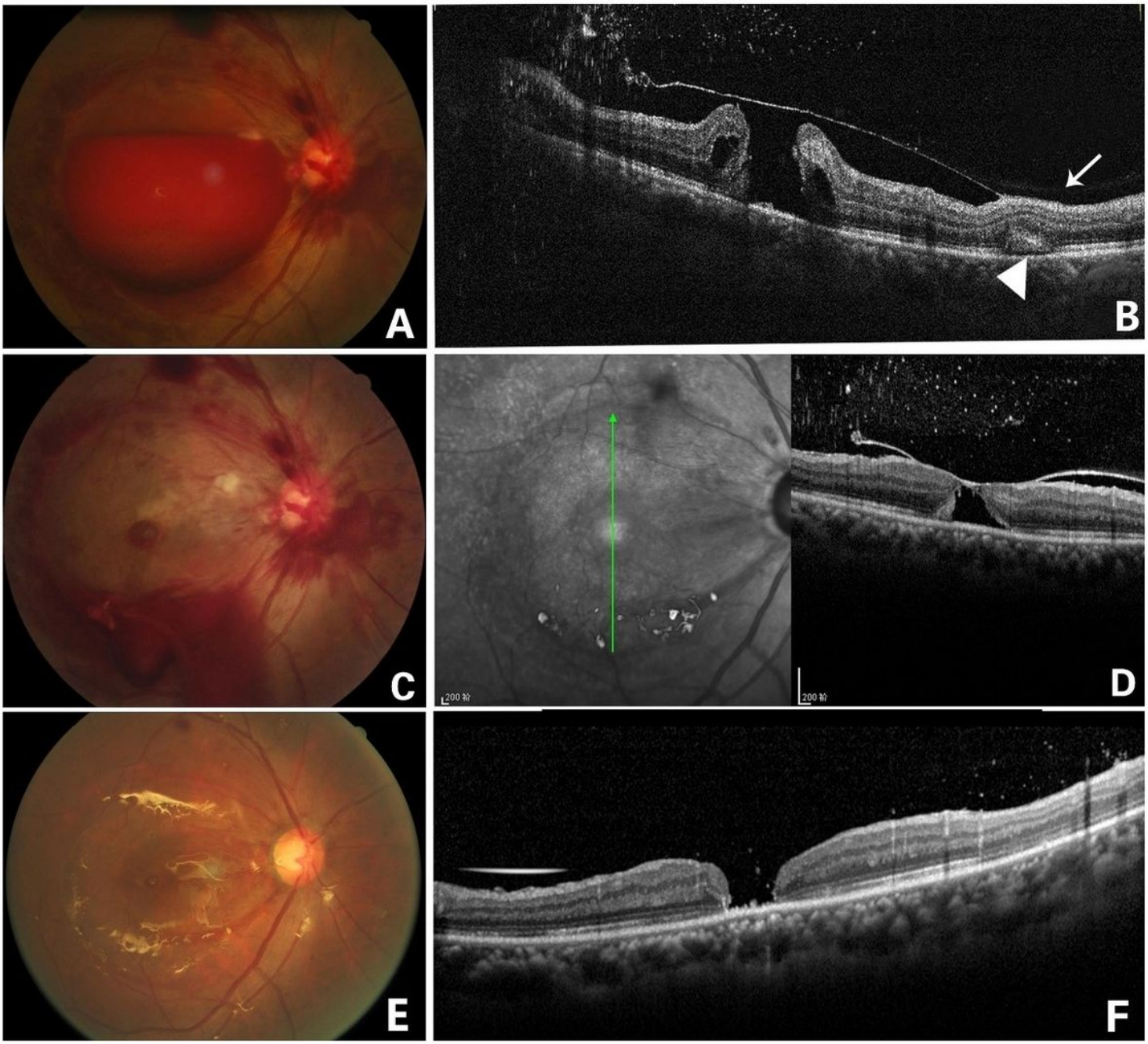

Figure 1

Fundus photograph of the right eye (case 1) showing a large sub-ILM hemorrhage (A). OCT of the right eye 4 days after laser showed ILM and ILM hole, multiple punctate hyperreflexia in the vitreous cavity. Full-thickness macular hole under the ILM could be seen. Posterior vitreous cortex was in front of the ILM attached to the retina (arrow), “Patchy-like” structue located in the outer retina(arrowhead) (B). The fundus photograph on the day of laser, blood flowed out from the hole of ILM, Vitreous bleeding and a round lesions of macula could be seen, which was later confirmed as macular hole (C). OCT two weeks later, the ILM fell back and attached to the surface of the macular hole but the macular hole did not close (D). Fundus photograph of right eye two months after laser treatment, vitrectomy with ILM peeling and silicone oil filling were performed in the right eye (E). OCT two months later after vitrectomy showed that the macular hole was still not closed (F).

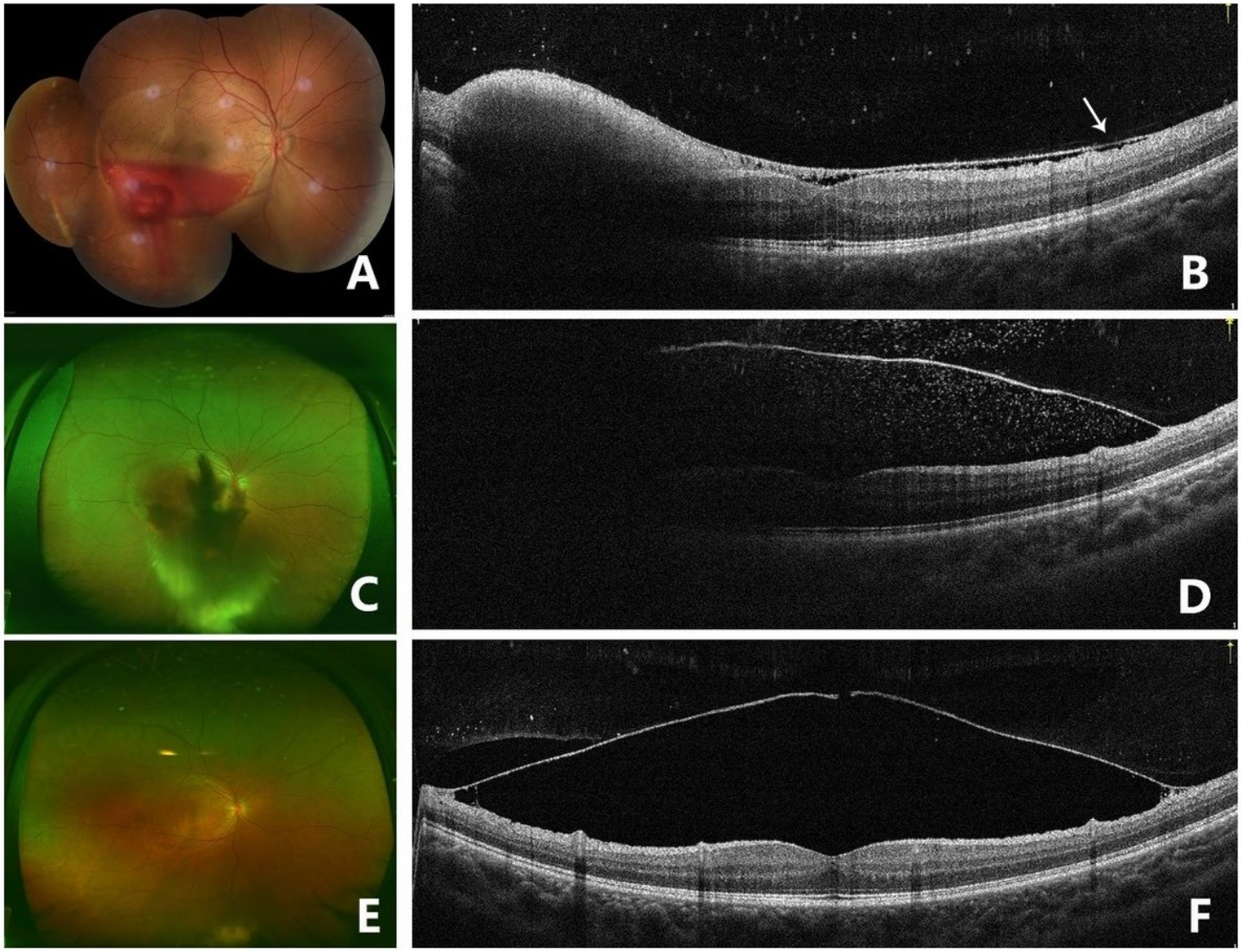

Figure 2

Fundus photograph of the right eye (case 3) showing sub-ILM hemorrhage 5 days after laser membranotomy. Blood could be seen flow out from the ILM hole (A). OCT on the 5th day after laser treatment in the right eye showed that the ILM above the macula dropped and a thin hyporeflective band above the anterior surface of ILM, which was the posterior vitreous cortex (arrow). The hyperreflective spots could be seen on the retinal surface of the ILM, and residual hemorrhage under ILM could still be seen in the lower part of macular fovea. The contour of macula fovea was normal but the surface of retinal nerve fiber layer was undulant. Hyperreflective point could be seen in the vitreous cavity. The BCVA improved to 0.5 (B). The fundus photograph one month after laser treatment, the right eye developed sub-ILM hemorrhage and vitreous hemorrhage again, and the BCVA decreased to 0.05 (C). OCT of the right eye one month after laser treatment showed that the ILM was stiff and protruding, and there were hyperreflective points inside and outside the ILM (D). The fundus photography showed that the sub-ILM hemorrhage had been absorbed 9 months after laser, and vitreous opacity could be seen in the lower periphery of vitreous cavity (E). OCT of the right eye 9 months after laser showed that the ILM hole did not heal and a cavity was formed below. Retinoschisis was seen at the attachment of ILM to retina (F).

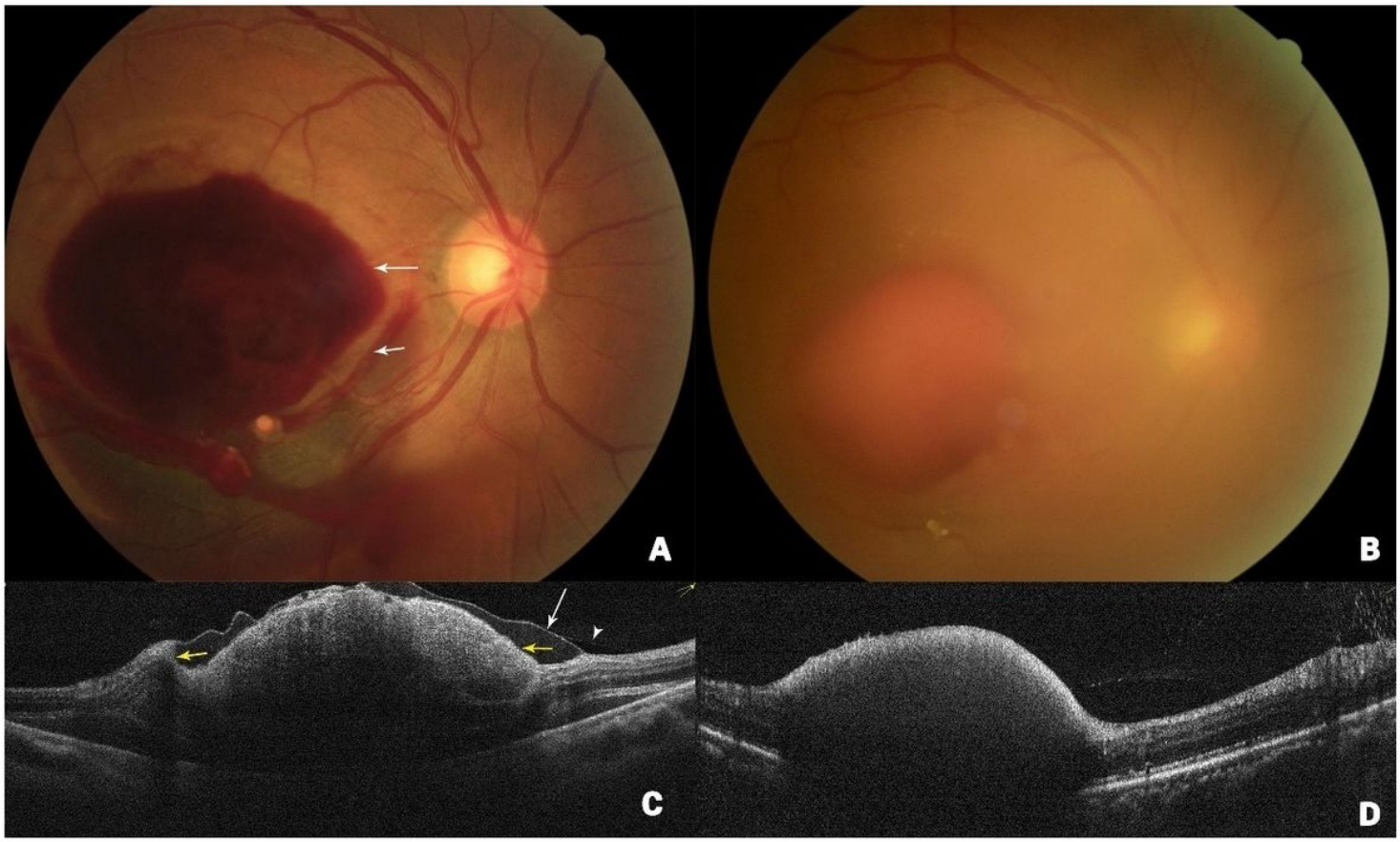

Figure 3

Fundus photograph of the right eye (case 7) showing sub-ILM hemorrhage on the day of laser membranotomy. Blood could be seen flow out from the ILM hole. There were two “ring” of hemorrhage which represented two kinds of sub-ILM hemorrhage as liquefying (short arrow) and coagulative (long arrow). This is different from “double ring” sign with the “inner ring” caused by the sub-ILM hemorrhage and the “outer ring” caused by the sub-hyaloid hemorrhage (A). 1.5 months later the sub-ILM hemorrhage became smaller and the sub-retina hemorrhage had been absorbed completely (B). The OCT of right eye. The arrowhead showed the posterior vitreous cortex. The white arrow showed the wavy-like ILM. The yellow arrow showed the sub-ILM hemorrhage with different contents (C). The OCT 1.5 months later after laser. the sub-ILM hemorrhage had not been absorbed completely but the ILM had fallen back to retina (D).