Topographical Landmarks for Identification of Inferior Alveolar Nerve and its Surgical Implications - a Cadaveric Study

Ariyanachi K (ariyan.mahi@gmail.com)
Government Medical College

Sushma P
All India Institute of Medical Sciences

Research Article

Keywords: Inferior alveolar nerve, nerve block techniques, sagittal split osteotomies, mandibular foramen.

Posted Date: June 2nd, 2021

DOI: https://doi.org/10.21203/rs.3.rs-541391/v1

Abstract

Background: Inferior alveolar nerve, which arises from the posterior division of the mandibular nerve, contains both sensory and motor fibres. The intraosseous course of the nerve is variable. Mandibular foramen is situated on the medial surface of the mandibular ramus. It is an important anatomical landmark for procedures like sagittal split osteotomies and inferior alveolar nerve block.

Methods: The precise location of mandibular foramen was studied by the dissection of formalin fixed cadavers available for undergraduate dissection for a period of two years fron 2014-2016.

Results: The mandibular foramen was 21±3.33 mm superior to the gonion at an angle of $98^0 \pm 5^0$ with the base of the mandible. The mandibular foramen was 20.13±3.1 mm inferior to the lowest point of the mandibular notch. Accessory mandibular foramen was observed in 9.37% of the samples dissected.

Conclusion: The present study explains the position of mandibular foramen in relation to prominent bony landmarks and the knowledge about the mandibular foramen, helps dental surgeons during inferior alveolar nerve blocks and split osteotomies.

Practical implications: Failure rate of the inferior alveolar nerve block has been reported to be approximately 20-25%. A thorough anatomical knowledge of the mandibular ramus is essential for inferior alveolar nerve blocks and sagittal split osteotomies, since they are technically difficult procedures and as they are also associated with a higher incidence of complications.

Background:

The mandibular nerve is the largest division of the trigeminal nerve containing both afferent and efferent fibers. It enters the infratemporal region via the foramen ovale and divides into anterior division and posterior division. The trunk gives off two branches namely nervus spinosus and nerve to medial pterygoid. The anterior division gives four branches namely masseteric nerve, deep temporal nerve, buccal nerve and nerve to lateral pterygoid. Masseteric nerve, deep temporal nerve and the nerve to lateral pterygoid innervate the muscles of mastication whereas the buccal nerve provides sensory innervation to the skin of the cheek, buccal mucosa and buccal gingivae of mandibular molars. The posterior division gives three branches namely auriculotemporal nerve, lingual nerve and inferior alveolar nerve.[1]

Inferior alveolar nerve, which arises from the posterior division of the mandibular nerve, contains both sensory and motor fibres. It enters the mandibular canal, via the mandibular foramen. It then leaves the mandibular canal through the mental foramen as the mental nerve. The intraosseous course of the nerve is variable. It may have a gentle curve towards the mental foramen or an ascending or descending pathway. [1, 2, 3, 4] Mandibular foramen is situated on the medial surface of the mandibular ramus. It is an important anatomical landmark for procedures like sagittal split osteotomies and inferior alveolar nerve block. [5, 6]

Inferior alveolar nerve block is a commonly performed procedure in dentistry. It involves the precise localization of the mandibular foramen and deposition of local anesthesia.[7] Failure rate of the inferior alveolar nerve block has been reported to be approximately 20–25%. [8, 9] Inadequate knowledge regarding the position of the mandibular foramen and the presence of accessory mandibular foramen are the main factors responsible for the failure of this technique.[10–14]

Bilateral sagittal split osteotomy (BSSO) and vertical ramus osteotomy (VRO) are the common procedures which are done for the correction of the mandibular prognathism, to reposition the mandible surgically. A thorough anatomical knowledge of the mandibular ramus is essential for these procedures, since they are technically difficult procedures and as they are also associated with a higher incidence of complications. [6, 15]

Methodology:

The study was conducted on sixteen formalin fixed cadavers, available for the undergraduate dissection in the Department of Anatomy. Ethical clearance was obtained from the Institute's Ethics Committee. The mandibles taken out from the cadavers were cleared of the muscle fibres attached to them. The position of the mandibular foramen was examined **(**Fig. 1**)**. The distance of the mandibular foramen from the angle of the mandible was measured using the vernier calliper (C). The distance of the mandibular foramen from the lowest point on the mandibular notch was additionally quantified (D). Using a protractor, the angle made by the mandibular foramen at the gonion with the base of the mandible was measured (E) **(**Fig. 2, Fig. 3**)**. The mandibles were then examined for the presence of any accessory mandibular foramen. **(Fig. 4**).

Statistical analysis was performed using GraphPad Instat 3 software.

- Descriptive statistics were determined for each variable.
- Comparisons were made for each variable on the right and the left side using the student t test.

Results:

1. Mandibular foramen topography

The parameters considered were:

- **C –** Distance from the angle of the mandible to the mandibular foramen
- **D –** Distance from the lowest point of the mandibular notch to the mandibular foramen
- **E –** Angle formed by the mandibular foramen at the gonion with the base of the mandible

Table 1
Mandibular foramen topography in relation to the angle of the mandible and mandibular notch. (**C –** Distance from the angle of the mandible to the mandibular foramen; **D –** Distance from the lowest point of the mandibular notch to the mandibular foramen; **E –** Angle formed by the mandibular foramen at the gonion with the base of the Mandible)

	Mean ± SD (n = 32)	**Range**
C (mm)	21 ± 3.33	13–27
D (mm)	20.13 ± 3.1	14–25
E (0)	98 ± 5	85–110

- The mandibular foramen was **21 ± 3.33 mm** superior to the gonion at an angle of **980 ± 50**

with the base of the mandible

- The mandibular foramen was **20.13 ± 3.1 mm** inferior to the mandibular notch

Table 2
Comparison of the measurements related to the topography of the mandibular foramen between the right and the left side. (**C –** Distance from the angle of the mandible to the mandibular foramen; **D –** Distance from the mandibular notch to the mandibular foramen; **E –** Angle formed by the mandibular foramen at the gonion with the base of the mandible.)

	Side	**Mean ± SD (n = 16)**	**Range**	**p value**
C (mm)	Right	21.18 ± 3.12	15–26	0.755
	Left	20.81 ± 3.61	13–27	
D (mm)	Right	20 ± 3.48	14–25	0.824
	Left	20.25 ± 2.79	16–24	
E (0)	Right	98.43 ± 5.97	85–110	0.739
	Left	97.8 ± 4.46	90–110	

In the sixteen formalin fixed cadavers dissected, no statistically significant difference was observed in the measurements related to the topography of the mandibular foramen between the right and the left side ($p > 0.05$)

Accessory mandibular foramen was observed in 9.37% of the specimens dissected

Discussion:

A precise knowledge about the position of the mandibular foramen is indispensable to attain a successful inferior alveolar nerve block. The data obtained from dry mandibles and radiographs have shown that the position of mandibular foramen is highly variable. [10, 13, 16]

In the current study, each half of the mandibles collected from sixteen cadavers were examined for the position of mandibular foramen in relation to the gonion, base of the mandible and mandibular notch. The position of the mandibular foramen in relation to the occlusal plane was also noted.

In the present study, in 87.5% of the samples, the mandibular foramen was at the level of the occlusal surface of the third molar. In 6.25% of the samples, it was approximately 9.51 mm above the occlusal surface of the third molar. In 6.25% of the samples, it was 8.19 mm below the occlusal surface of the third molar. Afadhali et al., advocated that the mandibular foramen could be located immediately above the occlusal plane of mandibular first molar and second premolar.[17] Augier M et al., and Basmajian et al., described the mandibular foramen slightly above the level of the occlusal plane [18, 19] whereas Thangavelu et al., demonstrated it at or below the level of the occlusal plane.[20]

In the previous studies, the mandibular foramen was described in relation to the ramus of the mandible and gonion angle. In a study conducted by Nicholson et al., the mandibular foramen was located predominantly at the centre of the ramus of the mandible.[11] In another study, the mandibular foramen was located slightly above the middle of the mandibular ramus.[21]Ennes JP et al., tried to explore the relation between the gonion angle and the distance between the mandibular foramen and the base of the mandible and concluded that the distance from the mandibular foramen to the base of the mandible was inversely related to the gonion angle.[12] (Table 3)

In the current study, the mandibular foramen was described in relation to the angle of the mandible. In addition, the angle formed by the mandibular foramen with the base of the mandible has been explored. The mandibular foramen was located 21 ± 3.33 mm superior to the gonion at an angle of $98^0 \pm 5^0$ with the base of the mandible (Table 1).

In this study, we also studied the relationship between the mandibular foramen and mandibular notch. Mandibular foramen was located 20.13 ± 3.1 mm inferior to the lowest point of

the mandibular notch (Table 1). This is consistent with the findings of Oguz et al., who observed that the shortest distance between the mandibular foramen and the mandibular notch was 22.27 mm. [22]

In the present study, no significant statistical difference was observed in the position of the mandibular foramen between the right and left sides (Table 2). This is consistent with the findings of Tsai HH [23] and Braga et al.,[24] indicating bilateral symmetry of the mandibular foramen.

Accessory Mandibular Foramen:

Presence of accessory mandibular foramen could lead to ineffective inferior alveolar nerve block.[21] In the present study, accessory mandibular foramen was observed in 9.37% of the samples (**Fig. 4**). In all 9.37% of the samples, they are seen inferior to the mandibular foramen. In a study done in Brazilian population, accessory mandibular foramina were observed below the mandibular foramen in 22.07% of the mandibles and above the mandibular foramen in 25.22% of the population.[25]

Table 3
Topography of the mandibular foramen

Sl. No	Authors	Landmarks	Location of the mandibular foramen
1.	Thangavelu et al., (2012)	Occlusal plane	At or below the occlusal plane
2.	Nicholson (1985)	Ramus of the mandible	Centre of the ramus of the mandible
3.	Mbajiorgu (2000)	Ramus of the mandible	2.5 mm behind the midpoint of width of the ramus; 3 mm superior to the midpoint of the height of the ramus
4.	Padmavathi et al., (2014)	Ramus of the mandible	0.9 mm behind the midpoint of width of the ramus; 1.4 mm superior to the midpoint of the height of the ramus
5.	Lavanyaet al., (2011)	Mandibular notch	20 mm below the centre of the mandibular notch
6.	Current study	Mandibular notch, gonion	20.13 mm inferior to the mandibular notch; 21 mm superior to the gonion at an angle of 98^0 with the base of the mandible

Conclusion:

The mandibular foramen was 21 ± 3.33 mm superior to the gonion at an angle of $98^0 \pm 5^0$ with the base of the mandible. The mandibular foramen was 20.13 ± 3.1 mm inferior to the lowest point of the mandibular notch. Accessory mandibular foramen was observed in 9.37% of the samples dissected. In this study, constant, predictable bony landmarks were used. Since the bony landmarks are fixed and reliable, they could be used effectively in clinical practice.

Declarations

Ethical approval and consent:

The study was approved by the Post Graduate Research Monitoring Committee [Reg. No: PGRMC/ANAT/02/2014]. Ethical clearance [Project No: JIP/IEC/SC/2014/8/600] was obtained from the Institute Ethics Committee.

Consent for publication:

The authors give our complete consent for publication of the result of this study

Availability of data and materials:

The dataset analysed during the current study are cited as references within the square brackets in the manuscript and corresponding details are provided under the reference title.

Competing interest:

There is no conflict of interest in this study

Funding:

Not applicable

Authors contribution:

1) Ariyanachi K * - conceptualization, investigation, methodology, writing, analysis, editing

2) Sushma P - editing

*Corresponding author

Acknowledgement:

Not applicable

References

1. Afadhali D, Russa, Flora M, Fabian. (2016). Position of the mandibular foramen in adult male Tanzania mandibles. Ital J Anat Embryol. 155:33-9.
2. Akal Uk, Sayan NB, Aydogan S, Yaman Z. Evaluation of neurosensory deficiencies of oral and maxilla facial region following surgery. Int J Maxillofac Surg. 2000;29:331-6.
3. Anderson LC, Kosinski TF, Mentag PJ. A review of the intraosseous course of the nerves of the mandible. J Oral Implantol. 1991;17:394-403.

4. Augier (1928). Sequelettecephalique. Poirier P, Charpy A, eds. In:Traite d Anatomic Humaine. 4th ed. Nicolas Massom Paris .p.264
5. Basmajian JV. (1980). Grant's method of Anatomy by Regions Descriptive and Deductive. 10th Williams and Wilkins Co: Baltimore: p.473.
6. Bremer G. (1952). Measurements of special significance in connection with anaesthesia of the inferior alveolar nerve. Oral Surg Oral Med Oral Pathol. 5:966-88.
7. Braga RRS, Silva LMT, Galvanini PA, Gomes PP, Victorini FR. (2014). Analysis of the mandibular position and its implication to the inferior alveolar nerve block. Rev Odontol Bras Central. 23:67
8. Daw JL, Paz MG, Han H, Aitken ME, Patel PK. (1999). The mandibular foramen: an anatomic study and its relevance to the sagittal ramus osteotomy. J Craniofac Surg. 10(6):475- 9.
9. Das S, Suri RK. (2004). An anatomico radiological study of an accessory mandibular foramen on the medial mandibular surface. Folia Morphol. 63;511-3.
10. Ennes JP, Medeiros RM, Grant JC. (2009). Localisation of mandibular foramen and clinical impications. Int J Morphol. 27:1305-11.
11. Erika C. (2013). Bilateral anomalous high position of the mandibular foramen: a case SurgRadiol Anat. 36(6):613-6.
12. Freire AR, Rossi AC, Prado FB, Caria PHF, Botacin PR. (2012). Incidence of mandibular accessory foramina in Brazilian population. J Morphol Sci. 29(3):171-3.
13. Grover PS, Lorton L. (1983) Bifid mandibular nerve as a possible cause of inadequate anaesthesia in the mandible. J Oral Maxillofac Surg. 41:177-9.
14. Hillerup S, Jensen R. (2006). Nerve injury caused by mandibular block anaesthesia. Int J Oral Maxillofac Surg. 35:437-43.
15. Javad Y, Kourosh TT, Mohammad HKM, Mohammad AG. (2010). Changes in the gonial angle following bilateral sagittal split osteotomy and vertical ramus osteotomy for mandibular excess. ePlasty 10: 165-
16. Kanan S, Pratik S, Parmar A. (2013). Study of location of the mandibular foramen in Indian dry mandibles. GJRA. 2(7):128-30.
17. Kaffe I, Ardekian L, Gelerenta I, Taicher S. (1994). Location of the mandibular foramen in panoramic radiographs. Oral Surg Oral Med Oral Patho 78:662-9.
18. Malamed S. (2012). Handbook of local anaesthesia. 6th Maryland Heights:Mosby: p.157- 253.
19. Nicholson (1985)A study of position of the mandibular foramen in adult human mandible. Anat Rec. 212:110-2.
20. Oguz O, Bozkii MG. (2002). Evaluation of location of mandibular and mental foramina in dry, young, adult human. West Indian Med J. 51(1):14
21. Ono E, Medici FE, Moraes MC, Castilho JC, Moraes ME. (2005). Anteroposterior location of the mandibular foramen of 7 to 12 year old children in panoramic radiographs. Braz dent J. 8:6-12.

22. Robinson PD. (2011). Infratemporal region and pterygopalatine fossa and temporomandibular joint. In: Standring S, editor. Gray's Anatomy: The Anatomical Basis of Clinical Practice. 40th Edinburgh: Elsevier Churchill Livingstone.p.541-3.
23. Thangavelu K, Kannan R, Senthil KN, Rethish E, Sabitha S, Sayeeganesh N. (2012). Significance of localization of mandibular foramen in an inferior alveolar nerve block. J Nat SciBiol Med. 3(2):156-60.
24. Tsai HH. (2002). Panoramic radiographic findings of mandibular growth from deciduous dentition to early permanent dentition. J ClinPaediatr Dent. 26:279-84.
25. Williams PL, Bannister, Berry LH, Collins P, Dyson M, Dussak JE et al. (2000) Gray's Anatomy: The anatomical basis of clinical practice. 38th ed. Edinburg: Elsevier Churchill Livingstone: p.576-7.

Figures

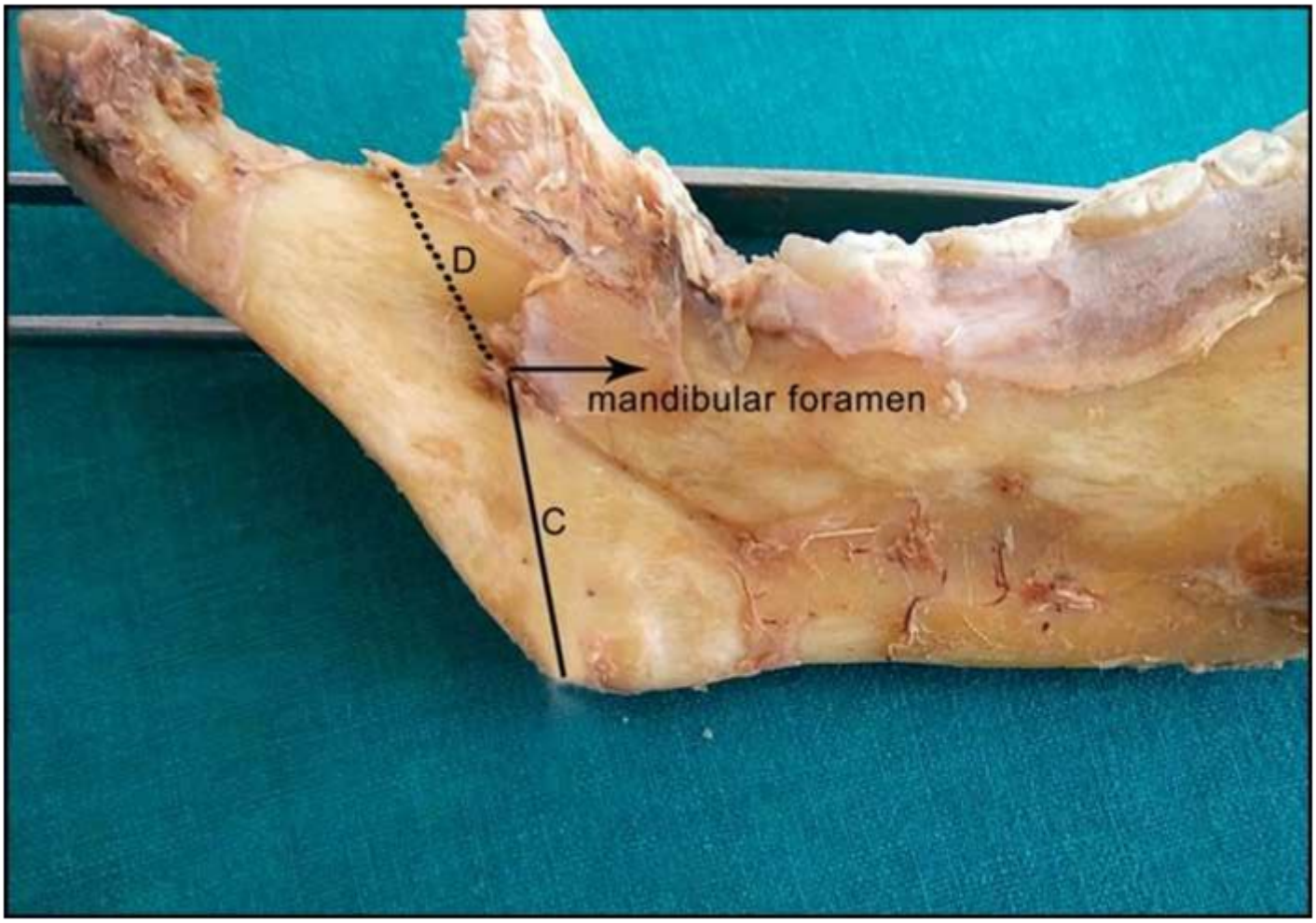

Figure 1

Topography of mandibular foramen on a cadaveric specimen.



Figure 2

Topography of mandibular foramen measured with a protractor.

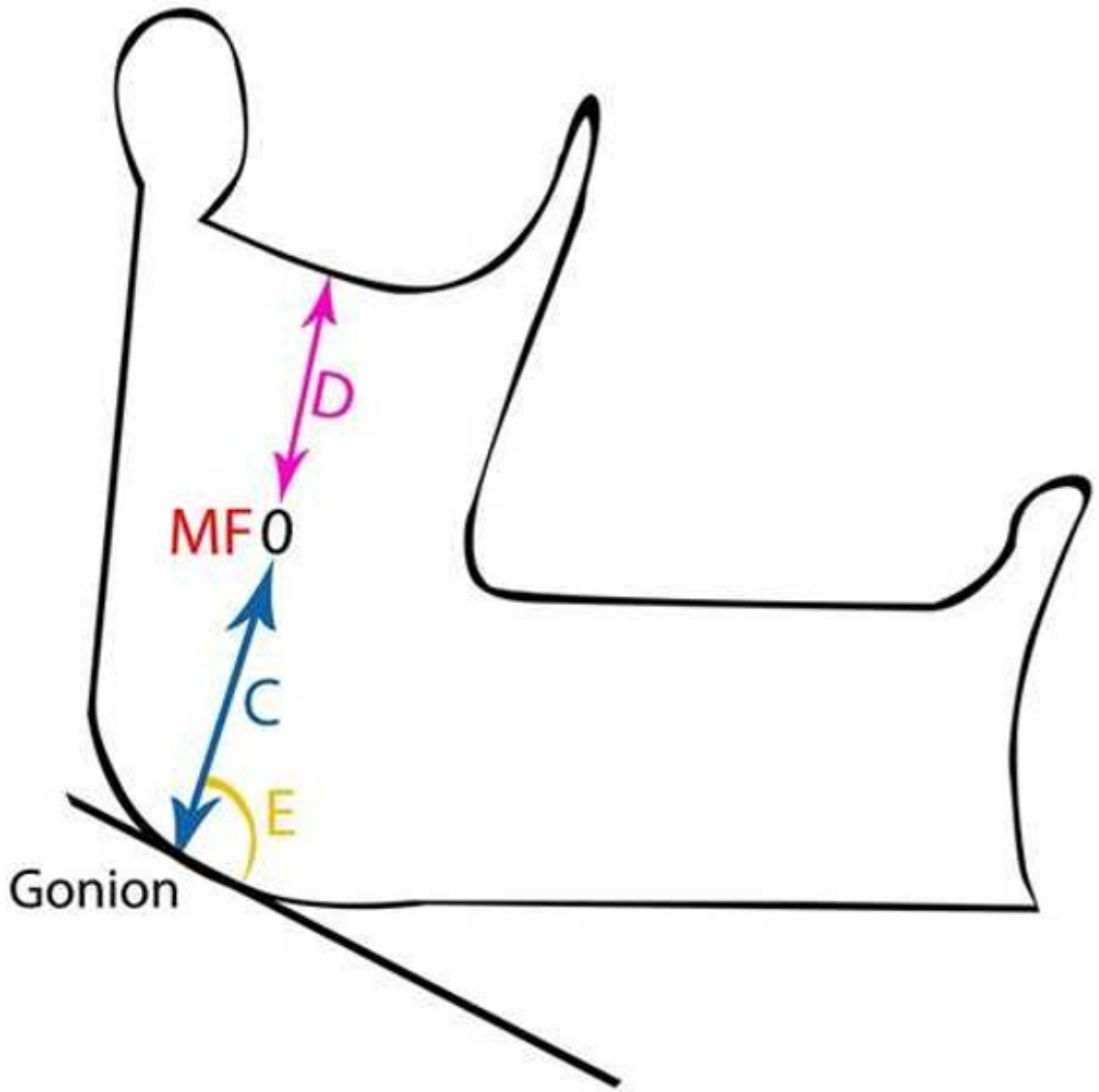

Figure 3

Landmarks for the mandibular foramen topography - C (Distance from the angle of the mandible to the mandibular foramen), D (Distance from the lowest point of the mandibular notch to the mandibular foramen), E (Angle formed by the mandibular foramen at the gonion with the base of the mandible), MF (Mandibular foramen).

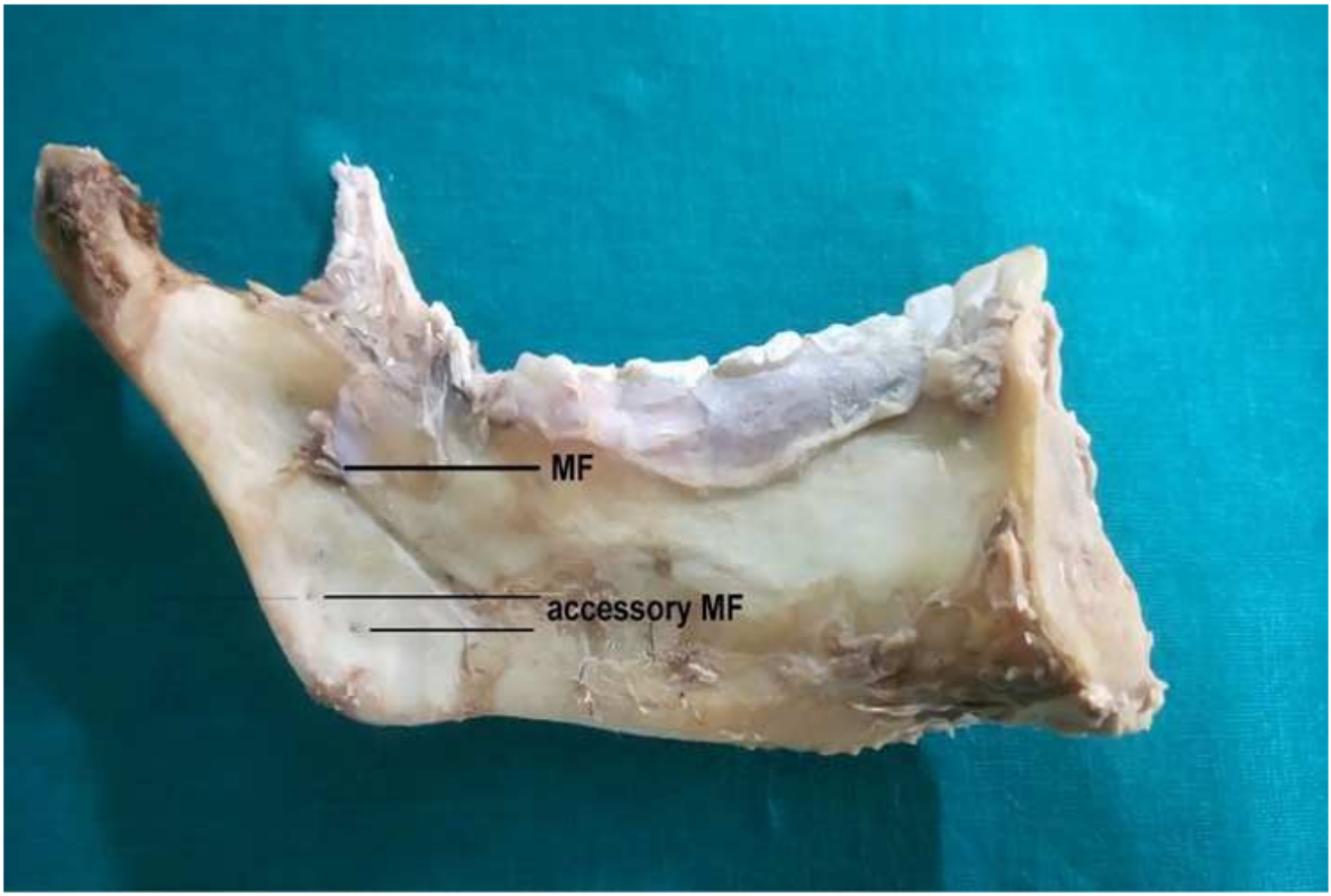

Figure 4

Accessory mandibular foramen