Incidence and Risk Factors for L5-S1 Complications After Long-level Floating Fusion in Adult Degenerative Scoliosis

Tinghua Jiang
Beijing Huairou Hospital of University of Chinese Academy of Sciences

Yunzhong Cheng
Beijing Chao-Yang Hospital: Beijing Chaoyang Hospital

Yong Hai (yong.hai@ccmu.edu.cn)
Beijing Chaoyang Hospital https://orcid.org/0000-0002-7206-325X

Xinuo Zhang
Beijing Chao-Yang Hospital: Beijing Chaoyang Hospital

Qingjun Su
Beijing Chao-Yang Hospital: Beijing Chaoyang Hospital

Xianglong Meng
Beijing Chao-Yang Hospital: Beijing Chaoyang Hospital

Aixing Pan
Beijing Chao-Yang Hospital: Beijing Chaoyang Hospital

Hanwen Zhang
Beijing Chao-Yang Hospital: Beijing Chaoyang Hospital

Gang Xu
Beijing Chao-Yang Hospital: Beijing Chaoyang Hospital

Research article

Keywords: Risk factors, Long floating fusion, L5-S1 degenerative diseases

Posted Date: May 28th, 2021

DOI: https://doi.org/10.21203/rs.3.rs-546988/v1

Abstract

Background

Whether to preserve L5-S1 with no pre-existing pathology in the fusion for patients with adult degenerative scoliosis (ADS) remains controversial. This study is to determine the predictors of L5-S1 diseases for the distal fusion to L5 in the long instrumented fusion for ADS.

Methods

A total of 159 patients with ADS who had undergone long floating fusion were evaluated with a minimum 2 year follow-up between 2014 to 2018. The patient- and surgical-related risk factors for each individual were identified by using univariate testing. All patients were divided into groups with and without L5-S1 diseases. Univariate testing was used to identify the potential risk factors. Independent risk factors of L5-S1 diseases were identified using multivariate logistic regression.

Results

BMD of the patients with L5-S1 diseases were much higher than that without L5-S1 diseases (P = 0.003). Postoperative sacral slope in L5-S1 diseases group was much higher than that without L5-S1 diseases group (P = 0.000). Patient-related independent risk factors for the development of L5-S1 diseases included gender (OR = 0.41, P = 0.016) and BMD (OR = 0.42, P = 0.000). Surgical-related independent risk factors for the development of L5-S1 diseases included fusion level (OR = 2.64, P = 0.033) and postoperative sacral slope (OR = 1.43, P = 0.000).

Conclusions

Gender and BMD were the most common patient-related independent risk factors, Fusion levels and postoperative sacral slope were the most common surgical-related independent risk factors. Prevention of these risk factors can reduce the incidence of L5-S1 diseases in patients with long floating fusion.

Introduction

Adult degenerative scoliosis (ADS), an aetiology of adult scoliosis, is defined as a scoliosis Cobb angle greater than 10° in patients with no history of adolescent idiopathic scoliosis during childhood and adolescence [1]. With the aging population in China, the prevalence of ADS is increasing at an alarming rate. Although the estimated prevalence of ADS ranges from 30–60% in the general population [2], it may be as high as 64%–68% among the elderly [3]. Surgical candidates with ADS exhibit a combination of severe low back pain, leg pain, neuro-claudication, radiculopathy, and spinopelvic malalignment. Although conservative treatments are often the first-line approach, surgical treatment may be performed for ADS patients with unsatisfactory improvement [4].

The purpose of the surgical procedure is decompression and spine stabilization with the realignment of both coronal and sagittal balance [5]; however, recent studies recommended avoiding long-level internal fixation in patients without substantial spinal imbalance [6]. Although intervertebral fusion and fixation are recommended in ADS decompression surgery, this procedure improves spinal alignment at the expense of mobility. So, whether to preserve L5-S1 with no pre-existing pathology in the fusion for patients with ADS remains controversial.

L5 was selected as the lowest instrumented vertebra (LIV) providing preservation of the L5-S1 motion segment and has the advantages of a minimized fusion level and decreased morbidity due to pseudarthrosis [7]. However, the most concerning problem of spinal fusion arthrodesis terminating at L5 is whether subsequent advanced L5-S1 disc degeneration would occur owing to concentrated stress [8]. Previous studies have assessed radiographic parameters, clinical outcomes, postoperative complications, and revision surgery resulting from subsequent L5-S1 disc degeneration [9]. However, no studies have discussed separately the patient- and surgical-related risk factors for subsequent L5-S1 complications after long-level spinal arthrodesis terminating at L5 in patients with ADS.

Therefore, the present study aimed to retrospectively evaluate the patient- and surgical-related risk factors of subsequent L5-S1 complications after posterior-only internal fixation and fusion stopping at L5 in patients with ADS who were followed up for a minimum of 2 years. Meanwhile, we also provide a general assessment of surgical outcomes that may be associated with the occurrence of subsequent L5-S1 complications.

Methods

Patients

This retrospective study enrolled a total of 159 patients with ADS who underwent spinal arthrodesis terminating at L5 with lumbar fusion and fixation at a single centre by one spinal deformity surgeon between January 2014 and August 2018. This study followed the principles of the Declaration of Helsinki and was approved by the institutional review board of Beijing Chao-yang Hospital affiliated with China Capital Medical University.

The inclusion criteria were: (1) Cobb angle >10°, (2) posterior procedure only, (3) age greater than 45 years at the time of surgery, (4) surgery segments with pedicle screw instrumentation ≥4, (5) L5 as the lower instrumented vertebra; and (6) a minimum of 2 years of follow-up. The exclusion criteria were (1) previous lumbar surgery history, (2) spinal tumours or inflammation; (3) adolescent idiopathic scoliosis, (4) ankylosing spondylitis, (5) L5-S1 degenerative diseases, and (6) incomplete imaging information, and functional evaluation results. Finally, this study enrolled 112 women and 47 men with a mean age at the first spinal surgery of 61.01 years (47–75 years).

Among the 159 patients, 47 (29.6%) developed L5-S1 segment diseases (the L5-S1 complications group), while 112 (70.4%) did not (the non-L5-S1 complications group). Neurological complications occurred in

24 patients (15.1%) while 40 patients (25.2%) experienced radiographic complications. Clinical data, including age, sex, body mass index (BMI), bone mineral density (BMD), follow-up time, symptom duration, and spinopelvic parameters, were collected as potential predictors of subsequent lumbosacral disc degeneration.

Clinical and radiographic analysis

Data on surgical parameters included the levels of fusion, levels of decompression, intraoperative blood loss, intraoperative time, and osteotomy were collected postoperatively.

Anteroposterior and lateral standing whole-spine X-rays (Philips Digital Diagnost, Zhejiang Province, China) were performed preoperatively to evaluate the patients with ADS. All images were downloaded from picture archiving and communication system (PACS) (DICOM format) and analysed using dedicated software (Surgimap, Nemaris, Inc., New York, USA). Plain radiographs were taken at 180 cm standard distance. Radiological measurements collected before surgery and 1 month after the surgery included the Cobb angle, the distance between the seventh cervical and sacral centre plumb line (C7SC), coronal imbalance, pelvic incidence minus lumbar lordosis (PI-LL), sagittal vertical axis (SVA), sagittal imbalance, L5 tilt, sacral tilt, sacral slope, and L5-S1 range of motion (ROM). Radiographic assessment limited to the L5-S1 segment included: spondylolisthesis, spondylolysis, facet joint degeneration, and disc diseases. All radiographic measurements were performed independently by two spinal surgeons to decrease intra-observer variability.

The clinical outcomes included clinical function score and L5-S1 neurological complications, which were collected preoperatively and the last follow-up after surgery. The clinical outcomes included the Oswestry Disability Index (ODI), Japanese Orthopaedic Association (JOA) score, and Visual Analog Scale (VAS).

Definitions of imbalance

Sagittal imbalance was defined as a horizontal distance from the C7 plumb and posterosuperior corner of the sacrum, >5 cm. Coronal imbalance was defined as a horizontal distance from the C7 plumb and central sacral vertical line >3 cm.

Complications

The baseline patient characteristics and demographics such as age, sex, BMI, BMD, follow-up time, and symptom duration were collected preoperatively. L5-S1 complication data were collected postoperatively and further divided into neurological and radiographical complications. The neurological complication in our study included: radiculopathy, back pain, both leg pain, and cauda equina syndrome. The radiographical complication included spondylolisthesis, spondylolysis, facet joint degeneration, and disc diseases. The disc diseases included disc herniation, disc degeneration, vacuum phenomenon disk, intervertebral space height, and end-plate osteochondritis (Figure 1). To evaluate the relationship between risk factors and L5-S1 complications, the 159 patients were divided into the L5-S1 complications (n = 47) and non-L5-S1 complications (n = 112) groups.

Radiculopathy symptoms or sciatica are likely to result from the compression or inflammation of the L5-S1 segment nerve root. Back pain is always caused by instability of the L5-S1 junction or discogenic pain which is typically associated with disc degeneration disease. Pain in both legs was caused by lumbar spinal stenosis secondary to L5-S1 degenerative hyperplasia of the facet joints or L5 spondylolisthesis after long floating fusion. Cauda equina syndrome may be caused by severe L5-S1 disc herniation or lumbar spondylolisthesis that damages the cauda equina nerve descending from the spinal cord.

Statistical analysis

All data were analysed using SPSS Statistics for Windows, Version 17.0 (SPSS, Inc., Chicago, IL). Continuous variables are presented as means and standard deviation, while categorical variables are presented as frequencies with percentages. Univariate tests were performed using Pearson chi-square or Fisher exact tests as appropriate. The potential predictors of L5-S1 complications were identified among baseline patient characteristics and demographics as well as the surgical parameters. Risk factors with p-value < 0.05 in univariate analysis were identified as potential predictors of L5-S1 complications and included in the multivariate analyses. Multivariate logistic regression was used to determine the independent risk factors for medical complications. P-values < 0.05 were considered statistically significant.

Results

Demographics and operative data

Among the 159 patients with ADS who underwent long-level floating fusion, the mean age of patients at the time of surgery was 61.01 ± 5.59 years and 47 (29.6%) patients were male. The mean BMI, BMD, follow-up time, and symptom duration were 24.11 ± 3.84 kg/m^2, 0.75 ± 1.39, 31.36 ± 10.90 months, and 4.80 ± 1.97 months, respectively. The mean levels of fusion, levels of decompression, intra-operative blood loss, and operative time were 5.47 ± 1.66, 2.68 ± 1.02, 915.60 ± 455.53 mL, and 243.77 ± 49.95 minutes, respectively (Table 1).

Radiological and clinical outcomes

The preoperative Cobb angle, C7SC, coronal imbalance, PI-LL, SVA, sagittal imbalance, L5 tilt, sacral tilt, sacral slope, and L5-S1 ROM were 28.00 ± 12.11°, 29.60 ± 14.72 mm, 57 (35.8%), 30.24 ± 4.94°, 44.72 ± 16.18 mm, 52 (32.7%), 1.89 ± 1.7°, 2.11 ± 1.95°, 40.19 ± 10.83°, and 5.12 ± 1.47°, respectively, while the postoperative values were 7.50 ± 5.97°, 13.49 ± 10.57 mm, 24 (15.1%), 13.69 ± 8.37°, 27.14 ± 18.65 mm, 27 (17.0%), 1.25 ± 1.12°, 1.94 ± 1.44°, 38.79 ± 12.02°, and 5.47 ± 2.10°, respectively.

Comparisons of pre-operative and last follow-up ODI, JOA, and VAS scores between the patients with and without L5-S1 complications showed that patients without L5-S1 complications had similar pre-operative ODI (63.12 ± 2.66 vs. 63.74 ± 2.51, P = 0.725), JOA (5.63 ± 1.27 vs. 5.98 ± 1.31, P = 0.930), VAS (6.71 ± 1.37 vs. 7.36 ± 1.44, P = 0.504), and last follow-up JOA (3.02 ± 1.46 vs. 3.51 ± 1.55, P = 0.422). However,

patients with L5-S1 complications had significant higher ODI score at last follow-up (25.61 ± 8.43 vs. 35.60 ± 12.50, P = 0.000) and VAS (2.79 ± 0.98 vs. 3.49 ± 1.47, P = 0.007) (Table 2).

Summary of L5-S1 complications

A total of 47 (29.6%) patients experienced L5-S1 complications among the 159 patients who underwent ADS correction surgery. Twenty-four (15.1%) and 40 (25.2%) of the 159 patients experienced neurological and radiography complications, respectively. The most frequent neurological complication was L5-S1 back pain, which occurred in 16 (10.1%) patients, followed by six patients (3.8%) with radiculopathy and six patients (3.8%) with leg pain. Only two patients (1.3%) experienced cauda equina with severe neurological symptoms caused by L5-S1 complications. The most frequent radiography complication was disc diseases, which occurred in 25 patients (15.7%), followed by 11 patients (6.9%) with facet joint degeneration, nine patients (5.7%) with spondylolisthesis, and four patients (2.5%) with spondylolysis (Table 3).

Univariate analysis

Potential risk factors for patients with and without L5-S1 complications were identified by univariate analysis (Table 4). For L5-S1 complications, the risk factors included sex (odds ratio [OR] = 0.41, P = 0.016), BMD (OR = 0.42, P = 0.000), follow-up (OR = 1.04, P = 0.025), fusion level (OR = 3.14, P = 0.000), postoperative PI-LL (OR = 1.58, P = 0.000), postoperative SVA (OR 1.10, P = 0.000), postoperative L5 tilt (OR = 1.28, P = 0.012), postoperative sacral slope (OR 1.52, P = 0.000), and postoperative L5-S1 ROM (OR = 1.65, P = 0.000).

Multivariate analysis of patient characteristics

Multivariate logistics regression analysis was used to identify the patient-related independent risk factors of L5-S1 complications. The independent risk factors for the development of L5-S1 complications included sex (OR = 0.41, P = 0.016) and BMD (OR = 0.42, P = 0.000) (Table 5).

Multivariate analysis of surgical variables

Multivariate logistic regression analysis was used to identify the surgical-related independent predictors of L5-S1 complications. Independent factors associated with an increased risk of L5-S1 complications included fusion level (OR = 2.64, P = 0.033) and postoperative sacral slope (OR = 1.43, P = 0.000) (Table 6).

Discussion

Due to the aging population and advancements in medical technologies and surgical techniques, the rate of ADS surgery has increased significantly over the last three decades [10]. Most elderly patients with ADS have mild or severe degenerative diseases at L5-S1. Determination of distal fusion level, whether to save L5-S1 motion segment, remains controversial, especially in patients with long-level lumbar fusion.

Surgical treatment of ADS is challenging for spine surgeons and is associated with a relatively high incidence of L5-S1 disease and the need for revision surgery[7].

Previous studies have mainly focused on instrument-related complications, especially L5-S1 disease requiring revision after long-level floating fusion in patients with ADS. Although according to the spinal deformity questionnaire, both the S1 and L5 cohorts showed good clinical prognosis, the S1 cohort (75%) had a significantly higher complication and revision rates than the L5 cohort (22%), especially for sham joints and diseases [11]. However, fusion to L5 also involves some major complications such as subsequent disc degeneration and sagittal malalignment which occur more frequently (reported incidence rate, 15.91–69% [12]. Therefore, it is necessary to evaluate the independent risk factors for L5-S1 complications in floating fusion for ADS patients.

This study aimed to identify the patient- and surgical-related risk factors for L5-S1 complications in patients with ADS following long fusion arthrodesis to L5. In this study, 47 (29.6%) of the 159 patients who underwent ADS correction surgery with long fusion stopping at L5 experienced L5-S1 complications while 24 (15.1%) experienced neurological complications and 40 (25.2%) experienced radiography complications. Multivariate logistic regression identified sex, BMD, fusion level, and postoperative sacral slope as patient- and surgical- related risk factors for L5-S1 complications after floating fusion in the entire patient population.

Although ADS is an adult degenerative spine disease, female patients comprise the majority of this population, with twice the number of patients compared to men [13]. ADS is more common in postmenopausal women than in men. This may be due to low levels of oestrogen and progesterone, which increase the risk of osteoporosis in postmenopausal women [14]. Previous studies reported a trend for an increased occurrence of ADS in the female population [15]. Our findings showed that, among the patient-related risk factors associated with degeneration of the adjacent segment of the lumbosacral region after floating fusion, male sex was a protective risk factor (OR = 0.41, P = 0.016). Since postmenopausal women contribute to osteoporosis which susceptible to asymmetry degenerative in the lumbosacral region after long floating fusion.

In the present study, osteoporosis with low vertebral BMD was an independent risk factor for L5-S1 complications (OR = 0.42, P = 0.000). Osteoporosis and ADS occur frequently in the elderly population and are often accompanied by reduced BMD [16]. Osteoporosis increases patient susceptibility to the loosening of the distal screws in long floating fusion, which, in turn, leads to lumbar spine instability adjacent to the segment, resulting in low back pain. Moreover, osteoporosis combined with vertebral fractures leads to changes in the anterior, middle, and posterior heights of the vertebral body; thus, subsequent changes in vertebral body height can lead to spinal and vertebral stenoses due to narrowing of the L5-S1 intervertebral space. The foramen stenosis is finally manifested as clinical symptoms of low back pain and lower limb radiation pain.

In the present study, 25 (15.7%) patients with floating fusion surgery experienced L5-S1 disc degeneration, one of the most common L5-S1 complications. Asymmetric degeneration in the

lumbosacral junction should be considered carefully because it is likely to withstand large loads from the trunk, which increases the asymmetric stress load of the L5-S1 intervertebral disc. Because the lumbosacral junction is located at the lower end of the lumbar spine fusion segment, it often experiences excessive biomechanical stress that can lead to a greater load and increased risk of disease in the adjacent segments of the lower vertebrae [17]. The height of the L5-S1 intervertebral disc can be reduced postoperatively, which indicates that the relatively unchanged height of the L5-S1 intervertebral disc can cause a gradual decline and degradation of L5-S1 [18].

Long floating fusion has been reported to be associated with an increased incidence of L5-S1 complications. In our study, the fusion level (OR = 2.64, P = 0.033) was an independent risk factor for L5-S1 complications as it is susceptible to L5-S1 disc degeneration after long-level fusion surgery compared to single-segment or short lumbar fusion. Our findings are consistent with those of the study by Vaccaro et al, in which 78% of patients with postoperative adjacent segment disease had undergone multisegmental fusion surgery (Indications for instrumentation in degenerative lumbar spinal disorders, 2000). In previous studies, the incidence of L5-S1 degenerative diseases ranged from 15–69% after long fusion arthrodesis stopping at L5, with an average follow-up over 5 years. Spine surgeons choose long-segment lumbar spine fusion because ADS patients are typically elderly and usually have rigid scoliosis curves that are difficult to correct. However, long fusion contributes to higher shear stress and increases the risk of disc injury and degradation in the L5-S1 junction.

The increased inclination of the L5-S1 intervertebral disc resulted in a higher incidence of L5-S1 degenerative diseases after long floating fusion in patients with ADS. In the current study, sacral slope (OR = 1.43, P = 0.000) was an independent risk factor for L5-S1 complications. The increased slope or tilt of the intervertebral disc contributed to higher shear stress and risks of disc injury and degradation [19]. Selection of an L5 with high sacral slope (wedged L5 disc) was selected as the lower instrumented vertebra (LIV) in the long floating fusion internal fixation will significantly increase the shear stress on the L5-S1 disc, accelerating the risk of disc injury and degradation. Our findings are consistent with those of previous biomechanical studies reporting that changes in sacral slope lead to changes in the L5-S1 disc shape, which contribute to different biomechanical environments in the lumbosacral spine that may result in different pathomechanisms for the progression of L5 bilateral isthmic spondylolysis to spondylolisthesis[20].

There is no pedicle subtraction osteotomy (PSO) (level 3 or above osteotomy) above the L5-S1 level, and the fusion segment is only from the thoracolumbar junction to L5 is strong enough, there is unnecessary to perform L5-S1 junction fusion. However, if the L5 tilt is not horizontal, the distal end needs to be fused to S1. If the patient has osteoporosis with L3 above the vertebral body for level 3 osteotomy, LIV should choose S1 as possible to avoid osteotomy above level 3 to protect L5-S1 from fusion, we recommend taking multiple segments The Ponte osteotomy replaces Grade 3 osteotomy.

Conclusions

The identification of risk factor analysis for L5-S1 complications improved our ability to predict personal risk conditions to provide better medical optimization for surgery. The results of this study revealed sex, BMD, fusion level, and sacral slope as independent risk factors for L5-S1 complications. Overall, sex and BMD were the most common patient-related independent risk factors for the increased development of individual L5-S1 complications. In contrast, fusion level and sacral slope were the most common surgical-related independent risk factors for the increased the development of individual L5-S1 complications. Our findings provide a reference for spine surgeons to inform patients who are undergoing long floating fusion regarding the risks of secondary L5-S1 complications and clinical outcomes.

Abbreviations

ADS: adult degenerative scoliosis

LIV: lowest instrumented vertebra

C7SC: the distance between the seventh cervical and sacral centre plumb line

PI-LL: pelvic incidence minus lumbar lordosis

SVA: sagittal vertical axis

BMD: bone mineral density

BMI: Body mass index

ODI: Oswestry disability index

JOA: Japanese orthopaedic scores

VAS: visual analogue scale

ROM: range of motion.

SE: standard error

OR: odds ratio

CI: confidence interval

Declarations

Acknowledgments

The authors are thankful for the invaluable support from Beijing Chao-Yang Hospital affiliated with China Capital Medical University.

Funding

This study was partially supported by a research fund provided by the National Natural Science Foundation of China (NSFC) (No. 81772421) and the Beijing Natural Science Foundation (No. L192019).

Availability of data and materials

The datasets used and/or analysed during the current study available from the corresponding author upon reasonable request.

Contributions

(1) Conception and design: All authors (2) Administrative support: Yong Hai (3) Provision of study materials or patients: Tinghua Jiang, Yunzhong Cheng (4) Collection and assembly of data: Xinuo Zhang, Qingjun Su (5) Data analysis and interpretation: Xianglong Meng, Aixing Pan (6) Manuscript writing: All authors (7)Supplement to follow-up information: Hanwen Zhang, Gang Xu. All authors reviewed the manuscript. All authors read and approved the final manuscript.

Ethics approval and consent to participate

This study followed the principles of the Declaration of Helsinki and was approved by the institutional review board of Beijing Chao-yang Hospital affiliated with China Capital Medical University (No.2018-D-125-4). All subjects have signed informed consent.

Consent for publication

Not applicable.

Competing interests

The authors declare that they have no competing interests.

References

1. Schwab FJ, Smith VA, Biserni M, Gamez L, Farcy JP, Pagala M. Adult scoliosis: a quantitative radiographic and clinical analysis. Spine (Phila Pa 1976). 2002;27:387-92. https://doi.org/10.1097/00007632-200202150-00012.
2. Wong E, Altaf F, Oh LJ, Gray RJ. Adult Degenerative Lumbar Scoliosis. Orthopedics. 2017;40:e930-e939. https://doi.org/10.3928/01477447-20170606-02.
3. Zhang XN, Sun XY, Hai Y, Meng XL, Wang YS. Incidence and risk factors for multiple medical complications in adult degenerative scoliosis long-level fusion. J Clin Neurosci 2018;54:14-19. https://doi.org/10.1016/j.jocn.2018.04.070.

4. Zhang XN, Sun XY, Meng XL, Hai Y. Risk factors for medical complications after long-level internal fixation in the treatment of adult degenerative scoliosis. Int Orthop 2018;42:2603-2612. https://doi.org/10.1007/s00264-018-3927-6.
5. Mendoza-Lattes S, Ries Z, Gao Y, Weinstein SL. Natural history of spinopelvic alignment differs from symptomatic deformity of the spine. Spine (Phila Pa 1976). 2010;35:E792-8. https://doi.org/10.1097/BRS.0b013e3181d35ca9.
6. Lee CH, Chung CK, Sohn MJ, Kim CH. Short Limited Fusion Versus Long Fusion With Deformity Correction for Spinal Stenosis With Balanced De Novo Degenerative Lumbar Scoliosis: A Meta-analysis of Direct Comparative Studies. Spine (Phila Pa 1976). 2017;42:E1126-E1132. https://doi.org/10.1097/BRS.0000000000002306.
7. Phan K, Xu J, Maharaj MM, Li J, Kim JS, Di Capua J, et al. Outcomes of Short Fusion versus Long Fusion for Adult Degenerative Scoliosis: A Systematic Review and Meta-analysis. Orthop Surg. 2017;9:342-349. https://doi.org/10.1111/os.12357.
8. Cho KJ, Suk SI, Park SR, Kim JH, Choi SW, Yoon YH, et al. Arthrodesis to L5 versus S1 in long instrumentation and fusion for degenerative lumbar scoliosis. Eur Spine J.2009;18:531-7. https://doi.org/10.1007/s00586-009-0883-2.
9. Yan C, Gao X, Sun Y, Dong Z, Shen Y. The preoperative predictors for subsequent degeneration in L5-S1 disc after long fusion arthrodesis terminating at L5 in patients with adult scoliosis: focus on spinopelvic parameters. J Orthop Surg Res.2018;13:285. https://doi.org/10.1186/s13018-018-0987-7.
10. Gao X, Wang L, Zhang J, Wang P, Shen Y. Long Fusion Arthrodesis Stopping at L5 for Adult Scoliosis: Fate of L5-S1 Disk and Risk Factors for Subsequent Disk Degeneration. Clin Spine Surg.2018;31:E171-E177. https://doi.org/10.1097/BSD.0000000000000624.
11. Bao H, Zhu F, Liu Z, Zhu Z, He S, Ding Y, et al. Coronal curvature and spinal imbalance in degenerative lumbar scoliosis: disc degeneration is associated. Spine (Phila1976).2014;39:E1441-7. https://doi.org/10.1097/BRS.0000000000000603.
12. Cho KJ, Suk SI, Park SR, Kim JH, Kang SB, Kim HS, et al. Risk factors of sagittal decompensation after long posterior instrumentation and fusion for degenerative lumbar scoliosis. Spine (Phila Pa 1976).2010;35:1595-601. https://doi.org/10.1097/BRS.0b013e3181bdad89.
13. Sardar ZM, Ouellet JA, Fischer DJ, Skelly AC. Outcomes in adult scoliosis patients who undergo spinal fusion stopping at L5 compared with extension to the sacrum. Evid Based Spine Care J.2013; 4:96-104. https://doi.org/10.1055/s-0033-1357360.
14. Sciubba DM, Yurter A, Smith JS, Kelly MP, Scheer JK, Goodwin CR, et al. A Comprehensive Review of Complication Rates After Surgery for Adult Deformity: A Reference for Informed Consent. Spine Deform.2015;3:575-594. https://doi.org/10.1016/j.jspd.2015.04.005.
15. Bridwell KH, Edwards CC 2nd, Lenke LG. The pros and cons to saving the L5-S1 motion segment in a long scoliosis fusion construct. Spine (Phila Pa 1976). 2003;28:S234-42. https://doi.org/10.1097/01.BRS.0000092462.45111.27.

16. Kuhns CA, Bridwell KH, Lenke LG, Amor C, Lehman RA, Buchowski JM, et al. Thoracolumbar deformity arthrodesis stopping at L5: fate of the L5-S1 disc, minimum 5-year follow-up. Spine (Phila Pa 1976).2007;32:2771-6. https://doi.org/10.1097/BRS.0b013e31815a7ece.
17. Kim YJ, Bridwell KH, Lenke LG, Cho KJ, Edwards CC 2nd, Rinella AS. Pseudarthrosis in adult spinal deformity following multisegmental instrumentation and arthrodesis. J Bone Joint Surg Am.2006;88:721-8. https://doi.org/10.2106/JBJS.E.00550.
18. Gao X, Wang L, Yan C, Gao Y, Shen Y. Predictors of Deterioration in Sagittal Balance Following Long Fusion Arthrodesis to L5 in Patients with Adult Scoliosis. Med Sci Monit. 2018;24:919-927. https://doi.org/10.12659/msm.908155.
19. Lee JS, Shin JK, Goh TS. Interleukin 6 gene polymorphism in patients with degenerative lumbar scoliosis: a cohort study. Eur Spine J. 2018;27:607-612. https://doi.org/10.1007/s00586-017-5074-y.
20. Wang C, Chang H, Gao X, Xu J, Meng X. Risk factors of degenerative lumbar scoliosis in patients with lumbar spinal canal stenosis. Medicine (Baltimore). 2019; 98:e17177. https://doi.org/10.1097/MD.0000000000017177.
21. Matsumura A, Namikawa T, Terai H, Tsujio T, Suzuki A, Dozono S, et al. The influence of approach side on facet preservation in microscopic bilateral decompression via a unilateral approach for degenerative lumbar scoliosis. J Neurosurg Spine. 2010;13:758-65. https://doi.org/10.3171/2010.5.SPINE091001.
22. Hashimoto K, Aizawa T, Kanno H, Itoi E. Adjacent segment degeneration after fusion spinal surgery-a systematic review. Int Orthop. 2019; 43:987-993. https://doi.org/10.1007/s00264-018-4241-z.
23. Cho KJ, Suk SI, Park SR, Kim JH, Kim SS, Lee TJ, et al. Short fusion versus long fusion for degenerative lumbar scoliosis. Eur Spine J. 2008;17:650-6. https://doi.org/10.1007/s00586-008-0615-z.
24. Orita S, Yamagata M, Ikeda Y, Nakajima F, Aoki Y, Nakamura J, et al. Retrospective exploration of risk factors for L5 radiculopathy following lumbar floating fusion surgery. J Orthop Surg Res. 2015;10:164. https://doi.org/10.1186/s13018-015-0307-4.
25. Du CZ, Li S, Xu L, Zhou QS, Zhu ZZ, Sun X, et al. Sagittal reconstruction of lumbosacral contiguous double-level spondylolytic spondylolisthesis: a comparison of double-level and single-level transforaminal lumbar interbody fusion. J Orthop Surg Res. 2019;14:148. https://doi.org/10.1186/s13018-019-1197-7.
26. Ramakrishna VAS, Chamoli U, Viglione LL, Tsafnat N, Diwan AD.The Role of Sacral Slope in the Progression of a Bilateral Spondylolytic Defect at L5 to Spondylolisthesis: A Biomechanical Investigation Using Finite Element Analysis. Global Spine J. 2018;8:460-470. https://doi.org/10.1177/2192568217735802.

Tables

Table 1

Patient demographics.

Characteristic	Total (n=159)	L5-S1 disease (n=112)	non L5-S1 disease (n=47)	P value
Age (y/o)	61.01 ± 5.59	60.33 ± 5.76	62.64 ± 4.85	0.338
Sex (male %)	47 (29.6%)	33 (29.8%)	14 (8.8%)	0.015
BMI (kg/m2)	24.11 ± 3.84	22.56 ± 3.02	27.81 ± 2.96	0.858
BMD	-0.75 ± 1.39	-0.39 ± 1.37	-1.62 ± 1.01	0.003
Follow-up (mo)	31.36 ± 10.90	30.04 ± 9.86	34.51 ± 12.60	0.015
Symptom duration (mo)	4.80 ± 1.97	4.12 ± 1.58	6.40 ± 1.88	0.184
Levels of fusion (n)	5.47 ± 1.66	4.73 ± 0.97	7.21 ± 1.64	0.000
Level of decompression (n)	2.68 ± 1.02	2.40 ± 0.89	3.34 ± 1.03	0.309
Intraoperative blood loss (ml)	915.60 ± 455.53	856.61 ± 436.35	1056.17 ± 473.94	0.101
Operative time (min)	243.77 ± 49.95	237.59 ± 46.54	258.51 ± 55.04	0.201
Osteotomy (n %)	22 (13.8%)	12 (7.5%)	10 (6.3%)	0.078
Preoperative ODI (%)	63.30 ± 2.62	63.12 ± 2.66	63.74 ± 2.51	0.725
ODI at last follow-up (%)	28.56 ± 10.78	25.61 ± 8.43	35.60 ± 12.50	0.000
Preoperative JOA	5.74 ± 1.29	5.63 ± 1.27	5.98 ± 1.31	0.930
JOA at last follow-up	3.16 ± 1.50	3.02 ± 1.46	3.51 ± 1.55	0.422
Preoperative VAS	6.90 ± 1.42	6.71 ± 1.37	7.36 ± 1.44	0.504
VAS at last follow-up	3.00 ± 1.19	2.79 ± 0.98	3.49 ± 1.47	0.007

y/o, years old; BMI, Body mass index; BMD, bone mineral density; L5-S1, the segment from fifth lumbar vertebra to first sacral vertebra; ODI, Oswestry disability index; JOA, Japanese orthopaedic scores; VAS, visual analogue scale. Values are expressed as the mean±standard deviation or number.

Table 2

Radiographic parameters between with and without L5-S1 complications groups.

Characteristic	Total (n=159)	L5-S1 disease (n=112)	Non-L5-S1 disease (n=47)	P value
Preoperative Cobb (°)	28.00 ± 12.11	27.21 ± 12.32	29.87 ± 11.48	0.702
Postoperative Cobb (°)	7.50 ± 5.97	5.91 ± 5.64	11.30 ± 4.97	0.100
Preoperative C7SC (mm)	29.60 ± 14.72	25.55 ± 12.89	39.26 ± 14.44	0.138
Postoperative C7SC (mm)	13.49 ± 10.57	12.45 ± 10.07	15.98 ± 11.42	0.113
Preoperative coronal imbalance (n %)	57 (35.8%)	36 (22.6%)	21 (13.2%)	0.132
Postoperative coronal imbalance (n %)	24 (15.1%)	14 (8.8%)	10 (6.3%)	0.158
Preoperative PI-LL (°)	30.24 ± 4.94	30.20 ± 4.37	30.06 ± 5.91	0.035
Postoperative PI-LL (°)	13.69 ± 8.37	9.57 ± 4.27	23.51 ± 7.55	0.000
Preoperative SVA (mm)	44.72 ± 16.18	39.40 ± 13.50	57.40 ± 15.05	0.661
Postoperative SVA (mm)	27.14 ± 18.65	20.92 ± 17.31	43.38 ±8.84	0.000
Preoperative sagittal imbalance (n %)	52 (32.7%)	32 (20.1%)	20 (12.6%)	0.086
Postoperative sagittal imbalance (n %)	27 (17.0%)	15 (9.4%)	12 (7.5%)	0.063
Preoperative L5 tilt (°)	1.89 ± 1.77	1.66 ± 1.53	2.45 ± 2.14	0.000
Postoperative L5 tilt (°)	1.25 ± 1.12	1.06 ± 1.04	1.69 ± 1.18	0.203
Preoperative sacral tilt (°)	2.11 ± 1.95	1.57 ± 1.86	3.40 ± 1.52	0.101
Postoperative sacral tilt (°)	1.94 ± 1.44	1.67 ± 1.28	2.57 ± 1.62	0.068
Preoperative sacral slope (°)	40.19 ± 10.83	35.69 ± 7.97	50.91 ± 9.08	0.280
Postoperative sacral slope (°)	38.79 ±	32.48 ± 7.89	53.83 ± 4.27	0.000

	12.02			
Preoperative L5-S1 ROM (°)	5.12 ± 1.47	4.86 ± 1.29	5.76 ± 1.69	0.270
Postoperative L5-S1 ROM (°)	5.47 ± 2.10	4.85 ± 1.36	6.94 ± 2.76	0.000
C7SC, distance between the seventh cervical and sacral centre plumb line; PI-LL, pelvic incidence minus lumbar lordosis; SVA, sagittal vertical axis; ROM, range of motion. Values are expressed as the mean±standard deviation or number.				

Table 3

Summary of L5-S1 complications.

Type	Complications	Number of cases (n%)
Neurological		24 (15.1)
	Radiculopathy	6 (3.8%)
	Back pain	16 (10.1%)
	Both leg pain	6 (3.8%)
	Cauda equina syndrome	2 (1.3%)
Radiographical		40 (25.2)
	Spondylolisthesis	9 (5.7%)
	Spondylolysis	4 (2.5%)
	Facet joint degeneration	11 (6.9%)
	Disc herniation	25 (15.7%)
% Percentage listed in parentheses.		

Table 4

Univariate analysis of baseline patient characteristics.

Variables	B	SE	Wald	df	P value	OR	95% CI for EXP(B)	
							Lower	Upper
Patient-related								
Sex (male %)	-0.893	0.371	5.804	1	0.016	0.409	0.198	0.847
BMD	-0.871	0.189	21.317	1	0.000	0.418	0.289	0.606
Follow-up	0.035	0.016	4.998	1	0.025	1.036	1.004	1.068
Surgical-related								
Levels of fusion	1.143	0.166	47.675	1	0.000	3.136	2.267	4.337
Preoperative PI-LL	-0.001	0.035	0.001	1	0.972	0.999	0.932	1.07
Postoperative PI-LL	0.456	0.082	30.833	1	0.000	1.578	1.343	1.854
Postoperative SVA	0.097	0.017	34.356	1	0.000	1.102	1.067	1.138
Preoperative L5 tilt	0.244	0.097	6.297	1	0.012	1.276	1.055	1.543
Postoperative sacral slope	0.415	0.077	29.127	1	0.000	1.515	1.303	1.761
Postoperative L5-S1 ROM	0.502	0.100	25.440	1	0.000	1.652	1.359	2.008

A P value of 0.05 represents the threshold for statistical significance

SE, standard error; OR, odds ratio; CI, confidence interval; BMD, bone mineral density; L5-S1, the segment from fifth lumbar vertebra to the first sacral vertebra; PI-LL, pelvic incidence minus lumbar lordosis; SVA, sagittal vertical axis; ROM, range of motion
*P < 0.05

Table 5

Multivariate logistic regression model of patient characteristics.

Variables	B	SE	Wald	df	P value	OR	95% CI for EXP(B)	
							Lower	Upper
Sex	0.931	0.413	5.092	1	0.024	2.538	1.13	5.698
BMD	-0.868	0.193	20.269	1	0.000	0.420	0.288	0.613
Follow up	0.035	0.018	3.645	1	0.056	1.036	0.999	1.074

A P value of 0.05 represents the threshold for statistical significance

SE, standard error; OR, odds ratio; CI; confidence interval; BMD, bone mineral density
*P < 0.05

Table 6

Multivariate logistic regression model of surgical variables.

Variables	B	SE	Wald	df	P value	OR	95% CI for EXP(B)	
							Lower	Upper
Level of fusion	0.971	0.456	4.546	1	0.033	2.641	1.082	6.45
Postoperative PI-LL	0.034	0.062	0.300	1	0.584	1.035	0.916	1.169
Postoperative SVA	0.064	0.038	2.853	1	0.091	1.066	0.99	1.147
Postoperative sacral slope	0.360	0.099	13.320	1	0.000	1.434	1.181	1.739
Preoperative L5 tilt	-0.050	0.306	0.026	1	0.871	0.952	0.523	1.732
Postoperative L5-S1 ROM	0.531	0.330	2.588	1	0.108	1.700	0.891	3.244

A P value of 0.05 represents the threshold for statistical significance

SE, standard error; OR, odds ratio; CI, confidence interval; PI-LL, pelvic incidence minus lumbar lordosis; SVA, sagittal vertical axis; ROM, range of motion
*P < 0.05

Figures

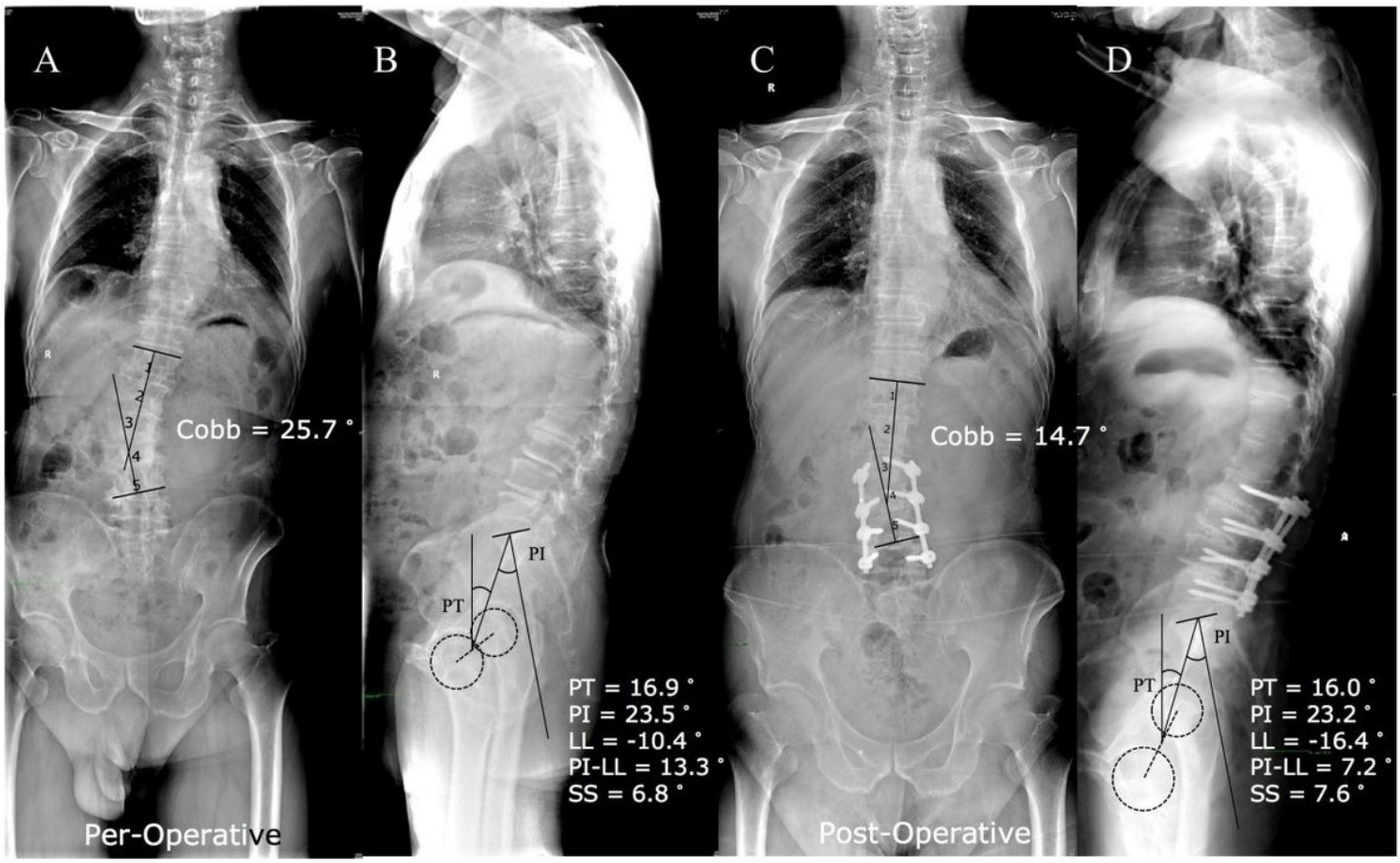

Figure 1

Male patient, 78 years old, with back pain accompanied by intermittent claudication for 10 years that had worsened for 1 year, Diagnosis: LSS and ADS. Two years after the operation, the coronal balance and Cobb angle remained in good alignment but L5-S1 junction is unstable in the sagittal plane.