Endoscopic submucosal dissection for treatment of stromal tumor of descending duodenum in association with postoperative perforation and retroperitoneal abscess: a case report

Wei Wei
Zigong First People's Hospital
Hang Gong (343311398@qq.com)
Zigong First People's Hospital https://orcid.org/0000-0001-5985-1254
Zhong Huang
Zigong First People's Hospital
Tingyu Wang
Zigong First People's Hospital
Xinlian Chen
Zigong First People's Hospital

Case report

Keywords: Endoscopic submucosal dissection, Gastrointestinal stromal tumors, GISTs, Duodenum, Case report

Posted Date: August 12th, 2020

DOI: https://doi.org/10.21203/rs.3.rs-56050/v1

Abstract

Background: With the development of endoscopic technology, the clinical detection rates of duodenal lesions have been significantly increased. Endoscopic submucosal dissection (ESD) has been increasingly applied to the minimally invasive treatment of duodenal space-occupying lesions and has similar therapeutic effects as surgery. However, postoperative complications such as perforation and bleeding easily occur after ESD, but there were few reports about it. We report a case, which we designed to evaluate the efficacy and safety of ESD treatment for stromal tumor in descending duodenum.

Case presentation: A 64-year-old woman suffered from duodenal fistula and retroperitoneal abscess after ESD for stromal tumor in descending duodenum. The purse-string suture therapy of the wound was not very effective for the patient during the operation. Thus, the patient underwent a series of treatment measures successfully, such as endoscopic jejunum feeding tube placement, anti-infection, endoscopic closure of duodenal fistula, etc, and without evidence of perforation of duodenum. Follow-up was done for 6 months without recurrence.

Conclusions: ESD is a efficient and promising strategy for treating of stromal tumor in descending duodenum, while the ESD of security needs to be further evaluated.

Background

Gastrointestinal stromal tumors (GISTs) are the most usual mesenchymal tumors of the alimentary canal, and stromal tumors were often referred to as “smooth muscle-derived tumors” or “schwannomas” until the diagnosis of GISTs was first put forward by Mazur and Clark in 1983 [1].With the further understanding of the pathological features and malignant potential of stromal tumors, especially the discovery of the gene mutation of c-kit and PDGFRA, and the expression of CD117, thus the diagnosis of stromal tumors was further clarified [2-3]. GISTs could occur in the gastrointestinal tract from the esophagus to the anus, mostly stomach (50% to 60%), only 3%~5% of mesenchymal tumors occur in the duodenum [4]. The symptoms and physical signs of the patients with GISTs are closely related with the size, location and growth pattern of the tumor, thereinto the most common symptoms are gastrointestinal bleeding (including melena, hematemesis and anemia) due to the mucosal ulceration of tumor. In addition, more nonspecific symptoms contain nausea, vomiting, stomachache, et al. Although the occurence rate of duodenum stromal tumors is extremely low, its special anatomic location brings great challenge to surgery, and what's more, there was a literature reported that the malignant degree of duodenum stromal tumor is higher than other parts of gastrointestinal tract [5]. In recent years, with the rapid development of digestive endoscopy technology, ESD brings about a viable option for the treatment of duodenal stromal tumors. However, there are few reports on ESD therapy for duodenal stromal tumors, one reason is the extremely low incidence of duodenal stromal tumors, the other is that the special anatomical location of the duodenum makes ESD therapy more risky, and the main complications include bleeding, perforation and pancreatitis [6]. We should evaluate the effectiveness and safety of ESD for the treatment of stromal tumor of duodenum. In this paper, we report a case of ESD for the treatment

of stromal tumor of descending duodenum in association with postoperative perforation and abdominal infection.

Case Presentation

A 64-year-old woman presented to our department complained of repeated melena with persistent right upper quadrant pain for 5 months. Esophagogastroduodenoscopy (EGD) showed a submucosal eminence about 2.0 cm in size at the descending duodenum, with a deep ulcer on the tip and a little bleeding (Fig. 1). Endoscopic ultrasonography indicated that the hypoechoic space occupying lesion from the muscularis propria, with the maximum cross sectional value of 1.91 × 1.53 cm (Fig. 2). Similarly, computed tomography (CT) scan of abdomen showed local thickening of the descending duodenum (Fig. 3a, b). We achieved en bloc resection by ESD with intraoperative perforation. During the operation, we attempted local submucosal injection of mixed solutions [a mixture of diluted epinephrine with normal saline (1:10,000), sodium hyaluronate, glycerol fructose and methylene blue] and no significant lifting sign was observed. Therefore, ESD was performed with HybridKnife and ITKnife, the submucosal tumor was confirmed to originate from muscularis propria and protrude outward from the lumen (Fig. 4), then the primary outcome was en bloc resection of the lesion (Fig. 5). The resected lesion size was 2.0 × 2.5 cm (Fig. 6). But, there was intraoperative perforation during ESD, with 2.5 cm in diam (Fig. 7), and the wound surface was ultimately closed by purse-string suture using nylon rope and titanium clips without adverse events (Fig. 8). So, ESD for the treatment of duodenal stromal tumor is very feasible and promising, but several safety issues need further evaluation. The post-ESD pathological analysis was GISTs (risk assessment grade: low), and immunohistochemistry and histochemistry staining showed P-CK - , Vim + , CD34 - , CD117 + , Dog-1 + , S100 - , SMA - , Ki67 (+, 10%) , which was further consistent with the above diagnosis (Fig. 9). To assess the presence of delayed perforation, abdominal CT scan performed after postoperative a few days revealed that there was no evidence of postoperative perforation. However, the patient developed fever 1 month after discharge from hospital, with the maximum body temperature value of 38.5 degree centigrade. Eventually, the patient was again admitted to our department for endoscopic evaluation and therapy, considering the possibility of severe intra-abdominal infection. Abdominal CT scan showed retroperitoneal abscess in the right lower quadrant of the abdomen (Fig. 10), and EGD showed fistula of duodenum (Fig. 11). Next, the patient underwent endoscopic jejunum feeding tube placement, percutaneous drainage of retroperitoneal abscess under real-time CT guidance and anti-infection for treatment (Fig. 12). More importantly, we performed endoscopic closure of duodenal fistula and percutaneous endoscopic gastrostomy (Fig. 13). Finally, the symptoms improved and without complications such as fever, perforation, bleeding. We followed up the patient for 3 months and there was no recurrence of perforation and infection. The last abdominal CT scan demonstrated absent abscess in the right lower retroperitoneal space (Fig. 14), EGD and digestive tract radiography showed there was no longer evidence of perforation of duodenum (Fig. 15). Long-term follow-up is ongoing.

Discussion

Over 60% of small intestinal tumors are found in the duodenum, and the most frequent malignancies of the duodenum include GISTs, neuroendocrine neoplasm, adenocarcinoma, lymphoma, sarcoma, teratoma, and secondary metastases [2]. GISTs is the most common submucosal tumours of gastrointestinal tract, which originate from connective tissue, muscle, lymphoid tissue, adipose tissue, nerves and blood vessels located below the submucosa [7]. GISTs can be probably classified as unfavourable prognosis when they are more than 5 cm, occuring tumor rupture and the mitotic rate is more than 5 mitoses per 50 high-power fields [8]. Study has shown that adequate endoscopic treatment strategies of GISTs could lead to favorable outcomes and good prognosis [9]. ESD has been established as a curable safe procedure for the treatment of tumours on the surface of the stomach, esophagus, and colon, while most endoscopic strategies for the resection of duodenal tumours remain undefined [9]. With the rapid development and continuous maturity of endoscopic therapy, the incidence of complications have received widespread attention during the perioperative period. The complications of ESD include bleeding, perforation (about 30%), and pancreatitis [10-11]. Shi et al. [12] reported a novel “endoscopic interrupted suture——purse-string suture”, which combined the traditional nylon rope and titanium clips for closure of operative wound, and was widely used to repair iatrogenic perforation or active perforation during ESD. In our case, the patient with recurrent upper gastrointestinal bleeding followed a comprehensive examination, so the diagnosis of stromal tumor in descending duodenum with bleeding was considered. ESD or abdominal surgery was selected as the operative method, ESD was performed in accordance with the wishes of the patient after full communication with the patient in the end. It is necessary to evaluate the depth of tumors infiltration by endoscopic ultrasonography and CT before ESD, because 30% to 40% of GISTs grow outwards, 29% to 44% of GISTs in intramural growth, 18% to 22% in endoluminal growth, 16% to 20% in mixed growth [13]. The preoperative CT indicated that the tumor body was significantly outward from the lumen, and thus iatrogenic perforation could be foreseeable during ESD. Therefore, we already communicated adequately with the patient about the possible complications and prognosis before ESD. Not surprisingly, the postoperative pathology confirmed the diagnosis of descending duodenal stromal tumor. We applied improved purse-string suture technique to close perforated wound of descending duodenum, but there were few reports about it in the world. Unfortunately, follow-up to 1 month suggested that delayed perforation and abdominal infection occurred. This may be related to the personal factors and immature purse-string suture technique, which was rarely used in the duodenum. Besides, the risk of complications with ESD resection of nonampullary duodenal tumours is higher compared to tumours in other digestive tracts because of thinner intestinal wall and existence of duodenal fluid containing abundant digestive enzymes. Especially in the posterior wall of duodenum, the gas may pass through the exposed thin muscularis propria into the retroperitoneum during treatment, even if there is no obvious sign of perforation [14]. On the other hand, because the position of the descending duodenum is relatively fixed, it is difficult to gather relatively fixed mucosa together, and even if the wound is successfully closed by titanium clips, its effect is not as obvious as that of other parts of gastrointestinal tract [15]. But it did not significantly affect the prognosis of the patient. The remedial treatment of duodenal fistula after closure of ESD-related perforation is still unclear. Because the lesion which gave rise to serious retroperitoneal abscess was located in the descending duodenum, gastrointestinal surgeon and hepatobiliary surgeon considered that surgical

treatment was very difficult and risky. After multidisciplinary discussions, We determined to carry through a series of treatments mentioned in the case presentation. Thereinto, it is very necessary to place abscess drainage tube under the guidance of CT, which can obviously relieve the systemic and local symptoms caused by pus. Finally, all the symptoms improved markedly. Follow-up was done for 6 months without recurrence.

Although there were few reports about the application of ESD and purse-string suture for stromal tumors in descending duodenum, they are a promising mean of minimally invasive treatment. Endoscopic therapies effectively could avoid most traditional surgical procedures, relieve the suffering of the patients, shorten hospital stay, and improve the medical therapy efficiency. There are some experiences that are summarized as follows: (1) Preoperative CT and endoscopic ultrasonography can help us to preliminarily understand the depth of tumor invasion and provide a reference for the depth of resection during the operation. (2) Intraoperative perforation is a common complication of ESD for treatment of duodenal lesions. So, we recommend experienced doctors to manage ESD. More attention should be paid to the purse-string suture of the perforated wound. (3) Due to the abundant blood supply of the duodenum, intraoperative and postoperative hemorrhage are more possible to happen, although it did not occur in this patient. After endoscopic resection, the exposed blood vessels of the wound should be carefully searched and coagulated. (4) Observing postoperative complications closely, such as bleeding, perforation, fever, and pancreatitis. (5) If serious complications occur, multidisciplinary discussions should be conducted for further treatment.

Conclusions

In conclusion, ESD is a feasible and promising therapy for the treatment of stromal tumor in descending duodenum. ESD is possible to achieve curative treatment of duodenal lesions and obtain complete pathological specimens, but more studies are needed to confirm the safety of ESD. Preoperative indications should be mastered, and manage carefully in the operation to avoid bleeding and perforation. In the future, with the improvement and experience accumulation of endoscopic treatment techniques, the success rates of ESD treatment for duodenal lesions will be improved continuously.

Abbreviations

ESD: endoscopic submucosal dissection; GISTs: Gastrointestinal stromal tumors; EGD: Esophagogastroduodenoscopy; CT: computed tomography

Declarations

Acknowledgements

We appreciate the contributions of all the doctors, coworkers, and friends involved in this study and thank the editors and reviewers for their help with this manuscript.

Funding

No funding was received specifically for this study.

Availability of data and materials

The datasets used and/or analyzed during the current study are available from the corresponding author on reasonable request.

Ethics approval and consent to participate

Written consent for participation was obtained. No ethics approval was required.

Consent for publication

Written consent for publication of images and necessary data was obtained.

Authors' contributions

WW and HG conceived of the study, designed it, and acquired the data. HG participated in the design of the study, coordination, and analysis of the data. WW and HG drafted the manuscript. ZH, TW, and XC participated in the manuscript preparation and critical revision. All authors read and approved the manuscript.

Competing interests

The authors declare that they have no competing interests.

References

1. Mazur MT, Clark HB. Gastric stromal tumors. Reappraisal ofhistogenesis. Am J Surg Pathol. 1983; 7: 507-19.
2. Domenech-Ximenos B, Juanpere S, Serra I, Codina J, Maroto A. Duodenal tumors on cross-sectional imaging with emphasis on multidetector computed tomography: a pictorial review. Diagn Interv Radiol. 2020;26:193-199.
3. Yang WL, Yu JR, Wu YJ, et al. Duodenal gastrointestinal stromal tumor: clinical, pathologic, immunohistochemical characteristics, and surgical prognosis. J Surg Oncol. 2009; 100:606-610.
4. Crown A, Biehl TR, Rocha FG. Local resection for duodenal gastrointestinal stromal tumors. Am J Surg. 2016; 211:867-870.
5. Dusunceli Atman E, Erden A, Ustuner E, Uzun C, Bektas M. MRI Findings of intrinsic and extrinsic duodenal abnormalities and variations. Korean J Radiol. 2015; 16:1240–1252
6. Chen WC, Wallace MB. Endoscopic management of mucosal lesions in the gastrointestinal tract. Expert Rev Gastroenterol Hepatol. 2016;10:481-495.

7. Latos W, Kawczyk-Krupka A, Strzelczyk N, Sieroń A, Cieślar G. Benign and non-neoplastic tumours of the duodenum. Prz Gastroenterol. 2019;14:233-241.
8. Sakamoto Y, Yamamoto J, Takahashi H, et al. Segmental resection of the third portion of the duodenum for a gastrointestinal stromal tumor: a case report. Jpn J Clin Oncol. 2003;33:364-366.
9. Hoteya S, Furuhata T, Takahito T, et al. Endoscopic Submucosal Dissection and Endoscopic Mucosal Resection for Non-Ampullary Superficial Duodenal Tumor. Digestion. 2017;95:36-42.
10. Moussata D, Napoleon B, Lepilliez V, et al. Endoscopic treatment of severe duodenal polyposis as an alternative to surgery for patients with familial adenomatous polyposis. Gastrointest Endosc. 2014;80:817-825.
11. Musumba C, Sonson R, Tutticci N, Nanda K, Bourke MJ. Endoscopic submucosal dissection of a duodenal neuroendocrine tumor. Gastrointest Endosc. 2014; 79: 716.
12. Shi Q, Chen T, Zhong YS, et al. Complete closure of large gastric defects after endoscopic full-thickness resection, using endoloop and metallic clip interrupted suture. Endoscopy. 2013;45:329-334.
13. Oh JY, Nam KJ, Choi JC, et al. Benign submucosal lesions of the stomach and duodenum: imaging characteristics with endoscopic and pathologic correlation. Eur J Radiol. 2008; 67:112–124.
14. Yamamoto H, Miura Y. Duodenal ESD: conquering difficulties. Gastrointest Endosc Clin N Am. 2014;24:235-244.
15. Bourke MJ. Endoscopic resection in the duodenum: current limitations and future directions. Endoscopy. 2013;45:127-132.

Figures

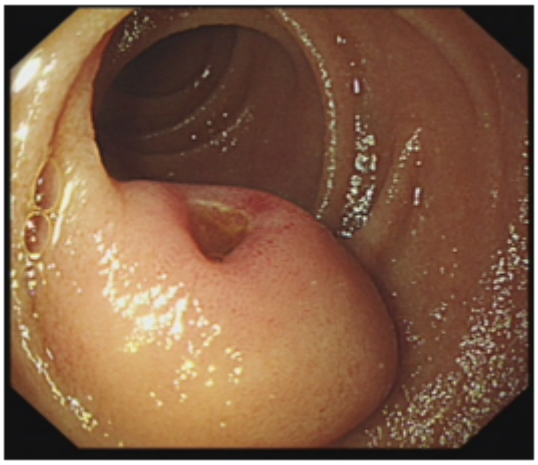

Figure 1

EGD showing submucosal tumour of the descending duodenum.

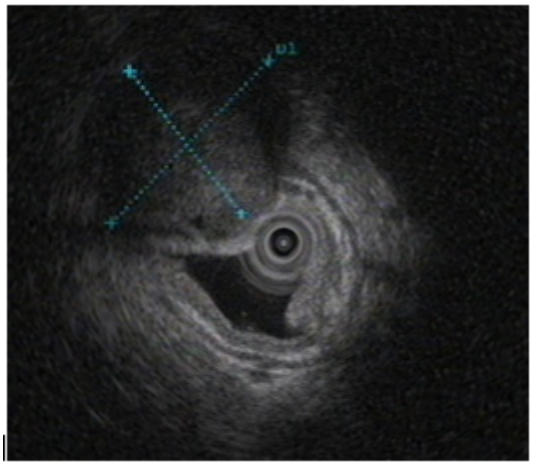

Figure 2

Endoscopic ultrasonography showing the hypoechoic space-occupying lesion from the muscularis propria .

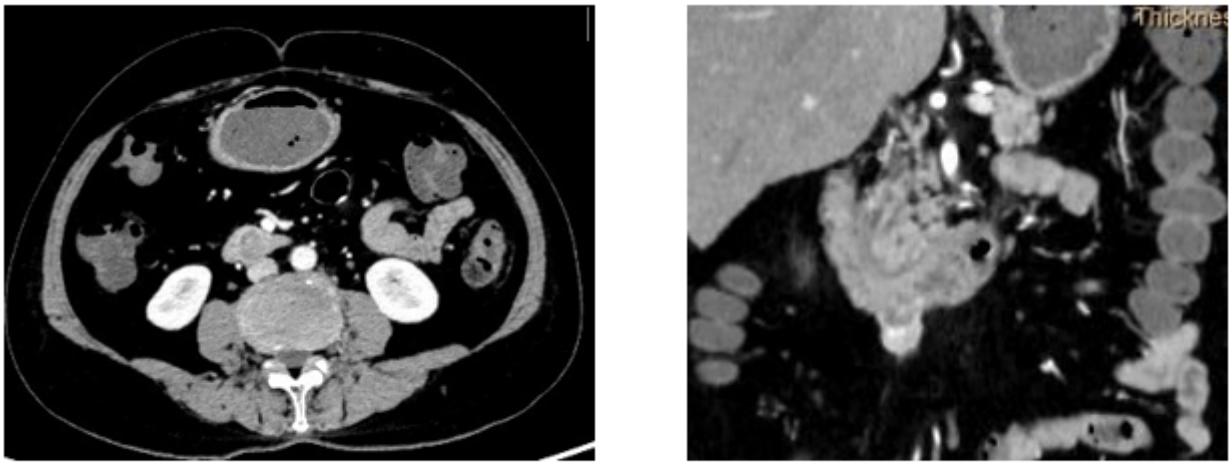

Figure 3

CT showing lump of the descending duodenum.

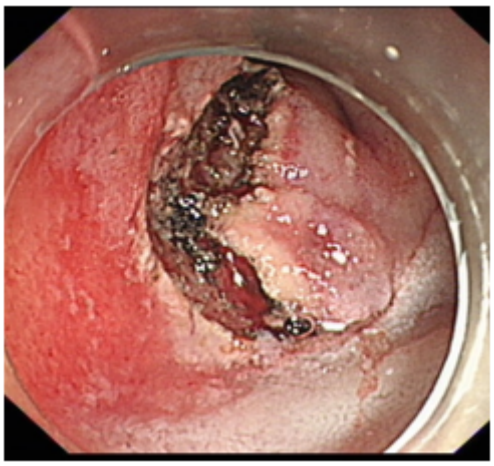

Figure 4

Used the HybridKnife and ITKnife to perform ESD, and the duodenal wall is being incised.

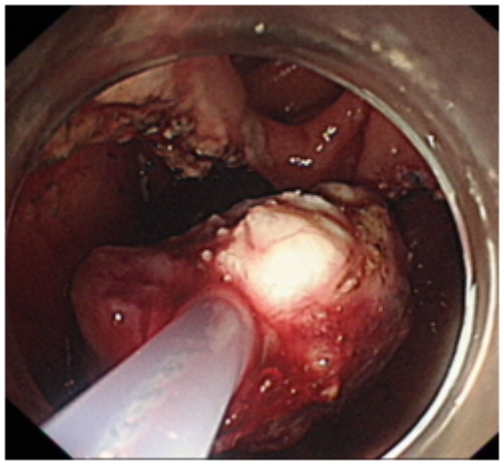

Figure 5

En-bloc resection of lesions by ESD.

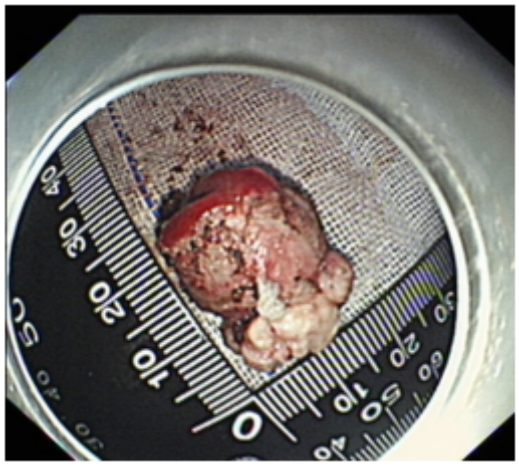

Figure 6

The resected lesion size was 2.0 × 2.5 cm.

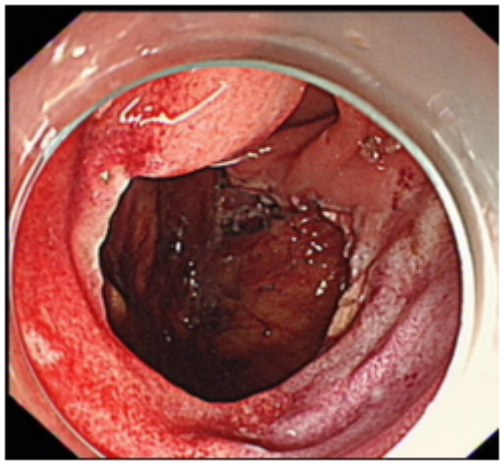

Figure 7

There was intraoperative perforation during ESD, with 2.5 cm in diam.

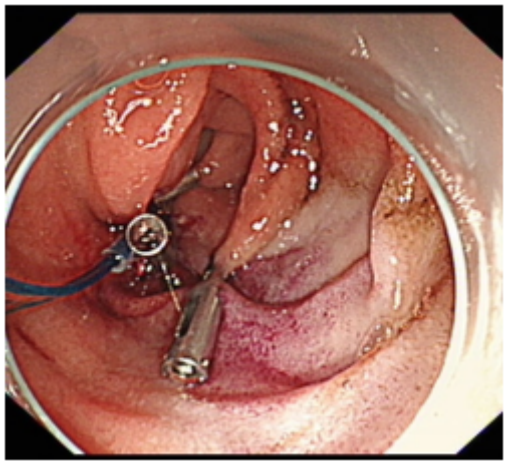

Figure 8

The perforated wound was closed by purse-string suture using nylon rope and titanium clips.

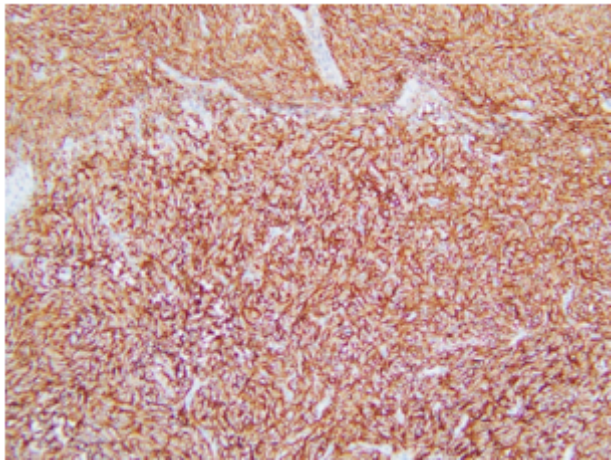

Figure 9

The post-ESD pathological analysis indicated GISTs.

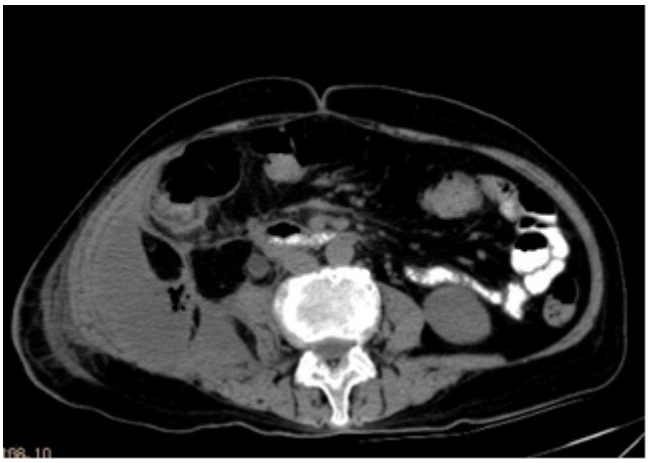

Figure 10

CT showing retroperitoneal abscess in the right lower quadrant of the abdomen.

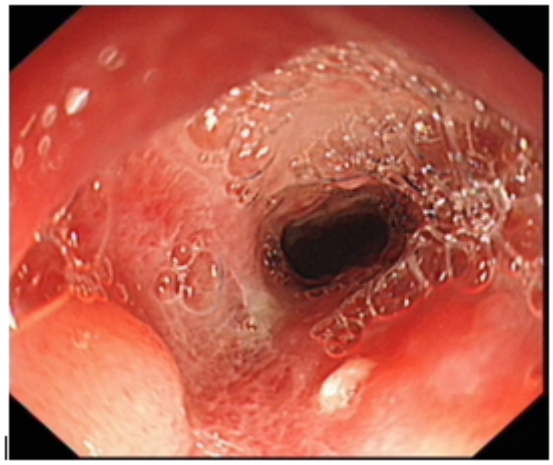

Figure 11

EGD showing fistula of duodenum.

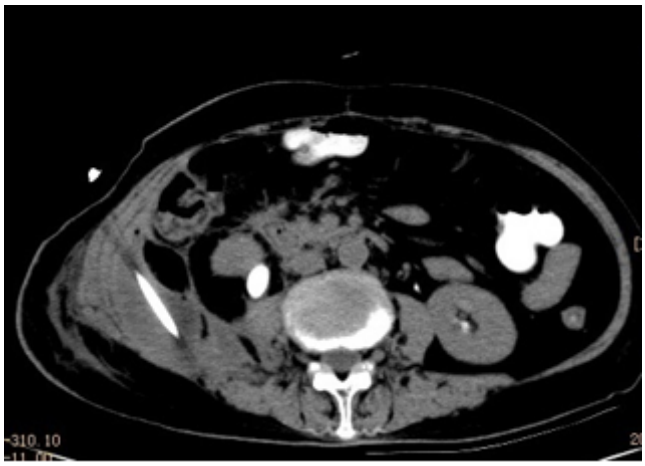

Figure 12

Placed the abscess drainage tube under CT guidance.

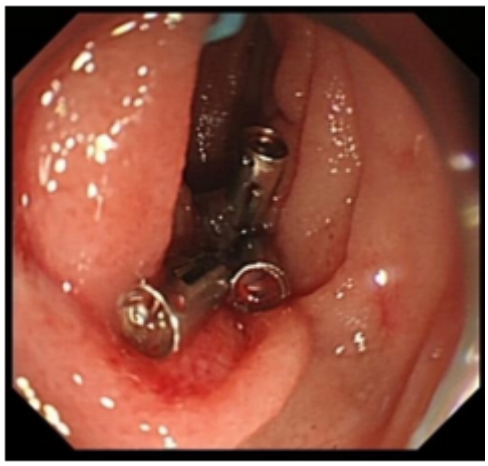

Figure 13

Endoscopic closure of duodenal fistula was performed.

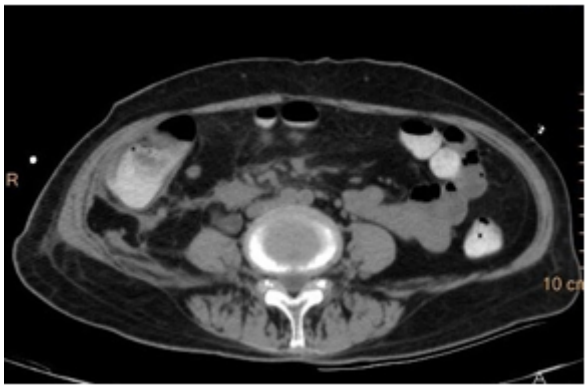

Figure 14

The last CT showing the retroperitoneal abscess disappeared.

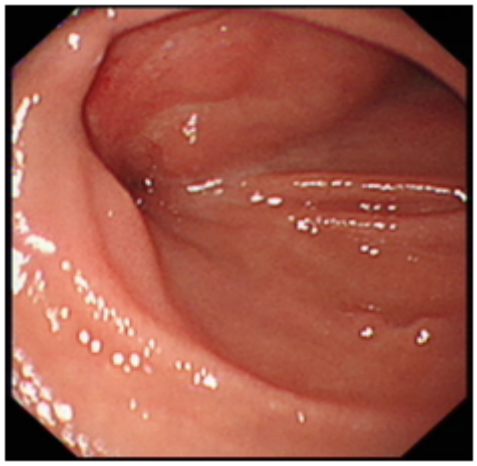

Figure 15

The last EGD showing duodenal fistula was completely closed.